

Successful treatment with lamivudine may correlate with reduction of serum ferritin levels in the patients with chronic hepatitis and liver cirrhosis type B

Shogo Ohkoshi · Akira Yoshimura · Satoshi Yamamoto · Masahiko Yano ·
So Kurita · Kazuhide Yamazaki · Yo-hei Aoki · Satoshi Yamagiwa ·
Hiroto Wakabayashi · Motoya Sugiyama · Tohru Takahashi ·
Tohru Ishikawa · Yasunobu Matsuda · Takafumi Ichida · Tomoteru Kamimura ·
Yutaka Aoyagi

Received: 11 December 2007 / Accepted: 19 June 2008 / Published online: 25 July 2008
© Asian Pacific Association for the Study of the Liver 2008

Abstract

Purpose To study the changes in serum ferritin levels in lamivudine (LAM)-treated patients with chronic hepatitis and liver cirrhosis type B and determine whether successful treatment with LAM results in a reduction of serum ferritin levels.

Methods Thirty patients with chronic hepatitis B virus (HBV) infection were followed prospectively during their

treatment with LAM for 12 months. Serum HBV DNA, ferritin levels, and emergence of YMDD mutants were monitored. A case of severe liver cirrhosis with hepatic hemosiderosis that was treated successfully with LAM also is shown as a representative case.

Results Serum alanine aminotransferase and ferritin levels decreased significantly more in the patients treated with LAM without YMDD mutants ($n = 23$) than those with mutants ($n = 7$). Hepatic hemosiderosis along with serum iron markers improved greatly in the representative patient.

Conclusion Successful treatment with LAM may reduce serum ferritin levels and improve hepatic siderosis in a subset of patients with chronic HBV infection.

A study of Niigata-Zeffix investigation meeting.

S. Ohkoshi (✉) · A. Yoshimura · M. Yano · S. Kurita ·
K. Yamazaki · Y. Aoki · S. Yamagiwa · Y. Matsuda ·
Y. Aoyagi

Division of Gastroenterology and Hepatology, Graduate School
of Medical and Dental Sciences of Niigata University, 1-754,
Asahimachi-Dori, Niigata-city 951-8122, Japan
e-mail: okoshi@med.niigata-u.ac.jp

S. Yamamoto
Division of Radiology, Graduate School of Medical and Dental
Sciences of Niigata University, 1-754, Asahimachi-Dori,
Niigata-city 951-8122, Japan

H. Wakabayashi
Takeda General Hospital, Fukushima, Japan

M. Sugiyama
Shibata Hospital, Niigata, Japan

T. Takahashi
Nagaoka Red Cross Hospital, Niigata, Japan

T. Ishikawa · T. Kamimura
Saiseikai daini Hospital, Niigata, Japan

T. Ichida
Juntendo-University Hospital of Shizuoka, Shizuoka, Japan

Keywords Lamivudine · Chronic hepatitis ·
Liver cirrhosis · Ferritin · YMDD mutant

Introduction

Hepatitis B virus (HBV) is one of the major causes of liver cirrhosis and hepatocellular carcinoma (HCC) [1–3]. Progression of liver disease is caused by inflammation due to active replication of HBV. It is thus important to implement antiviral therapy against chronic hepatitis B to minimize liver damage [4, 5].

Lamivudine (LAM), the first-licensed anti-HBV drug in Japan, has been shown to be effective in inhibiting HBV replication [6, 7]. A significant improvement in necroinflammation activity has been shown following LAM treatment [8]. However, deterioration of the clinical course results from the emergence of YMDD mutants during treatment [9, 10]. Frequently this may cause an acute flare of alanine aminotransferase (ALT), probably attributable to the immune response to the newly developed variants.

Iron overload is observed frequently in the livers of patients with chronic viral hepatitis [11]. It has been suggested that iron overload may facilitate virus replication in hepatocytes and virus-infected liver cells may tend to accumulate iron. In addition, cirrhosis alone may cause iron overload and this state is common in patients with end-stage liver cirrhosis [12, 13]. Hepatic siderosis may improve with successful interferon treatment of patients with chronic hepatitis C [14].

Liu et al. [15] reported that the LAM treatment could reduce the serum ferritin levels in patients with chronic HBV infection. In this study, we show that patients who were treated successfully with LAM without the emergence of YMDD mutants had a clear reduction in their serum ferritin levels. We also describe a patient with severe hepatic siderosis, accompanying end-stage liver cirrhosis due to HBV infection, who showed a reduction of iron accumulation following successful treatment with LAM.

Materials and methods

Patients

We studied prospectively 30 patients with chronic HBV infection. The patients' characteristics are shown in Table 1. Liver biopsy was performed in 21 patients (70%). Six (20%) had histologically proven liver cirrhosis (F4). All patients received LAM treatment for more than 1 year and the first 12 months of treatment were analyzed. Individual

Table 1 Patient profile and laboratory data at commencement of lamivudine therapy in 30 patients with chronic hepatitis B or cirrhosis

Demographic data	
Number	30
Sex, M/F	24/6
Age, years	45(26–67)
Family history of HBV carrier	14 (45%)
Laboratory data	
Serum alanine aminotransferase, IU/l	161 (31–835)
Serum albumin, g/dl	4.1(2.5–5.1)
Platelet count, $\times 10^4/\text{mm}^3$	13.7(4.4–23.1)
Serum ferritin, ng/ml	163(15–602)
Virological data	
HBV DNA, LGE/ml	6.8(3.9–>8.7)
HBeAg(+/-)	18/12
Genotype(C:B)	29/1
Precore(wild/mutant/mixture)	14/9/7
Core promoter(wild/mutant/n.d)	3/25/2
Histological findings	
Stage (F1/F2/F3/F4/n.d) ^a	6/5/4/6/9

Data are expressed as median (range). n.d (not detected)

^a Stage of chronic hepatitis by Desmet et al. [26]

biochemical data and serum HBV DNA levels were obtained each month. Detection of YMDD mutants was carried out 6 and 12 months after the initiation of treatment. In addition to these patients, we present a single case with liver cirrhosis type B in whom successful treatment by LAM brought a marked improvement of serum iron markers.

Methods

HBV genotype and precore and core promoter mutations were detected using a commercial kit (Genome Science Laboratory, Japan). HBV DNA concentrations were determined using the transcription-mediated amplification (TMA) test. YMDD mutants were detected by a mini-sequencing method (Genome Science Laboratory, Japan).

Statistical analysis

The results were expressed as means \pm standard deviation. Student's *t* test was used for statistical analysis as appropriate. A *P* value of < 0.05 was considered statistically significant.

Results

Seven (7/30, 23%) patients had developed YMDD mutants at 12 months after the initiation of LAM treatment. Serum ALT levels were significantly higher in patients with mutants at 12 months ($P \leq 0.01$) (Fig. 1a). All seven patients with mutants had an elevation of ALT levels that showed breakthrough hepatitis. All 23 patients without mutants had HBV DNA levels below the detection limit (< 3.7 LGE/ml), whereas seven patients with mutants had detectable HBV DNA levels at 12 months (Fig. 1b). Serum ferritin levels decreased at 6 months of treatment, along with a decrease of ALT and HBV DNA levels. They increased in patients in whom mutants appeared along with an increase of ALT and HBV DNA values, whereas they continued to decrease in patients without mutants ($P < 0.01$ at 12 months after the treatment) (Fig. 1c).

We analyzed serum iron and unsaturated iron-binding capacity (UIBC) levels in the course of LAM treatment (Table 2). Although there were no significant changes in serum iron levels between each time point after the initiation of treatment, irrespective of the appearance of mutants, the mean UIBC value at 12 months posttreatment was significantly higher than pretreatment in patients without mutants ($P < 0.05$).

Case

A 55-year-old Japanese man had been followed for chronic HBV infection since 1988. Interferon therapy was ineffective

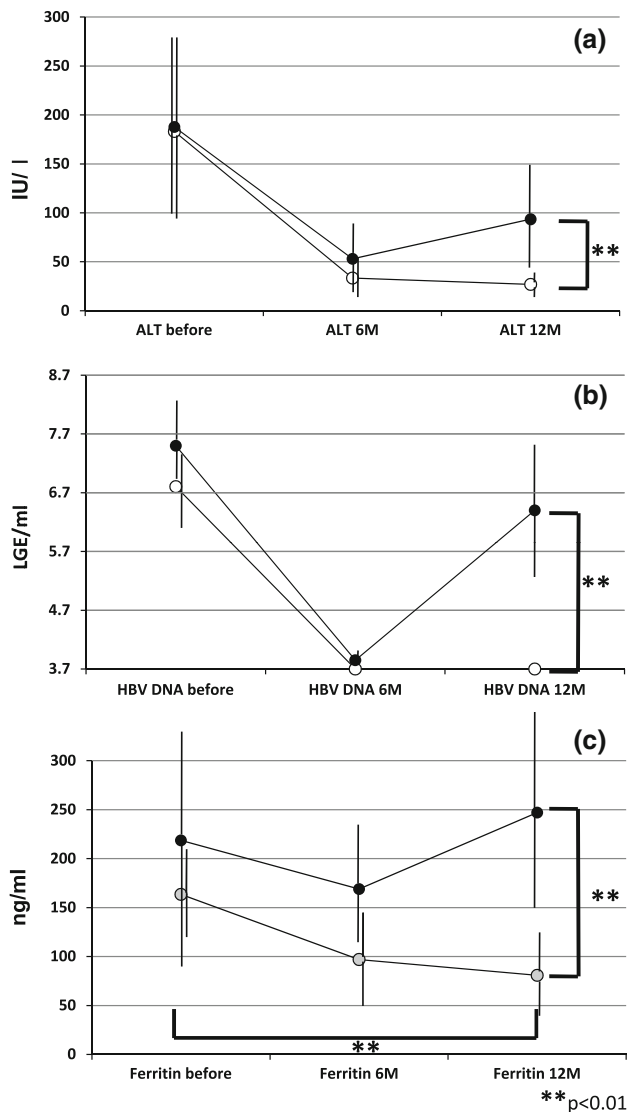


Fig. 1 Changes of serum ALT (a), HBV DNA (b), and ferritin levels before and at 6 and 12 months after LAM treatment. Open and closed circles indicate the values for YMDD mutant (-) and (+), respectively. All three values were significantly higher in the patients with mutants than those without mutants at 12 months after the treatment (** $P < 0.01$). Serum ferritin levels decreased significantly 12 months after treatment in the patients without mutants

and the disease progressed to liver cirrhosis. Liver biopsy in 1999 showed hemosiderotic nodules (Fig. 2). Because of the enhancement of jaundice and appearance of ascites, he was hospitalized in July 2001. He was HBeAg positive and his serum HBV DNA level was 7.6 LGE/ml. Serum iron, UIBC, and ferritin levels were 167 $\mu\text{g/dl}$, 7 $\mu\text{g/dl}$, and 291.7 ng/ml , respectively. Abdominal CT scan showed diffuse high-density nodules and magnetic resonance imaging (MRI) showed multiple nodules, with markedly low-signal intensities by T1-weighted gradient echo MRI and with longer TE (echo time) revealing hemosiderotic nodules [16] (Fig. 3a, b: left). Changes in laboratory findings (Fig. 4a), serum ferritin levels

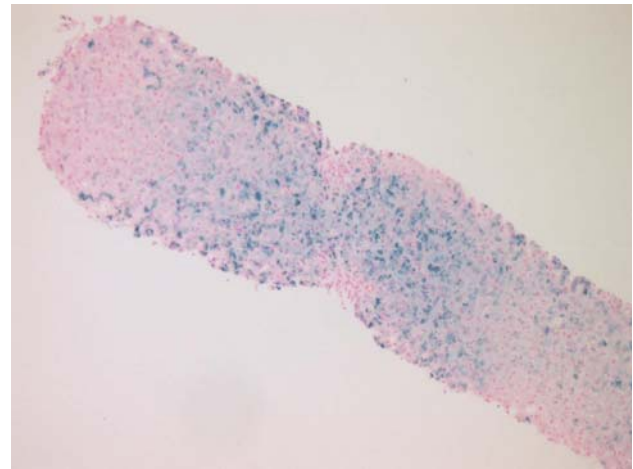


Fig. 2 Liver biopsy obtained in July 1999. Perl's Prussian blue staining demonstrated that hepatocytes were stained intensely and formed hemosiderotic nodules

Table 2 Changes of serum iron and UIBC levels in the patients treated with LAM. Mean SD values are shown

	Before	6 M	12 M
Fe ($\mu\text{g/dl}$)			
Mutant(-)	162 \pm 62	130 \pm 51	137 \pm 57
Mutant(+)	127 \pm 50	136 \pm 30	125 \pm 38
UIBC ($\mu\text{g/dl}$)			
Mutant(-)	188 \pm 93*	215 \pm 68	221 \pm 70*
Mutant(+)	187 \pm 48	173 \pm 72	184 \pm 63

* $P < 0.05$

(Fig. 4b), and iron and UIBC levels (Fig. 4c) are shown. HBV DNA became undetectable 6 months after the initiation of therapy and remained undetectable thereafter. Break-through hepatitis due to a YMDD mutant strain was not observed. Serum ALT, albumin, and jaundice levels improved gradually. Along with these findings, serum iron and ferritin levels decreased gradually and UIBC levels increased. CT scanning, 30 months after the initiation of LAM, showed a marked reduction of high-density nodules and MRI, 36 months after, also showed a reduction in the number of hemosiderotic nodules (Fig. 3a, b: right). These findings revealed a marked improvement of hepatic hemosiderosis with LAM treatment.

We looked for mutations of the HFE gene using DNA from white blood cells after informed consent was obtained [17]. We could not detect either the C282Y or the H63D mutations by PCR-RFLP analysis (data not shown).

Discussion

A large number of studies have explored the relationship between iron and chronic viral hepatitis [11]. Several

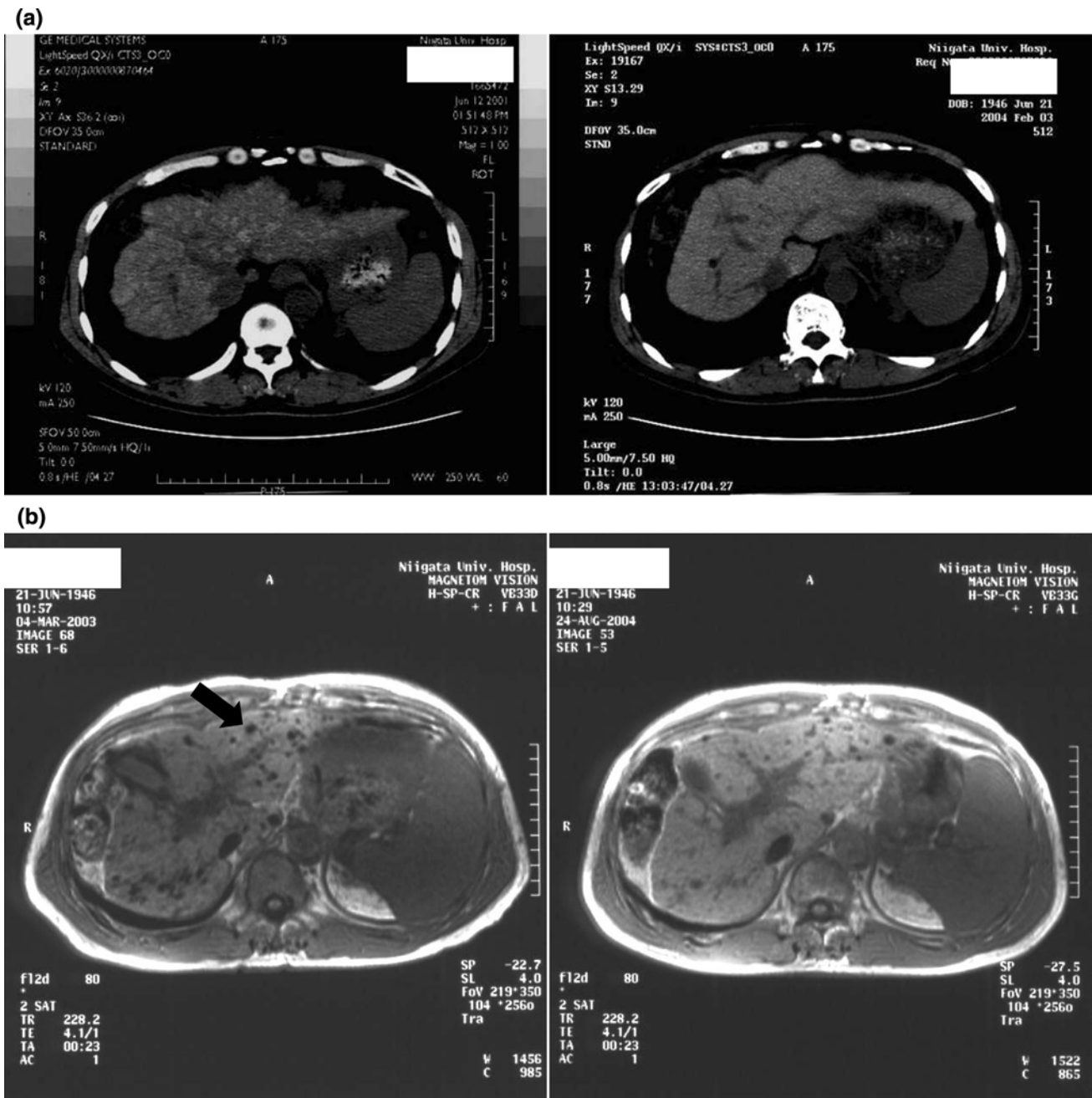


Fig. 3 (a) Abdominal CT scan showing a cirrhotic liver with severe atrophy and diffuse high-density nodules (left) that were considered to be hemosiderotic nodules, with a marked improvement of these findings 30 months after the initiation of LAM therapy (right).

Hemosiderotic nodules were revealed as multiple hepatic nodules with markedly low-signal intensities (arrow) by T1-weighted gradient echo MRI with longer TE (echo time) (b) [16]. Their number relatively decreased 36 months after the initiation of therapy (right)

investigators have noted a high prevalence of elevated serum iron transferrin and ferritin levels in subjects with chronic viral hepatitis [18, 19]. It is implied that active HBV replication increases ferritin synthesis, resulting in increased liver iron storage [20, 21]. In addition, elevated serum ferritin levels are caused by active hepatitis, perhaps reflecting a release of ferritin and ALT from damaged hepatocytes and the upregulation of serum ferritin levels

may be a part of the inflammatory response [11]. This may imply that serum ferritin levels are directly correlated with ALT levels [18]. Successful antiviral treatment, resulting in the reduction of virus replication, may normalize the serum ALT levels and reduce the ferritin levels. Liu et al. [15] showed that LAM could reduce the serum ferritin levels in patients with chronic HBV infection. The effect was more significant in patients exhibiting virological, serological,

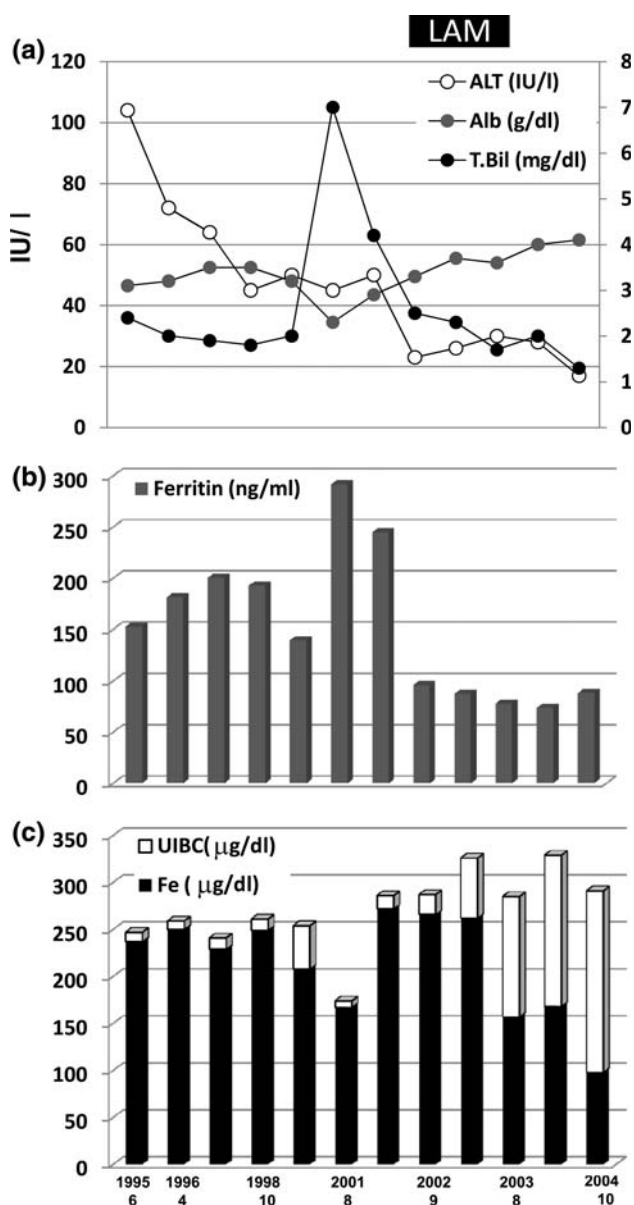


Fig. 4 Changes of laboratory findings before and after the initiation of LAM therapy. Left and right vertical axes show the ALT, serum albumin, and bilirubin values, respectively. There was an amelioration of liver function, that is, a decrease of ALT and bilirubin levels and increase of albumin levels after the start of LAM (a). A marked reduction of serum ferritin levels (b), as well as a reduction of serum iron and increase of UIBC levels, was observed after the start of LAM treatment

and biochemical responses. However, they did not address the relationship between the iron-decreasing effect of LAM and the emergence of YMDD mutants.

In this study, 23 of 30 (77%) patients had undetectable serum HBV DNA levels after 12 months of LAM treatment, whereas seven (23%) had detectable levels of HBV DNA. Because YMDD mutants were detected only in seven patients who were positive for HBV DNA, there was a clear correlation of positivity of HBV DNA with the

emergence of mutants. Serum ALT levels were significantly lower in patients who had undetectable HBV DNA. Interestingly, serum ferritin levels were significantly lower in patients who had lower ALT and undetectable levels of HBV DNA (i.e., those with mutants) than those with higher ALT and HBV DNA levels (i.e., those without mutants). These results show that the ferritin-decreasing effect of LAM was evident in patients exhibiting virological and biochemical responses [15] and this effect was diminished when YMDD mutants emerged and ALT and HBV DNA levels became elevated. This reflects the clear correlation between replication of HBV and flare up of hepatitis and the elevation of ferritin levels. Thus, serum ferritin levels may correlate clearly with the activity of hepatitis [18]. Successful long-term LAM therapy may maintain this improvement as long as an emergence of mutants does not occur.

In addition to the ferritin-decreasing effect of LAM in the cohort of 30 patients, we present a single case of a patient with end-stage liver cirrhosis type B who was treated with LAM. Severe iron overload is seen frequently in patients with end-stage liver cirrhosis [12, 13]. This might be the case with this patient whose iron accumulation in the liver may have been the consequence of long-standing inflammation due to active replication of HBV. Successful LAM therapy brought a long-term suppression of HBV replication and an improvement of liver function. Both effects were considered to result in a dramatic reduction in the iron accumulation that had occurred in the liver.

Although serum ferritin levels decreased significantly with the reduction of serum HBV DNA and ALT levels, we could not observe dramatic changes of serum iron and UIBC levels in 30 patients, such as was seen in the representative patient. Serum UIBC levels increased significantly after 12 months of treatment only in the patients without mutants (Table 2). The progress of liver damage and accumulation of iron were not as severe in 30 patients as in the particular case, so that the iron-decreasing effect of LAM was more marginal than that observed in the case.

There is a close relationship between iron accumulation and hepatocarcinogenesis [22]. A direct effect of iron on cellular proliferation and an indirect effect on the formation of reactive oxygen species within the liver have been considered [22]. A positive effect of phlebotomy on chronic hepatitis C infection has also been confirmed [23]. Long-term phlebotomy with a low-iron diet lowers the risk of development of HCC in chronic hepatitis C infection [24]. Recently, LAM has been shown to reduce the incidence of HCC in patients with chronic HBV infection [25].

In summary, this preliminary study shows that effective antiviral treatment with LAM may reduce iron accumulation in the liver. Successive anti-HBV treatment possibly might lower the risk of HCC by both the suppression of

inflammation due to HBV replication and the iron-reducing effect. This hypothesis should be tested in the future large-scale study.

Acknowledgment We thank Ms. Naomi Cho for her technical assistance.

References

1. Sherlock S. Viruses and hepatocellular carcinoma. *Gut* 1994;35: 828–832
2. Omata M, Yoshida H. Prevention and treatment of hepatocellular carcinoma. *Liver Transpl* 2004;10(2 Suppl 1):S111–S114
3. Chu CM, Liaw YF. Hepatitis B virus-related cirrhosis: natural history and treatment. *Semin Liver Dis* 2006;26(2):142–152
4. Hoofnagle JH, di Bisceglie AM. The treatment of chronic viral hepatitis. *N Engl J Med* 1997;336:347–356
5. Lok AS, Heathcote EJ, Hoofnagle JH. Management of hepatitis B: 2000—summary of a workshop. *Gastroenterology* 2001;120: 1828–1853
6. Doong SL, Tsai CH, Schinazi RF, Liotta DC, Cheng YC. Inhibition of the replication of hepatitis B virus in vitro by 2', 3'-dideoxy-3'-thiacytidine and related analogues. *Proc Natl Acad Sci U S A* 1991;88:8495–8499
7. Dienstag JL, Perrillo RP, Schiff ER, Bartholomew M, Vicary C, Rubin M. A preliminary trial of lamivudine for chronic hepatitis B infection. *N Engl J Med* 1995;333:1657–1661
8. Lai CL, Chien RN, Leung NW, Chang TT, Guan R, Tai DI, et al. A one-year trial of lamivudine for chronic hepatitis B. Asia Hepatitis Lamivudine Study Group. *N Engl J Med* 1998;339(2): 61–68
9. Allen MI, Deslauriers M, Andrews CW, Tipples GA, Walters KA, Tyrrell DL, et al. Identification and characterization of mutations in hepatitis B virus resistant to lamivudine. Lamivudine Clinical Investigation Group. *Hepatology* 1998;27: 1670–1677
10. Buti M, Jardi R, Cotrina M, Rodriguez-Frias F, Esteban R, Guardia J. Transient emergence of hepatitis B variants in a patient with chronic hepatitis B resistant to lamivudine. *J Hepatol* 1998;28:510–513
11. Bonkovsky HL, Banner BF, Rothman AL. Iron and chronic viral hepatitis. *Hepatology* 1997;25:759–768
12. Ludwig J, Hashimoto E, Porayko MK, Moyer TP, Baldus WP. Hemosiderosis in cirrhosis: a study of 447 native livers. *Gastroenterology* 1997;112:882–888
13. Deugnier Y, Turlin B, le Quilleuc D, Moirand R, Loreal O, Messner M, et al. A reappraisal of hepatic siderosis in patients with end-stage cirrhosis: practical implications for the diagnosis of hemochromatosis. *Am J Surg Pathol* 1997;21:669–675
14. Kageyama F, Kobayashi Y, Kawasaki T, Toyokuni S, Uchida K, Nakamura H. Successful interferon therapy reverses enhanced hepatic iron accumulation and lipid peroxidation in chronic hepatitis C. *Am J Gastroenterol* 2000;95:1041–1050
15. Liu ZW, Han QY, Zhang N, Kang W. Sequential changes of serum ferritin levels and their clinical significance in lamivudine-treated patients with chronic viral hepatitis B. *World J Gastroenterol* 2004;10:972–976
16. Ito K, Mitchell DG. Imaging diagnosis of cirrhosis and chronic hepatitis. *Intervirology* 2004;47:134–143
17. Shiono Y, Ikeda R, Hayashi H, Wakusawa S, Sanae F, Takikawa T, et al. C282Y and H63D mutations in the HFE gene have no effect on iron overload disorders in Japan. *Intern Med* 2001;40: 852–856
18. Di Bisceglie AM, Axiotis CA, Hoofnagle JH, Bacon BR. Measurements of iron status in patients with chronic hepatitis. *Gastroenterology* 1992;102:2108–2113
19. Arber N, Konikoff FM, Moshkowitz M, Baratz M, Hallak A, Santo M, et al. Increased serum iron and iron saturation without liver iron accumulation distinguish chronic hepatitis C from other chronic liver diseases. *Dig Dis Sci* 1994;39:2656–2659
20. Lustbader ED, Hann HW, Blumberg BS. Serum ferritin as a predictor of host response to hepatitis B virus infection. *Science* 1983;220:423–425
21. Cohen C, Berson SD, Shulman G, Budgeon LR. Liver iron stores and hepatitis B antigen status. *Cancer* 1985;56:2201–2204
22. Kowdley KV. Iron, hemochromatosis, and hepatocellular carcinoma. *Gastroenterology* 2004;127:S79–S86
23. Heathcote EJ. Prevention of hepatitis C virus-related hepatocellular carcinoma. *Gastroenterology* 2004;127(5 Suppl 1): S294–S302
24. Kato J, Miyanishi K, Kobune M, Nakamura T, Takada K, Takimoto R, et al. Long-term phlebotomy with low-iron diet therapy lowers risk of development of hepatocellular carcinoma from chronic hepatitis C. *J Gastroenterol* 2007;42:830–836
25. Matsumoto A, Tanaka E, Rokuhara A, Kiyosawa K, Kumada H, Omata M, et al. Efficacy of lamivudine for preventing hepatocellular carcinoma in chronic hepatitis B: a multicenter retrospective study of 2795 patients. *Hepatol Res* 2005;32: 173–184
26. Desmet VJ, Gerber M, Hoofnagle JH, Manns M, Scheuer PJ. Classification of chronic hepatitis: diagnosis, grading and staging. *Hepatology* 1994;19:1513–1520