

# Gallbladder perforation in a patient with alcoholic liver cirrhosis and asymptomatic gallstones

## A case report

Xiaoju Shi, MM<sup>a</sup>, Shuo Jin, MM<sup>b</sup>, Siyuan Wang, MM<sup>c</sup>, Weijie Tao, MM<sup>d</sup>, Guangyi Wang, MD<sup>a,\*</sup>

### Abstract

**Rationale:** Gallbladder perforation is a relatively uncommon complication of alcoholic liver cirrhosis and may happen with or without gallstones.

**Patient concerns:** Here we report a 52-year-old male patient who was diagnosed as gallbladder perforation with chronic liver cirrhosis and asymptomatic gallstones. The patient was admitted with acute and severe abdominal pain during weight-bearing physical labor. He had a history of alcoholic liver cirrhosis but no chronic abdominal pain or gallstones. The patient presented with localized peritoneal irritation, and abdominal puncture showed non-clotting blood. A preliminary clinical diagnosis was made as hepatocellular carcinoma rupture based on imaging findings. However, this diagnosis changed to gangrenous cholecystitis with gallbladder perforation by the laparotomy examination.

**Diagnoses:** He was diagnosed with gangrenous cholecystitis with gallbladder perforation.

**Interventions and outcomes:** The patient performed well postoperatively.

**Lessons:** This case suggests that gallbladder perforation should be considered as a potential cause of acute abdominal pain even without evidence of gallstones. Early examination with a laparotomy examination can help achieve a timely diagnosis.

**Abbreviations:** CT = computed tomography, HCC = hepatocellular carcinoma, MELD = model of end-stage liver disease.

**Keywords:** abdominal pain, diagnostic errors, gallbladder diseases

## 1. Introduction

Gallstone disease is a worldwide medical problem and is often described as a major affliction in modern society.<sup>[1]</sup> As one liver disorder, gallstones usually develop after a longer duration of cirrhosis, a common disease that may develop as the end-stage of chronic liver diseases.<sup>[2]</sup> The pathological hallmark of cirrhosis is the development of scar tissue that replaces normal parenchyma. This scar tissue blocks the portal flow of blood through the organ, raising the blood pressure and disturbing normal function. The prevalence of gallstone in cirrhotic patients is estimated to range from 25% to 30%. Gallstones in cirrhotic patients pose a significant challenge as

morbidity and mortality with acute complications are high. Moreover, approximately 1% to 2% of patients with gallstones are reported to develop secondary acute cholecystitis,<sup>[3]</sup> among which 2% to 11% will progress to gallbladder perforation,<sup>[4,5]</sup> a rare but life threatening complication of acute cholecystitis. Gallbladder perforation represents a special diagnostic and surgical challenge because of the high mortality (predicted as high as 70%) caused by a delay in the correct diagnosis and following adequate surgical treatment.<sup>[6]</sup> It is described that only 3% of patients with gallbladder perforations are timely and correctly diagnosed before surgery, and the remaining patients succumb to this disease due to a delayed diagnosis.<sup>[5]</sup>

Perforation is thought to result from occlusion of the cystic duct, resulting in retention of intraluminal secretions. Distention of the organ with a consequent rise in intraluminal pressure impedes venous and lymphatic drainage, leading to vascular compromise and ultimately to necrosis and perforation of the gallbladder wall.<sup>[7]</sup> Niemeier<sup>[8]</sup> classified perforations into 3 categories: type I includes patients with free perforation into the peritoneal cavity, type II describes patients with localized perforation, and type III patients with cholecysto-enteric fistulas. There are no classical symptoms, thus signs of perforation diagnosis is challenging. Right upper quadrant pain, palpable right upper quadrant tenderness, or high fever are regarded as the cardinal symptoms of gallbladder perforation. These symptoms, however, may be caused by various factors and lead to a misdiagnosis.<sup>[4,9–12]</sup> A delay in the correct diagnosis and following adequate surgical treatment results in the high mortality of gallbladder perforation.<sup>[13]</sup> Thus, it is of high importance to distinguish patients of gallbladder perforation from those with acute abdominal pain.

Editor: Ewa Janczewska.

The authors declare no conflicts of interests.

<sup>a</sup> Department of Hepatobiliary Surgery, the First Hospital of Jilin University, Chaoyang District, Changchun, Jilin, <sup>b</sup> Department of General Surgery, Beijing Tsinghua Changgung Hospital Medical Center, Tsinghua University, <sup>c</sup> Department of ICU, Capital Medical University Affiliated Chao-Yang Hospital, Beijing, <sup>d</sup> Department of General Surgery, Tianjin Union Medical Center, Tianjin, China.

\* Correspondence: Guangyi Wang, Department of Hepatobiliary Surgery, the First Hospital of Jilin University, 71 Xinmin Avenue, Changchun 130021, Jilin, China (e-mail: Guangyi\_Wang123@126.com).

Copyright © 2018 the Author(s). Published by Wolters Kluwer Health, Inc. This is an open access article distributed under the terms of the Creative Commons Attribution-Non Commercial-No Derivatives License 4.0 (CCBY-NC-ND), where it is permissible to download and share the work provided it is properly cited. The work cannot be changed in any way or used commercially without permission from the journal.

Medicine (2018) 97:18(e0414)

Received: 1 September 2017 / Received in final form: 3 January 2018 /

Accepted: 16 March 2018

<http://dx.doi.org/10.1097/MD.0000000000010414>

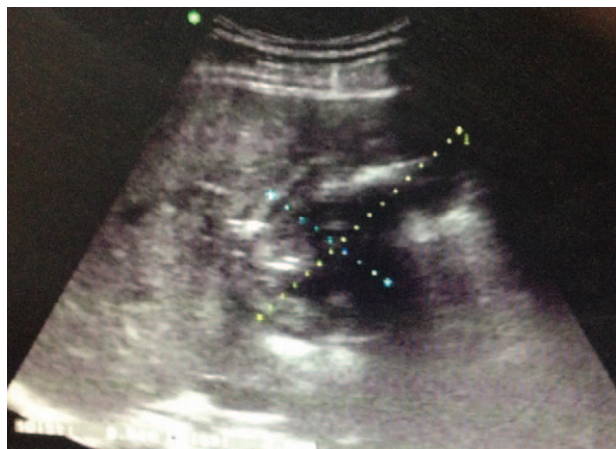
In this study, a case of acute abdominal pain caused by gallbladder perforation was reported, which was also diagnosed with chronic liver cirrhosis.

## 2. Case presentation

The enrolled patient information was approved by the Ethics Committee of Bethune First Hospital of Jilin University, and the patient signed the informed consent.

A 52-year-old male patient was admitted to the Department of Hepatobiliary and Pancreatic Surgery at the First Affiliated Hospital of the Bethune Medical College, Jilin University in June 2013. He complained of severe abdominal pain induced by weight-bearing physical labor, and the pain was acute, dull, and persistent but tolerable and unrelated to postural changes. His admission blood pressure was 110/80 mmHg, heart rate was 95 beats per minute, and body temperature was 38.2 °C. The patient had no obvious signs of jaundice or sclera icterus, but had symptoms of mild anemia and the gallbladder tenderness in the right upper quadrant. Laboratory data revealed: white blood cell count  $10.54 \times 10^{12}/L$  with neutrophil accounting for 83%, hemoglobin 111 g/L, aspartate aminotransferase 56 U/L, total bilirubin 39.3  $\mu\text{mol}/L$ , direct bilirubin 19.8  $\mu\text{mol}/L$ , serum creatinine 200  $\mu\text{mol}/L$ , urea nitrogen 20 mmol/L, and creatinine clearance rate 34.5 mL/min. Additionally, the patient had a long history of intemperance, but no history of viral hepatitis. Abdominal puncture found non-coagulating blood.

Ultrasonography of abdomen identified a solitary,  $70 \times 59$  mm, hypoechoic area in the region of right lobe (Fig. 1). Additionally, ultrasonography combined with computed tomography (CT) of abdomen discovered the presences of liver cirrhosis, portal hypertension, unclear gallbladder, and ascites. An enhanced CT further revealed the abnormal liver in size and rough in texture, which showed less structured shape and low-density lesions with unclear boundaries in right lobe posterior segment, as well as signs of rupture and bleeding (Fig. 2). Based on the arterial phase of CT scan, enhancement was not observed, however, the degree of venous and delayed phase enhancement appeared to be higher than that of normal liver parenchyma. In addition, the gallbladder was observed to enlarge, with a thick wall and stratified structures. In the gallbladder, there was a high cavity density, and nodular calcifications (0.7 cm in size) in the cavity. Liquid was detected on the liver, spleen, and in intestinal



**Figure 1.** Ultrasonography of abdomen. Ultrasonography showed a solitary,  $70 \times 59$  mm, hypoechoic area in the region of right lobe.

gaps. Based on the patient's clinical history and the examinations above which suggested the presence of liver cirrhosis in the right lobe with unknown nature, cholecystitis and gallstones, and ascites with blood clots, the patient was initially diagnosed as hepatocellular carcinoma (HCC) rupture, alcoholic liver cirrhosis, portal hypertension, gallstones, and cholecystitis.

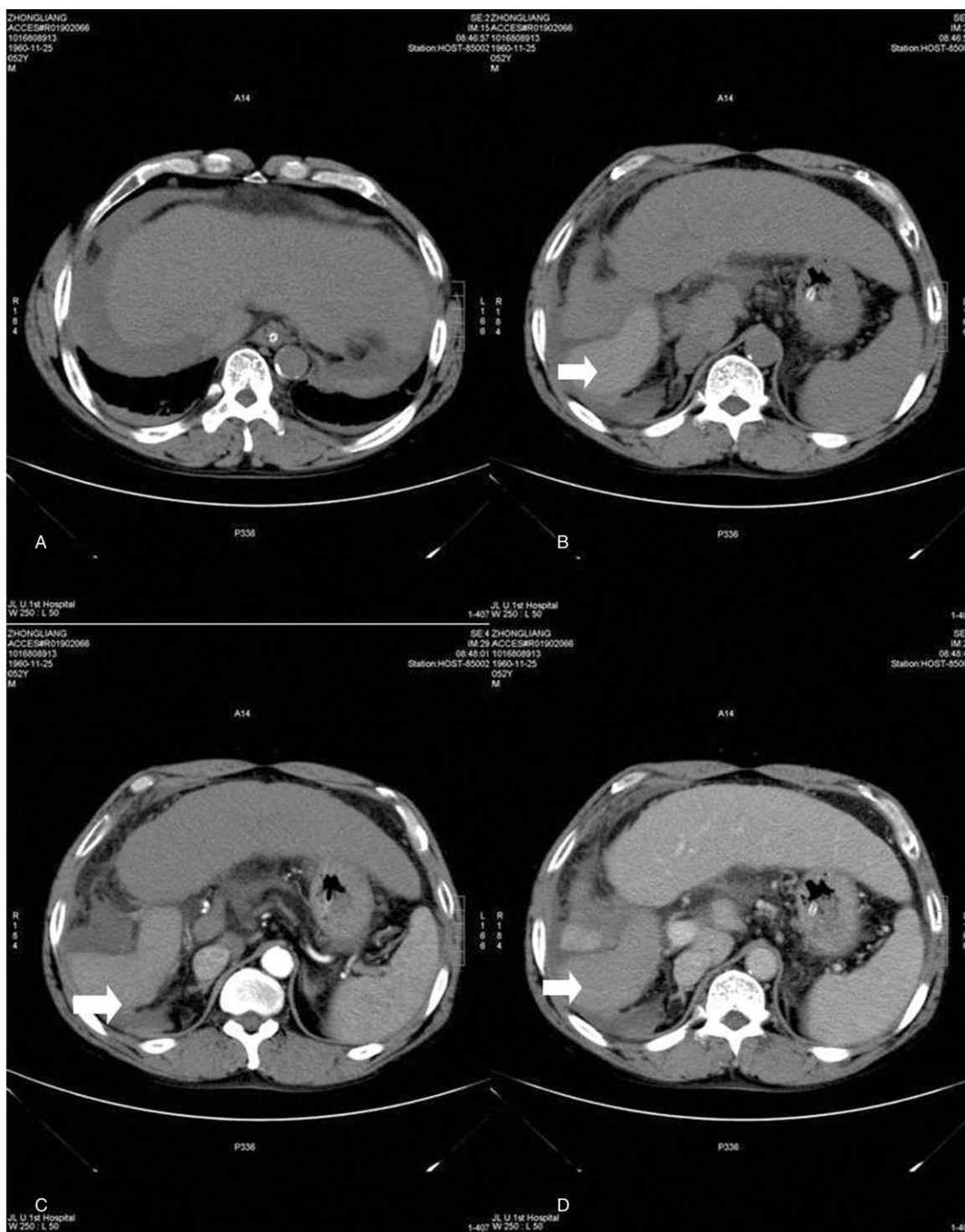
After symptomatic treatments, including hemostasis, anti-inflammation, and hepatoprotection, hemoglobin levels along with liver and kidney functions regressed to normal. Model of end-stage liver disease (MELD) score was 24. Child-Pugh scoring of the severity of disease obtained score of 9 (Child-Pugh B). Then, laparotomy was performed 46 hours after admission, which confirmed the presence of hemoperitoneum with approximately 1000 mL and mainly on the right edge of the liver. Additionally, the liver showed nodular sclerosis, right lobe atrophy, and left lobe proliferation. Nevertheless, no visible occupying lesions on the surface of the liver or visible nodular in the intestinal, mesenteric, or pelvic areas were found. The gallbladder, with  $13 \times 5$  cm in size, showed fold-like changes in the gallbladder body and diffused gangrene in the gallbladder wall. An occupying lesion was discovered in gallbladder by CT scan. A perforation, approximately 1 cm in size, with surrounding black blood clots was identified beneath the body of gallbladder. Based on these findings, the initial clinical diagnosis of HCC was changed to gangrenous cholecystitis with perforation bleeding. To confirm the new diagnosis, a cholecystectomy was performed, during which a large number of black clots and small gallbladder stones (approximately 2~4 mm in size) were discovered in the gallbladder, as well as gangrene in 0.8 cm thickness within the gallbladder wall. Post-surgery pathogenic examination confirmed the presence of chronic cholecystitis with suppurative inflammation (Fig. 3). Besides, intraperitoneal effusion was extracted during the operation and send for bacterial culture and susceptibility testing, which suggested the presence of *Escherichia coli*. We then administrated Tienam (infusion 3g/day Q8H) for 5 days. The white blood cell count dropped to  $7.5 \times 10^{12}/L$  with neutrophil accounting for 70% in 7th day after the surgery, the liver and renal function index dropped to normal range in 10th day. The patient discharged from the hospital in 12th day after the surgery.

After 3 and 6 months of hospital discharge, the color Doppler ultrasound scanning and CT were performed and suggested no obvious abnormality in the cavity. In addition, the patient showed normal liver function, and normal diet, urination, and defecation. The body weight did not obviously change, and the daily life of the patient was well maintained.

## 3. Discussion

In this study, a case of gallbladder perforation with alcoholic liver cirrhosis and asymptomatic gallstones was reported. Based on enhanced CT scan images and the clinical history, the patient was initially diagnosed as HCC rupture. Correct diagnosis of gangrenous cholecystitis with perforation was made after further examination by a laparotomy. Based on this experience, we recommend timely laparotomy or laparoscopy examination for patients suffering from agnogenic and acute abdominal pain in order to ensure an accurate diagnosis and save the patients' lives.

If untreated, acute cholecystitis may develop into gallbladder perforations 1 or 2 days (even several weeks) after onset, which usually occur in the neck and the bottom of the gallbladder due to a compromised blood supply caused by incarcerated gallbladder stones. Gallbladder perforations can progress to peritonitis and

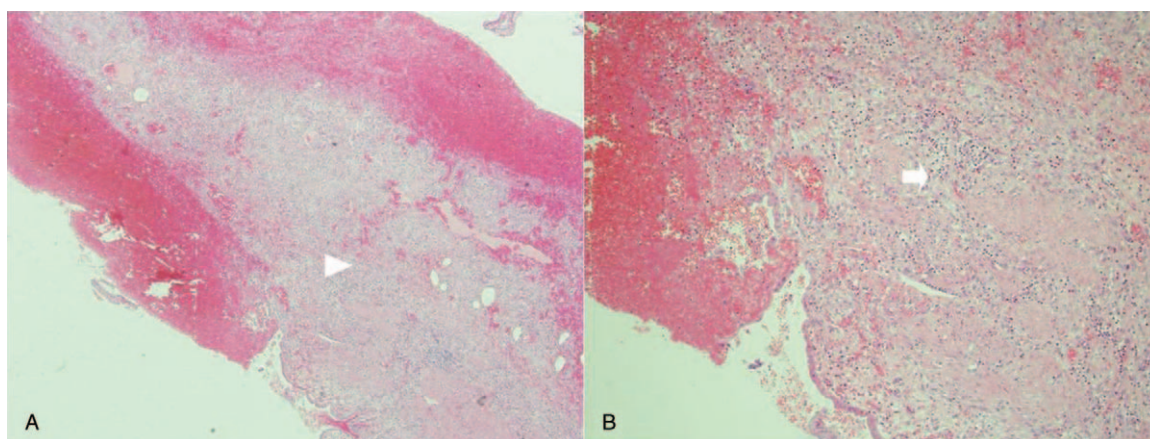


**Figure 2.** General and enhanced abdominal CT scans in three phases. A, General scan of the abdomen illustrates effusion around the liver and gas under the diaphragm. B, General scan of an occupying lesion marked by an arrow (→). C, Arterial phase shows a modest enhancement in the density of the occupying lesion as marked by an arrow (→). D, Venous phase illustrates that the density of the occupying lesion was slightly reduced and lower than that of the liver parenchyma as depicted by an arrow (→). (A laparotomy examination of the lesion in these images was originally considered hepatocellular carcinoma, but eventually confirmed to be the gallbladder perforation.).

ascites, alter normal anatomical structures, and even affect the accuracy of a CT scan diagnosis. In addition, reduced tension caused by the omentum surrounding the perforated gallbladder, made it difficult to obtain a clear CT image of the gallbladder wall. Comparing with imaging tools, an ultrasound may be more

sensitive and reproducible in detecting gallbladder perforation. Therefore, a comprehensive ultrasound at multiple positions and angles was needed performed to avoid a misdiagnosis. A previous study reported on a patient who was affected by Child-Pugh A alcoholic liver cirrhosis and developed an acute gallbladder





**Figure 3.** Pathological examination. Hematoxylin and eosin staining of the slides of gallbladder (A 10X and B 40X,) showed the presence of chronic cholecystitis with suppurative inflammation. Arrows indicate the suppurative inflammation.

perforation with spillage of stones into the peritoneal cavity.<sup>[14]</sup> On the contrary, that report considered that an early CT scan was the most important diagnostic tool, because in that case the blood in and around the gallbladder led to a misinterpretation of the sonographic image. A recent study reported a cirrhotic patients with cholecystitis and gallbladder perforation.<sup>[15]</sup> They made a correct diagnosis through ultrasonography and CT. In accordance with that study, we support the combination of an ultrasound examination with a CT scan to help improve the diagnostic accuracy of gallbladder perforations.

A retrospective study with a large amount of participants reported that 208 out of 11,360 patients who underwent a cholecystectomy were initially diagnosed with cholecystitis.<sup>[16]</sup> Of the 208 patients, 30 were finally diagnosed as gallbladder perforation, 97% of which, however, were misdiagnosed before the surgery. In the present case, the male patient was admitted to our hospital with acute abdominal pain and fever (38.2°C). Based on the patient's clinical history and the basic examinations, initially diagnosis was made as HCC rupture, alcoholic liver cirrhosis, portal hypertension, gallstones, and cholecystitis. Fortunately, a laparotomy was timely performed within 48 hours after admission, based on which we found the presence of gallstones with gangrenous cholecystitis and gallbladder perforation. Thus, the cholecystectomy was performed to prevent the spread of peritonitis, the recurrence of bleeding, and death. The patient was well recovered after the surgery and revisit observation demonstrated normal liver function, and normal diet, urination, and defecation. The body weight did not obviously change, and the daily life of the patient was well maintained. As approximately 70% of patients with gallbladder perforation are incurable due to the delay in making the correct diagnosis, we strongly recommended the performance of laparotomy or laparoscopy within 72 hours in order to reduce the mortality rates in patients with acute abdominal pain caused by liver cirrhosis and/or gallstones.

Several risk factors may contribute to the occurrence of gallbladder perforations. First, liver cirrhosis may lead to portal hypertension and gallbladder venous obstruction both of which may induce edema and increase the thickness of the gallbladder wall.<sup>[15]</sup> Second, gallstones could put pressure on the gallbladder wall, obstruct the cystic duct, lead to cholestasis, and then progress to gangrene. In addition, a bacterial infection can also cause mucosal edema in the neck of the gallbladder. In our study, the

patient was found to be present with gallstones cholecystitis, and thick gallbladder wall (8 mm) but without obvious symptoms. An abdominal CT scan showed arteriosclerosis in the abdominal aorta, suggesting a blood circulation disorder and mucosal necrosis which could also progress to gallbladder gangrene and perforation.

There were several reasons leading to the misdiagnosis of the 52-year old male patient. First, 90% to 95% of patients with gallbladder perforation also present with acute cholecystitis and gallbladder stones, and the patient in our study had a history of alcoholic liver cirrhosis, but no history of gallstones. Second, evidence of peritonitis was not obvious in this patient. A plausible explanation is that blood clots quickly filled the perforation by forming a small stone after bleeding. Third, the patient in our study had no prior history of abdominal pain. However, cholecystitis and abdominal aortic stiffness were detected in the abdominal CT scan. Therefore, we hypothesized that the gallbladder stones and acute inflammation played a role in blocking blood circulation in the gallbladder wall. We also speculated that necrotic perforation may result from coronary atherosclerosis in the terminal branches of cystic arteries.

There was a limitation in this study. The diagnosis of cirrhosis was made according to some clinical indicators obtained from ultrasonography, laboratory examination, and intraoperative observation. However, we did not confirm it with a biopsy and pathological examination.

#### 4. Conclusion

In conclusion, gallbladder perforation is a rare but very serious condition. Despite the absence of gallstones evidence, this case suggests that gallbladder perforation should be taken into consideration as a potential cause of acute abdominal pain. A misdiagnosis of HCC rupture may be made if the perforation occurs after the enlarged gallbladder is folded. Therefore, combination of an ultrasound examination with a CT scan, as well as early examination with a laparotomy examination can help achieve a timely diagnosis.

#### Acknowledgment

The authors would like to thank the Department of Pathology, the First Hospital of Jilin University, for providing pictures for this study.

## Author contributions

**Conceptualization:** Shuo Jin.

**Data curation:** Siyuan Wang.

**Formal analysis:** Siyuan Wang.

**Investigation:** Weijie Tao.

**Methodology:** Shuo Jin.

**Supervision:** Guangyi Wang.

**Visualization:** Weijie Tao.

**Writing – original draft:** Xiaoju Shi.

**Writing – review & editing:** Guangyi Wang.

## References

- [1] Njeze GE. Gallstones. *Niger J Surg* 2013;19:49–55.
- [2] Kanwal F, Hoang T, Kramer JR, et al. Increasing prevalence of HCC and cirrhosis in patients with chronic hepatitis C virus infection. *Gastroenterology* 2011;140:1182–8.
- [3] Friedman GD. Natural history of asymptomatic and symptomatic gallstones. *Am J Surg* 1993;165:399–404.
- [4] Judd ES, Phillips JR. Perforation of the gall-bladder in acute cholecystitis. *Ann Surg* 1933;98:359–61.
- [5] Macdonald JA. Perforation of the gallbladder associated with acute cholecystitis: 8-year review of 20 cases. *Ann Surg* 1966;164:849–52.
- [6] Bennett D, Plum F. *Cecil Textbook of Medicine*. WB Saunders, Philadelphia:1996.
- [7] Madrazo BL, Francis I, Hricak H, et al. Sonographic findings in perforation of the gallbladder. *AJR Am J Roentgenol* 1982;139:491.
- [8] Niemeier OW. Acute free perforation of the gall-bladder. *Ann Surg* 1934;99:922.
- [9] Fields JM, Dean AJ. Systemic causes of abdominal pain. *Emerg Med Clin North Am* 2011;29:195–210.
- [10] Ragsdale L, Southerland L. Acute abdominal pain in the older adult. *Emerg Med Clin North Am* 2011;29:429–48.
- [11] Mellado JM, Martín J, Solanas S, et al. Uncommon causes of acute abdominal pain: multidetector computed tomography pearls and pitfalls for the radiologist on call. *Curr Probl Diagn Radiol* 2012;41:179–88.
- [12] Piero P, Antonio M, Giuseppe P. Cholesterol gallstone disease. *Lancet* 2006;368:230–9.
- [13] Derici H, Kara C, Bozdag AD, et al. Diagnosis and treatment of gallbladder perforation. *World J Gastroenterol* 2006;12:7832–6.
- [14] Chiapponi C, Wirth S, Siebeck M. Acute gallbladder perforation with gallstones spillage in a cirrhotic patient. *World J Emerg Surg* 2010;5:11.
- [15] Hanson B, Roat J, Pocha C. Cholecystitis and gallbladder perforation in cirrhotic patients: a clinical dilemma. *Dig Liver Dis* 2014;46:960–1.
- [16] Stefanidis D, Sirinek KR, Bingener J. Gallbladder perforation: risk factors and outcome. *J Surg Res* 2006;131:204–8.