



Diagnostic Value of Microarray Method in Autism Spectrum Disorder, Intellectual Disability, and Multiple Congenital Anomalies and Some Candidate Genes for Autism: Experience of Two Centers

Otizm Spektrum Bozukluğu, Entellektüel Yetersizlik ve Çoklu Konjenital Anomalilerde Mikroarray Yönteminin Tanısal Değeri ve Bazı Otizm Aday Genleri: İki Merkez Deneyimi

İ Akif AYAZ¹, İ Alper GEZDIRICI², İ Elif YILMAZ GULEC³, İ Ozge OZALP⁴, İ Abdullah Huseyin KOSEOGLU⁵, İ Zeynep DOGRU⁵, İ Sinem YALCINTEPE⁶

¹Istanbul Medipol University Faculty of Medicine, Department of Medical Genetics, Istanbul, Turkey

²University of Health Sciences Turkey, Basaksehir Cam and Sakura City Hospital, Genetic Diseases Assessment Center, Istanbul, Turkey

³Istanbul Medeniyet University Faculty of Medicine, Department of Medical Genetics, Istanbul, Turkey

⁴University of Health Sciences Turkey, Adana City Training and Research Hospital, Genetic Diseases Assessment Center, Adana, Turkey

⁵Istanbul Medipol University, Genetic Diseases Assessment Center, Istanbul, Turkey

⁶Trakya University Faculty of Medicine, Department of Medical Genetics, Edirne, Turkey

ABSTRACT

Objective: This study aimed to demonstrate the diagnostic value of microarray testing in autism spectrum disorder, intellectual disability, and multiple congenital anomalies of unknown etiology, as well as to report some potential candidate genes for autism.

Methods: Microarray analysis records between January 2016 and December 2017 from two Genetic Diagnostic Centers in Turkey, Kanuni Sultan Süleyman and Adana Numune Training and Research Hospital, were compiled. Detected copy number variations (CNVs) were classified as benign, likely benign, variants of uncertain significance (VUS), likely pathogenic, and pathogenic according to American College of Medical Genetics and Genomics guidelines. The clinical findings of the some patients and the literature data were compared.

Results: In 109 (24.5%) of 445 patients, a total of 163 CNVs with reporting criterion feature were detected. Sixty-nine (42%) and 8 (5%) of these were evaluated as pathogenic and likely pathogenic, respectively. Fifteen (9%) CNVs were also evaluated as VUS. Pathogenic or likely pathogenic CNVs were detected in 61 (13.6%) of 445 patients.

Conclusions: We found that the probability of elucidating the etiology of microarray method in autism spectrum disorder, intellectual disability, and multiple congenital anomalies is 13.6% with a percentage similar to the literature. We suggest that the *MYT1L*, *PXDN*, *TPO*, and *AUTS2* genes are all strong candidate genes for autism spectrum disorders. We detailed the clinical findings of the cases and reported that some CNV regions in the genome may be associated with autism.

Keywords: Microarray, autism spectrum disorders, autism genes and CNV regions

ÖZ

Amaç: Otizm spektrum bozukluğu, zihinsel yetersizlik ve etiyolojisi bilinmeyen çoklu konjenital anomalilerde mikroarray testinin tanısal değerini göstermek ve otizm için bazı potansiyel aday genleri bildirmektir.

Yöntemler: Türkiye'deki iki Genetik Tanı Merkezi Kanuni Sultan Süleyman ve Adana Numune Eğitim ve Araştırma Hastanesi'nin Ocak 2016 ile Aralık 2017 tarihleri arasında mikroarray analiz kayıtları derlendi. Tespit edilen kopya sayısı değişimleri (CNV), Amerikan Tıbbi Genetik ve Genomik Koleji kriterlerine göre iyi huylu, olası iyi huylu, klinik önemi belirsiz, olası patojenik ve patojenik olarak sınıflandırıldı. Bazı hastaların klinik bulguları ile literatür verileri karşılaştırıldı.

Bulgular: Dört yüz kırk beş hastanın 109'unda (%24,5) raporlama kriteri özelliğine sahip toplam 163 CNV tespit edildi. Bunların 69'u (%42) ve 8'i (%5) sırasıyla patojenik ve olası patojenik olarak değerlendirildi. On beş (%9) CNV de klinik önemi belirsiz varyant olarak değerlendirildi. Dört yüz kırk beş hastanın 61'inde (%13,6) patojenik veya olası patojenik CNV tespit edildi.

Sonuçlar: Otizm spektrum bozukluğu, zihinsel yetersizlik ve çoklu doğumsal anomalilerde mikroarray yönteminin etiyolojisini aydınlatma olasılığının literatüre benzer bir yüzdeyle %13,6 olduğunu gösterdik. *MYT1L*, *PXDN*, *TPO* ve *AUTS2* genlerinin bir kez daha otizm spektrum bozuklukları için güçlü bir aday gen olduğunu öneriyoruz. Olguların klinik bulgularını detaylandırarak genomda otizm ile ilişkili olabilecek bazı CNV bölgelerini bildirdik.

Anahtar kelimeler: Mikroarray, otizm spektrum bozuklukları, otizm genleri ve CNV bölgeleri

Address for Correspondence: A. Ayaz, Istanbul Medipol University Faculty of Medicine, Department of Medical Genetics, Istanbul, Turkey

E-mail: aayaz@medipol.edu.tr **ORCID ID:** orcid.org/0000-0001-6930-7148

Received: 05 April 2022

Accepted: 31 May 2022

Online First: 07 June 2022

Cite as: Ayaz A, Gezdirici A, Yilmaz Gulec E, Ozalp O, Koseoglu AH, Dogru Z, Yalcintepe S. Diagnostic Value of Microarray Method in Autism Spectrum Disorder, Intellectual Disability, and Multiple Congenital Anomalies and Some Candidate Genes for Autism: Experience of Two Centers. Medeni Med J 2022;37:180-193

INTRODUCTION

Rare diseases, which affect 6% to 8% of the European Union population and 10% of the US population, are a major health issue worldwide¹. Each country allocates a significant portion of its health expenditures to the diagnosis and treatment of rare diseases. For effective medical management and genetic counseling, definitive etiological diagnosis is crucial in rare diseases. It has been reported that approximately 80% of rare diseases have genetic variations in the etiology, and these diseases are often chronic and life-threatening¹. However, for this group, who were mostly evaluated by many health specialists, the diagnostic rates are not at the desired level. There are several different reasons for this situation. Some these reasons include lack of information about the diseases, challenges in the availability of genetic tests, and high-priced tests. For two decades, through advances in genetic techniques, diagnostic rates in rare diseases have significantly increased. Microarray-based copy number variation (CNV) analysis and next-generation sequencing techniques, in particular, have provided significant contributions to diagnostic rates. Other factors that increase this rate include the application of genetic tests in laboratories of genetic diagnosis centers in many parts of the world, as well as the decrease in test prices.

Microarray is one of the important diagnostic tools that we frequently use in molecular genetics for intellectual disability (ID), developmental delay (DD), autism spectrum disorder (ASD), and multiple congenital anomalies (MCAs), which are common findings of rare diseases. The International Standards for Cytogenomic Arrays (ISCA) have recommended comparative genomic hybridization and single nucleotide polymorphism analysis as first-line diagnostic tests in patients with these conditions². The discovery of 10%-15% of diagnostic yield using microarray analysis in these populations has been supported in the literature³⁻⁵. Many criteria are considered to classify CNVs. Many CNVs are classified as of uncertain clinical significance⁶⁻¹⁰, despite the fact that many databases have been evaluated, such as DECIPHER, ISCA, ClinVar, Online Mendelian Inheritance in Man (OMIM), and Database of Genomic Variants. This problem can be overcome by bringing more microarray data into the literature and clinical databases, as well as by standardizing existing databases. As a result, it is possible to understand the real diagnosis rate of microarray testing in related diseases. For this purpose, we analyzed the microarray results and clinical findings of cases with mental retardation and MCAs, especially ASD, who applied to two different genetic diagnosis centers in Turkey.

MATERIALS and METHODS

Between January 2016 and December 2017, microarray analysis records from two genetic diagnosis centers in Turkey, Kanuni Sultan Suleyman and Adana Numune Training and Research Hospital, were compiled. The files of the patients who had any microarray analysis findings were examined. In addition, parental kinship and, if available, microarray results were compiled. This study was retrospectively designed, and all patient files between January 2016 and December 2017 were examined. Written informed consent for the study was obtained from all patients or their parents. The study was approved by University of Health Sciences Turkey, Kanuni Sultan Suleyman Training and Research Hospital Clinical Research Ethics Committee (decision no: 04, date: 28.09.2018). Every patient underwent a detailed evaluation by a medical geneticist, which included prenatal and birth history, pedigree, family history, and detailed clinical and dysmorphology examinations.

Statistical Analysis

According to the manufacturer's instructions, genomic DNA was extracted from peripheral blood samples kept in EDTA tube. Affymetrix CytoScan Optima 315K arrays (Affymetrix, Santa Clara, CA, USA) were used in the microarray study of all patients. The data obtained were evaluated with the Chromosome Analysis Suite for the CHAS 3.1 program and reference GRCh 37/hg19. CNVs were classified as benign, likely benign, variants of uncertain significance (VUS), likely pathogenic, and pathogenic according to American College of Medical Genetics (ACMG) guidelines¹¹. In the study, descriptive biostatistical analysis was used.

RESULTS

CNV with reporting criteria was detected in 109 (24.5%) of 445 patients (229 men and 216 women). The mean age of the patients was 5.1 yr. Some patients had more than one CNV finding, a total of 163, of which 75 (46%) were gains, and 88 (54%) were losses. According to the ACMG criteria¹¹, 69 (42%) of them were considered pathogenic and 8 (5%) likely pathogenic, while 26 (16%) of them were benign, and 45 (27%) were considered likely benign. Fifteen (9%) CNVs were also classified as VUS (Figure 1). Pathogenic or likely pathogenic CNV was observed in 61 (13.6%) of 445 patients (Table 1).

22q11.21 region was the most common pathogenic CNV region in our report. 22q11 deletion and duplication were observed in four and two patients, respectively. In addition, deletion and duplication in this region were detected in a patient (P71) together. 15q11.2 region was

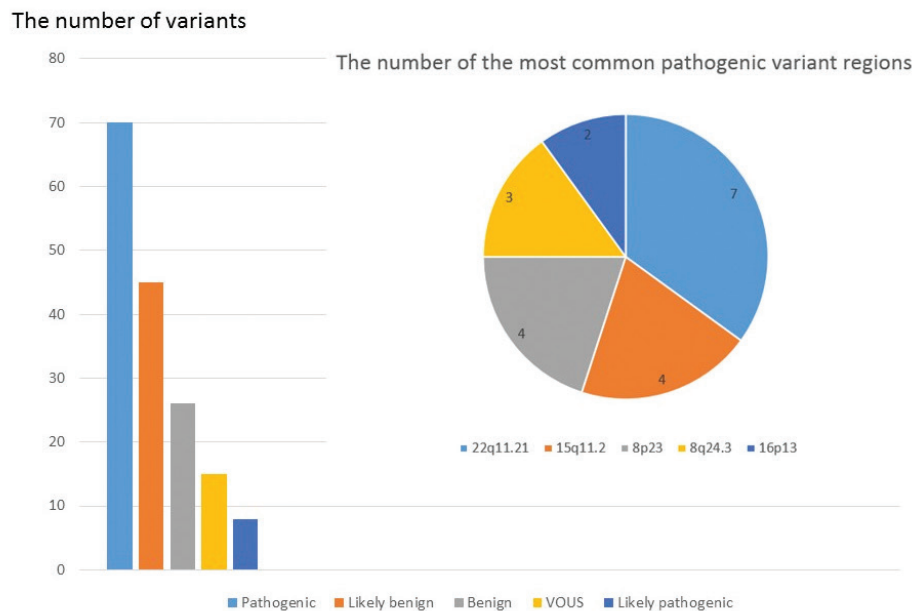


Figure 1. Number of variants and most common pathogenic variants according to American College of Medical Genetics classification criteria.

the second most common pathogenic CNV region. Three patients had a deletion of the region, whereas one patient had duplication. One of the other pathogenic variants was 8q24.3 duplication detected in three patients. Other frequent pathogenic variant regions observed in our two genetic diagnosis centers were 8p23, 16p13, 1p36, 1q21.1, 2p25.3, 9q34.3, 4p16, 6p25.3, 22q13.3, and 17q11.2.

CNVs in the Yq11.2 region were the most common benign variant and were observed in seven patients. CNVs in Xp22, Xq28, 10q11.22, and 15q11.2 regions were other common benign variants shown in this study (Table 2).

Fifteen VUS in 15 patients whose size ranged from 400 to 1,200 kb were detected (Table 3). Four of these patients' pathogenic CNVs were also present.

DISCUSSION

In many rare disease groups, arrayCGH method has started to be used as a first-line diagnostic test. The arrayCGH test has a diagnostic value of 10%-15% in this population, and this rate in the literature was observed to be similar in our study (13.6%). The most significant issue in the arrayCGH results of these patient groups today is the difficulty in evaluating the data. Parental studies may contribute to the solution of this problem, but this brings

the additional cost of using arrayCGH. There are many suggestions for evaluating arrayCGH data in these large patient groups more effectively and efficiently, including enriching the data content of relevant clinical databases and increasing healthy population studies. In this article, we aimed to share the arrayCGH results of patients who were referred to two genetic diagnosis centers in Turkey.

Cases Diagnosed with ASD

In five patients with ASDs, pathogenic or likely pathogenic CNVs located on 2p25.3, 7q11.22, 15q11.2q13.1, and 17p11.2 were observed. In addition, 1p36.32, 8q24.3, and 9q34.2 duplications were seen together in P4. Deletions involving chromosome band 2p25.3 are associated with a nonspecific clinical phenotype that includes ID, obesity, and various dysmorphic features¹². Deletion of the 2p25.3 region, including the disease-causing *MYT1L*, *PXDN*, and *TPO* genes, was observed in P76. Our patient had ASDs, ID, and epileptic seizures. When we evaluated the patient at the age of 6, she did not have obesity, but we have no information about her current condition. Major clinical findings as 7q11.22 deletion, mental motor retardation (MMR), ASD, and atypical facial appearance were detected in P109. One of the important genes in this region is *AUTS2*, which has been reported to be linked to autism, ID, and juvenile myoclonic epilepsy^{13,14}.

Table 1. Pathogenic/likely pathogenic variants.									
Patient no	Gender	Age	Consanguinity	Major findings	Chromosomal location	Deletion/duplication	Size Kb	Evaluation of pathogenicity	Inheritance
P4	M	7 yr	NA	Autism spectrum disorders, delayed speech development	1p36.32	Gain	798	LP	<i>De novo</i>
					8q24.3	Gain	1.297	LP	<i>De novo</i>
					9q34.3	Gain	1.145	LP	<i>De novo</i>
P5	M	3 yr	NA	MCA, epilepsy, atypical facial appearance, growth retardation, intellectual disability, atrial septal defect, hypospadias	2q35q37.3	Gain	24.480	P	Unknown
					9p24.3p24.1	Loss	4.850	P	Unknown
P6	M	2 yr	NA	Congenital cardiac anomalies	22q11.21	Loss	2.843	P	Unknown
P7	M	1 yr	NA	Microcephaly, cerebellum hypoplasia, hypotonia, growth retardation, intellectual disability	2q36.3q37.3	Gain	15.162	P	<i>De novo</i>
					10q26.2q26.3	Loss	7.518	P	<i>De novo</i>
P9	F	9 yr	NA	Corpus callosum agenesis, mental retardation, atypical facial appearance, iris abnormality	18q21.31q21.32	Loss	1.755	LP	<i>De novo</i>
P10	F	10 yr	NA	MMR, epilepsy	22q13.31q13.33	Loss	4.964	P	<i>De novo</i>
P12	M	5 yr	NA	MCA/MR, microcephaly, cardiomyopathy, IUGR	9q21.11q22.32	Gain	27.304	P	<i>De novo</i>
P16	F	2 yr	NA	Autism Spectrum Disorders, MMR, atypical facial appearance	17p11.2	Gain	3.511	P	<i>De novo</i>
P18	M	2 yr	No	Growth retardation(prenatal onset), microcephaly, hypotonia, corpus callosum hypoplasia	15q11.2q12	Loss	3.924	P	Unknown
P20	F	3 yr	NA	MCA, Growth retardation	4p16.3p16.1	Loss	6.799	P	<i>De novo</i>
					4p16.1p15.1	Gain	22.306	P	<i>De novo</i>
P23	M	2 yr	No	MMR, atypical facial appearance, microcephaly, myoclonic seizure, pes valgus, flexion contractures	1p36.33p36.31	Loss	5.207	P	<i>De novo</i>
					4p16.3	Gain	3.800	P	<i>De novo</i>
P24	M	2 yr	NA	IUGR, atypical facial appearance, hypotonia, cataract, cryptorchidism, pes equinovarus	4p16.3p15.1	Loss	31.803	P	<i>De novo</i>
P29	F	3 yr	NA	Intellectual disability, growth retardation, microcephaly, severe short stature	19p13.3	Gain	3.153	P	Unknown
P30	M	1 yr	No	Epilepsy, microcephaly, developmental delay	1p34.2	Loss	3.033	P	Unknown
P31	F	8 yr	Yes	MMR, atypical facial appearance, ASD, cleft palate, cataract	6q25.1q27	Loss	15.072	P	<i>De novo</i>
P33	F	9 yr	NA	MMR	16p13.3p13.2	Gain	9.084	P	Unknown
P38	M	17 yr	NA	West syndrome, MR	5q14.3	Loss	4.588	P	<i>De novo</i>
P39	F	2 yr	NA	MMR, premature	2q37.1q37.3	Loss	7.703	P	<i>De novo</i>
P40	M	2 yr	NA	Atypical facial appearance, coarse face, frequent upper respiratory infections, truncus arteriosus	22q11.21	Loss	1.800	P	<i>De novo</i>
P41	M	2 yr	Yes	Autism spectrum disorders (early onset), developmental delay	15q11.2q13.1	Gain	6.058	P	<i>De novo</i>
P43	M	1 yr	NA	MCA/MR	9q34.3	Loss	3.015	P	Unknown
					22q13.31q13.33	Gain	3.859	P	Unknown

Table 1. continued										
Patient no	Gender	Age	Consanguinity	Major findings	Chromosomal location	Deletion/ duplication	Size Kb	Evaluation of pathogenicity	Inheritance	
P48	M	5 yr	NA	Congenital cardiac anomaly, intellectual disability	22q11.21	Loss	2.549	P	<i>De novo</i>	
P50	F	1 yr	No	Mental retardation, unilateral renal agenesis, ASD, periferic pulmoner stenosis, blue sclerae, atypical facial appearance, overlapping fingers	15q24.1q24.2	Loss	2.920	P	<i>De novo</i>	
P51	M	8 yr	No	Atypical autism, epilepsy	16p11.2	Loss	659	P	Unknown	
P53	M	3 yr	No	MMR, epilepsy, microcephaly, dolicocephaly, strabismus, atypical facial appearance, hypermetropia, lissencephaly	17p13.3p13.2	Loss	1.590	P	<i>De novo</i>	
P55	F	12 yr	NA	MR, obesity, hyperthyroidism	22q11.21	Gain	2.888	P	Paternal	
P56	M	9 months	NA	MMR, growth retardation, deafness	5p15.33	Loss	1.557	P	Paternal	
					6p25.3p22.2	Gain	26.687	P	Paternal	
P57	M	5 yr	No	Unilateral diaphragm hernia, tracheal stenosis, immune deficiency, tetralogy of Fallot, cryptorchidism	22q11.21q11.22	Loss	4.034	P	<i>De novo</i>	
P58	M	4 yr	No	MR, aortic coarctation, PDA, VSD, left ventricular hypertrophy	13q33.3q34	Loss	4.824	P	Unknown	
					18q23	Gain	2.965	P	Unknown	
P60	F	2 yr	No	MR, hypotonia	9q22.2q22.32	Loss	5.386	P	Unknown	
P61	F	3 yr	Yes	Atypical facial appearance, intellectual disability, cafe-au lait, feeding difficulties, hypothyroidism, eosinophilia	17q11.2	Loss	1.364	P	<i>De novo</i>	
P62	M	1 yr	No	MMR, growth retardation, infantile seizure, atypical facial appearance	11q25	Loss	916	P	<i>De novo</i>	
					19q13.33q13.43	Gain	9.515	P	<i>De novo</i>	
P65	M	11 yr	No	Learning disability, unilateral deafness, overcrowded teeth, cachectic, and atypical facial appearance	4q28.3q31.21	Loss	4.898	P	<i>De novo</i>	
P66	M	5 yr	Yes	MR, atypical facial appearance, growth retardation, aortic insufficiency (mild)	7q11.23	Loss	1.609	P	<i>De novo</i>	
P69	F	1 yr	No	Congenital hypotonia, atypical facial appearance	15q11.2q13.3	Loss	10.144	P	<i>De novo</i>	
P71	M	1 yr	No	Atypical facial appearance, low birth weight, short stature, hypotonia, fallot tetralogy, bilateral pes equinovarus	22q11.21	Loss	2.888	P	Unknown	
					22q11.21q11.23	Gain	1.847	P	Unknown	
P74	M	4 yr	No	MR, macrosomia, delayed speech development, hyperactivity, cafe-au lait, axillary freckling	17q11.2	Loss	1.285	P	<i>De novo</i>	
P76	F	6 yr	No	Autism spectrum disorders, MR, seizures	2p25.3	Loss	3.327	P	Unknown	
P77	M	16 yr	Yes	Epilepsy, short stature, MR (mildly)	Yp11.2	Gain	945	LP	Unknown	
P78	M	3 yr	No	Cerebellar vermian hypoplasia, atypical facial appearance, ASD, deafness	6p25.3	Loss	1.137	P	Paternal	
P79	M	3 yr	No	Atypical facial appearance, multifocal epileptic abnormalities	1q21.1	Gain	2.100	P	Unknown	

Table 1. continued									
Patient no	Gender	Age	Consanguinity	Major findings	Chromosomal location	Deletion/duplication	Size Kb	Evaluation of pathogenicity	Inheritance
P81	F	7 yr	No	Developmental delay, short stature, corpus callosum hypoplasia	13q21.33q31.1	Loss	11.842	P	Unknown
P82	M	2 yr	No	Intellectual disability, nystagmus, mega cisterna magna, VSD	16p13.12p12.3	Loss	2.139	P	<i>De novo</i>
P84	M	8 yr	Yes	Deafness, atypical facial appearance, cryptorchidism	6q14.3	Gain	2.307	LP	Unknown
P86	F	2 yr	No	Intellectual disability, developmental delay, corpus callosum agenesis, hydrocephaly	8p23.3p23.1	Loss	6.812	P	<i>De novo</i>
					8p23.1p11.21	Gain	29.014	P	<i>De novo</i>
P87	F	12 yr	No	Epilepsy, MMR, microgliosis, asymmetric hippocampus, and frontal lobes	13q14.11q21.2	Loss	18.822	P	<i>De novo</i>
P88	F	2 yr	No	Atypical facial appearance, hydrocephaly, corpus callosum agenesis, colpocephaly	17q21.31	Loss	590	P	<i>De novo</i>
P89	F	5 yr	No	MMR, atypical facial appearance, delayed myelination white matter	18p11.32p11.21	Gain	15.034	P	<i>De novo</i>
P91	F	3 yr	No	IUGR, MMR, microcephaly	7q36.1q36.3	Loss	9.553	P	<i>De novo</i>
P92	F	4 yr	Yes	Motor retardation, overgrowth, difficulty swallowing foods	Xp22.2p11.3	Loss	28.140	P	<i>De novo</i>
					Xp22.32p22.2	Loss	12.029	P	<i>De novo</i>
					Xp22.33	Loss	3.475	P	<i>De novo</i>
P93	F	3 yr	No	Atypical facial appearance, MMR, deafness, microcephaly, delayed myelination white matter	18q22.3q23	Loss	8.252	P	<i>De novo</i>
P94	M	5 yr	No	Atypical facial appearance, VSD, PDA, splenomegaly, vesicoureteral reflux, hallux valgus, renal ectopia	18q11.1q12.3	Gain	19.882	P	<i>De novo</i>
P96	M	2 yr	No	MMR, ASD, atypical facial appearance, cryptorchidism	15q11.2q13.1	Loss	6.265	P	<i>De novo</i>
P98	M	4 yr	Yes	Intellectual disability, microcephaly	7p11.2q11.21	Loss	4.547	LP	<i>De novo</i>
P103	M	7 yr	No	MR (mildly), atypical facial appearance, cryptorchidism, prematurity, pectus excavatum, preauricular pit	22q11.1q11.21	Gain	4.577	P	Unknown
P104	F	8 yr	No	MR (midly), short stature	8p23.3p23.2	Loss	5.149	P	<i>De novo</i>
					8q24.13q24.3	Gain	20.839	P	<i>De novo</i>
P107	F	7 yr	No	MMR, atypical facial appearance	8p23.3	Loss	5.149	P	<i>De novo</i>
					8q24.13	Gain	20.839	P	<i>De novo</i>
P108	M	2 yr	No	MMR, autism spectrum disorder, atypical facial appearance	7q11.22	Loss	495	P	Unknown
P109	F	12 yr	No	Short stature, delayed puberty, cleft palate, bifid uvula, pectus excavatum (mildly)	1q21.1q12.1	Loss	2.016	P	Unknown
P110	F	8 yr	No	Intellectual disability, severe short stature, atypical facial appearance	1q44	Loss	2.952	LP	<i>De novo</i>
					19q13.41q13.43	Gain	7.169	P	<i>De novo</i>

M: Male, F: Female, P: Pathogenic, LP: Likely pathogenic, MR: Mental retardation, MMR: Mental motor retardation, MCA: Multiple congenital anomaly, IUGR: Intrauterin growth retardation, ASD: Atrial septal defect, VSD: Ventricular septal defect, PDA: Patent ductus arteriosus, EMC: Electromyography

Table 2. Benign/likely benign variants.									
Patient no	Gender	Age	Consanguinity	Major findings	Chromosomal location	Deletion/duplication	Size Kb	Evaluation of pathogenicity	Inheritance
P1	F	18 yr	NA	Delayed pubertal development, ovarian agenesis, small uterus, obesity	Xq28	Loss	286	LB	Unknown
P2	M	3 yr	NA	MCA/MR, contracture, hypotonia	3q26.1	Loss	961	LB	Unknown
					1p21.1	Loss	1.526	LB	Unknown
P3	F	1 yr	Yes	Pulmonary atresia/hypoplasia, ventricular septal defect	10q23.31	Gain	593	LB	Paternal
P5	M	3 yr	NA	MCA, epilepsy, atypical facial appearance, growth retardation, intellectual disability, atrial septal defect, hypospadias	4q34.1	Gain	1.045	B	Unknown
P6	M	2 yr	NA	Congenital cardiac anomalies	Yq11.223	Loss	133	B	Unknown
P8	M	14 yr	Yes	Autism spectrum disorders	3p25.2	Loss	243	B	Paternal
P10	F	10 yr	NA	MMR, epilepsy	18p11.31	Gain	1.200	LB	Paternal
P11	M	2 yr	No	Developmental anomaly, MR (mildly), obesity	15q11.2	Loss	534	B	Maternal
P13	M	1 yr	No	IVF pregnancy, MCA, hydronephrosis	7q35	Loss	124	B	<i>De novo</i>
P14	M	4 yr	NA	Growth retardation (prenatal onset), microcephaly, congenital cardiac anomalies, poor eyesight	8q24.3	Gain	241	LB	<i>De novo</i>
					19q13.2q13.31	Gain	498	B	Paternal
P15	M	2 yr	Yes	MMR, atypical facial appearance, subaortic ventricular defect, prematurity, spasticity	9q32	Gain	280	B	Unknown
P17	F	5 yr	NA	Psychomotor retardation, epilepsy	15q26.3	Loss	161	B	<i>De novo</i>
					17p11.2p11.1	Gain	756	LB	<i>De novo</i>
					10q11.22	Gain	1.321	LB	<i>De novo</i>
					13q13.3	Loss	561	LB	<i>De novo</i>
P18	M	2 yr	No	Growth retardation (prenatal onset), microcephaly, hypotonia, corpus callosum hypoplasia	Yq11.223	Loss	133	B	Unknown
P19	M	3 yr	No	Microcephaly, iris coloboma, cataract, strabismus	2q21.1	Loss	215	B	<i>De novo</i>
					2q21.1	Gain	598	B	<i>De novo</i>
					16q23.1	Gain	203	B	Paternal
P20	F	3 yr	NA	MCA, growth retardation	7q36.3	Gain	529	LB	<i>De novo</i>
P21	M	5 yr	Yes	Atypical facial appearance, pes equinovarus, VSD	8p23.3	Gain	288	B	<i>De novo</i>
P22	M	2 yr	NA	Autism spectrum disorders	Yq12	Loss	150	B	Paternal
					Xq28	Loss	150	B	Paternal

Table 2. continued									
Patient no	Gender	Age	Consanguinity	Major findings	Chromosomal location	Deletion/duplication	Size Kb	Evaluation of pathogenicity	Inheritance
P25	M	4 yr	Yes	Autism spectrum disorders, choanal atresia, cleft lip and palate, delayed speech development	16p13.3	Loss	518	LB	Unknown
P27	M	6 yr	Yes	Epilepsy, delayed speech development, atypical facial appearance, abnormal EEG	17q21.31	Loss	372	LB	<i>De novo</i>
					Xp22.31	Gain	1.600	LB	Maternal
P28	M	2 yr	Yes	MCA/MR, hypotonia, hydrocephaly	7q21.12q21.13	Gain	1.765	LB	Paternal
P29	F	3 yr	NA	Growth retardation, microcephaly, severe short stature	17q25.3	Loss	1.099	LB	Unknown
P32	M	14 yr	NA	Autism spectrum disorders, MMR, epilepsy	10q23.31	Gain	522	LB	Unknown
P35	M	6 months	NA	IUGR (prenatal onset), short extremities, polyhydramnios, duodenal atresia, ASD (secundum)	19q13.42	Loss	314	B	<i>De novo</i>
P37	M	17 yr	NA	Atypical facial appearance, learning disability, scoliosis, hypospadias	1q31.3	Loss	345	B	<i>De novo</i>
P45	M	1 yr	No	Atypical facial appearance, cutis laxa, low birth weight, cryptorchidism, deafness, cleft palate, multiple dislocation, congenital hip dislocation, aortic root dilation	3p26.3	Gain	716	LB	<i>De novo</i>
P46	M	3 yr	NA	Autism spectrum disorders	Yq11.23	Loss	1.320	LB	Unknown
P47	M	5 yr	NA	Autism spectrum disorders	3q21.3	Loss	908	LB	Unknown
P48	M	5 yr	NA	Congenital cardiac anomaly, intellectual disability	Yq11.23	Loss	1.831	LB	<i>De novo</i>
P49	M	5 yr	Yes	Atypical facial appearance, learning disability, short stature, short neck, delayed speech development	15q11.2	Loss	506	LB	Paternal
P52	F	1 yr	NA	MCA/MR	17q11.2	Loss	832	LB	Unknown
P54	F	10 yr	No	Micrognathia, ASD, pulmoner atresia, tricuspid valve hypoplasia	17p13.3	Loss	212	LB	Paternal
P58	M	4 yr	No	MR, aortic coarctation, PDA, VSD, left ventricular hypertrophy	3q23	Gain	486	LB	Unknown
P59	F	17 yr	NA	MR, scoliosis	4q21.21q21.22	Loss	691	LB	Unknown
					10q11.22	Gain	2.048	LB	Unknown
P64	F	18 yr	No	MR, seizures, hypothyroidism	10q11.22	Gain	1.959	B	Paternal

Table 2. continued									
Patient no	Gender	Age	Consanguinity	Major findings	Chromosomal location	Deletion/duplication	Size Kb	Evaluation of pathogenicity	Inheritance
P68	M	6 yr	No	Autism spectrum disorders, IVF pregnancy, delayed speech development	Yq11.223q11.23	Gain	4.042	LB	Paternal
P70	M	6 months	No	Unilateral cleft palate, high nasal bridge, skin tag on ear lobule	8q23.3	Gain	861	LB	<i>De novo</i>
					Xp22.31	Gain	1.669	LB	Paternal
P72	M	6 yr	NA	Common developmental disorder	16p13.3	Loss	518	LB	Paternal
P75	F	9 yr	Yes	Facial asymmetry, hemivertebrae, cafe-au lait, low back hairline	1p32.2p32.1	Loss	1.122	LB	Paternal
P77	M	16 yr	Yes	Epilepsy, short stature, MR (mildly)	7q11.23	Loss	525	LB	Unknown
					Yq11.221	Gain	513	LB	Unknown
					Yp11.2	Gain	748	LB	Unknown
P81	F	7 yr	No	Developmental delay, short stature, corpus callosum hypoplasia	1q21.3	Loss	200	LB	Unknown
					15q21.3	Loss	163	LB	Unknown
P83	F	2 yr	Yes	Developmental delay, motor retardation, cerebellar atrophy, irregular teeth	4q28.3	Loss	226	B	Paternal
P87	F	12 yr	No	Epilepsy, MMR, microgliosis, asymmetric hippocampus, and frontal lobes	15q11.2	Gain	518	LB	<i>De novo</i>
P90	M	2 yr	No	MMR, congenital cataract,	Xp22.2	Gain	262	LB	<i>De novo</i>
P91	F	3 yr	No	IUGR, MMR, microcephaly	1q21.2	Loss	522	B	<i>De novo</i>
					Xq28	Gain	789	LB	<i>De novo</i>
					Xq21.1	Gain	535	LB	<i>De novo</i>
P95	M	10 yr	No	Seizures, MR (mildly)	14q21.2	Gain	423	B	<i>De novo</i>
P97	M	14 yr	No	Epilepsy, MR	Xq21.31	Gain	485	LB	<i>De novo</i>
P98	M	4 yr	Yes	Intellectual disability, microcephaly	6q12	Loss	332	B	Paternal
P99	M	2 yr	No	Atypical facial appearance, MMR, inguinal hernia,	4q13.2	Loss	184	B	Paternal
					22q11.23	Loss	125	B	<i>De novo</i>
P100	F	19 yr	Yes	MMR, epilepsy, self-destructive behavior	22q11.22	Gain	433	LB	Unknown
					Xq26.3	Gain	356	LB	Unknown
P101	F	8 yr	Yes	MMR, epilepsy	2q13	Loss	266	LB	Paternal
P102	M	12 yr	Yes	MMR	Yq11.223q11.23	Gain	3.841	LB	Unknown
P105	M	4 yr	No	Delayed speech development, aortic coarctation, VSD, ASD, neuroblastoma, Meckel diverticulum	16q23.3	Gain	415	B	Paternal
P106	M	4 yr	Yes	Perimembranous VSD, motor retardation, facial asymmetry, skin tag	Xq22.2	Gain	190	LB	Unknown

M: Male, F: Female, B: Benign, LB: Likely benign, MR: Mental retardation, MMR: Mental motor retardation, MCA: Multiple congenital anomaly, IUGR: Intrauterin growth retardation, ASD: Atrial septal defect, VSD: Ventricular septal defect, PDA: Patent ductus arteriosus, EEG: Electroencephalography

Table 3. Variants of uncertain clinical significance.

Patient no	Gender	Age	Consanguinity	Major findings	Chromosomal location	Deletion/duplication	Size Kb	Evaluation of pathogenicity	Inheritance
P1	F	18 yr	NA	Delayed pubertal development, ovarian agenesis, small uterus, obesity	Xp22.33	Gain	1.254	VUS	Unknown
P22	M	2 yr	NA	Autism spectrum disorders	16q23.1	Gain	1.222	VUS	<i>De novo</i>
P26	M	3 yr	No	MR, distractibility, obesity, short stature	8q24.3	Loss	394	VUS	<i>De novo</i>
P34	F	1 yr	NA	MCA/MR	5p15.33	Gain	760	VUS	Unknown
P36	F	8 yr	NA	MMR	Xp22.11	Gain	405	VUS	<i>De novo</i>
P42	F	6 yr	NA	MMR, microcephaly, atypical facial appearance, ulnar deviation, hypothyroidism	12p13.31	Gain	595	VUS	<i>De novo</i>
P48	M	5 yr	NA	Congenital cardiac anomaly, intellectual disability	9q24.2	Gain	1.265	VUS	<i>De novo</i>
P58	M	4 yr	No	MR, aortic coarctation, PDA, VSD, left ventricular hypertrophy	3p24.2	Gain	662	VUS	Unknown
P63	F	1 yr	No	Microcephaly, hydrocephaly, ASD, pulmoner stenosis	16p13.11	Gain	990	VUS	Unknown
P67	F	5 yr	No	Autism spectrum disorders	4p16.1	Gain	1.116	VUS	Unknown
P73	F	5 yr	No	Atypical facial appearance, developmental retardation, retarded bone age	4q27q28.1	Loss	1.159	VUS	Unknown
P80	M	2 yr	Yes	Autism spectrum disorders, motor retardation, atypical facial appearance	1p36.33p36.32	Gain	613	VUS	Unknown
P85	F	9 yr	Yes	Epilepsy, intellectual disability, microcephaly, cerebellar atrophy, corpus callosum hypoplasia, multiple contracture, atypical facial appearance	Xq22.1	Gain	631	VUS	Unknown
P87	F	12 yr	No	Epilepsy, MMR, microgliosis, asymmetric hippocampus, and frontal lobes	19p13.3	Gain	505	VUS	<i>De novo</i>
P89	F	5 yr	No	MMR, atypical facial appearance, delayed myelination white matter	2q13	Loss	911	VUS	Paternal

M: Male, F: Female, VUS: Variant of unknown significance, MR: Mental retardation, MMR: Mental motor retardation, MCA: Multiple congenital anomaly, ASD: Atrial septal defect, VSD: Ventricular septal defect, PDA: Patent ductus arterious, EMG: Electromyography

The clinical findings of our patient with a 495 kbp deletion region in AUTS2 are compatible with the literature. The region we detected as duplication in another patient (P41) referred to our department due to

autism, and DD was 15q11.2q13.1. The association between approximately 6 Mb duplication of this region and autism is well known, and this phenotype is registered at OMIM with #608636. The other region, also known as

Potocki-Lupski syndrome (PTLS), which is well known to be associated with autism and identified in OMIM with the #610883 phenotype, is the 17p11.2 duplication region. In a 2-yr-old female patient referred to us due to early-onset autism, MMR and atypical facial appearance and duplication of 3,511 kbp in the 17p11.2 region was shown. Her clinical findings were consistent with PTLS. A 7-yr-old male patient (P4) referred for ASD and delayed speech development had three possible pathogenic CNV sites, 1p36.32, 8q24.3, and 9q34.3 duplications. To our knowledge, duplication of regions 1p36.32 and 9q34.2 has been reported in two individuals with autism at 292900 and 256523, respectively, in DECIPHER, although there is no proven association between duplication of these regions and autism.

In 15 patients, 15 CNV regions that we interpreted as VUS were shown, and three of them had ASD, whether isolated or not. Each of these three patients had duplication of the following regions: 16q23.1, 4p16.1, and 1p36.33p36.32. Duplication of 16q23.1, known as the fragile region, is not associated with autism in the light of current knowledge. In a patient with mental retardation and midface hypoplasia, duplication of 16q22.1 → q23.1 has been reported via karyotype¹⁵. However, although no array was used to detail this region, the duplication we detected as *de novo* in P22, who applied to our department with isolated ASD, covers the area with a high probability. 4p16.1 was the second VUS region we showed as duplication in patients with autism. Although the association between 4p16.1 duplication and some psychiatric conditions, such as schizophrenia, is known, there is no correlation between duplication of this region and autism. It is reported that DRD5, which encodes the D5 subtype dopamine receptor found in the duplication region of our patient, may be among the genes that have an important role in the etiopathogenesis of schizophrenia^{16,17}. However, our 5-yr-old girl patient had no psychiatric disease excluding autism. The third VUS we found as duplication in patient with ASD, motor retardation, and atypical facial appearance was 1p36.33p36.32. In the light of current knowledge, there is no known relationship between duplication of this region and autism in the literature, DECIPHER, and ClinVar.

Other Special Cases

ArrayCGH is a significant diagnostic method for mental disability of unknown etiology, as well as ASDs of unknown etiology. The majority of patients with likely pathogenic or pathogenic CNV had an ID, and the deletion duplication sizes in the regions, excluding six CNV, were larger than 1 Mb. A 24 Mb duplication of 2q35 and a 4.8

Mb deletion of 9p24.3p24.1 were detected in P5, who was referred to our department due to ID, MCAs, and atypical facial appearance and epilepsy findings. Congenital heart defects, dysmorphic facial features, hypotonia, feeding difficulties, microcephaly, and psychomotor development were observed in a patient with trisomy 2q31.2-37.3 and monosomy 9p24.3 reported by Colangelo et al.¹⁸ (2018). When both cases are compared, it is seen that the findings other than epilepsy are common.

We identified 15 Mb duplication of 2q36.3q37.3 and 7.5 Mb deletion of 10q26.2q26.3, which were inherited from his father with a balanced translocation between 10q and 2q, in P7, 1-yr-old male, who had severe hypotonia, microcephaly, and cerebellum hypoplasia. Common findings of this contiguous gene deletion syndrome are short stature, microcephaly, and mental retardation, which are also present in our case¹⁹. Duplication of 2q36.3q37.3 was identified together with 10p15.3 deletion in a case with an ID or DD by Lee et al.²⁰.

P10, a 10-yr-old female patient with MMR and epilepsy, has a 5 Mb deletion of 22q13.31q13.33 region. Deletion of this chromosomal location was known as Phelan-McDermid syndrome (PHMDS), which is caused by SHANK3 mutation. Although clinical findings of our patient, such as MMR and seizures, are also present in cases with PHMDS syndrome, the region we detected does not include this gene. Recently, cases without SHANK3 deletion but clinically compatible with PHMDS have been reported²¹.

P12 with MCAs, mental retardation, microcephaly, intrauterine growth retardation (IUGR), and cardiomyopathy had 9q21.11q22.32 duplication about 27 Mb in size. Microcephaly, mental retardation, MCAs, and facial dysmorphic findings were previously reported in duplication 9q^{22,23}. As far as we know, cardiomyopathy was not reported in cases with duplication of this region before.

In P18, a 2-yr-old male patient who is referred to our department because of microcephaly, prenatal onset growth retardation, hypotonia, and corpus callosum hypoplasia, approximately 4 Mb of deletion was seen in the region of 15q11.2q12, which is also a critical region for Prader-Willi syndrome and Angelman syndrome (AS). We think that his clinical findings are more compatible with AS because of the presence of microcephaly and corpus callosum hypoplasia and the absence of obesity. In addition, he had hypopigmentation of skin and hair, brachycephaly and hyperreflexia seen mostly in those cases with AS.

Loss of 4p16.3p16.1, which is the critical region for Wolf-Hirschhorn syndrome, one of the well-known contiguous gene deletion syndrome, and gain of 4p16.1p15.1 were observed in P20. A 3-yr-old female patient had MMR, ventricular septal defect, low birth weight, and atypical facial appearance (prominent glabella, high forehead, strabismus, and beaked nose). About half of the deletions are isolated, while the other half may be accompanied by trisomy of a different region as a result of balanced translocation^{24,25}. We could not find the chromosome results of our patient's parents, but one of the parents seems likely to have a translocation or inversion due to the presence of 4p16.1p15.1 gain. We found 4p16.3 duplication and 1p36.33p36.31 deletion in P23 who had MMR, atypical facial appearance, microcephaly, myoclonic seizure, pes valgus, and flexion contractures about 3.8 Mb and 5.2 Mb, respectively. Among the most common terminal deletions, monosomy 1p36 is characterized by MCA, mental retardation, typical craniofacial features, and hypotonia^{26,27}. His craniofacial findings, such as brachycephaly, straight eyebrows, thickened helices, and deep-set eyes were compatible with chromosome 1p36 deletion syndrome. To date, no other case has been found in these two chromosomal anomalies are detected together in the literature. In another patient with a large 4p16.3 deletion of approximately 32 Mb, also identified via cytogenetic before, IUGR, atypical facial appearance, hypotonia, cataract, cryptorchidism, and pes equinovarus were present (P24).

Duplication of 19p13.3 is one of the rarely reported microduplication syndromes, characterized by ID, dysmorphic facial appearance, and IUGR. We found about 3.2 Mb duplication in the region of 19p13.3 in P29 who had ID, growth retardation, microcephaly, and severe short stature. Orellana et al.²⁸ reported three affected siblings with IUGR, global growth retardation, and dysmorphic features. The duplication of 4.95 Mb in the 19p13.3 region reported in this family overlaps with the second half of our duplication region. These approximately 1.5 Mb regions include *AP3D1*, *AMH*, *LMNB2*, *TLE6*, and *GNA11* as disease-causing gene. Based on clinical findings, growth retardation, microcephaly, and ID were present both our case and aforementioned three cases.

One-year-old male patient (P30) with epilepsy, microcephaly, and DD had a 3.0 Mb deletion in the 1p34.2 encompassing *SLC2A1* gene. Glucose transporter type 1 deficiency syndrome, caused by mutations in the *SLC2A1* gene, is a neurometabolic disorder typically characterized by acquired microcephaly, progressive encephalopathy, and drug-resistant epilepsy. Sequence analysis detects 81% of the *SLC2A1* mutations, while

gene-targeted deletion/duplication analysis detects 14%²⁹. In this article, *SLC2A1* deletion was demonstrated by the arrayCGH method in a patient with P30.

Common findings observed in 15q24 microdeletion cases are global growth retardation, short stature, skeletal abnormalities, and joint laxity. We detected a 2.9 Mb deletion of the 15q24 region involving *SIN3A*, responsible for Witteveen-Kolk syndrome, in P50. She had motor retardation, unilateral renal agenesis, ASD, peripheral pulmonary stenosis, blue sclerae, atypical facial appearance, and overlapping fingers when she was 1 yr old. Atypical facial findings, such as microretrognathia and high arched palate, and digital abnormalities identified in Witteveen-Kolk syndrome were present in our case. Although peripheral pulmonary stenosis was reported before in 15q24 microdeletion syndrome, renal agenesis and atrial septal defect were not reported before³⁰.

Miller-Dieker lissencephaly syndrome, which is caused by the deletion of the lissencephaly 1 gene and tyrosine 3-monooxygenase/tryptophan 5 monooxygenase activation protein (*YWHAE*), is a severe neurological disease characterized by typical facial features, ID, and epileptic seizures. Positive findings of patient P53, 3-yr-old male, were MMR, epilepsy, microcephaly, dolichocephaly, strabismus, atypical facial appearance, hypermetropia, and lissencephaly. Approximately 1.6 Mb deletion of 17p13.3p13.2 region we showed in the aforementioned patient includes *LIS*, one of the crucial genes for cerebral development, not *YWHAE*. A *de novo* 17p13.3 deletion is observed in approximately 80% of affected individuals. The remaining 20% are inherited from a parent with balanced chromosomal rearrangement. Chromosomal analysis of his parent were normal.

Neurofibromatosis type 1 (*NF1*) associated with monoallelic *NF1* gene mutations is characterized by multiple cafe-au lait spots, freckling in the axillary and inguinal, multiple cutaneous neurofibromas, and lisch nodules in the iris. In P61 referred to our department due to *NF1* prediagnosis, atypical facial appearance, ID, cafe-au lait, feeding difficulties, hypothyroidism, and eosinophilia were present. After his *NF1* sequence analysis had been detected as normal, arrayCGH was planned and 1.4 Mb deletion of 17q11.2 region involving *NF1* gene was found. While no obvious intellectual development problem is observed in most of the affected cases, learning difficulties or behavioral problems is observed in some of the cases^{31,32}. Even if *NF1* sequencing is normal, the possibility of deletion should not be ignored if the patient's findings are compatible with *NF1*. In addition, cases with *NF1* gene deletion are more risky in terms of

findings and stricter follow-up is recommended.

Monoallelic *NAA15* (N-alpha-acetyltransferase 15) gene mutations have been reported with the phenotype "intellectual developmental disorder, autosomal dominant 50, with behavioral abnormalities" in the OMIM database. This phenotype is characterized by varying degrees of ID, ASD, and global DD. Craniofacial dysmorphism, congenital heart anomalies, and epileptic seizures are other findings observed³³. We showed 4.9 Mb deletion of 4q28.3, where the *NAA15* was localized, in P65 who had a learning disability, unilateral deafness, overcrowded teeth, cachectic, and atypical facial appearance. *PCDH18* (protocadherin 18), the other possible candidate gene is located in the deletion region for ID, is expressed in the brain, heart, kidney, lung, and trachea³⁴. The association of other genes in the deletion region with deafness and dental malocclusion has not been previously reported to date.

We detected 15 VUS regions in 15 patients, but four of these (P48, P58, P87, and P89) also had pathogenic variants. In addition, VUS in six patients (P22, P26, P36, P42, P48, and P87) was detected de novo. While 911 kb VUS on 2q13 inherited from her father was showed in one patient (P89), no parental study was performed in eight patients. As a negative aspect of our study, we can show that parental array studies are insufficient, especially in this group. In these disease groups, clinical exome analysis, whole exome analysis, or whole genome analysis can be recommended for cases that cannot be diagnosed by microarray analysis.

CONCLUSIONS

With this paper, we aim to bring the array of results of two genetic diagnosis centers serving in Turkey to literature together with the genotype-phenotype relationship. We mentioned the importance of the array technique in the etiology of unknown autism, ID, and MCAs once again. In the evaluation of the pathogenesis of array results, it is important to obtain more data into the literature, especially together with parental results. In addition, functional studies, protein-protein interaction studies and more literature data are needed to elucidate candidate genes.

Ethics

Ethics Committee Approval: The study was approved by University of Health Sciences Turkey, Kanuni Sultan Suleyman Training and Research Hospital Clinical Research Ethics Committee (decision no: 04, date: 28.09.2018).

Informed Consent: Written informed consent for the study was obtained from all patients or their parents.

Peer-review: Externally and internally peer-reviewed.

Author Contributions

Surgical and Medical Practices: A.A., A.G., E.Y.G., O.O., S.Y., Concept: A.A., E.Y.G., S.Y., Design: A.A., S.Y., Data Collection and/or Processing: A.A., A.G., E.Y.G., O.O., S.Y., Analysis and/or Interpretation: A.A., E.Y.G., O.O., S.Y., Literature Search: A.A., A.G., A.H.K., Z.D., Writing: A.A., E.Y.G., A.H.K., Z.D., S.Y.

Conflict of Interest: The authors have no conflict of interest to declare.

Financial Disclosure: The authors declared that this study has received no financial support.

REFERENCES

1. EURORDIS. Rare Diseases: Understanding this Public Health Priority. Available from: <http://www.eurordis.org/publication/rare-diseases-understanding-public-health-priority> (accessed January 6, 2012).
2. Miller DT, Adam MP, Aradhya S, et al. Consensus statement: chromosomal microarray is a first-tier clinical diagnostic test for individuals with developmental disabilities or congenital anomalies. *Am J Hum Genet.* 2010;86:749-64.
3. Vissers LE, de Vries BB, Osoegawa K, et al. Array-based comparative genomic hybridization for the genomewide detection of submicroscopic chromosomal abnormalities. *Am J Hum Genet.* 2003;73:1261-70.
4. de Vries BB, Pfundt R, Leisink M, et al. Diagnostic genome profiling in mental retardation. *Am J Hum Genet.* 2005;77:606-16.
5. Quintela I, Eirís J, Gómez-Lado C, et al. Copy number variation analysis of patients with intellectual disability from North-West Spain. *Gene.* 2017;626:189-99.
6. Firth HV, Richards SM, Bevan AP, et al. DECIPHER: Database of Chromosomal Imbalance and Phenotype in Humans using Ensembl Resources. *Am J Hum Genet.* 2009;84:524-33.
7. Riggs ER, Jackson L, Miller DT, Van Vooren S. Phenotypic information in genomic variant databases enhances clinical care and research: the International Standards for Cytogenomic Arrays Consortium experience. *Hum Mutat.* 2012;33:787-96.
8. Landrum M, Lee J, Riley G, et al. ClinVar. In: The NCBI Handbook [Internet]. 2nd edition. Bethesda (MD): National Center for Biotechnology Information (US); 2013.
9. Online Mendelian Inheritance in Man, OMIM®. McKusick-Nathans Institute of Genetic Medicine, Johns Hopkins University (Baltimore, MD), {date}. World Wide Web URL: <https://omim.org/>.
10. MacDonald JR, Ziman R, Yuen RK, Feuk L, Scherer SW. The database of genomic variants: a curated collection of structural variation in the human genome. *Nucleic Acids Res.* 2014;42:D986-92.
11. Riggs ER, Andersen EF, Cherry AM, et al. Technical standards for the interpretation and reporting of constitutional copy-number

- variants: a joint consensus recommendation of the American College of Medical Genetics and Genomics (ACMG) and the Clinical Genome Resource (ClinGen). *Genet Med.* 2020;22:245-57.
12. Stevens SJ, van Ravenswaaij-Arts CM, Janssen JW, et al. MYT1L is a candidate gene for intellectual disability in patients with 2p25.3 (2pter) deletions. *Am J Med Genet A.* 2011;155A:2739-45.
 13. de la Barra F, Skoknic V, Alliende A, Raimann E, Cortés F, Lacassie Y. Gemelas con autismo y retardo mental asociado a translocación cromosómica balanceada (7;20) [Twins with autism and mental retardation associated with balanced (7;20) chromosomal translocation]. *Rev Chil Pediatr.* 1986;57:549-54.
 14. Mefford HC, Muhle H, Ostertag P, et al. Genome-wide copy number variation in epilepsy: novel susceptibility loci in idiopathic generalized and focal epilepsies. *PLoS Genet.* 2010;6:e1000962.
 15. Tokutomi T, Wada T, Nakagawa E, Saitoh S, Sasaki M. A de novo direct duplication of 16q22.1→q23.1 in a boy with midface hypoplasia and mental retardation. *Am J Med Genet A.* 2009;149A:2560-3.
 16. van Os J, Kapur S. Schizophrenia. *Lancet.* 2009;374:635-45.
 17. Van Den Bossche MJ, Strazisar M, Cammaerts S, et al. Identification of rare copy number variants in high burden schizophrenia families. *Am J Med Genet B Neuropsychiatr Genet.* 2013;162B:273-82.
 18. Colangelo M, Alfonsi M, Palka C, et al. Case report of newborn with de novo partial trisomy 2q31.2-37.3 and monosomy 9p24.3. *J Genet.* 2018;97:311-7.
 19. Lewandowski RC Jr, Kukulich MK, Sears JW, Mankinen CB. Partial deletion 10q. *Hum Genet.* 1978;42:339-43.
 20. Lee JS, Hwang H, Kim SY, et al. Chromosomal Microarray With Clinical Diagnostic Utility in Children With Developmental Delay or Intellectual Disability. *Ann Lab Med.* 2018;38:473-80.
 21. Li S, Xi KW, Liu T, et al. Fraternal twins with Phelan-McDermid syndrome not involving the SHANK3 gene: case report and literature review. *BMC Med Genomics.* 2020;13:146.
 22. Stalker HJ, Aymé S, Delneste D, Scarpelli H, Vekemans M, Der Kaloustian VM. Duplication of 9q12-q33: a case report and implications for the dup(9q) syndrome. *Am J Med Genet.* 1993;45:456-9.
 23. Sutherland GR, Carter RF, Morris LL. Partial and complete trisomy 9: delineation of a trisomy 9 syndrome. *Hum Genet.* 1976;32:133-40.
 24. South ST, Bleyl SB, Carey JC. Two unique patients with novel microdeletions in 4p16.3 that exclude the WHS critical regions: implications for critical region designation. *Am J Med Genet A.* 2007;143A:2137-42.
 25. Ou Z, Stankiewicz P, Xia Z, et al. Observation and prediction of recurrent human translocations mediated by NAHR between nonhomologous chromosomes. *Genome Res.* 2011;21:33-46.
 26. Shaffer LG, Lupski JR. Molecular mechanisms for constitutional chromosomal rearrangements in humans. *Annu Rev Genet.* 2000;34:297-329.
 27. Heilstedt HA, Ballif BC, Howard LA, Kashork CD, Shaffer LG. Population data suggest that deletions of 1p36 are a relatively common chromosome abnormality. *Clin Genet.* 2003;64:310-6.
 28. Orellana C, Roselló M, Monfort S, Mayo S, Oltra S, Martínez F. Pure duplication of 19p13.3 in three members of a family with intellectual disability and literature review. Definition of a new microduplication syndrome. *Am J Med Genet A.* 2015;167:1614-20.
 29. Yang H, Wang D, Engelstad K, et al. Glut1 deficiency syndrome and erythrocyte glucose uptake assay. *Ann Neurol.* 2011;70:996-1005.
 30. Mefford HC, Rosenfeld JA, Shur N, et al. Further clinical and molecular delineation of the 15q24 microdeletion syndrome. *J Med Genet.* 2012;49:110-8.
 31. Pride NA, North KN. The cognitive profile of NF1 children: therapeutic implications. In: Upadhyaya M, Cooper DN, eds. *Neurofibromatosis Type 1.* Berlin, Germany: Springer-Verlag; 2012. p. 55-69.
 32. Lehtonen A, Howie E, Trump D, Huson SM. Behaviour in children with neurofibromatosis type 1: cognition, executive function, attention, emotion, and social competence. *Dev Med Child Neurol.* 2013;55:111-25.
 33. Cheng H, Gottlieb L, Marchi E, et al. Phenotypic and biochemical analysis of an international cohort of individuals with variants in NAA10 and NAA15. *Hum Mol Genet.* 2019;28:2900-19.
 34. Wolverson T, Lalande M. Identification and characterization of three members of a novel subclass of protocadherins. *Genomics.* 2001;76:66-72.