

Hepatoblastoma metastatic to brain mimicking intracranial hemorrhage: Case report and literature review

Amans, Matthew R., MD, MSc, and C. Douglas Phillips, MD, FACR

Many pediatric malignancies have a propensity for CNS metastases. Metastases have been reported to present as intracranial hemorrhages, occasionally without a discernible underlying mass. Lack of contrast enhancement should not be exclusionary criteria for intracranial metastases in these patients. Our case is a metastatic lesion presenting as an intracranial hemorrhage without an identifiable solid component on imaging in a patient with hepatoblastoma. Radiologists should consider metastases in cases of intracranial hemorrhage in a child.

Case report

A 4-year-old girl with known primary hepatoblastoma presented to the emergency department after the acute onset of a severe headache. The initial imaging examination ordered through the emergency department was a head MRI (Fig. 1), which demonstrated multiple hemorrhagic lesions, the majority with essentially no contrast enhancement. The largest lesion in the posterior left parietal lobe had findings consistent with acute and subacute hemorrhage, surrounding vasogenic edema, and notable lack of enhancement on postcontrast T1WI. While suspicious for metastases in a patient with a known high-grade hepatic malignancy, the imaging appearance was thought atypical without a discernible enhancing underlying mass. The appearance raised concern for a primary vascular mass with recent hemorrhage, such as cavernous malforma-

tion. Edema surrounding a cavernous malformation might have indicated recent hemorrhage.

After palliative resection, pathology confirmed the diagnosis of metastatic hepatoblastoma (Fig. 2). The sheetlike appearance of tumor cells demonstrated on pathology (Fig. 2) would seem atypical, given the paucity of enhancement on MRI.

Discussion

Pediatric solid malignancies may result in CNS metastases. Unlike typical metastases of adult tumors, CNS metastases in these cases may be atypical in imaging appearance. Metastases from many solid neoplasms have been reported to present as intracranial hemorrhage, occasionally without a discernible associated mass, or contrast enhancement. Lack of contrast enhancement should not be exclusionary criteria for intracranial metastases in these patients. Our case was a metastatic lesion presenting as significant intracranial hemorrhage in a patient with hepatoblastoma. Historical elements may be lacking on occasion, and the radiologist should be cautious of atypical hemorrhage in a child, which could mimic a primary vascular lesion such as cavernous malformation, or bland hemorrhage.

Hepatoblastoma is the most common primary hepatic fetal malignant neoplasm (1). CNS metastases are not uncommon. This patient presented with headache and the known history of hepatoblastoma, and the MRI demonstrated multiple intracranial lesions with imaging appearances suggestive of hemorrhage of varying age. Because hepatoblastoma is a highly cellular tumor, the paucity of

Citation: Hepatoblastoma metastatic to brain mimicking intracranial hemorrhage: Case report and literature review. *Radiology Case Reports*. (Online) 2012;7:611.

Copyright: © 2012 The Authors. This is an open-access article distributed under the terms of the Creative Commons Attribution-NonCommercial-NoDerivs 2.5 License, which permits reproduction and distribution, provided the original work is properly cited. Commercial use and derivative works are not permitted.

Dr. Amans is in the Department of Radiology and Biomedical Imaging, Neuroradiology section, at UCSF, San Francisco CA. Dr. Phillips is in the Department of Radiology at the Weill Medical College of Cornell University, Ithaca NY. Contact Dr. Amans at matthew.amans@ucsf.edu.

Competing Interests: The authors have declared that no competing interests exist.

DOI: 10.2484/rcr.v7i2.611

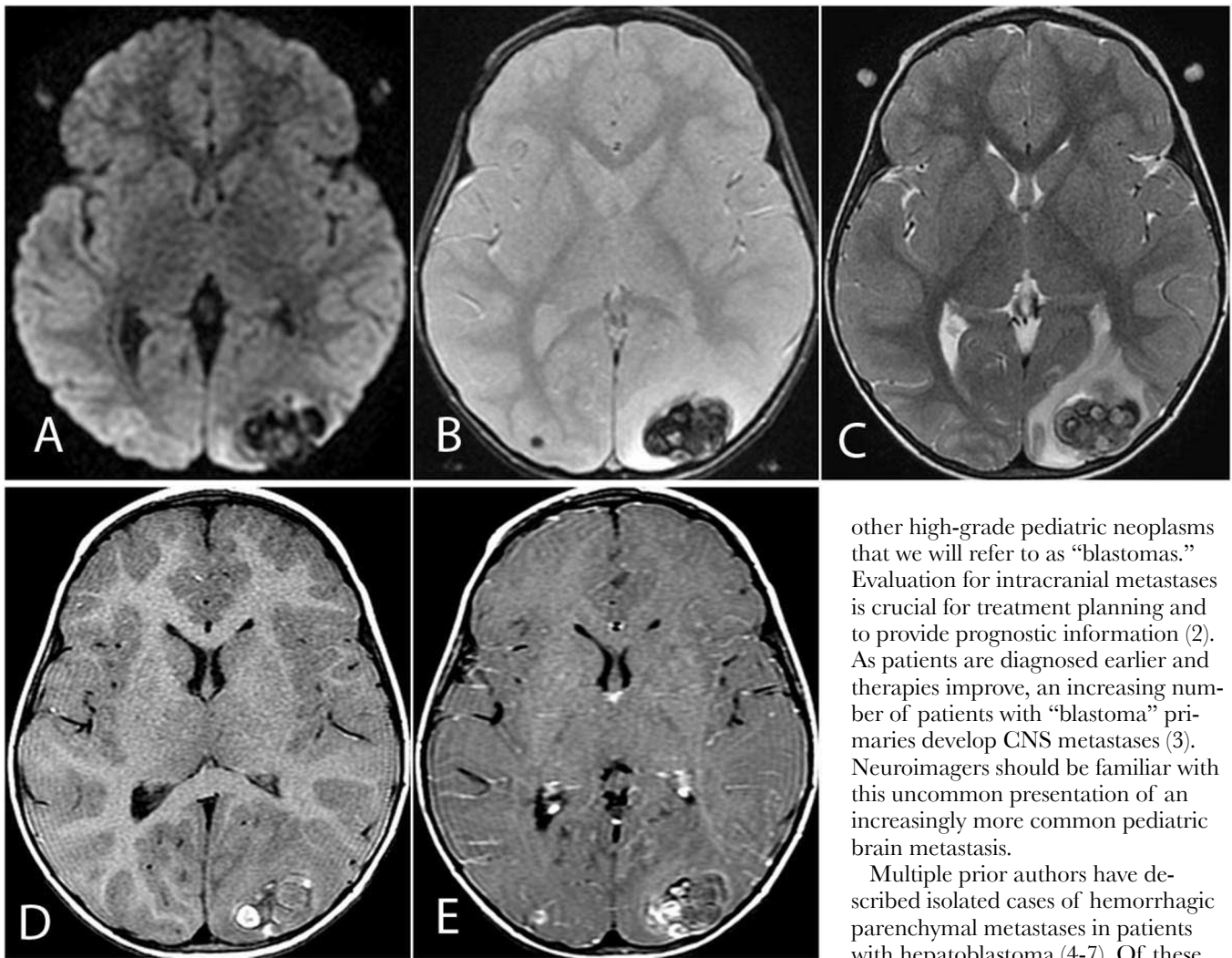


Figure 1. 4-year-old girl with hepatoblastoma. Initial MRI performed from the emergency department (A-E) demonstrating multiple lesions containing acute and subacute hemorrhage and minimal, if any, contrast enhancement. DWI (A) demonstrates no reduced diffusion associated with the lesion to suggest hemorrhagic infarct. MPGR (B) demonstrates bosselated hemorrhage within the dominant lesion in the left occipital lobe. Of note, a second hemorrhagic lesion is also present in the right occipital lobe. Axial T2WI (C) demonstrates hemorrhage of varying degrees of T2 intensity, consistent with hemorrhage of different chronicity. Surrounding vasogenic edema in the white matter may be indicative of acute hemorrhage, or edema secondary to an underlying mass. Axial T1WI (D) and after contrast (E) demonstrate minimal if any enhancement and intrinsic T1 shortening consistent with hemorrhage.

contrast enhancement would seem atypical. However, review of the literature shows this atypical imaging appearance of CNS metastases to be a not-uncommon characteristic of intracranial hepatoblastoma, neuroblastoma, and

other high-grade pediatric neoplasms that we will refer to as “blastomas.” Evaluation for intracranial metastases is crucial for treatment planning and to provide prognostic information (2). As patients are diagnosed earlier and therapies improve, an increasing number of patients with “blastoma” primaries develop CNS metastases (3). Neuroimagers should be familiar with this uncommon presentation of an increasingly more common pediatric brain metastasis.

Multiple prior authors have described isolated cases of hemorrhagic parenchymal metastases in patients with hepatoblastoma (4-7). Of these, both Kabudi and colleagues and

Roberson et al describe these metastatic lesions to be densely enhancing on MRI, in keeping with the extreme cellularity of these tumors. Porto and colleagues (6) describe an imaging pattern of recurring foci of hemorrhage with little to no associated enhancement, similar to a cavernous malformation.

CNS metastases from neuroblastoma, the most common “blastomas,” most often present as marrow replacement of the vertebral bodies or skull, enhancing masses of the dura, or solid enhancing intraparenchymal masses (7-8). Rarely, metastases present as multiple foci of hemorrhage (8).

We present a case of hepatoblastoma metastases to the brain demonstrating imaging characteristics of hemorrhage of varying age without a significant enhancing component. Although uncommon, this is a documented presentation of CNS metastatic “blastomas.” Recognition of intracranial hemorrhage in patients with a known “blastoma” as a possible metastasis may greatly impact prognosis and therapeutic decisions.

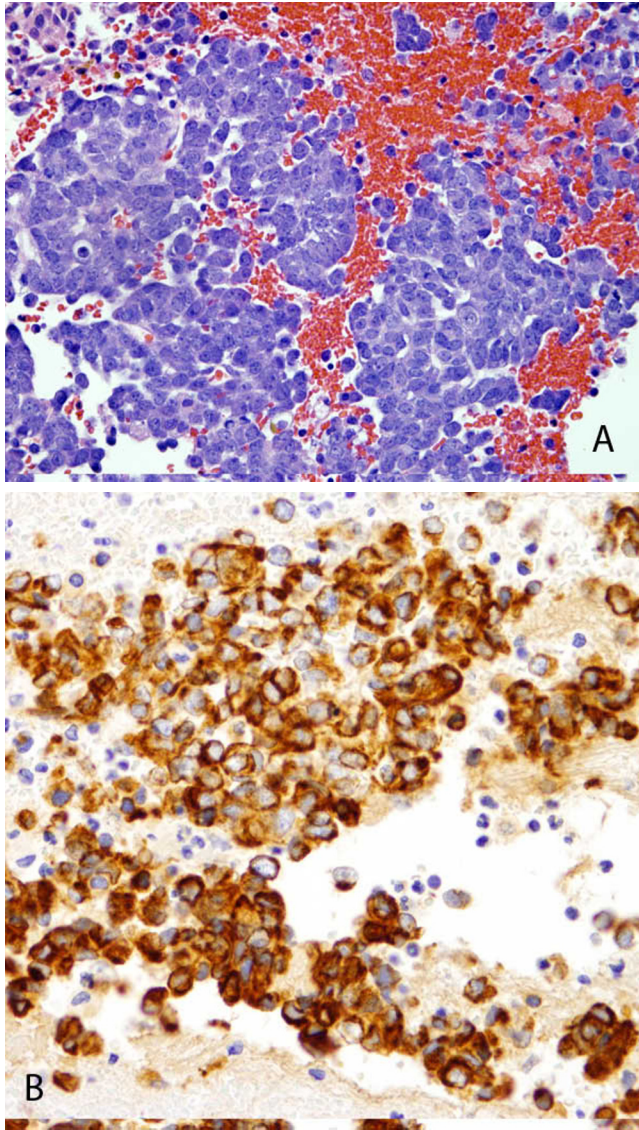


Figure 2. 4-year-old girl with hepatoblastoma. A: 400 x H&E staining demonstrates extensive cellularity of the resected left parietal mass with immunostaining for cytokeratin AE1/AE3 (a pan-cytokeratin stain that includes both low and high molecular weight CKs) as well as a stain for alpha-fetoprotein (B).

References

1. Woodward PJ, Sohaey R, Kennedy A, Koeller KK. From the archives of the AFIP: A comprehensive review of fetal tumors with pathologic correlation. *Radiographics* 2005; 25:215-42. [\[PubMed\]](#)
2. Weinstein JL, Katzenstein HM, Cohn SL. Advances in the diagnosis and treatment of neuroblastoma. *The Oncologist* 2003; 8: 278-92. [\[PubMed\]](#)
3. Kramer K, Kushner B, Heller G, Cheung NKV. Neuroblastoma metastatic to the central nervous system, the Memorial Sloan-Kettering Cancer Center experience and a literature review. *Cancer* 2001; 91 (8): 1510-9. [\[PubMed\]](#)
4. Begemann M, Trippett TM, Lis E, Antunes NL. Brain metastases in hepatoblastoma. *Pediatr Neurol* 2004; 30: 295-7. [\[PubMed\]](#)
5. Robertson PL, Murasko KM, Axtell RA. Hepatoblastoma metastatic to brain: Prolonged survival after multiple surgical resections of a solitary brain lesion. *J Pediatr Hematol Oncol* 1997; 19 (2): 168-71. [\[PubMed\]](#)
6. Porto L, Jarisch A, Zanella F, et al. The role of magnetic resonance imaging in children with hematogenous brain metastases from primary solid tumors. *Pediatr Hematol Oncol* 2010; 27: 103-11. [\[PubMed\]](#)
7. Kebudi R, Ayan I, Grgn O, et al. Brain metastasis in pediatric extracranial solid tumors: survey and literature review. *J Neurooncol* 2005; 71: 43-8. [\[PubMed\]](#)
8. Sidi-Fragandrea V, Hatzipantelis E, Panagopoulou P, Fragandrea I. Isolated central nervous system recurrence in a child with stage IV neuroblastoma. *Pediatr Hematol Oncol* 2010; 27: 387-92. [\[PubMed\]](#)