



## Case Report

## The details of an unusual “ghost” after transvenous lead extraction: Three-dimensional computed tomography analysis

Kunihiko Kiuchi, MD, FHRS<sup>a,\*</sup>, Koji Fukuzawa, MD<sup>a</sup>, Shumpei Mori, MD<sup>b</sup>, Tatsuya Nishii, MD<sup>c</sup>, Kensuke Matsumoto, MD<sup>b</sup>, Hirotochi Ichibori, MD<sup>b</sup>, Takashi Yamada, MD<sup>d</sup>

<sup>a</sup> Section of Arrhythmia, Division of Cardiovascular Medicine, Department of Internal Medicine, Kobe University Graduate School of Medicine, 7-5-2 Kusunoki-chou chuou-ku, Kobe, Hyogo, Japan

<sup>b</sup> Division of Cardiovascular Medicine, Department of Internal Medicine, Kobe University Graduate School of Medicine, 7-5-2 Kusunoki-chou chuou-ku, Kobe, Hyogo, Japan

<sup>c</sup> Department of Radiology, Kobe University Graduate School of Medicine, 7-5-2 Kusunoki-chou chuou-ku, Kobe, Hyogo, Japan

<sup>d</sup> TakaishiFujii Cardio-Vascular Hospital, 2-15-18 Ayazono, Takaishi, Osaka, Japan

## ARTICLE INFO

## Article history:

Received 31 May 2017

Received in revised form

11 July 2017

Accepted 20 July 2017

Available online 6 September 2017

## Keywords:

Transvenous lead extraction

Cardiac rhythm device

Device infection

Computed tomography

## ABSTRACT

Transvenous lead extraction (TLE) is performed to prevent deaths in patients with device infections. Intracardiac masses detected by echocardiography, i.e., “ghosts,” are reported in 8% of patients after a TLE in retrospective studies and in 14% in prospective studies. We herein describe a case with unusual ghosts after a TLE. Three-dimensional computed tomography (3DCT) is useful for revealing all the details of unusual ghosts. In this case, the residual silicone insulation and “cast,” including the fibrous sheath and severe calcifications could be visualized and differentiated by 3DCT.

© 2017 Japanese Heart Rhythm Society. Published by Elsevier B.V. This is an open access article under the CC BY-NC-ND license (<http://creativecommons.org/licenses/by-nc-nd/4.0/>).

### 1. Case presentation

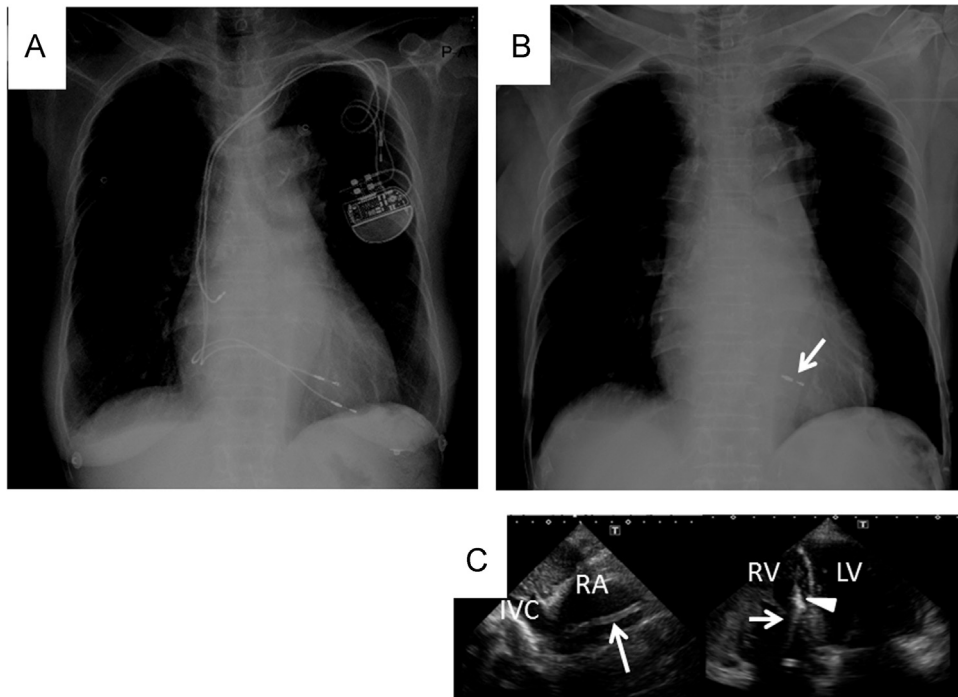
An 83-year-old woman was referred to our center due to a fever, bloodstream bacterial infection, and fistula related to an implanted device. The patient underwent a double-chamber pacemaker implantation 8 years prior for sick sinus syndrome, with additional right ventricular lead implantation for a lead malfunction 5 years prior (Fig. 1A). Transvenous lead extraction (TLE) was indicated due to a serious device infection. An atrial lead was easily extracted from the entry site. However, both ventricular leads were fractured due to adhesion to the subclavian angle and superior vena cava. Except for the distal tip, the two RV leads could be extracted with a Needle's Eye Snare (Cook Medical, Bloomington, IN, USA) from the inferior vena cava (IVC) (Fig. 1B). Although the patient was asymptomatic, transthoracic echocardiography (TTE) 7 days after the TLE detected ghosts, which were located in both the RV and RA (Fig. 1C). To visualize and assess the ghosts, computed tomography (CT) (SOMATOM Force; Siemens Healthcare, Forchheim, Germany) was performed. The data underwent three-dimensional CT (3DCT) reconstruction, which clearly demonstrated the full picture of the ghost. Three

structures were identified: one extended from the RV and RA toward the IVC, and the others extended from the RA toward the superior vena cava (SVC) (Fig. 2A). The ghost extending from the RV and RA toward the IVC could be grasped with an EN Snare device (Merit Medical, Utah, USA) from the IVC and was completely removed. However, a tubular object with high CT value persisted on 3DCT (Fig. 2B). The ghost was actually the residual silicone insulation of the RV lead, which had a length of approximately 21 cm and completely corresponded to the estimated length on the 3DCT (Fig. 2C). Therefore, this residual tubular object was considered to be a “cast” including fibrous and calcified tissue (Fig. 2B, white arrow). The other ghosts extending from the RA toward the SVC could not be grasped.

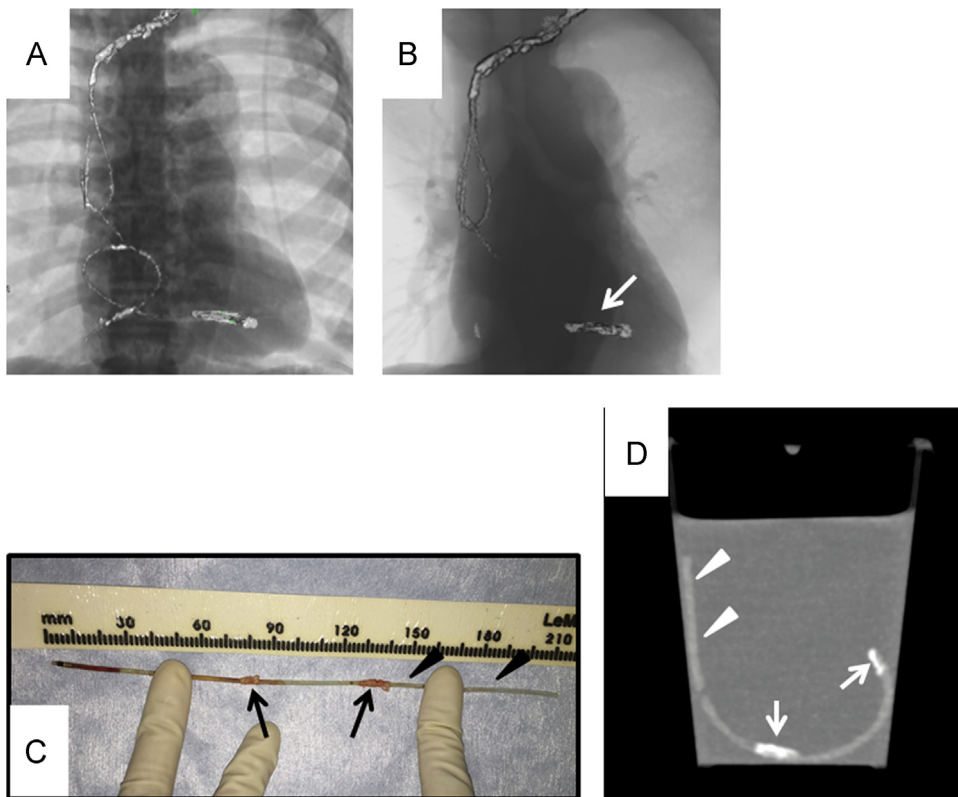
To assess whether 3DCT could visualize and differentiate silicone insulation from the cast, the image of the removed silicone sheath was acquired by CT with the cast in water (Fig. 2D). Segments with a relatively high CT value and an extremely high value corresponded to silicone insulation and cast, respectively (Fig. 2C and D). The CT value of the silicone insulation and cast in the water measured 130 and 370 HU, respectively. The tubular segment was diagnosed as a cast of the RV lead, and the severe RV trabecular adhesion consisted of fibrous tissue with severe calcifications. The patient was discharged after antibiotic treatment for 6 weeks. However, 2 weeks after discharge, she was again referred

\* Corresponding author. Fax: +81 78 382 5859.

E-mail address: [kunihikokiuchi@yahoo.co.jp](mailto:kunihikokiuchi@yahoo.co.jp) (K. Kiuchi).



**Fig. 1.** A: Chest X-ray before transvenous lead extraction showing 1 atrial and 2 right ventricular leads. B: Chest X-ray after transvenous lead extraction showing only the distal tip of the right ventricular lead (white arrow). C: Transthoracic echocardiography showing residual material in both the RA and RV. The extremely high value echoic mass (white arrowhead) was tightly attached to the RV septum, and the relatively high value echoic mass (white arrow) was probably floating in the RV and RA. RA = right atrium, RV = right ventricle, IVC = inferior vena cava.



**Fig. 2.** A: 3DCT after first transvenous lead extraction. B: 3DCT after second transvenous lead extraction. The white arrow indicates a cast of the right ventricular lead. C: The removed silicone insulation and cast. The black arrows and arrowheads indicate the cast and silicone insulation, respectively. The length was 21 cm, indicating that the silicone insulation was completely removed. D: 3DCT showing the removed silicone insulation and cast in water. The distal portion of the removed silicone insulation was cut off for bacterial examination. The CT value of the silicone insulation and cast were 130 and 370 HU, respectively. This indicated that the silicone insulation could be differentiated from the cast by the CT value. The white arrows and arrowheads indicate segments with extremely high and relatively high CT values, which completely correspond to the cast and silicone sheath, respectively. 3DCT = three-dimensional computed tomography, RAO = right anterior oblique, LAO = left anterior oblique, IVC = inferior vena cava, HU = Hounsfield unit.

to our center due to severe general fatigue and a fever. Vegetations, as well as persistence of the previously detected ghosts in the SVC and RA were observed with transesophageal echocardiography (TEE). Therefore, surgery was planned. The 2 residual ghosts were found to consist of silicone insulation and small vegetations.

Intracardiac masses detected by echocardiography, i.e., ghosts, are observed in 8% of patients after a TLE in retrospective studies and in 14% in prospective studies [1,2]. A postmortem study demonstrated that pacemaker leads and implantable cardioverter defibrillator leads may be encapsulated by a fibrous sheath that grows over time [3]. Ghosts are usually considered to represent fibrous sheaths or possibly vegetations [4]. TEE and intracardiac echocardiography (ICE) during TLE can detect the presence of ghosts, but cannot reveal the full picture, which might underestimate their clinical severity in a subgroup of patients with ghosts after TLE. 3DCT could clearly demonstrate the full picture of the unusual ghosts in both the RA and RV. It is noteworthy that 3DCT could diagnose the nature of the ghosts based on a CT value: a relatively high CT value and an extremely high value were considered to represent silicone and cast around the lead, respectively.

Recently, the association between the presence of a ghost and mortality has become evident [1,5]. A possible reason for the high mortality in patients with a ghost was considered due to uncontrolled severe systemic infection, endocarditis, or pulmonary embolism after TLE. Therefore, all the details of any ghost should be assessed by 3DCT and an appropriate decision for further intervention should be made. It is important to determine whether a lead can be completely removed and to perform TEE to detect both usual and unusual ghosts at the end of a procedure.

As a clinical implication, 3DCT is useful for revealing all the details of both unusual and usual ghosts. Residual silicone insulation, fibrous sheaths, and severe calcifications can be visualized and differentiated by 3DCT. This information, combined with the patient's status, can aid in appropriate decision-making for further surgical intervention.

## Disclosures

None.

## Conflict of interest

The Section of Arrhythmia is supported by an endowment from Medtronic JAPAN and St. Jude Medical JAPAN.

## Acknowledgement

The authors greatly thank Mr. John Martin for his linguistic assistance.

## References

- [1] Narducci ML, Di Monaco A, Pelargonio G, et al. Presence of 'ghosts' and mortality after transvenous lead extraction. *Europace* 2017;19:432–40.
- [2] Le Dolley Y, Thuny F, Mancini J, et al. Diagnosis of cardiac device-related infective endocarditis after device removal. *JACC Cardiovasc Imaging* 2010;3:673–81.
- [3] Candinas R, Duru F, Schneider J, et al. Postmortem analysis of encapsulation around long-term ventricular endocardial pacing leads. *Mayo Clin Proc* 1999;74:120–5.
- [4] Le Dolley Y, Thuny F, Bastard E, et al. Pacemaker lead vegetation trapped in patent foramen ovale: a cause of hypoxemia after percutaneous extraction. *Circulation* 2009;119:e223–4.
- [5] Andreas M, Wiedemann D, Kocher A, et al. Materialization of ghosts: severe intracardiac masses after pacemaker lead extraction requiring immediate surgical intervention. *Heart Rhythm* 2013;10:1826.