

Original Article
Cell Therapy & Organ
Transplantation



Kidney Transplantation in Patients with Atypical Hemolytic Uremic Syndrome due to Complement Factor H Deficiency: Impact of Liver Transplantation

Sejin Kim ^{1,*} Eujin Park ^{1,2,*} Sang-il Min ³ Nam-Joon Yi ³ Jongwon Ha,³
Il-Soo Ha ¹ Hae Il Cheong ^{1,2,4} and Hee Gyung Kang ^{1,2}

¹Department of Pediatrics, Seoul National University College of Medicine, Seoul, Korea

²Research Coordination Center for Rare Disease, Seoul National University Hospital, Seoul, Korea

³Department of Surgery, Seoul National University College of Medicine, Seoul, Korea

⁴Kidney Research Institute, Medical Research Center, Seoul National University College of Medicine, Seoul, Korea

 OPEN ACCESS

Received: Aug 3, 2017

Accepted: Oct 1, 2017

Address for Correspondence:

Hee Gyung Kang, MD, PhD

Department of Pediatrics, Seoul National University Children's Hospital, 101 Daehak-ro, Jongno-gu, Seoul 03080, Korea.
E-mail: kanghg@snu.ac.kr

*Sejin Kim and Eujin Park contributed equally to this work.

© 2018 The Korean Academy of Medical Sciences.

This is an Open Access article distributed under the terms of the Creative Commons Attribution Non-Commercial License (<https://creativecommons.org/licenses/by-nc/4.0/>) which permits unrestricted non-commercial use, distribution, and reproduction in any medium, provided the original work is properly cited.


ORCID iDs

Sejin Kim 


<https://orcid.org/0000-0002-8721-0697>

Eujin Park 


<https://orcid.org/0000-0002-4413-468X>

Sang-il Min 

<https://orcid.org/0000-0002-0688-0278>

Nam-Joon Yi 

<https://orcid.org/0000-0002-5467-425X>

Il-Soo Ha 

<https://orcid.org/0000-0001-5428-6209>

ABSTRACT

Background: Atypical hemolytic uremic syndrome (aHUS) is a rare disease that is often associated with genetic defects. Mutations of complement factor H (*CFH*) are the most common genetic defects that cause aHUS and often result in end-stage renal disease. Since *CFH* is mainly produced in the liver, liver transplantation (LT) has been performed in patients with defective *CFH*.

Methods: The clinical courses of four kidney allograft recipients who lost their native kidney functions due to aHUS associated with a *CFH* mutation were reviewed.

Results: Subject A underwent kidney transplantation (KT) twice, aHUS recurred and the allograft kidney failed within a few years. Subject B received a KT and soon experienced a recurrence of aHUS coinciding with infection. Her allograft kidney function has worsened, and she remains on plasma infusion therapy. Subject C underwent LT followed by KT. She is doing well without plasma infusion therapy after combined LT-KT for 3 years. Subject D received KT following LT and is now recurrence-free from aHUS.

Conclusion: In patients with aHUS associated with a *CFH* mutation, KT without LT was complicated with a recurrence of aHUS, which might lead to allograft loss. Conversely, LT was successful in preventing the recurrence of aHUS and thus might be another option for a recurrence-free life for aHUS patients associated with *CFH* mutation.


Keywords: Atypical Hemolytic Uremic Syndrome; Complement Factor H, Kidney Transplantation; Liver Transplantation

INTRODUCTION

Hemolytic uremic syndrome (HUS) is a syndromic disease characterized by thrombocytopenia, microangiopathic hemolytic anemia and acute kidney injury. Typical HUS manifests with bloody diarrhea that is mostly caused by Shiga toxin-producing

Hae Il Cheong 

<https://orcid.org/0000-0001-7556-1265>

Hee Gyung Kang 

<https://orcid.org/0000-0001-8323-5320>

Funding

This study was supported by a grant (HI12C0014) of the Korean Health Technology R & D Project, Ministry of Health and Welfare, Republic of Korea.

Disclosure

The authors have no potential conflicts of interest to disclose.

Author Contributions

Conceptualization: Cheong HI, Kang HG. Data curation: Min SI, Yi NJ, Ha J, Ha IS. Writing - original draft: Kim S, Park E.

enterohemorrhagic *Escherichia coli* infections.¹ HUS is an important cause of advanced acute kidney injury in childhood, but patients generally recover renal functions completely and have a good prognosis without recurrence. HUS without bloody diarrhea (so-called atypical hemolytic uremic syndrome or aHUS) recurs often and eventually results in end-stage renal disease (ESRD) in many cases, which is different from typical HUS. In the majority of aHUS cases, complement activation via the dysregulation of the alternative pathway (AP) is a primary cause.^{2,3} Approximately 60%–70% of the genetic predispositions to aHUS are mutations in essential regulators of AP, such as complement factor H (*CFH*), complement factor I (*CFI*), membrane co-factor protein and others.^{4–6} A *CFH* mutation is the most common cause of aHUS. *CFH* is an essential regulator of AP complement activation, and the loss of function of this protein results in uncontrolled activation of AP, which induces endothelial damage and leads to thrombotic microangiopathy (TMA).

The treatment of aHUS is focused on restoring the regulation of AP to intervene in the destruction of host cells by complement activation. However, plasma therapy is often insufficient to prevent end organ damage in aHUS, and in the past approximately 70% of patients with *CFH* mutations died or developed ESRD within one year of presentation despite extensive plasma therapy.⁷ Therefore, liver transplantation (LT) has been considered as a therapeutic option for patients with defective *CFH* or *CFI*, since these factors are produced mainly in the liver.^{2,8,9} However, LT is a major operation with a considerable mortality rate of 8%–25%. Moreover, LT in patients with aHUS carries a higher risk of failure due to the thrombogenic tendency of the recipients.¹⁰

Eculizumab, which is a monoclonal anti-C5 antibody that blocks C5 cleavage,¹¹ has been recommended as the first-line treatment for aHUS over plasma therapy or LT since its introduction.¹² However, eculizumab is not efficacious for some causes of aHUS and is not always available due to its high price. Additionally, eculizumab therapy should be life-long, indicating that the patients will have a defective complement system for the rest of their lives. Therefore, we investigated which of the two therapies was preferable in patients with aHUS associated with a *CFH* mutation (*CFH*-aHUS).

Due to the rarity of the disease and the diversity of the clinical courses of aHUS, a prospective study comparing eculizumab and LT is not feasible; the collection of experiences with each treatment modality would be needed to obtain clinical information. Here, we present four cases of aHUS associated with *CFH*-aHUS. The post-kidney transplantation (KT) clinical courses were quite different according to the patients' LT statuses.

METHODS

Study design and patient collection

The cases of 4 unrelated Korean children with *CFH*-aHUS who were enrolled at our hospital from 1996 to 2016 were retrospectively evaluated. For this study, we reviewed the clinical and laboratory data and included patients who progressed to ESRD with *CFH*-aHUS and were under the age of 18 years at the time of onset.

Mutational analysis

Genomic DNA was extracted from peripheral blood nucleated cells collected from the patients and their parents. Targeted exome sequencing that covered 46 complement-related

genes was performed at Samsung Genome Institute as part of the aHUS: Korean pediatric series.¹³ The detected mutations were confirmed with traditional Sanger sequencing.

Allograft transplantation

Allograft transplantation was performed with massive pre- and intra-operative plasma infusions to prevent thrombotic events. Induction therapy was conducted with anti-CD20 antibodies, high-dose steroids, tacrolimus, and mycophenolate mofetil. A conventional triple regimen consisting of tacrolimus, mycophenolate mofetil and an oral steroid was given to suppress each patient's immune status after KT, and tacrolimus and/or a corticosteroid was administered after LT. The trough level of tacrolimus was 8–12 ng/mL within the first year of transplantation and then 5–8 ng/mL thereafter.¹⁴

Ethics statement

This study was approved by the Seoul National University Hospital's Institutional Review Board (IRB No. 0812-002-264). Informed consent was obtained from all individual participants included in this study.

RESULTS

Subject A was a 20-year-old woman who was first diagnosed with aHUS at the age of 3 years. At her first presentation, she had a fever, cough and vomiting, followed by gross hematuria. The initial laboratory evaluation demonstrated severe anemia (hemoglobin, 5.1 g/dL), thrombocytopenia (platelet count, 93,000/mm³), and azotemia (creatinine, 1.8 mg/dL). Her serum albumin (3.2 g/dL), complement 3 (C3, 98 mg/dL), and complement 4 (C4, 28 mg/dL) levels were all normal (normal range: C3, 70–150 mg/dL and C4, 10–35 mg/dL). The patient was treated with a plasma infusion, plasmapheresis and hemodialysis for 6 weeks. After treatment, she recovered from acute hemolysis (hemoglobin, 9.1 g/dL and platelet count, 345,000/mm³), but the kidney injury remained (serum blood urea nitrogen [BUN], 33 mg/dL and serum creatinine, 1.4 mg/dL) and the proteinuria persisted (24-hour urine protein, 1.6 g/day). She experienced multiple episodes of aHUS, which were managed each time with plasma infusion therapy. Although she was treated properly, she progressed to ESRD at the age of 5 years and started renal replacement therapy. Three years later, she received a deceased allograft KT. Two years after the KT, her graft function started to deteriorate gradually (**Fig. 1**). A biopsy of the allograft kidney revealed chronic allograft nephropathy (25% global sclerosis) with occasional multilayering of the glomerular basement membrane (GBM), cellular interposition or subendothelial widening of the GBM and moderate to severe tubulitis. Since her laboratory test results were unremarkable for acute hemolysis, intravenous methylprednisolone therapy was performed repeatedly, because this situation was considered an acute rejection episode. However, her renal function did not recover. After seven months, an allograft kidney biopsy was performed again. The global sclerosis had progressed to 43%, and marked endothelial cell proliferation was noted. Because this incident was considered a recurrence of aHUS, aggressive plasma therapy was applied; however, she lost her allograft five years after her first KT. After two years of peritoneal dialysis, she received a second deceased KT; similarly, her allograft kidney function has deteriorated again in two years after the recurrence of aHUS.

Genetic analysis revealed a heterozygous mutation (c.3644G>A [p.Arg1215Gln]) of the *CFH* gene (**Fig. 2**), which was inherited from her father, and another de novo mutation (c.1649G>A

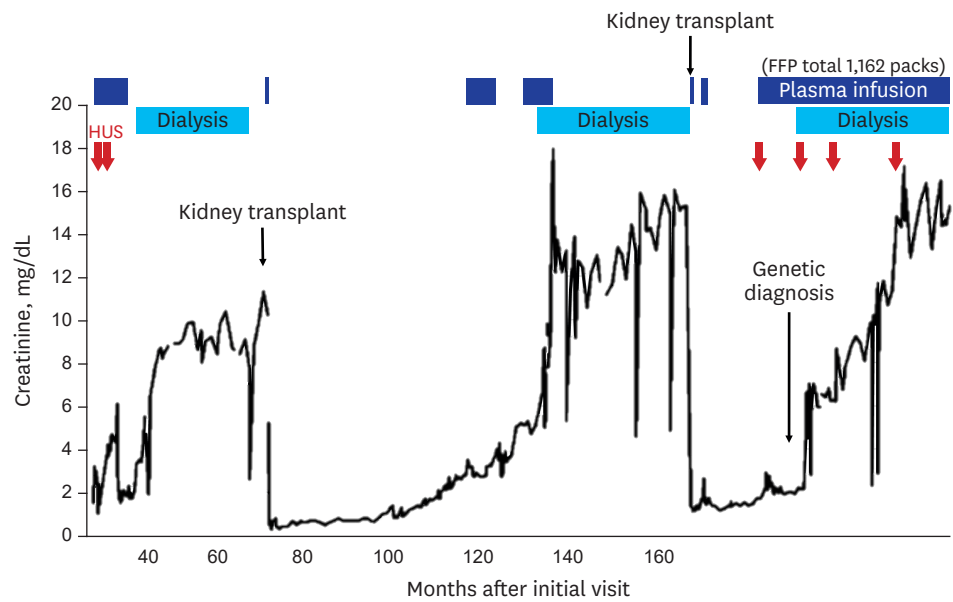


Fig. 1. Timeline of serum creatinine results and treatments for subject A. HUS = hemolytic uremic syndrome, FFP = fresh frozen plasma.

[p.Cys550Tyr] of the *CFI* gene. After the genetic diagnosis, the patient has been managed with regular plasma infusion therapy but is still experiencing a recurrence of aHUS.

Subject B was a 16-year-old girl who was first found to have ESRD at the age of 7 years. Although her medical history was uncertain, she was suspected of having aHUS because she had a history of hematuria, azotemia and decreased serum complement levels. She was transferred to our pediatric nephrology team for management of uncontrolled hypertension. On admission, her laboratory findings were hemoglobin 13.3 g/dL, a platelet count of 279,000/mm³, BUN 54 mg/dL, and creatinine 13.36 mg/dL. Her plasma C3 and C4 levels were 78 and 30 mg/dL, respectively. After a bilateral nephrectomy, her blood pressure stabilized with anti-hypertensive medications (amlodipine and irbesartan).

A genetic diagnosis was made when she was 13 years old, and a heterozygous mutation (c.3593A>T in exon 22 [p.Glu1198Val] of *CFH*) (**Fig. 2**) was found. She received a deceased

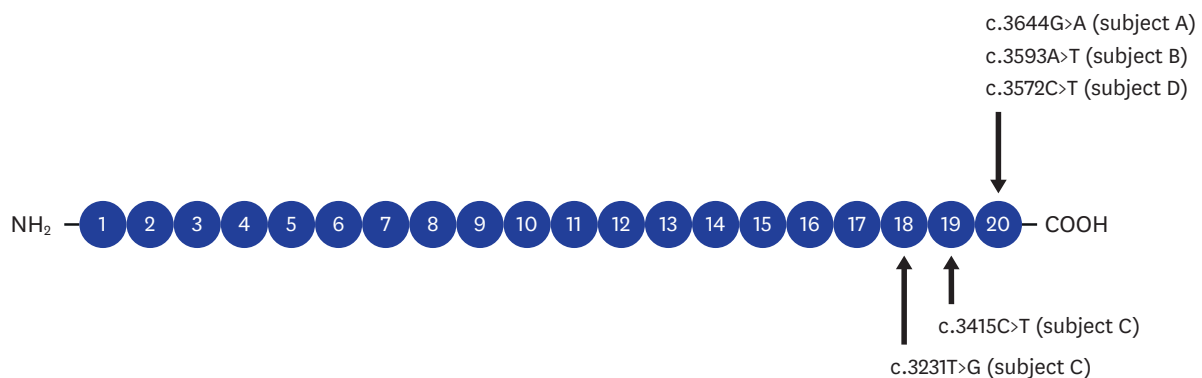


Fig. 2. Localization of the mutations in 4 patients. Subject A has a mutation of c.3644G>A, subject B has a mutation of c.3593A>T. Subject C has 2 mutations of c.3231T>G and c.3415C>T from both parents and subject D has a mutation of c.3572C>T.

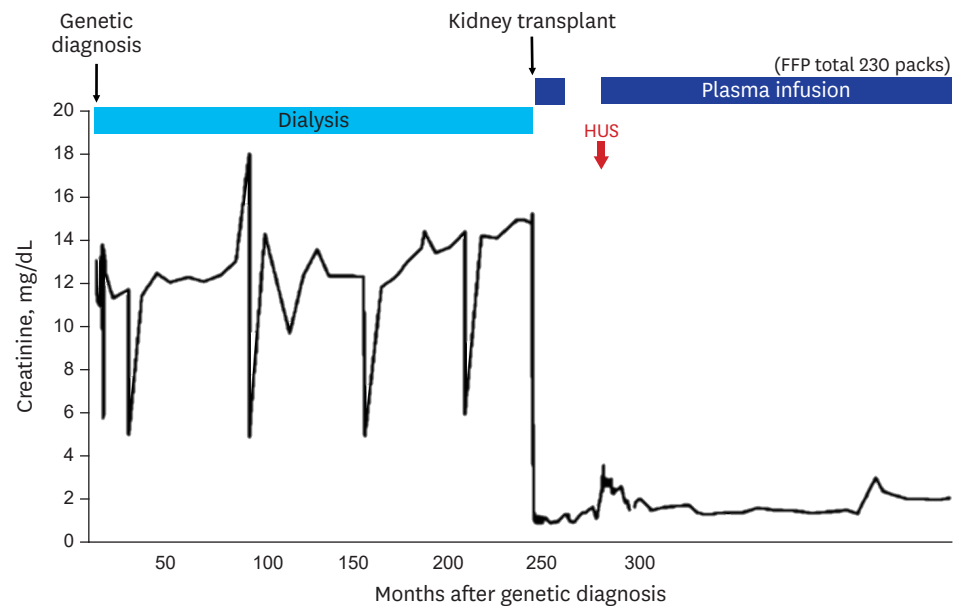


Fig. 3. Timeline of serum creatinine results and treatments for subject B. HUS = hemolytic uremic syndrome, FFP = fresh frozen plasma.

donor KT at the age of 14 years. Soon after the KT, she experienced several recurrences of aHUS coinciding with infections, such as *Pneumocystis pneumonia* and chickenpox (Fig. 3). Although she received intensive plasma infusion therapy, her allograft renal function did not fully recover. Currently, two years after the KT, she is managed with regular plasma infusions to prevent the recurrence of aHUS, with an allograft estimated glomerular filtration rate of 39 mL/min/1.73 m². She is still on the waiting list for a LT.

Subject C was a 12-year-old girl who presented with aHUS at one month of age with vomiting, generalized edema, and decreased urine output. At the initial presentation, she had anemia (hemoglobin, 9.3 g/dL and platelet count, 188,000/mm³), azotemia (serum BUN, 35 mg/dL and serum creatinine, 1.7 mg/dL) and hypoalbuminemia (2.6 g/dL) with proteinuria (spot urine protein creatinine ratio of 23.31). She also had low C3 (8 mg/dL) and C4 (9 mg/dL) levels. A renal biopsy revealed TMA with diffuse proliferative glomerulonephritis and C3 deposition. Her anemia and thrombocytopenia worsened (hemoglobin, 7.4 g/dL and platelets count, 77,000/mm³), and a peripheral blood smear showed schistocytes. The patient's serum *CFH* expression detected by western blotting was relatively low compared to that in a normal control (Fig. 4). After receiving a diagnosis of *CFH*-aHUS, the patient was treated with plasma infusion and recovered from acute hemolysis after four months. A genetic study of *CFH* confirmed the presence of a compound heterozygous mutation (c.3231T>G [p.Cys1077Trp] and c.3415C>T [p.Gln1139*]), both of which were inherited from her parents. Her renal function declined gradually as she experienced numerous episodes of aHUS that required hospital admission (45 times over a 9-year period) (Fig. 5A). When she was 9 years old, she received a deceased LT to replace the defective *CFH*. After the LT, her plasma complement and *CFH* levels normalized for the first time in her life (Fig. 4). However, the perioperative hemodynamic instability before and after surgery reduced her renal function, and she progressed to ESRD and received a living donor KT 6 months later. She is doing well without plasma infusion therapy after combined liver-kidney transplantation (CLKT) for 3 years (Fig. 5A).

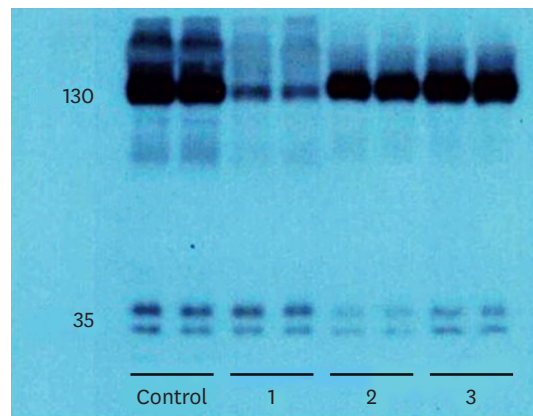


Fig. 4. Analysis of *CFH* binding by western blotting in subject C. The control sample is from a normal person. Lanes 1, 2, and 3 are the patient's results: lane 1 is before the LT, lane 2 is 2 weeks after the LT, and lane 3 is 25 days after the LT. The plasma *CFH* levels in the patient increased to within the normal range after the LT. *CFH* = complement factor H, LT = liver transplantation.

Subject D was a 7-year-old boy who presented with aHUS at the age of 1 year. He was managed with regular plasma infusion therapy. At the age of 4 years, genetic analysis found a heterozygous mutation (c.3572C>T [p.Ser119Leu]) in *CFH* (Fig. 2), which was inherited from his asymptomatic mother. He was transferred to our center for a LT. On admission, his laboratory findings were hemoglobin 10.2 g/dL, a platelet count of 298,000/mm³, BUN 51 mg/dL, and creatinine 1.00 mg/dL. His plasma complement C3 and C4 levels were 112 and 36 mg/dL, respectively. He had a normal serum albumin level with proteinuria (his spot urine protein creatinine ratio was 2.1). While awaiting a deceased donor LT, his renal function gradually deteriorated with repeated episodes of recurrence, and he progressed to ESRD at 5 years old. Soon thereafter, he received a deceased donor LT and subsequently received a living donor KT from his father. After the operations, he has been free from aHUS for 14 months (Fig. 5B).

DISCUSSION

As described above, *CFH*-aHUS is considered a devastating disease. Patients with *CFH*-aHUS experience numerous episodes of recurrence and often progress to ESRD if they survive. All four cases in this study suffered from a recurrence of aHUS, usually coinciding with infection, and lost kidney functions at the age of 5–7 years. However, their presentations were diverse, probably due to their mutation types and sites, which would have different consequences on the quantity and quality of *CFH*. Subject C has combined heterozygous mutations in *CFH*; both of her *CFH* alleles are defective, and one allele has a stop-gain mutation leading to very low *CFH* and C3 levels. The other subjects, who presented later than subject C, had missense mutations on SCR20 in one of their two alleles and normal *CFH* and C3 levels. Although subject C suffered more frequent and more severe recurrences, her diagnosis was straightforward from a very early stage due to her very low *CFH* concentration; thus, the patient has been very aggressively treated with plasma. Conversely, a definitive diagnosis was uncertain for the other patients until the genetic analysis was conducted at a later time point for research purposes. Therefore, the plasma therapy applied for these patients was less aggressive than the therapy applied for subject C, which might be related to the worse outcomes. For subjects A and B, a definitive diagnosis of *CFH*-aHUS was obtained only after their diseases progressed to ESRD; subject A obtained her diagnosis only after she lost her first allograft (Table 1). Nonetheless, the clinical

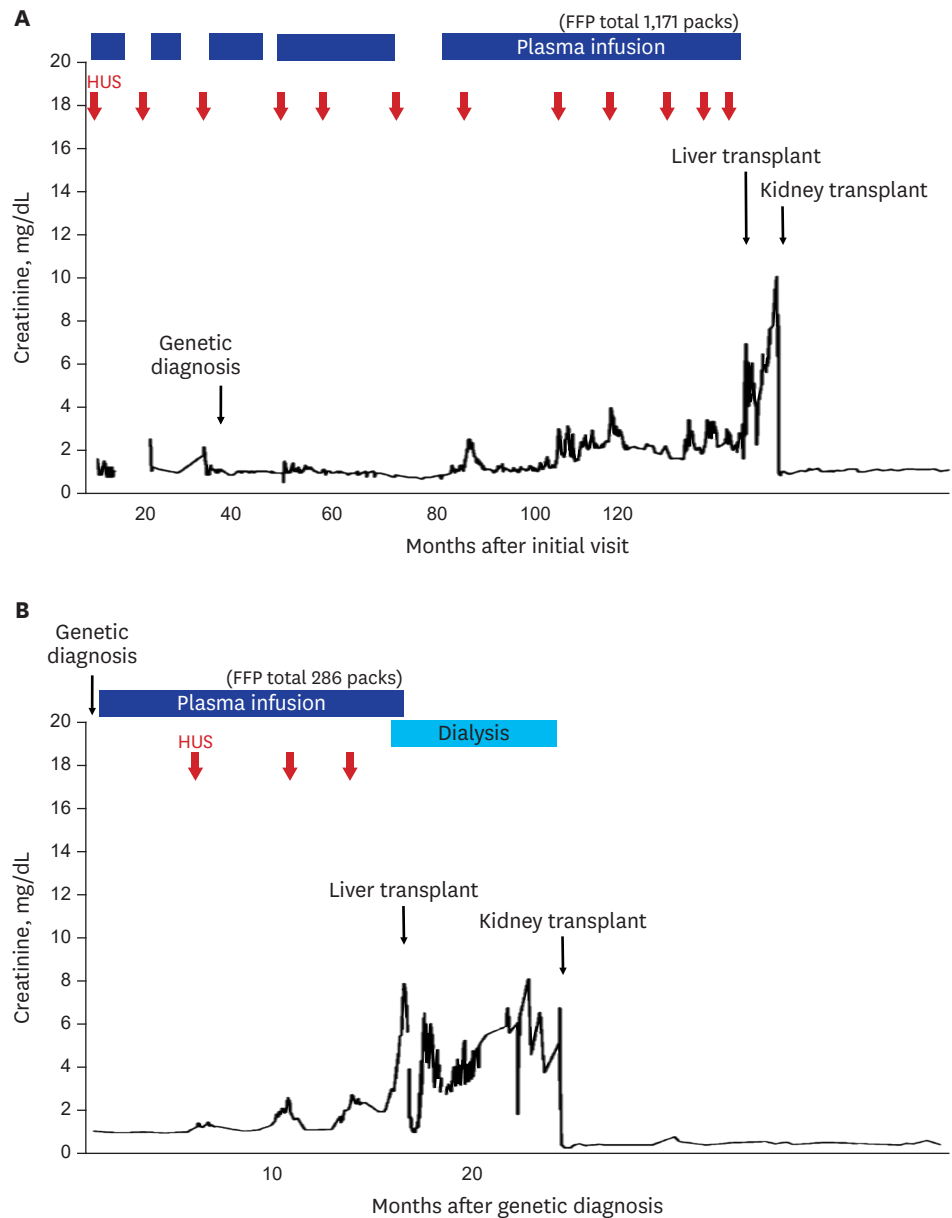


Fig. 5. Timeline of serum creatinine results and treatments. (A) Subject C. (B) Subject D. HUS = hemolytic uremic syndrome, FFP = fresh frozen plasma.

courses before the KT in the subjects were similar, with all four patients progressing to ESRD due to aHUS with episodes of acute exacerbation of renal dysfunction. However, the clinical courses after KT were quite different depending on whether the subjects had received an LT. The patients with an LT (subjects C and D) are having uneventful courses of CLKKT. Despite several infection episodes, the patients without a LT (subjects A and B) have suffered from a recurrence of aHUS and repetitive insults on the allograft kidneys.

Although plasma therapy has been the mainstay of aHUS treatment advocated by the guideline from the European Pediatric Study Group for HUS published in 2009,¹⁵ plasma therapy cannot prevent renal damage, as shown in our subjects. Additionally, plasma therapy is sometimes associated with considerable morbidity due to central line-associated

Table 1. Clinical and biochemical characteristics of *CFH*-aHUS patients from our study

Characteristics	Subject A	Subject B	Subject C	Subject D
Age at presentation	3 yr	7 yr	1 mon	1 yr
Symptoms at presentation	Fever, cough, vomiting	Vomiting, hematuria	Vomiting, generalized edema, gross hematuria	Fever
<i>CFH</i> mutation	c.3644G>A (p.Arg1215Gln)	c.3593A>T (p.Glu1198Val)	c.3231T>G (p.Cys1077Trp) c.3415C>T (p.Gln1139*)	c.3572C>T (p.Ser1191Leu)
Age of ESRD	5 yr	7 yr 6 mon	6 yr 8 mon	5 yr 9 mon
Age of KT/donor type	8 yr/DDKT 12 yr/DDKT	13 yr/DDKT	9 yr/LDKT	6 yr/LDKT
Recurrence after KT	+	+	-	-
Age of LT/donor type	-	-	9 yr/DDLT	5 yr/DDLT
Last eGFR, mL/min/1.73 m ²	3.3 (4 yr 8 mon after KT)	29 (2 yr 5 mon after KT)	126.8 (2 yr 7 mon after KT)	243 (1 yr 3 mon after KT)

CFH = complement factor H, aHUS = atypical hemolytic uremic syndrome, KT = kidney transplantation, DDKT = deceased donor kidney transplantation, LDKT = living donor kidney transplantation, ESRD = end-stage renal disease, LT = liver transplantation, DDLT = deceased donor liver transplantation, eGFR = estimated glomerular filtration rate.

bloodstream infections and a hypersensitivity to plasma.^{16,17} Therefore, a more effective therapeutic strategy than plasma therapy is required. LT has been an option for the treatment of patients with aHUS due to defective *CFH* or *CFI*. Since 2002, approximately 25 patients who have undergone LT alone or CLKT for aHUS have been reported in the literature (Table 2).^{7,18-31} The outcomes of LT have been variable, ranging from the demise of the patients from LT complications^{23,24} to a successful long-term outcome.^{8,9,21} In the current study, we report two more cases with a successful clinical course of CLKT.

Eculizumab, which is a more effective therapeutic strategy than plasma therapy, currently is available in at least some parts of the world. Eculizumab therapy is a very effective treatment for aHUS considering the pathogenesis of the disease and is well established due to well-designed prospective studies. However, this therapy is very costly. In 2009, the European guidelines suggested that eculizumab was the first line therapy for aHUS.¹²

The long-term impairment of the immune system is a problem not only for eculizumab but also for LT, since recipients of a LT also need to take immunosuppressive medication as long as their grafted liver is functioning. Moreover, if the *CFH*-aHUS patient is a KT recipient, the patient needs to take immunosuppressive medications to prevent rejection of the KT even when the patient is managed with eculizumab. Thus, for KT recipients, LT would not result in additional immunosuppression. In the past, the surgical outcome of LT was not satisfactory for aHUS patients due to their thrombotic diathesis, but recently the application of

Table 2. Published reports on liver or CLKT in *CFH*-aHUS patients

Authors (yr)	Age at presentation	<i>CFH</i> mutation	Age of KT	Age of LT	Outcome
Remuzzi et al. (2002) ¹⁹	1 yr	c.3547T>A (p.Trp1183Arg)	(+)	(+)	Alive
Cheong et al. (2004) ²⁰	3 mon	c.2777G>T (p.Cys926Phe)	(-)	30 mon	Died
Remuzzi et al. (2005) ²¹	13 mon	c.3514G>T (p.Glu1172*)	3 yr	3 yr	Died
Saland et al. (2006) ²²	4 mon	c.3590T>C (p.Val1197Ala) c.2918G>A (p.Cys973Tyr) compound heterozygous	26 mon	5 yr	Alive
Jalanko et al. (2008) ²⁸	12 mon	c.3644G>A (p.Arg1215Gln)	18 mon	18 mon	Alive
Saland et al. (2009) ²³	9 mon	c.3572C>T (p.Ser1191Leu)	4 yr	4 yr	Alive
Haller et al. (2010) ²⁹	5 mon	c.3644G>A (p.Arg1215Gln)	(-)	5 yr	Alive
Tran et al. (2014) ³⁰	11 mon	c.3644G>A (p.Arg1215Gln)	5 yr	5 yr	Alive
Gonzales et al. (2016) ²⁶	5 mon	c.2697T>A (p.Tyr899*) homozygous	(+)	(+)	Alive
Coppo et al. (2016) ⁸	6 mon	c.3572C>T (p.Ser1191Leu)	5 yr	8 yr	Alive

CLKT = combined liver-kidney transplantation, *CFH* = complement factor H, aHUS = atypical hemolytic uremic syndrome, KT = kidney transplantation, LT = liver transplantation.

perioperative plasmapheresis or eculizumab therapy has much improved the prognosis of LT in *CFH*-aHUS patients.²⁴ Therefore, for KT recipients with *CFH*-aHUS, LT may be a better choice than eculizumab; for instance, our subjects C and D, who are CLKT recipients, will not require eculizumab if their liver allografts last.

However, LT is only applicable for patients with proven causative mutations of *CFH* or *CFI* whose main source is the liver.¹⁸ Patients with mutations of other complement regulators or whose mutations have not been found are not eligible for LT, because LT may not satisfactorily restore the defective component. Conversely, non-responders of eculizumab would have to choose to receive an LT if they had defective *CFH* or *CFI*.

In the past, isolated LT was considered early in the course of *CFH*-aHUS to prevent further damage of the kidneys and to preserve renal functions.²³ Is this approach still feasible in this era of eculizumab? From a medical cost perspective, the answer is yes. From the immunological perspective, which option is a better choice is unknown. LT has its own limitations (i.e., it may be rejected at any time and is not reversible), whereas eculizumab may be discontinued at any time if indicated. Moreover, the clinical courses of *CFH*-aHUS are quite variable.^{23,26} Although all of the patients described in this study lost their kidneys, some patients with the same genetic background grow out of the disease and do not need a constant restoration of *CFH* or the inhibition of complement activation; for example, some of the parents of our subjects were completely asymptomatic even though they had same *CFH* mutation as the subjects. Therefore, a genetic diagnosis of *CFH*-aHUS per se is not an indication for LT³²⁻³⁵ even if the procedure is feasible. For patients with *CFH*-aHUS whose course is not devastating, eculizumab is the better choice, because it can be discontinued when the patient's condition improves.

Additional studies are needed to evaluate the long-term prognosis and risk-benefit of LT or CLKT. Additionally, clinicians should deeply consider the best treatment for refractory aHUS and maintain their adherence to national or international registries for aHUS patients after transplantation.²⁴

For patients with *CFH*-aHUS, plasma therapy is not sufficiently effective to prevent renal failure. In *CFH*-aHUS patients, KT without LT was complicated with the recurrence of aHUS, which might lead to allograft loss. Conversely, LT was successful for the prevention of the recurrence of aHUS. LT may be an option for an aHUS-free life for aHUS patients with proven genetic defects in *CFH* or *CFI*, even in the era of eculizumab, which is a costly standard therapy.

REFERENCES

1. Richards A, Goodship JA, Goodship TH. The genetics and pathogenesis of haemolytic uraemic syndrome and thrombotic thrombocytopenic purpura. *Curr Opin Nephrol Hypertens* 2002;11(4):431-5.
[PUBMED](#) | [CROSSREF](#)
2. Saland JM, Ruggenti P, Remuzzi GConsensus Study Group. Liver-kidney transplantation to cure atypical hemolytic uremic syndrome. *J Am Soc Nephrol* 2009;20(5):940-9.
[PUBMED](#) | [CROSSREF](#)
3. Maga TK, Nishimura CJ, Weaver AE, Frees KL, Smith RJ. Mutations in alternative pathway complement proteins in American patients with atypical hemolytic uremic syndrome. *Hum Mutat* 2010;31(6):E1445-60.
[PUBMED](#) | [CROSSREF](#)

4. Sellier-Leclerc AL, Fremeaux-Bacchi V, Dragon-Durey MA, Macher MA, Niaudet P, Guest G, et al. Differential impact of complement mutations on clinical characteristics in atypical hemolytic uremic syndrome. *J Am Soc Nephrol* 2007;18(8):2392-400.
[PUBMED](#) | [CROSSREF](#)
5. Nilsson SC, Karpman D, Vaziri-Sani F, Kristoffersson AC, Salomon R, Provot F, et al. A mutation in factor I that is associated with atypical hemolytic uremic syndrome does not affect the function of factor I in complement regulation. *Mol Immunol* 2007;44(8):1835-44.
[PUBMED](#) | [CROSSREF](#)
6. Kavanagh D, Goodship TH, Richards A. Atypical hemolytic uremic syndrome. *Semin Nephrol* 2013;33(6):508-30.
[PUBMED](#) | [CROSSREF](#)
7. Coppo R, Bonaudo R, Peruzzi RL, Amore A, Brunati A, Romagnoli R, et al. Liver transplantation for aHUS: still needed in the eculizumab era? *Pediatr Nephrol* 2016;31(5):759-68.
[PUBMED](#) | [CROSSREF](#)
8. Bresin E, Daina E, Noris M, Castelletti F, Stefanov R, Hill P, et al. Outcome of renal transplantation in patients with non-Shiga toxin-associated hemolytic uremic syndrome: prognostic significance of genetic background. *Clin J Am Soc Nephrol* 2006;1(1):88-99.
[PUBMED](#) | [CROSSREF](#)
9. Loirat C, Frémeaux-Bacchi V. Atypical hemolytic uremic syndrome. *Orphanet J Rare Dis* 2011;6:60.
[PUBMED](#) | [CROSSREF](#)
10. Afshar-Kharghan V. Unleashed platelets in aHUS. *Blood* 2008;111(11):5266.
[PUBMED](#) | [CROSSREF](#)
11. Zuber J, Fakhouri F, Roumenina LT, Loirat C, Frémeaux-Bacchi V French Study Group for aHUS/C3G. Use of eculizumab for atypical haemolytic uraemic syndrome and C3 glomerulopathies. *Nat Rev Nephrol* 2012;8(11):643-57.
[PUBMED](#) | [CROSSREF](#)
12. Loirat C, Fakhouri F, Ariceta G, Besbas N, Bitzan M, Bjerre A, et al. An international consensus approach to the management of atypical hemolytic uremic syndrome in children. *Pediatr Nephrol* 2016;31(1):15-39.
[PUBMED](#) | [CROSSREF](#)
13. Lee JM, Park YS, Lee JH, Park SJ, Shin JI, Park YH, et al. Atypical hemolytic uremic syndrome: Korean pediatric series. *Pediatr Int* 2015;57(3):431-8.
[PUBMED](#) | [CROSSREF](#)
14. Miyata Y, Akamatsu N, Sugawara Y, Kaneko J, Yamamoto T, Suzuki H, et al. Pharmacokinetics of a once-daily dose of tacrolimus early after liver transplantation: with special reference to CYP3A5 and ABCB1 single nucleotide polymorphisms. *Ann Transplant* 2016;21:491-9.
[PUBMED](#) | [CROSSREF](#)
15. Ariceta G, Besbas N, Johnson S, Karpman D, Landau D, Licht C, et al. Guideline for the investigation and initial therapy of diarrhea-negative hemolytic uremic syndrome. *Pediatr Nephrol* 2009;24(4):687-96.
[PUBMED](#) | [CROSSREF](#)
16. Johnson S, Stojanovic J, Ariceta G, Bitzan M, Besbas N, Frieling M, et al. An audit analysis of a guideline for the investigation and initial therapy of diarrhea negative (atypical) hemolytic uremic syndrome. *Pediatr Nephrol* 2014;29(10):1967-78.
[PUBMED](#) | [CROSSREF](#)
17. Taylor CM. Complement factor H and the haemolytic uraemic syndrome. *Lancet* 2001;358(9289):1200-2.
[PUBMED](#) | [CROSSREF](#)
18. Remuzzi G, Ruggenenti P, Codazzi D, Noris M, Caprioli J, Locatelli G, et al. Combined kidney and liver transplantation for familial haemolytic uraemic syndrome. *Lancet* 2002;359(9318):1671-2.
[PUBMED](#) | [CROSSREF](#)
19. Cheong HI, Lee BS, Kang HG, Hahn H, Suh KS, Ha IS, et al. Attempted treatment of factor H deficiency by liver transplantation. *Pediatr Nephrol* 2004;19(4):454-8.
[PUBMED](#) | [CROSSREF](#)
20. Remuzzi G, Ruggenenti P, Colledan M, Gridelli B, Bertani A, Bettinaglio P, et al. Hemolytic uremic syndrome: a fatal outcome after kidney and liver transplantation performed to correct factor h gene mutation. *Am J Transplant* 2005;5(5):1146-50.
[PUBMED](#) | [CROSSREF](#)
21. Saland JM, Emre SH, Shneider BL, Benchimol C, Ames S, Bromberg JS, et al. Favorable long-term outcome after liver-kidney transplant for recurrent hemolytic uremic syndrome associated with a factor H mutation. *Am J Transplant* 2006;6(8):1948-52.
[PUBMED](#) | [CROSSREF](#)

22. Saland JM, Shneider BL, Bromberg JS, Shi PA, Ward SC, Magid MS, et al. Successful split liver-kidney transplant for factor H associated hemolytic uremic syndrome. *Clin J Am Soc Nephrol* 2009;4(1):201-6.
[PUBMED](#) | [CROSSREF](#)
23. Haller W, Milford DV, Goodship TH, Sharif K, Mirza DF, McKiernan PJ. Successful isolated liver transplantation in a child with atypical hemolytic uremic syndrome and a mutation in complement factor H. *Am J Transplant* 2010;10(9):2142-7.
[PUBMED](#) | [CROSSREF](#)
24. Saland J. Liver-kidney transplantation to cure atypical HUS: still an option post-eculizumab? *Pediatr Nephrol* 2014;29(3):329-32.
[PUBMED](#) | [CROSSREF](#)
25. Gonzales E, Ulinski T, Habes D, Deschênes G, Frémeaux-Bacchi V, Bensman A. Long-term successful liver-kidney transplantation in a child with atypical hemolytic uremic syndrome caused by homozygous factor H deficiency. *Pediatr Nephrol* 2016;31(12):2375-8.
[PUBMED](#) | [CROSSREF](#)
26. Noris M, Remuzzi G. Atypical hemolytic-uremic syndrome. *N Engl J Med* 2009;361(17):1676-87.
[PUBMED](#) | [CROSSREF](#)
27. Jalanko H, Peltonen S, Koskinen A, Puntila J, Isoniemi H, Holmberg C, et al. Successful liver-kidney transplantation in two children with aHUS caused by a mutation in complement factor H. *Am J Transplant* 2008;8(1):216-21.
[PUBMED](#)
28. Tran H, Chaudhuri A, Concepcion W, Grimm PC. Use of eculizumab and plasma exchange in successful combined liver-kidney transplantation in a case of atypical HUS associated with complement factor H mutation. *Pediatr Nephrol* 2014;29(3):477-80.
[PUBMED](#) | [CROSSREF](#)
29. Nishimura J, Yamamoto M, Hayashi S, Ohyashiki K, Ando K, Brodsky AL, et al. Genetic variants in C5 and poor response to eculizumab. *N Engl J Med* 2014;370(7):632-9.
[PUBMED](#) | [CROSSREF](#)
30. Schalk G, Kirschfink M, Wehling C, Gastoldi S, Bergmann C, Hoppe B, et al. A complicated case of atypical hemolytic uremic syndrome with frequent relapses under eculizumab. *Pediatr Nephrol* 2015;30(6):1039-42.
[PUBMED](#) | [CROSSREF](#)
31. Park SH, Kim GS. Anesthetic management of living donor liver transplantation for complement factor H deficiency hemolytic uremic syndrome: a case report. *Korean J Anesthesiol* 2014;66(6):481-5.
[PUBMED](#) | [CROSSREF](#)
32. Terrell DR, Vesely SK, Kremer Hovinga JA, Lämmle B, George JN. Different disparities of gender and race among the thrombotic thrombocytopenic purpura and hemolytic-uremic syndromes. *Am J Hematol* 2010;85(11):844-7.
[PUBMED](#) | [CROSSREF](#)
33. Burchard EG, Ziv E, Coyle N, Gomez SL, Tang H, Karter AJ, et al. The importance of race and ethnic background in biomedical research and clinical practice. *N Engl J Med* 2003;348(12):1170-5.
[PUBMED](#) | [CROSSREF](#)
34. Cheong HI, Jo SK, Yoon SS, Cho H, Kim JS, Kim YO, et al. Clinical practice guidelines for the management of atypical hemolytic uremic syndrome in Korea. *J Korean Med Sci* 2016;31(10):1516-28.
[PUBMED](#) | [CROSSREF](#)
35. Cho H. Complement regulation: physiology and disease relevance. *Korean J Pediatr* 2015;58(7):239-44.
[PUBMED](#) | [CROSSREF](#)