



## Research Report

## Primary vaginal sarcoma in a single center

Hua Yuan<sup>a,1,\*</sup>, Tonghui Wang<sup>b,1</sup><sup>a</sup> Department of Gynecologic Oncology, National Cancer Center/National Clinical Research Center for Cancer/Cancer Hospital, Chinese Academy of Medical Sciences and Peking Union Medical College, Beijing, China<sup>b</sup> Clinical Lab, Beijing Bo'ai Hospital, China Rehabilitation Research Center, Beijing, China

## ARTICLE INFO

## Keywords:

Vaginal sarcoma  
Clinical characteristics  
Prognosis

## ABSTRACT

**Objectives:** To investigate the clinical characteristics and prognosis of primary vaginal sarcoma.**Methods:** A retrospective analysis of patients with primary vaginal sarcoma treated at our center from 2000 to 2020 was conducted.**Results:** Fifteen patients were identified, among which 9 (60.0 %) patients had leiomyosarcoma, 2 (13.3 %) patients had Ewing's sarcoma, 2 (13.3 %) patients had rhabdomyosarcoma, 1 (6.7 %) patient had undifferentiated sarcoma, and 1 (6.7 %) patient had malignant peripheral schwannoma. Nine patients presented with vaginal mass that was the most common primary symptoms. Eleven patients received their primary surgery, and 7 of them received postoperative adjuvant chemotherapy or radiation therapy. The remaining 4 patients received initial chemotherapy and/or radiotherapy because of advanced stage. The distribution by stage was as follows: stage I in 10 patients, stage II in 1 patient, stage III in 2 patients and stage IV in 2 patients. The median follow-up was 43.7 months (10.1–137.5 months). Thirteen patients (86.7 %) had disease extent during follow-up, and among them, 11 patients (11/13, 84.6 %) developed local relapse or adjacent organ metastases, 1 patient (1/13, 7.7 %) developed liver metastases, and the remaining 1 patient (1/13, 7.7 %) developed lung metastases and local relapse during follow-up. Ten (10/13, 76.9 %) patients relapsed within 2 years after diagnosis. Eight patients (8/11, 72.7 %) with local recurrence or adjacent organ metastases received a secondary surgery treatment, and only 2 of them relapsed again. Two-year overall survival (OS) and 5-year OS were 80.0 % and 66.7 %, respectively. Patients with leiomyosarcoma had a tendency toward a better 5-year OS than those with other sarcomas (74.1 % vs 66.7 %,  $P = 0.307$ ).**Conclusions:** Primary vaginal sarcomas are aggressive neoplasms with different presenting characteristics. Surgery is the main treatment for primary vaginal sarcoma and for local relapse vaginal sarcoma.

## 1. Introduction

Primary vaginal cancer is rare, constituting only 1 %–2% of all female genital tract malignancies and only 10 % of all vaginal malignant neoplasms (Sung et al., 2021). The predominant histologic subtype in primary vaginal cancer is squamous carcinoma, which comprises 90 % of cases. Adenocarcinoma accounts for approximately 8 %–10 % of cases. Sarcomas, lymphomas, and melanomas of the vagina are extremely rare (Adams et al., 2021). Sarcomas constitute 2 % of malignant vaginal lesions, with leiomyosarcomas being the most common type of sarcoma (Matsuo et al., 2009).

Primary vaginal sarcomas are aggressive neoplasms with different

presenting characteristics and increased adjusted risk of mortality as compared to squamous cell and adenocarcinoma subtypes (Ghezelayagh et al., 2015). Because of their low incidence and the lack of prospective studies, it is very difficult to reach conclusions regarding the best disease management recommendations for primary vaginal sarcoma. Surgical resection of the tumor is currently the modality of choice for patients with localized disease (Khosla et al., 2014).

We therefore conducted a retrospective cohort study to evaluate the clinical characteristics and treatment outcomes of women with primary vaginal sarcoma and identify prognostic factors.

\* Corresponding author at: Department of Gynecologic Oncology, National Cancer Center/National Clinical Research Center for Cancer/Cancer Hospital, Chinese Academy of Medical Sciences and Peking Union Medical College, Beijing 100021, China.

E-mail address: [huage19880915@126.com](mailto:huage19880915@126.com) (H. Yuan).

<sup>1</sup> These authors contributed equally to the work.

<https://doi.org/10.1016/j.gore.2022.101122>

Received 13 September 2022; Received in revised form 26 October 2022; Accepted 23 November 2022

Available online 13 December 2022

2352-5789/© 2022 The Author(s). Published by Elsevier Inc. This is an open access article under the CC BY-NC-ND license (<http://creativecommons.org/licenses/by-nc-nd/4.0/>).

## 2. Patients and methods

### 2.1. Patients

After receiving approval from the Institutional Review Board, we performed a retrospective analysis of all patients diagnosed to have primary vaginal sarcoma from January 1, 2000 to January 1, 2020 who received treatment in the Department of Gynecological Oncology of Cancer Hospital, Chinese Academy of Medical Sciences, National Cancer Center. Only patients with a diagnosis of primary vaginal sarcoma confirmed by an experienced gynecologic pathologist in our hospital were included. The patients' full medical records were included in this study. Clinical and pathologic variables, treatment modalities, and outcomes were assessed. Stage was retrospectively assigned using the International Federation of Gynecology and Obstetrics (FIGO) 2009 staging system for uterine sarcomas.

### 2.2. Statistical analyses

For the survival analyses, overall survival (OS) was defined as the time from the date of diagnosis to death for which primary vaginal sarcoma was the primary or underlying cause. Survival was estimated using the Kaplan–Meier product-limit method, and differences were tested for statistical significance using the log-rank test. Two-sided P-values < 0.05 were considered statistically significant. All analyses were performed using SPSS Statistics 20.0 software.

## 3. Results

### 3.1. Patient characteristics

Fifteen patients were identified. The median age of all patients was 48 years (range, 29–66 years). Nine patients (60.0 %, 9/15) were diagnosed to have the tumor before the age of 50 years. Nine patients presented with vaginal mass, which was the most common primary symptom. Four and two patients presented with vaginal bleeding and difficulty with defecation, respectively. The proportion of patients with a smaller tumor (< 5 cm) was only 33.3 % as compared to 66.7 % for tumors  $\geq$  5 cm (Table 1).

Furthermore, 40 % (6/15) and 40 % (6/15) tumors occur in the anterior or lateral wall of the vagina, respectively. Two patients had a tumor in the posterior wall of the vagina, while 1 patient had a tumor in the vaginal cuff. Additionally, 40 % (6/15) and 60 % (9/15) tumors occurred in the upper and lower vagina, respectively (Table 1).

Of these patients, 9 (60.0 %) patients had leiomyosarcoma, 2 (13.3 %) patients had Ewing's sarcoma, 2 (13.3 %) patients had rhabdomyosarcoma, 1 (6.7 %) patient had undifferentiated sarcoma, and 1 (6.7 %) patient had malignant peripheral schwannoma. The FIGO 2009 distribution according to the stage was as follows: stage I in 10 patients, stage II in 1 patient, stage III in 2 patients, and stage IV in 2 patients (Table 1).

### 3.2. Treatment

#### 3.2.1. Surgical treatment

Eleven patients received their primary surgery at our institution or at an outside institution. The remaining 4 patients received initial chemotherapy and/or radiotherapy because of advanced stage disease. For patients who received surgery (n = 11), 8 patients received simple resection, and 3 patients received local wide excision. Five patients received simple resection from an external institution (Table 1). In 90.9 % (10/11) and 9.1 % (1/11) of the cases, patients were diagnosed with stage I or stage III disease, respectively.

#### 3.2.2. Adjuvant therapy

Seven patients received postoperative adjuvant therapy after

**Table 1**

Clinicopathological characteristics of patient with primary vaginal sarcoma (n = 15).

Clinical Characteristics	n	%
<b>Age (years)</b>		
<50	9	60.0
$\geq$ 50	6	40.0
<b>Primary symptoms</b>		
Vaginal mass	9	60.0
Vaginal bleeding	4	26.7
Difficulty with defecation	2	13.3
<b>Tumor size (cm)</b>		
< 5	5	33.3
$\geq$ 10	10	66.7
<b>Pathologic Stage</b>		
I	10	66.7
II	1	6.7
III	2	13.3
IV	2	13.3
<b>Pathological subtype</b>		
Leiomyosarcoma	9	60.0
Ewing's sarcoma	2	13.3
Rhabdomyosarcoma	2	13.3
Undifferentiated sarcoma	1	6.7
Malignant peripheral schwannoma	1	6.7
<b>Tumor site</b>		
Anterior	6	40.0
Lateral	6	40.0
Posterior	2	13.3
Vaginal cuff	1	6.7
<b>Tumor location</b>		
Upper	6	40.0
Lower	9	60.0
<b>Treatment</b>		
Surgery alone	4	26.7
Surgery + chemo	5	33.3
Surgery + radio	1	6.7
Surgery + chemo + radio	1	6.7
Chemo alone	2	13.3
Chemo + radio	2	13.3
<b>Surgical treatment</b>		
Simple resection	8	53.3
Local wide excision	3	20.0
No surgery	4	26.7
<b>Recurrent disease</b>		
Yes	13	86.7
No	2	13.3

NOTE.

Abbreviations.

chemo, chemotherapy.

radio, radiotherapy.

surgery. Five (71.4 %) of 7 patients received adjuvant chemotherapy. The treatments included the following: doxorubicin/ifosfamide/cisplatin (4), ifosfamide/cisplatin (1). One patient (14.3 %, 1/7) received adjuvant intravaginal brachytherapy. One patient (14.3 %, 1/7) received adjuvant pelvic radiation. One patient (14.3 %, 1/7) received endocrine treatment after surgery.

#### 3.2.3. Non-surgical treatment

One patient with stage III disease received anthracycline-based chemotherapy and intravaginal brachytherapy. For patients with stage IV disease, 1 of them received three lines of chemotherapy regimens, and the disease progressed during therapy. She died 10 months after diagnosis. The other one received anthracycline-based chemotherapy, pelvic external radiotherapy and brachytherapy plus cisplatin-based chemotherapy. One patient with stage II disease received chemotherapy (Table 1).

### 3.3. Recurrent disease

Thirteen patients (13/15, 86.7 %) had disease extent during follow-up, among whom 11 (11/1384.6 %) patients developed local relapse or

adjacent organ metastases, 1 patient (1/13, 7.7 %) developed liver metastases, and the remaining 1 patient (1/13, 7.7 %) developed lung metastases and local relapse during follow-up (Table 2). Ten (10/13, 76.9 %) of them relapsed within 2 years after diagnosis. Eight patients (8/11, 72.7 %) with local recurrence or adjacent organ metastases received a surgery treatment including 2 patients received anterior pelvic exenteration and 7 patients had no residual disease after surgery. (Table 3) 25 % (2/8) of them relapsed again. Other 5 patients (5/13, 38.5 %) with recurrent disease received systematic chemotherapy. (Table 3).

### 3.4. Survival analysis

The median follow-up time was 43.7 months (range 10.1–137.5 months). Five patients died during follow up. Two-year OS and 5-year OS were 80.0 % and 66.7 %, respectively. (Fig. 1) Patients with leiomyosarcoma had a tendency toward better survival than those with other sarcomas (5-year OS: 74.1 % vs 66.7 %,  $P = 0.307$ ). (Fig. 2).

## 4. Discussion

Primary vaginal sarcomas are rare gynecologic tumors with easy recurrence and an unknown etiology. In the present study, 15 patients with primary vaginal sarcomas treated at our institution from 2000 to 2020 were analyzed. Our series is one of the largest to report on surgical and treatment outcomes for patients with primary vaginal sarcomas in a single center.

Compared to women with squamous cell carcinoma and adenocarcinoma, patients diagnosed to have vaginal sarcomas tend to be younger, have larger tumors with less regional extension and lymph node positivity, and be treated primarily with surgery without radiation (Ghezelayagh et al., 2015).

Because of the rarity, there is no standard of treatment in the literature, and management should be undertaken by clinicians experienced in these particular malignancies (Magné et al., 2011). Surgery is the main treatment for primary vaginal sarcoma, especially for patients with early stage (Wang et al., 2015). Surgical treatments include simple resection, local wide excision, and radical vaginectomy. Radical surgery may have the best prognosis. Some patients received only simple resection of the tumor and were diagnosed with sarcoma after initial surgery. In our present study, patients who received simple resection had stage I disease, and tumor recurrence occurred in all of them. The median time from diagnosis to first recurrence was 13.6 months.

Before surgery, a biopsy is recommended to obtain a definitive diagnosis, to differentiate between benign and malignant lesions, and to plan the optimal surgical strategy (Horn et al., 1998). Biopsy followed by immunohistochemistry and electron microscopy still represents a good diagnostic choice.

The benefit of adjuvant chemotherapy and radiotherapy remains unclear in the treatment of vaginal sarcoma. Although there are limited data specifically examining chemotherapy or radiation in vaginal sarcoma, the retrospective and prospective experience in gynecologic sarcomas echo the soft tissue sarcoma data. These data are primarily obtained for uterine sarcoma and suggest that postoperative therapy leads to a reduction in local relapse with no benefit in progression-free

**Table 2**  
Sites of first relapse disease in the entire population (n = 15).

First recurrence	All	
	N	(%)
Vaginal	9	69.2
Vulvar	1	7.7
Liver	1	7.7
Lung + vaginal	1	7.7
Inguinal lymph nodes	1	7.7

**Table 3**  
Treatment for patients with recurrent vaginal sarcoma (n = 13).

Treatment	N	(%)
Surgery alone	6	46.2
Surgery + chemo	1	7.7
Surgery + radio + endoc	1	7.7
Chemo alone	5	38.5
Total	13	

Abbreviation: chemo, chemotherapy; radio, radiotherapy.

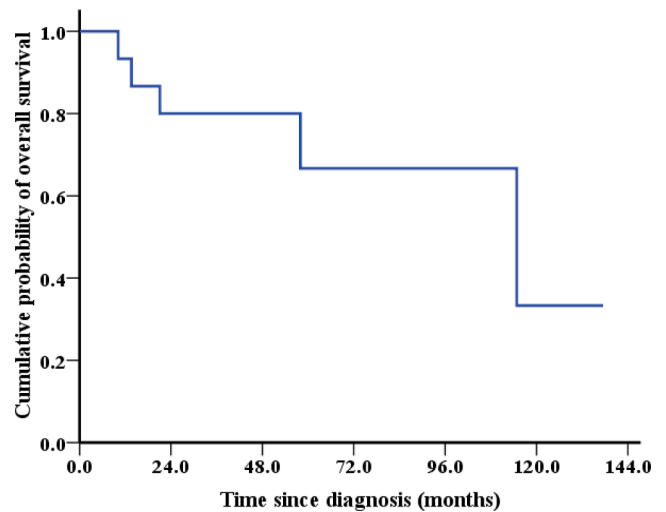


Fig. 1. Kaplan–Meier estimates of overall survival in 15 patients with primary vaginal sarcoma.

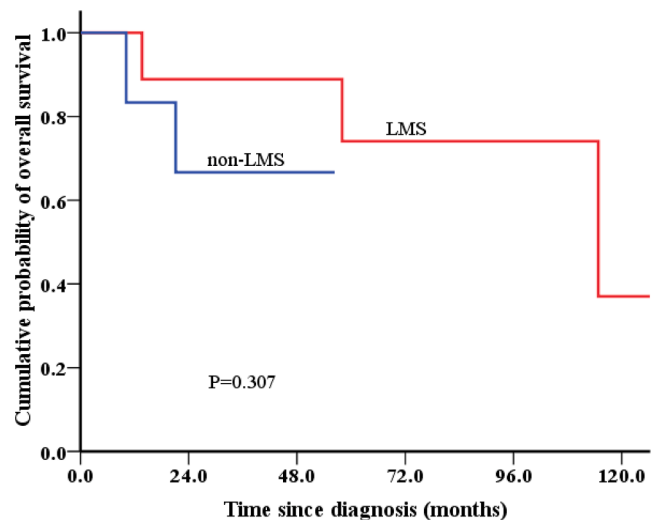


Fig. 2. Kaplan–Meier estimates of overall survival according to the pathological subtype in 15 patients with primary vaginal sarcoma.

or overall survival (Ghezelayagh et al., 2015). Because the poor prognosis of vaginal sarcoma, adjuvant chemotherapy is suitable for these patients, especially for those with poor prognostic factors. 63.6 % (7/11) patients in our study received adjuvant therapy.

Primary vaginal sarcomas have a high tendency for local recurrent after initial treatment. Patients with single site recurrence are more likely to receive cytoreduction surgery and achieve a complete resection with no residual disease. Similar to patients diagnosed with uterine sarcomas, resection of pulmonary metastases may offer women with recurrent vaginal leiomyosarcoma improved survival with good quality

of life (Anderson and Bodurka, 2008). Optimal surgical resection for recurrent vaginal sarcomas may provide an opportunity for long-term survival in a select patient population.

Pelvic exenteration remains a therapeutic option with an acceptable complication rate and postoperative mortality rate (Chiantera et al., 2014). Pelvic exenteration performed with curative intent may be considered a treatment option in well-counseled, carefully selected patients, irrespective of tumor size and progression-free interval before exenteration (Straubhar et al., 2021). For patients with stage III-IV and recurrent vaginal sarcoma; pelvic exenteration may be an option for select patients, but ultimately management should continue on a case-by-case basis (Ciaravino et al., 2000). In our study, 2 patients with recurrent vaginal sarcoma received anterior pelvic exenteration and achieved a 137.5 and 25.6 months of progression-free interval, respectively.

Leiomyosarcomas are easily recurrent tumors with an unknown etiology and comprise <2 % of all malignant vaginal neoplasms (Suh and Park, 2008; Vizza et al., 2020). Treatment for vaginal leiomyosarcomas have not been determined. The overall 5-year survival rate was 43 %. Five-year survival for stage I and II tumors was 55 % and 44 %, respectively (Ciaravino et al., 2000). The very poor prognosis associated with this lesion emphasizes the critical need for early diagnosis and expeditious therapy (Ahram et al., 2006). The 5-year OS in our study was 66.7 % (stage I).

Rhabdomyosarcomas are the most common soft tissue cancers in children and adolescents, accounting for 4 %–6% of all malignancies in this age group (Adams et al., 2021). Since vaginal rhabdomyosarcomas is a rare entity, treatment is based on the case reports and series that have been collected over time. In our study, one patient with stage IV disease received systematic chemotherapy. The tumor showed a progressive growth, and the patient died 10 months after diagnosis. The other one with stage III disease, received two local wide excision surgeries, and was alive without disease at 29.5 months after diagnosis.

Ewing sarcoma (ES) and primitive neuroectodermal tumor (PNET) are round-cell sarcomas with varying degrees of neuroectodermal differentiation; they are considered members of the same family of tumors based on their common genetic profile (Bancalari et al., 2012; Liao et al., 2004). The patient in our study with stage I disease died of local recurrence after 19.7 months of treatment. The other one with stage IV disease, received anthracycline-based chemotherapy, pelvic external radiotherapy, and brachytherapy plus cisplatin-based chemotherapy, and was alive without disease at 26.7 months after diagnosis. A larger number of cases is necessary to draw any firm conclusions.

There are three limitations to our study. Because of the rarity of vaginal sarcoma, the sample size of our study was small. The current study was retrospective, and the treatment was not assigned at randomized. Because the primary surgery of some patients was performed outside of our hospital, there were differences in surgical techniques. Therefore, caution is required when interpreting our results. A prospective large study is warranted to validate these findings.

## 5. Conclusion

Primary vaginal sarcomas are aggressive neoplasms with different presenting characteristics. Surgery is the main treatment for primary vaginal sarcoma and for local relapse vaginal sarcoma.

Funding.

None.

Author contribution.

Hua Yuan and Tonghui Wang conceived the present idea and

supervised the findings of this work. Hua Yuan developed the theory and performed the statistical analysis. Hua Yuan wrote the manuscript. Hua Yuan and Tonghui Wang contributed to the data preparations. Hua Yuan and Tonghui Wang contributed to sample collection. All authors discussed the results and contributed to the final manuscript.

## Declaration of Competing Interest

The authors declare that they have no known competing financial interests or personal relationships that could have appeared to influence the work reported in this paper.

## References

- Adams, T.S., Rogers, L.J., Cuello, M.A., 2021. Cancer of the vagina: 2021 update. *Int. J. Gynaecol. Obstet.* 155 (Suppl 1), 19–27. <https://doi.org/10.1002/ijgo.13867>.
- Ahram, J., Lemus, R., Schiavello, H.J., 2006. Leiomyosarcoma of the vagina: case report and literature review. *Int. J. Gynecol. Cancer.* 16, 884–891. <https://doi.org/10.1111/j.1525-1438.2006.00487.x>.
- Anderson, M.L., Bodurka, D.C., 2008. Thoracotomy for the management of recurrent vaginal leiomyosarcoma. *Int. J. Gynecol. Cancer.* 18, 188–190. <https://doi.org/10.1111/j.1525-1438.2007.00984.x>.
- Bancalari, E., de Álava, E., Tardío, J.C., 2012. Primary vaginal Ewing sarcoma: case report and review of the literature. *Int. J. Surg. Pathol.* 20, 305–310. <https://doi.org/10.1177/1066896911424898>.
- Chiantera, V., Rossi, M., De Iaco, P., Koehler, C., Marnitz, S., Fagotti, A., Fanfani, F., Parazzini, F., Schiavina, R., Scambia, G., Schneider, A., Vercellino, G.F., 2014. Morbidity after pelvic exenteration for gynecological malignancies: a retrospective multicentric study of 230 patients. *Int. J. Gynecol. Cancer.* 24, 156–164. <https://doi.org/10.1097/IGC.0000000000000011>.
- Ciaravino, G., Kapp, D.S., Vela, A.M., Fulton, R.S., Lum, B.L., Teng, N.N.H., Roberts, J.A., 2000. Primary leiomyosarcoma of the vagina. A case report and literature review. *Int. J. Gynecol. Cancer.* 10, 340–347. <https://doi.org/10.1046/j.1525-1438.2000.010004340.x>.
- Ghezelayagh, T., Rauh-Hain, J.A., Growdon, W.B., 2015. Comparing mortality of vaginal sarcoma, squamous cell carcinoma, and adenocarcinoma in the surveillance, epidemiology, and end results database. *Obstet. Gynecol.* 125, 1353–1361. <https://doi.org/10.1097/AOG.0000000000000861>.
- Horn, L.C., Fischer, U., Reuter, S., Pyttel, C., 1998. Leiomyosarcoma and leiomyoma of the vagina. *Zentralbl Gynakol.* 120, 38–41.
- Khosla, D., Patel, F.D., Kumar, R., Gowda, K.K., Nijhawan, R., Sharma, S.C., 2014. Leiomyosarcoma of the vagina: A rare entity with comprehensive review of the literature. *Int. J. Appl. Basic Med. Res.* 4, 128–130. <https://doi.org/10.4103/2229-516X.136806>.
- Liao, X., Xin, X., Lü, X., 2004. Primary Ewing's sarcoma-primitive neuroectodermal tumor of the vagina. *Gynecol. Oncol.* 92, 684–688. <https://doi.org/10.1016/j.ygyno.2003.10.051>.
- Magné, N., Pacaut, C., Auberdiac, P., Jacquin, J.-P., Chargari, C., Chaleur, C., Haie Meder, C., Merrouche, Y., 2011. Sarcoma of vulva, vagina and ovary. *Best Pract. Res. Clin. Obstet. Gynaecol.* 25, 797–801. <https://doi.org/10.1016/j.bpobgyn.2011.07.001>.
- Matsuo, K., Eno, M.L., Im, D.D., Rosenshein, N.B., 2009. Pregnancy and genital sarcoma: a systematic review of the literature. *Am. J. Perinatol.* 26, 507–518. <https://doi.org/10.1055/s-0029-1215428>.
- Straubhar, A.M., Chi, A.J., Zhou, Q.C., Iasonos, A., Filippova, O.T., Leitao, M.M., Awowole, I.O., Abu-Rustum, N.R., Broach, V.A., Jewell, E.L., Sandhu, J.S., Sonoda, Y., 2021. Pelvic exenteration for recurrent or persistent gynecologic malignancies: Clinical and histopathologic factors predicting recurrence and survival in a modern cohort. *Gynecol. Oncol.* 163 (2), 294–298.
- Suh, M.J., Park, D.C., 2008. Leiomyosarcoma of the vagina: a case report and review from the literature. *J. Gynecol. Oncol.* 19, 261–264. <https://doi.org/10.3802/jgo.2008.19.4.261>.
- Sung, H., Ferlay, J., Siegel, R.L., Laversanne, M., Soerjomataram, I., Jemal, A., Bray, F., 2021. GLOBOCAN Estimates of Incidence and Mortality Worldwide for 36 Cancers in 185 Countries. *CA Cancer J. Clin.* 71 (3), 209–249.
- Vizza, E., Petrozza, V., Porta, N., Certelli, C., Battaglione, E., Corrado, G., Familiari, G., Heyn, R., 2020. Primary vaginal leiomyosarcoma: A case report with complete morphological, immunohistochemical and ultrastructural study. *Taiwan J. Obstet. Gynecol.* 59, 314–317. <https://doi.org/10.1016/j.tjog.2020.01.023>.
- Wang, Y., Huang, Y.-W., Li, Y.-F., 2015. Primary vaginal sarcoma: Experience of a regional cancer center in China. *J. Obstet. Gynaecol. Res.* 41, 1463–1468. <https://doi.org/10.1111/jog.12746>.