

Case Report

Hemifacial spasm due to vertebral artery dissecting aneurysm treated with stent-in-stent placement; Pre- and post-treatment evaluation by 3D multifusion imaging using silent MR angiography

Toru Satoh¹, Yu Sato², Kenji Sugiu², Tomohito Hishikawa², Masafumi Hiramatsu², Jun Haruma², Isao Date²

¹Department of Neurological Surgery, Ryofukai Satoh Neurosurgical Hospital, Fukuyama, ²Department of Neurological Surgery, Okayama University Graduate School of Medicine, Okayama, Japan.

E-mail: *Toru Satoh - ucsfbtrc@urban.ne.jp; Yu Sato - satouuyuuu@gmail.com; Kenji Sugiu - ksugiu@md.okayama-u.ac.jp; Tomohito Hishikawa - t-hishi@md.okayama-u.ac.jp; Masafumi Hiramatsu - mhiramatsu@okayama-u.ac.jp; Jun Haruma - j.haruma619@okayama-u.ac.jp; Isao Date - idate333@md.okayama-u.ac.jp



*Corresponding author:

Toru Satoh,
Department of Neurological
Surgery, Ryofukai Satoh
Neurosurgical Hospital,
Fukuyama, Japan.

ucsfbtrc@urban.ne.jp

Received : 14 March 2022

Accepted : 07 May 2022

Published : 03 June 2022

DOI

10.25259/SNI_253_2022

Quick Response Code:



ABSTRACT

Background: Hemifacial spasm (HFS) due to vertebral artery (VA) dissecting aneurysm (VADA) is rare and endovascular treatment has been performed in selected cases.

Case Description: We encountered a case of HFS caused by VADA that was managed with endovascular stent placement and additional stent-in-stent placement. Therapeutic strategies and benefits based on pre- and post-treatment evaluation by 3D multifusion imaging using silent MRA were discussed.

Conclusion: This is the first case report of stent-in-stent placement in successful treatment of HFS caused by VADA, in which relief of neurovascular contact was demonstrated by multifusion imaging.

Keywords: Endovascular treatment, Hemifacial spasm, Multifusion imaging, Stent-in-stent, VA dissecting aneurysm

INTRODUCTION

The incidence of hemifacial spasm (HFS) due to vertebral artery (VA) dissecting aneurysm (VADA) is as low as 0.2–0.5%.^[1] Endovascular treatment has been reported in nine cases, including parent VA occlusion in six cases, coiling in two cases, and stent placement in one case.^[1–4] In this report, we describe a case of VADA in which HFS was completely eliminated by stent placement and additional stent-in-stent placement in the VA. Therapeutic strategies based on pretreatment 3D multifusion images of magnetic resonance (MR) angiography and MR cisternography and benefits of pre- and post-treatment 3D multifusion imaging using silent MR angiogram were discussed. This is the first case report of stent-in-stent placement in successful treatment of HFS caused by VADA, in which relief of neurovascular contact (NVC) was demonstrated by multifusion imaging.

This is an open-access article distributed under the terms of the Creative Commons Attribution-Non Commercial-Share Alike 4.0 License, which allows others to remix, transform, and build upon the work non-commercially, as long as the author is credited and the new creations are licensed under the identical terms.

©2022 Published by Scientific Scholar on behalf of Surgical Neurology International

CASE DESCRIPTION

A 50s female suffered from the left HFS in 2012 and visited a nearby hospital. She received Botox treatment, but it was not effective. In 2014, she was referred to our hospital and diagnosed bilateral fusiform type VADAs by computed tomographic angiography [Figures 1a and b]. Pretreatment 3D multifusion imaging of time-of-flight MR angiography and fast spin-echo MR cisternography was performed, which identified NVC at the root exit zone (RExZ) of the left facial nerve by the VADA [Figure 2]. In August 2015, the first endovascular treatment was performed through stent placement. Enterprise 2 VRD 4/30 was placed in the left VA [Figures 3a and b]. HFS was reduced in frequency and degree, although it did not disappear completely. In August 2016, the right VADA was successfully treated with a stent-assisted coil. At this time, the left VADA reduced size, but a small *de novo* aneurysm was observed at the proximal end of the stent [Figures 4a-c]. In July 2017, the second endovascular treatment was performed through stent-in-stent placement with coiling, because the *de novo* aneurysm had enlarged. LVIS-4.5/18 was placed stent-in-stent in the left VA, partially superimposed on the former Enterprise stent. Axiom PRIME 3/6 was used for coiling of the *de novo* aneurysm [Figures 5a and b]. The left VADA had shrunk and the running course of the parent VA was markedly changed. After the second treatment, posttreatment 3D multifusion imaging using silent MR angiography and MR cisternography was performed. Pre- and post-treatment 3D multifusion images confirmed the elimination of NVC. As a result, the HFS was cured completely without recurrence for 5 years.

DISCUSSION

Pretreatment image evaluation

HFS usually develops by NVC, in which the RExZ of the facial nerve is compressed by the responsible arteries

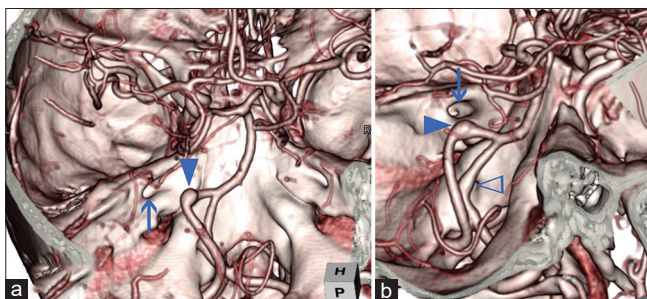


Figure 1: The initial CT angiography before the treatment showing bilateral fusiform type VADAs (a), and magnification (b). Arrowhead indicates left VADA, empty arrowhead right VADA, and arrow internal meatus. VADA: Vertebral artery dissecting aneurysm.

such as the posterior inferior cerebellar artery, anterior inferior cerebellar artery, or VA.^[6] To depict the anatomical relationship of NVC at RExZ, we performed 3D multifusion imaging of CT angiogram, MR angiogram, and MR cisternogram before the treatment.^[6] Through microvascular decompression surgery, NVC is eliminated by displacement of the responsible arteries at the RExZ. In this case, the pretreatment 3D multifusion images revealed that RExZ was directly compressed by VADA. Based on the image evaluation, direct surgery with MVD was judged to be risky, and endovascular treatment was selected.

Endovascular treatment strategy for VADA causing HFS

Recently, endovascular treatments for VA aneurysm, such as aneurysmal coiling, internal trapping, stent-assisted coiling, and stent-in-stents, have been widely performed.^[1-4,7,9] In this case, occlusion of the left dominant VA is not desirable because it may increase the blood flow load on the contralateral right VADA. Therefore, we established a treatment strategy comprising stent placement in the VA, aiming to release NVC by straighten VA and reduce the inflow blood to facilitate intra-aneurysmal thrombosis. At the first treatment, an enterprise stent was placed in the VA, resulting in straightening of VA and reduction of aneurysm. Although HFS was reduced in frequency and degree, it persisted. In the second treatment, the LVIS stent was placed stent-in-stent in the VA by superimposition, and the *de novo* aneurysm was coiled. As a result, the HFS disappeared completely.

Posttreatment image evaluation

Digital angiography has been performed for image evaluation after endovascular treatment of cerebral aneurysms with coils and stents. However, it is an invasive examination that involves risks such as procedural problems, side effects of iodine contrast media, and exposure to ionizing radiation. Therefore, time-of-flight MR angiography, with or without a contrast medium, is widely used as a noninvasive examination for long-term follow-up.^[5]

In time-of-flight MR angiography, the vessel image is obtained by the flow void due to the maximum blood flow velocity during systole. The offending artery is depicted as the MR signal intensity due to the inflow effect of blood protons passing through the blood vessel. However, in the vicinity of the coils and stents, it is difficult to depict the morphology of the neck and parent arteries in detail because of the magnetic susceptibility artifact of the metal.^[5,8]

Alternatively, silent MR angiography is a noncontrast and silent sound examination that uses an ultrashort TE (0.016 ms) with an artificial spin-labeling imaging sequence.^[5,8] A long RF inversion pulse was applied at a high level in the common carotid arteries. Data were collected over the entire brain by a

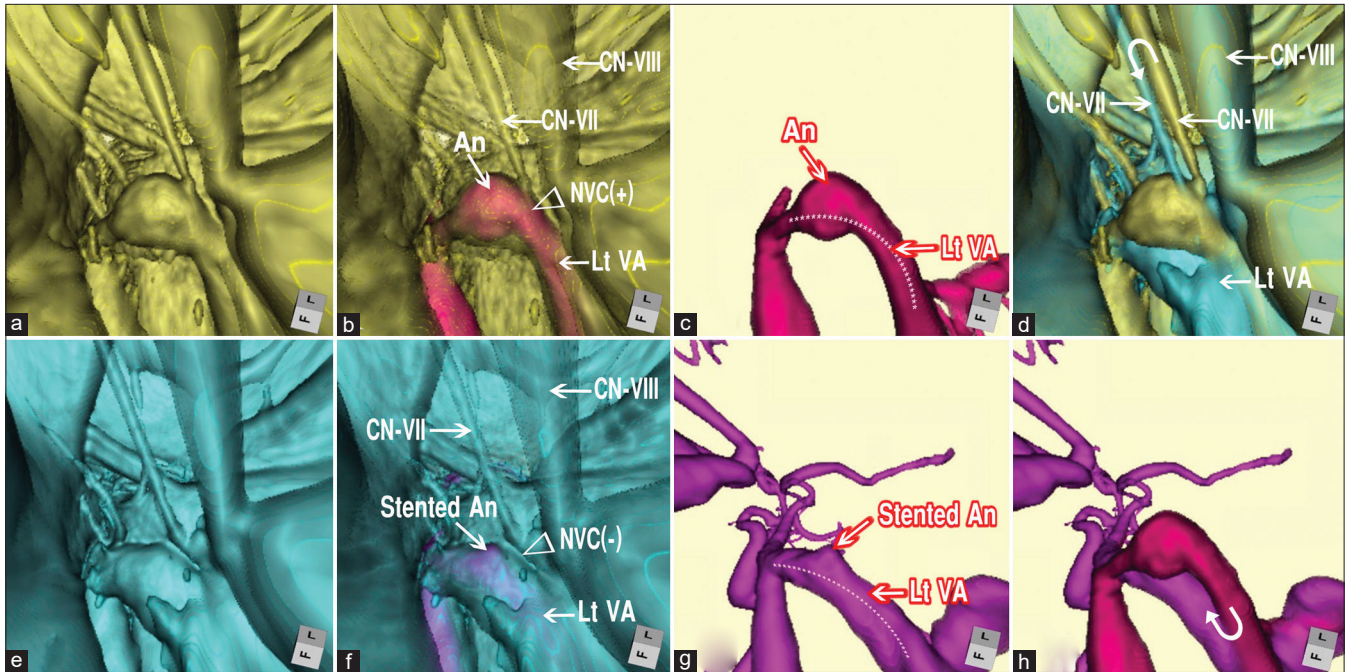


Figure 2: Pre- and post-treatment 3D multifusion images of HFS due to VADA. (a) Pretreatment 3D FSE MR cisternogram showing the NVC at the RExZ. The left facial nerve was directly compressed by the VADA. (b) Pretreatment 3D multifusion image of the time-of-flight MR angiography and fast spin-echo MR cisternography, same viewpoint as a. Arrowhead indicates the NVC. Arrows indicate CN-VII (facial nerve); CN-VIII, (vestibulocochlear nerve); VADA (An); VA. (c) Pretreatment 3D time-of-flight MR angiogram, same viewpoint as a, showing VADA. The dotted line indicates the running course of the left VA. (d) Pre- and post-treatment 3D multifusion image of the MR cisternogram, same viewpoint as a and e, showing the restoration form of the facial nerve after the second treatment through stent-in-stent placement. The curved arrow indicates the movement of the facial nerve. (e) Posttreatment 3D image of the MR cisternogram, same viewpoint as a, showing the elimination of NVC at the RExZ after the second treatment through stent-in-stent placement. (f) Posttreatment 3D multifusion image of silent MR angiogram and MR cisternogram, same viewpoint as a, showing the elimination of the NVC. (g) Posttreatment 3D silent MR angiogram, same viewpoint as a, showing the diminished size of the stented VADA. The dotted line indicates the running course of the left VA. (h) 3D multifusion images of (c) and (g). The curved arrow indicates the displacement of the left VA. HFS: Hemifacial spasm, MR: Magnetic resonance, VADA: Vertebral artery dissecting aneurysm, VA: VADA: Vertebral artery, RExZ: Root exit zone, NVC: Neurovascular contact.

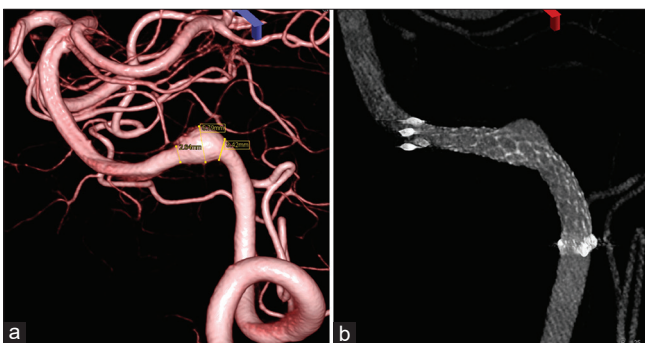

Figure 3: Digital angiography of the left VADA of the first endovascular treatment. (a) The left VADA before treatment. (b) Posttreatment with enterprise stent placement. VADA: Vertebral artery dissecting aneurysm.

3D radial scan until the excited blood spin reaches the crown as an endogenous tracer. By subtracting the data before and after excitation, information on the blood flowing through

the arterial lumen can be obtained as a T1-weighted image. Silent MR angiography is not easily affected by magnetic susceptibility artifacts, so the morphology of the aneurysmal neck and parent artery near metal objects is well visualized.

In this case, silent MR angiography was performed for image evaluation after stent treatment. Posttreatment 3D multifusion imaging with silent MR angiography and MR cisternography visualized the shrinkage of VADA and disappearance of NVC [Figure 2e-g].

Pre- and post-treatment image evaluation

The mechanism of endovascular treatment of VADA causing HFS has been considered to be because the coils and stents may reduce blood flow in the aneurysm and diminish arterial pulsation spread from the aneurysm wall over the facial nerve at the NVC site.^[1,4] In our case, however, we verified the running course of the VA including the aneurysm by

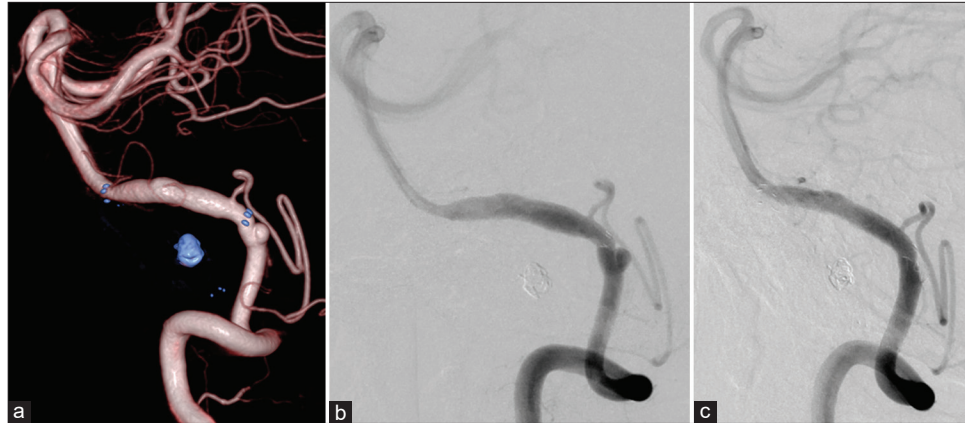

Figure 4: Digital angiography before the second treatment showing reduction of VADA, but appearance of a *de novo* aneurysm at the proximal end of the stent (a and b), after the second treatment using additional LVIS stent and coil (c). Note the running course of the parent VA was changed after the treatment. VADA: Vertebral artery dissecting aneurysm.

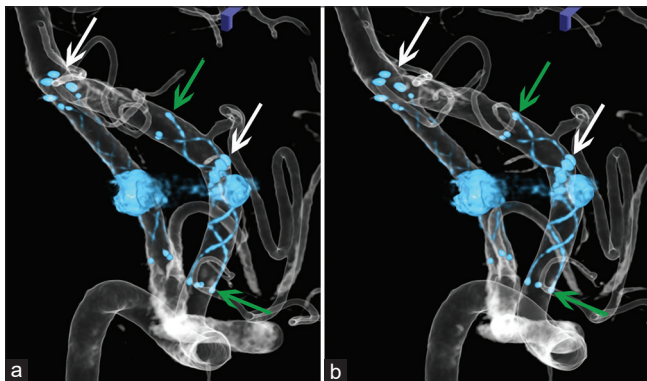


Figure 5: Stereotactic images (a and b) showing locations of two stents in the left VA after first and second treatments. White arrows indicate the proximal and distal ends of VRD (Enterprise 2 VRD 4/30) of the first treatment, and green arrows LVIS (additional stent-in-stent with LVIS-4.5/18) of the second treatment. VADA: Vertebral artery dissecting aneurysm.

superimposing the VA before and after stent placement [Figure 2h]. As a result, the size of the aneurysm was reduced; at the same time, the running course of VA was markedly changed. Yamashita *et al.* reported a case in which a microcatheter was inserted into the posterior inferior cerebellar artery for the functional diagnosis of HFS.^[10] HFS disappeared immediately after entry of the microcatheter and HFS was reproduced after its removal. Catheter insertion resulted in straightening and a change in the running course of artery flexion.

In our case, the initial stent placement and additional stent-in-stent placement reduced the size of the aneurysm. At the same time, the running pattern of the VA markedly changed, including VADA [Figure 2]. It was considered that the elimination of NVC in RExZ was obtained by the reduction in the size of the VADA and the change in the running course of the parent VA. As a result, the facial nerve was restored in

its form [Figure 2d] without NVC, and a complete cure of HFS was obtained.

CONCLUSION

In the strategy of endovascular treatment for HFS due to VADA, stent and stent-in-stent placement was useful for diminishing the size of VADA by intra-aneurysmal thrombosis and for changes in the running course of the parent VA. Both may result in the elimination of NVC and complete cure of HFS. Relief of NVC was demonstrated by posttreatment 3D multifusion imaging with silent MR angiography and MR cisternography.

Acknowledgments

We would like to thank Ms. Megumi Sasaki, Ms. Kana Murakami, and Mr. Yudai Abe of our hospital for conducting the MRI examination.

Declaration of patient consent

The authors certify that they have obtained all appropriate patient consent.

Financial support and sponsorship

Nil.

Conflicts of interest

There are no conflicts of interest.

REFERENCES

1. Arisawa K, Ochi T, Goto Y, Nanbu S, Shojima M, Maeda K. Coil embolization of VA-PICA aneurysm presenting with

- hemifacial spasm with assistance of abnormal muscle response monitoring. *J Neuroendovasc Ther* 2020;14:146-50.
2. Iida Y, Mori K, Kawahara Y, Fukui I, Abe K, Takeda M, *et al.* Hemifacial spasm caused by vertebral artery aneurysm treated by endovascular coil embolization. *Surg Neurol Int* 2020;11:431.
 3. Kugai M, Suyama T, Inui T, Yamazato K, Kitano M, Hasegawa H, *et al.* A case of vertebral artery aneurysm causing hemifacial spasm rapidly improved after parent artery occlusion. *J Neuroendovasc Ther* 2019;13:288-92.
 4. Santiago-Dieppa DR, McDonald MA, Brandel MG, Rennert RC, Khalessi AA, Olson SE. Endovascular flow diversion for hemifacial spasm induced by a vertebral artery aneurysm: First experience. *Oper Neurosurg (Hagerstown)* 2019;17: E115-8.
 5. Satoh T, Hishikawa T, Hiramatsu M, Sugiu K, Date I. Visualization of aneurysmal neck and dome after coiling with 3D multifusion imaging of silent MRA and FSE-MR cisternography. *AJNR Am J Neuroradiol* 2019;40:802-7.
 6. Satoh T, Onoda K, Date I. Fusion imaging of three-dimensional magnetic resonance cisternograms and angiograms for the assessment of microvascular decompression in patients with hemifacial spasms. *J Neurosurg* 2007;106:82-9.
 7. Sugiu K, Tokunaga K, Watanabe K, Sasahara W, Ono S, Tamiya T, *et al.* Emergent endovascular treatment of ruptured vertebral artery dissecting aneurysms. *Neuroradiology* 2005;14:158-64.
 8. Takano N, Suzuki M, Irie R, Yamamoto M, Hamasaki N, Kamagata K, *et al.* Usefulness of non-contrast-enhanced MR angiography using a silent scan for follow-up after Y-configuration stent-assisted coil embolization for basilar tip aneurysms. *AJNR Am J Neuroradiol* 2017;38:577-81.
 9. Wu X, Xu Y, Hong B, Zhao WY, Huang QH, Liu JM. Endovascular reconstruction for treatment of vertebrobasilar dolichoectasia. Long-term outcomes. *AJNR Am J Neuroradiol* 2013;34:583-8.
 10. Yamashita K, Hojo M, Okamoto S, Kim C, Nakatsu S, Nishima H. Possible role of neurointerventional techniques in the diagnosis of hemifacial spasm. *AJNR Am J Neuroradiol* 1997;18:287-90.

How to cite this article: Satoh S, Sato Y, Sugiu K, Hishikawa T, Hiramatsu M, Haruma J, *et al.* Hemifacial spasm due to vertebral artery dissecting aneurysm treated with stent-in-stent placement; Pre- and post-treatment evaluation by 3D multifusion imaging using silent MR angiography. *Surg Neurol Int* 2022;13:232.