


Bronchial Artery Chemoembolization With Radiopaque Doxorubicin Eluting Beads in Patients With Malignant Hemoptysis from Metastatic Lung Cancer

Technology in Cancer Research & Treatment
Volume 21: 1–7
© The Author(s) 2022
Article reuse guidelines:
sagepub.com/journals-permissions
DOI: 10.1177/15330338221131167
journals.sagepub.com/home/tct


Nariman Nezami, MD^{1,2} , Christos Georgiades, MD, PhD³,
Kelvin K. Hong, MBBCh, MBBS³, and Ji Buethe, MD³

Abstract

Purpose: This pilot study was designed to assess the technical feasibility and safety of bronchial artery chemoembolization with radiopaque doxorubicin eluting beads (DEB-BACE) in patients with malignant hemoptysis from pulmonary metastasis. **Materials & Methods:** Four patients underwent DEB-BACE using 70-150 μ m radiopaque DEB (LC Beads LUMI, Boston Scientific). Beads delivery and deposition were assessed under fluoroscopy and cone beam computed tomography (CT), respectively. **Results:** All 4 procedures were technically successful. Beads delivery and deposition were successfully visualized under fluoroscopy and cone beam CT guidance in all cases. Hemoptysis was resolved after embolization in all 4 patients. There were no adverse events or immediate or early complications after DEB-BACE. Two patients (50%) required repeat DEB-BACE within 1 week due to recurrent hemoptysis, and 1 patient had DEB-BACE 1.5 years later due to recurrent hemoptysis from the contralateral lung. All targeted lesions decreased in size in follow-up studies (mean 16 months, range 1-33 months). One patient died of progressive cancer disease invading the heart 1 month after DEB-BACE. **Conclusions:** DEB-BACE using radiopaque LC Beads LUMI loaded with doxorubicin is technically feasible and safe for controlling hemoptysis and cancer progression in patients with metastatic lung tumors. Visualization of beads delivery under fluoroscopy and deposition of beads under cone beam CT facilitate delivery of beads and embolization of bronchial arteries.

Keywords

lung, metastasis, bronchial artery embolization, radiopaque, drug-eluting beads, LC beads LUMI

Abbreviations

DEB-BACE, bronchial artery chemoembolization with radiopaque doxorubicin eluting beads; BACE, bronchial arterial chemoembolization; CT, computed tomography; CTA, CT angiogram; PFS, progression-free survival; OS, overall survival; DSA, digital subtraction angiogram; HCC, hepatocellular carcinoma; IRB, Institutional Review Board; PVA, polyvinyl alcohol; cTACE, conventional transarterial chemoembolization; NSCLC, nonsmall cell lung cancer.

Received: July 4, 2022; Revised: September 4, 2022; Accepted: September 11, 2022.

Introduction

Lung-directed therapies, such as bronchial arterial chemoembolization (BACE), are gaining attention and popularity as a treatment option for patients with primary or metastatic lung cancers who do not qualify for standard treatments.^{1–3} The lungs and supporting structures are supplied by 2 main blood resources, bronchial and pulmonary arteries. The bronchial arteries are heavily recruited by primary and metastatic tumors to provide additional blood supply for the tumoral cells.^{4,5} Due to the arterial nature of bronchial arterial supply, angiogenic growth factors such as vascular endothelial growth factors are

¹ Division of Vascular and Interventional Radiology, Department of Diagnostic Radiology and Nuclear Medicine, University of Maryland School of Medicine, Baltimore, MD, USA

² Experimental Therapeutics Program, University of Maryland Marlene and Stewart Greenebaum Comprehensive Cancer Center, Baltimore, MD, USA

³ Division of Vascular and Interventional Radiology, Department of Radiology and Radiological Sciences, the Johns Hopkins Hospital, Baltimore, MD, USA

Corresponding Author:

Ji Buethe, MD, Division of Vascular and Interventional Radiology, Department of Radiology and Radiological Sciences, Johns Hopkins Hospital, 1800 Orleans, Suite 7203, Baltimore, MD 21287, USA.

Email: jbuethel@jhmi.edu



postulated to promote collateral supply and neovascularity, causing proliferation and expansion of these arteries.⁵ This can offer a particular benefit in patients with advanced primary or metastatic lung cancers presenting with hemoptysis.⁶ Traditionally, embolic beads are utilized to control bleeding in patients presenting with hemoptysis.⁷ BACE with radiopaque doxorubicin eluting beads (DEB-BACE) could not only embolize the tumor-feeding artery and control hemoptysis, but also act as a vehicle for slow-release delivery of anti-neoplastic drugs to tumors and the local environment.⁸

LC Beads LUMI (Boston Scientific) offer radiopacity which makes them traceable.⁹ No study has yet reported the application of radiopaque LC Beads LUMI in patients with metastatic lung lesions. This small pilot study aimed to evaluate the technical feasibility and safety of DEB-BACE using radiopaque drug-eluting beads loaded with doxorubicin for the treatment of metastatic lung lesions presenting with hemoptysis.

Materials and Methods

Study Design and Population

This was a Health Insurance Portability and Accountability Act-compliant retrospective analysis of 4 patients with metastatic lung lesions who presented with massive hemoptysis (>300 mL in 24 h) to the Johns Hopkins Hospital from February 2017 to April 2020. This small pilot study relied on institutional innovation technical consent; therefore, Institutional Review Board (IRB) approval was waived by the Johns Hopkins School of Medicine's IRB committee (Baltimore, Maryland, USA). All patients had lung metastases presenting with active hemoptysis and were referred to interventional radiology for BAE. After a multidisciplinary discussion with pulmonology, oncology, and thoracic surgery, the decision was made to pursue DEB-BACE with DEB to address hemoptysis and provide palliative therapy.

Bronchial Artery Angiography Technique

Ultrasound-guided right common femoral artery access was obtained using a micropuncture set, then exchanged to a 5 French vascular sheath. The bronchial arteries, depending on the anatomy, were selected using a 5 French Mikaelson, Cobra 1, or glide Simmons 1 catheters. A digital subtraction angiogram was performed for identifying possible bronchial artery to pulmonary artery/vein shunt. The targeted bronchial arteries were distally subselected with a Renegade HI-FLO microcatheter (Boston Scientific) and 0.016 Fathom microwire (Boston Scientific). A subselective angiogram was performed to locate the bronchial artery which gave rise to tumor-supplying arteries in both right and left lungs. Before administering any particles, selective magnified arteriograms of the bronchial artery were performed to exclude the presence of spinal arteries or bronchial artery to pulmonary artery/vein shunt. Multiple phase cone beam computed tomography (CT) was then performed in noncontrast, arterial, and venous phases. After confirming the area of perfusion from this vessel, DEB-BACE

was done by infusing 1 mL of 70-150 μ m LC Bead LUMI (Boston Scientific) loaded with 50 mg of doxorubicin diluted with 40 mL of Visipaque 320 contrast medium (GE Healthcare). The median delivered dose with 100% dilution was 0.40 mL and 1.45 mL with 50% dilution. The embolization effect was confirmed with spot films and gentle hand contrast injection, with complete stasis observed in the distal vessels. The microcatheter was then withdrawn during aspiration to avoid nontarget embolization.

Preprocedural and Follow-up Imaging

Pretreatment chest CT angiogram (CTA) was routinely performed in all patients presenting with hemoptysis for localization of active hemorrhage and to see the disease progression using a 64 multidetector row CT scanner (Siemens). A chest CT without intravenous contrast was performed within 24 h after DEB-BACE to assess bead deposition.

Variables and Definition of Technical and Clinical Success Parameters

Patients' demographic data, past medical history, vital signs, imaging, and laboratory variables were collected. Pre- and postprocedural symptoms, stability, and CT angiographic findings were documented. Patient outcomes, including major, immediate, or early procedure-related complications and bleeding events were recorded.

Technical success was defined as successful catheterization of bronchial arteries and delivery of the embolic beads loaded with doxorubicin to a complete stasis. Beads delivery and deposition were assessed under fluoroscopy and cone beam CT, respectively, by an interventional radiologist with 11 years of clinical experience. Clinical success was defined as resolution of hemoptysis.

The target lesion's response to the DEB-BACE was evaluated using RECIST 1.1.¹⁰

Results

Four patients underwent a total of 7 DEB-BACE using doxorubicin-loaded LC Beads LUMI. The demographic characteristics of the studied patients are presented in Table 1. One patient had alveolar soft tissue sarcoma, 1 patient had intimal sarcoma of the right pulmonary artery, 1 patient had metastatic angiosarcoma, and 1 patient had metastatic hepatocellular carcinoma (HCC). Mean patient age was 67.4 ± 18.6 years; male to female ratio was 2:2. All patients received pre- and postembolization chest CT showing bilateral metastatic lung lesions. The target lesion's response to the DEB-BACE response is based on tumor response using RECIST 1.1 in Table 1. Except for 1 target lesion with stable disease, the rest of the lesions showed partial response to the DEB-BACE.

The mean number of DEB-BACE was 1.5 (range 1-2); 2 patients had repeat bronchial artery angiogram and DEB-BACE of the contralateral bronchial artery within <1 week due to

Table 1. Demographic Characteristics of the Studied Patients

No.	Age	Gender	Underlying disease	Target lesion	Follow-up interval (months)	Target lesion preembolization size (cm)	Target lesion most recent size (cm)	Target lesion response (RECIST 1.1)	Most recent CT appearance of a target lesion
1	54	Male	Metastatic angiosarcoma	Right lung	6	3.75	2.40	Partial response	Necrotic tissue
2	80	Male	Metastatic hepatocellular carcinoma	Right lung	24	5.39	2.08	Partial response	Scar tissue
3	29	Female	Metastatic alveolar sarcoma	Left lung	25	3.54	1.1	Partial response	Scar tissue
4	71	Female	Pulmonary artery sarcoma	Right lung	4	3.40	2.61	Stable disease	Necrotic tissue
				Right lung	0.5	7.27		The patient passed away before the follow-up imaging appointment.	

Abbreviation: CT, computed tomography.

recurrent hemoptysis. Figure 1 shows pre-DEB-BACE, angiographic, and post-DEB-BACE images of a patient with bilateral metastatic lung lesions originating from HCC. One patient underwent a repeat DEB-BACE session after 18 months when presenting with hemoptysis arising from a new metastasis in the contralateral lung (Figure 2).

The technical success rate was 100%. Bronchial arteries were successfully catheterized and DEB-BACE was performed in all patients. Beads delivery and deposition were successfully visualized under fluoroscopy and cone beam CT guidance in all cases. The clinical success rate was also 100%, resulting in resolution of hemoptysis. The median follow-up interval was 15 months (range 0.5-24.0). The mean pretreatment size of the 4 target lesions was 4.02 ± 0.92 cm (range 3.40-5.39). The mean posttreatment target lesion size on the most recent follow-up CT scan was 1.99 ± 0.61 cm (range 1.10-2.41). All target lesions on follow-up imaging were decreased in size in three patients (mean decrease of 2.02 ± 1.06 cm, range 0.99-3.31, Table 1). The distribution of radiopaque beads was heterogeneous in all target lesions on the same or next day follow-up noncontrast CT. Target lesion distribution was also assessed in all patients (100%); however, beads were not evenly distributed inside the target lesion in all cases.

No patients experienced immediate or early complications. There was no report of adverse events. Only 1 patient died after 1 month from DEB-BACE due to clinical deterioration and progression of metastatic disease.

Discussion

This small pilot study demonstrates the technical feasibility of DEB-BACE using drug-eluting radiopaque beads (LC Beads LUMI) loaded with doxorubicin in patients with malignant hemoptysis. Beads delivery and deposition were successfully visualized under fluoroscopy and cone beam CT guidance in all cases. Furthermore, DEB-BACE is well-tolerated for immediate control of hemoptysis and favorable for short-term control of target tumor progression in patients with lung metastasis who are poor candidates for standard therapy due to medical comorbidities or local tumor progression post standard therapies. Radiopaque feather of the LC Beads LUMI allows us to immediately assess beads deposition and embolization success. Furthermore, the small size of beads, 70-150 μ m, was chosen since no significant systemic artery to pulmonary artery shunt is noticed on selective bronchial artery angiogram.

BAE is considered a first-line treatment for most massive hemoptysis patients suffering from diffuse interstitial lung disease or chronic granulomatous disease and less commonly for aneurysms, arteriovenous fistulae, and neoplasms ranging from small benign endobronchial lesions to large malignant tumors.¹¹ BAE is not only minimally invasive in actively bleeding patients with poor underlying pulmonary function, but also often preserves pulmonary function compared to surgical resection.¹¹

While bland BAE is routinely used to address symptoms of malignant hemoptysis, DEB-BACE with doxorubicin-loaded beads is utilized in this study to both address active hemorrhage

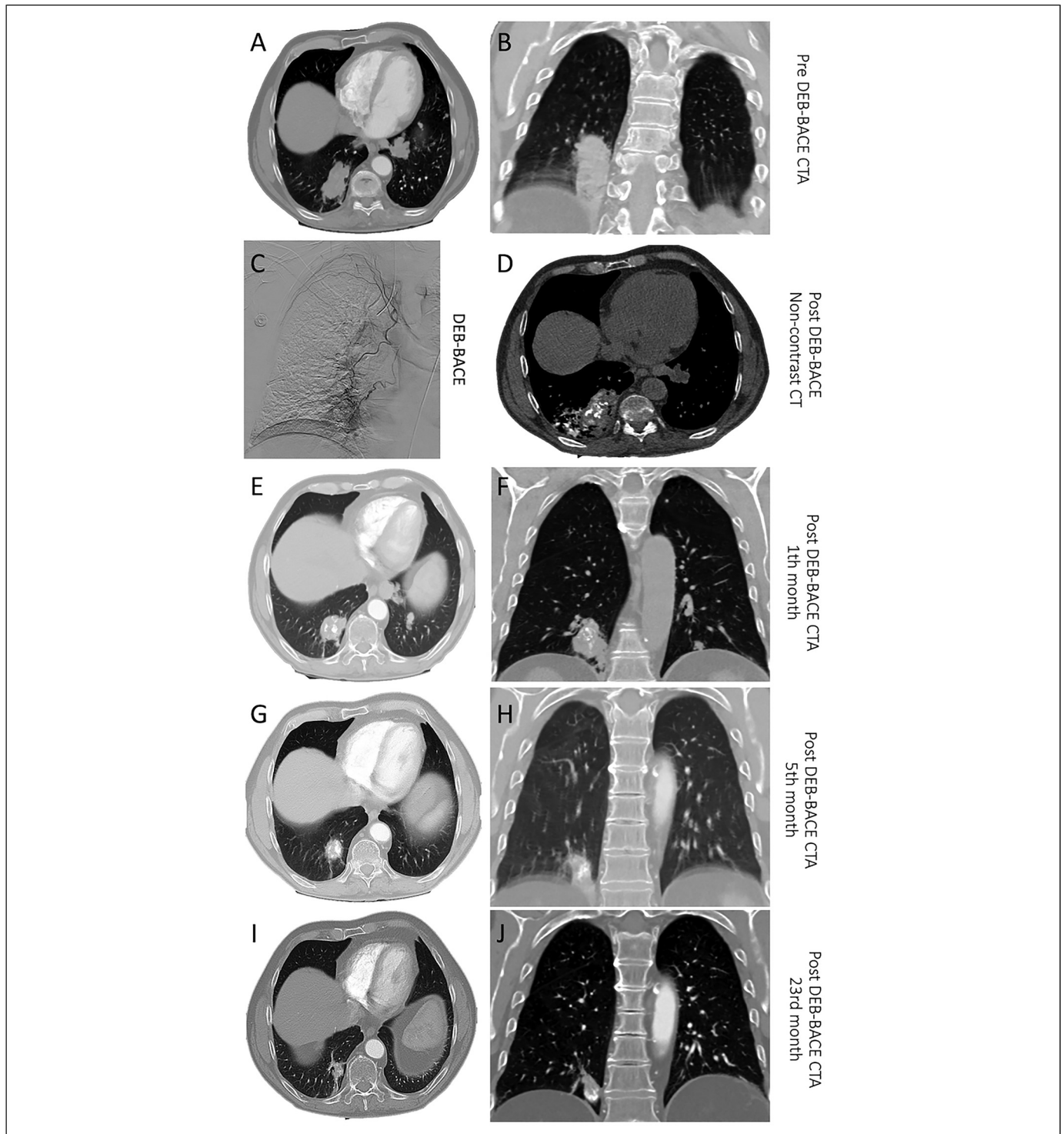


Figure 1. An 80-year-old male with hepatocellular carcinoma and metastatic lung lesions. (A) Axial chest CTA shows two large lesions in the bilateral lower lobes. (B) Coronal view of right lower lobe lesion. (C) DSA of the right bronchial artery shows significant tumor blush in the right lower lobe lesion. (D) Axial same-day noncontrast CT shows deposition of the radiopaque beads within the tumor post-DEB-BACE. (E, F) Axial and coronal chest CTA after 1 month shows an interval decrease in size of the metastatic lesion. (G, H) Axial and coronal chest after 5 months shows interval decrease in size of the tumor. (I, J) Axial and coronal chest CTA after 23 months shows a persistent interval decrease in the size of the metastatic lesion.

Abbreviations: CT, computed tomography; CTA, CT angiogram; DSA, digital subtraction angiogram; DEB-BACE, bronchial artery chemoembolization with radiopaque doxorubicin eluting beads.

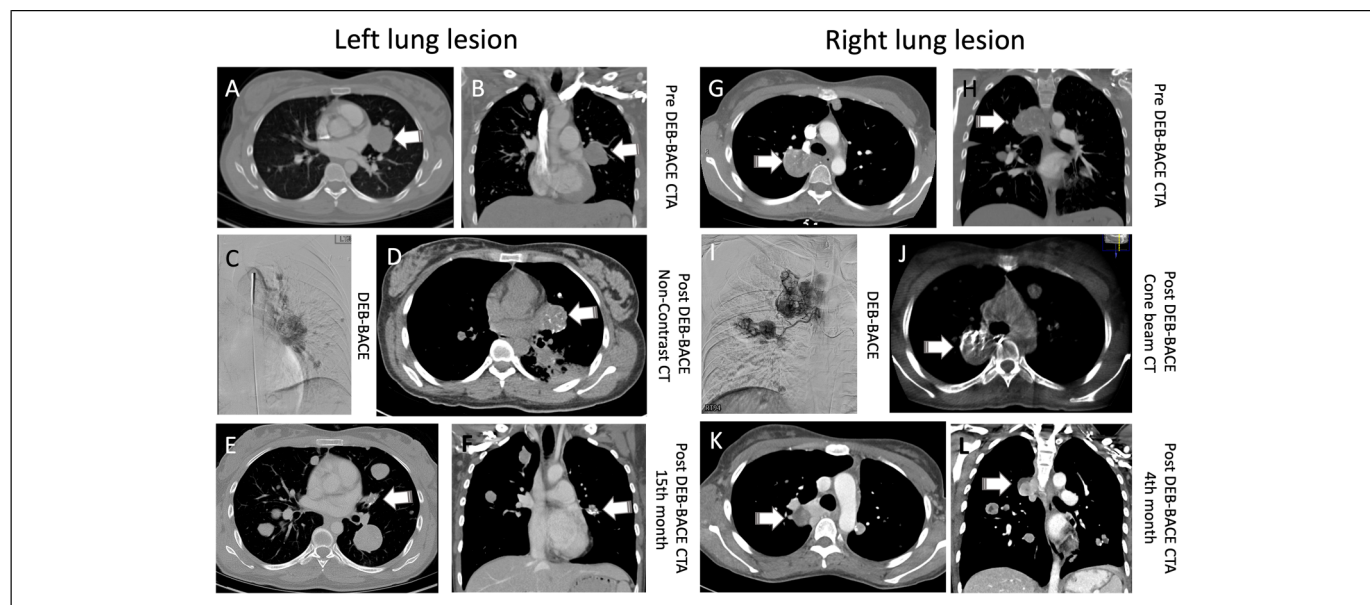


Figure 2. A 29-year-old female with metastatic alveolar sarcoma with cystic fibrosis. She presented with hemoptysis at 2 different timelines; first, her left lesion was embolized, then she presented with hemoptysis 18 months later, revealing a right-lung lesion. (A, B) Axial and coronal chest CTA demonstrates multiple metastatic lung lesions, with the largest lesion in the left lung at the time of presentation. (C) DSA of the left bronchial artery reveals a tumor blush in the left lung lesion. (D) Same-day noncontrast chest CT shows proper deposition of radiopaque beads in the left lung lesion. (E, F) Axial and coronal 15 months follow-up chest CTA show a significant decrease in the size of the left lung lesion. (G, H) Axial and coronal chest CTA demonstrates multiple metastatic lung lesions, now with the largest lesion in the right lung. (I) DSA of the right bronchial artery reveals a tumor blush in the right lung lesion. (J) Immediate in-room cone beam CT details the radiopaque beads in the right lung lesion. (K, L) Axial and coronal chest CTA after 4 months shows a significant decrease in the size of the right lung lesion. Abbreviations: CT, computed tomography; CTA, CT angiogram; DSA, digital subtraction angiogram.

and locally deliver chemotherapy to pulmonary metastases. Only a few case series or small sample size studies have shown the feasibility of DEB-BACE using different types of beads loaded with various antineoplastic agents in patients with primary or metastatic lung cancer.^{2,3,8} DEB-BACE can selectively deliver chemotherapy to the tumor, increase drug concentration locally, improve curative effect via the “first-pass effect,” and decrease adverse reactions of systemic chemotherapy.⁹

A retrospective study of DEB-BACE using superabsorbent polymer microspheres in unresectable pulmonary metastases from renal cell carcinoma showed objective response rates of 38.8%, 44.9%, and 38.8%, after 1, 3, and 6 months, respectively.² Another retrospective study of DEB-BACE using an infusion of superabsorbent polymer microspheres in patients with unresectable pulmonary or mediastinal breast cancer metastases showed a response rate and 5-year survival rate of 28.6% and 49.5%, respectively.³ Although, conventional transarterial chemoembolization (cTACE) with lipiodol may be associated with a reduced local antitumor drug concentration and increased systemic toxicity as chemotherapy may not reside long in the tumor tissues,¹² but the most recent phase I clinical trial of bronchial artery cTACE for unresectable metastatic lung disease showed successful result for the treatment of lung, mediastinal, and endobronchial metastases, with no severe adverse events.¹³ In another retrospective study, BAE was shown effective and safe option for the treatment of hemoptysis in patients with pulmonary metastasis from HCC.¹⁴ In this

study, verity embolics were utilized including polyvinyl alcohol (PVA) particles only in 6 patients, gel foam only in 5 patients, gel foam plus microcoils in 3 patients, PVA plus microcoils in 1 patient, embospheres, lipiodol plus PVA and gel foam, histoacryl with microballoon protection each in 1 patient. Retrospective analysis of 14 patients demonstrated that transarterial treatment with HepaSphere is a safe and effective treatment for patients with pulmonary or mediastinal metastases from HCC.¹⁵ Most recently, CalliSpheres[®] beads (Jiangsu Hengrui Medicine Co. Ltd) loaded with gemcitabine showed promising results in patients with nonsmall cell lung cancer (NSCLC).⁸

The role of DEB-BACE in prolonging progression-free or overall survival (OS) still remains controversial. DEB-BACE using CalliSphere in patients with small lungs resulted in median progression-free survival (PFS) and OS of 8.0 and 16.5 months, respectively. Additionally, the 6- and 12-month PFS rates after DEB-BACE with CalliSphere were 66.7% and 16.7%, and the 6- and 12-month OS rates were 100.0% and 66.7%, respectively.⁸ Studies have shown that adding other therapeutic options such as transarterial infusion, targeted therapy, and thermal ablation to DEB-BACE may improve the effect of BACE.¹⁶ Combining DEB-BACE with radioactive iodine-125 seed implantation in patients with stage III-IV NSCLC yielded higher local control and effective rate and longer PFS and OS time compared to BAE alone.¹⁷ Also combining DEB-BACE with radiofrequency improves the outcome

of the ablation.¹⁸ In a small sample size prospective study, the addition of DEB-BACE (50-100- μm HepaSphere [HepaSphere; BioSphere Medical] loaded with doxorubicin, irinotecan, or combination cisplatin and mitomycin-C) to radiofrequency ablation in patients with unresectable lung cancer resulted in 65% complete response.¹⁸ In another retrospective study of 63 patients with NSCLC, combining radiofrequency ablation and DEB-BACE was associated with a significantly higher short-term effective rate (93.0%), and 1-, 2-, and 3-year OS rates of 90.7%, 58.1%, and 20.9%, respectively.¹⁹ In general, larger lesion size and more prior treatments including chemotherapy and radiotherapy may predict poor therapeutic response to DEB-BACE, while more sessions of DEB-BACE may predict better disease control.⁸

LC Bead LUMI™ delivery was successfully visualized under fluoroscopy and deposition in the target area was assured by cone beam CT in all cases. The core chemistry of LC Bead LUMI™ used in this pilot study is the same as LC Bead™. This type of bead is also loaded based on ion exchange between sulfonic acid groups on the polymer and the positively charged amine groups of the chemotherapy agents. Doxorubicin elution kinetics for all bead sizes evaluated were within the parameters already investigated within the clinic for LC Bead™. The radiopacity of beads does not affect the drug loading capacity of the beads, and there is a direct linear correlation between the LC bead LUMI attenuation and loaded doxorubicin concentration. The ability to visualize doxorubicin-loaded LC Bead LUMI™ was demonstrated before by transhepatic delivery in a VX2 tumor-bearing rabbit model under fluoroscopy, followed by CT imaging.⁹

DEB-BACE using doxorubicin-loaded LC Beads LUMI was not associated with serious adverse events, in line with prior case reports or similar case series. Particles >300 μm are commonly used for bronchial artery embolization, since the size of bronchopulmonary shunts is about 250 μm . However, we safely utilized the largest size of LC Beads LUMI, 70-150 μm , which are the only radiopaque beads available on the US market for brachial artery embolization. Studies have also shown that the size of LC Beads LUMI changes once loaded with doxorubicin.²⁰ Additionally, hemoptysis in patients with metastatic lung disease originates from tumor vascularity which is different in nature compared to other diseases' bronchopulmonary shunts.²¹

Lack of post-embolization syndrome including fatigue, nausea and vomiting, dyspnea, and insomnia after DEB-BACE with LC Beads LUMI is likely related to the lesser systemic effect.²² Furthermore, prior studies have shown that BAE could improve performance status, global quality of life, physical functioning, and emotional functioning.^{3,8} Two of the patients in our study required repeat DEB-BACE of the contralateral bronchial artery due to recurrent hemoptysis. Recurrent hemoptysis after BAE has been reported in patients with metastatic lung disease in prior studies.¹⁴ DEB-BACE of bilateral bronchial arteries could avoid repeat BAE, if a decision was made to perform BAE for massive hemoptysis in a setting of metastatic lung disease.

Limitations of this pilot study include small sample size and a lack of longitudinal outcome. A feature study with a larger

population and longer study period is needed to fully assess the effect of DEB-BACE on PFS and OS in patients with metastatic lung disease.

Since neither DEB-BACE nor systematic chemoradiation therapies reach 100% complete response, new and more efficient treatment approaches are needed to further improve current treatment outcomes. A combination of different locoregional and systemic therapies has been successfully tried to address cancers in other organs such liver or kidney, resulting in increased response rates and OS benefits.²³ Further clinical trials could explore DEB-BACE combined with immunotherapies.

In conclusion, DEB-BACE with doxorubicin using radiopaque beads was technically feasible and safe in controlling hemoptysis in patients with metastatic lung cancer, while allowing immediate assessment of beads delivery, deposition, and embolization. This small pilot study also demonstrated a promising response of metastatic lung tumors to DEB-BACE, which should be validated by a clinical trial.


Declaration of Conflicting Interests

The author(s) declared no potential conflicts of interest with respect to the research, authorship, and/or publication of this article.

Funding

The author(s) received no financial support for the research, authorship, and/or publication of this article.

ORCID iD

Nariman Nezami  <https://orcid.org/0000-0002-8829-1548>

Supplemental Material

Supplemental material for this article is available online.

References

1. Abtin F, De Baere T, Dupuy DE, Genshaft S, Healey T, Khan S, et al. Updates on current role and practice of lung ablation. *J Thorac Imaging*. 2019;34(4):266-277.
2. Seki A, Hori S, Sueyoshi S, Hori A, Kono M, Murata S, et al. Transcatheter arterial embolization with spherical embolic agent for pulmonary metastases from renal cell carcinoma. *Cardiovasc Intervent Radiol*. 2013;36(6):1527-1535.
3. Kennoki N, Hori S, Yuki T, Hori A. Transcatheter arterial chemoembolization with spherical embolic agent in patients with pulmonary or mediastinal metastases from breast cancer. *J Vasc Interv Radiol*. 2017;28(10):1386-1394.
4. Walker CM, Rosado-de-Christenson ML, Martínez-Jiménez S, Kunin JR, Wible BC. Bronchial arteries: anatomy, function, hypertrophy, and anomalies. *RadioGraphics*. 2015;35(1):32-49.
5. Eldridge L, Moldobaeva A, Zhong Q, Jenkins J, Snyder M, Brown RH, et al. Bronchial artery angiogenesis drives lung tumor growth. *Cancer Res*. 2016;76(20):5962-5969.
6. Yu G, Hu J. Drug-eluting beads bronchial arterial chemoembolization as a neoadjuvant treatment for squamous non-small cell lung cancer. *Postgrad Med*. 2020:1-4. doi:10.1080/00325481.2020.1761711

7. Wang GR, Ensor JE, Gupta S, Hicks ME, Tam AL. Bronchial artery embolization for the management of hemoptysis in oncology patients: utility and prognostic factors. *J Vasc Interv Radiol.* 2009;20(6):722-729.
8. Bie Z, Li Y, Li B, Wang D, Li L, Li X. The efficacy of drug-eluting beads bronchial arterial chemoembolization loaded with gemcitabine for treatment of non-small cell lung cancer. *Thorac Cancer.* 2019;10(9):1770-1778.
9. Ashrafi K, Tang Y, Britton H, Domenge O, Blino D, Bushby AJ, et al. Characterisation of a novel intrinsically radiopaque drug-eluting bead for image-guided therapy: DC bead LUMI™. *J Control Release.* 2017;250:36-47.
10. Eisenhauer EA, Therasse P, Bogaerts J, Schwartz LH, Sargent D, Ford R, et al. New response evaluation criteria in solid tumours: revised RECIST guideline (version 1.1). *Eur J Cancer.* 2009;45(2):228-247.
11. Lorenz J, Sheth D, Patel J. Bronchial artery embolization. *Semin Interv Radiol.* 2012;29(3):155-160.
12. Xie ZB, Wang XB, Peng YC, Zhu SL, Ma L, Xiang BD, et al. Systematic review comparing the safety and efficacy of conventional and drug-eluting bead transarterial chemoembolization for inoperable hepatocellular carcinoma. *Hepatol Res.* 2015;45(2):190-200.
13. Boas FE, Kemeny NE, Sofocleous CT, Yeh R, Thompson VR, Hsu M, et al. Bronchial or pulmonary artery chemoembolization for unresectable and unablatable lung metastases: a phase I clinical trial. *Radiology.* 2021;301(2):474-484.
14. Kim S, Kim JH, Ko GY, Gwon DI, Shin JH, Yoon HK. Bronchial artery embolization for hemoptysis caused by metastatic hepatocellular carcinoma. *Sci Rep.* 2022;12(1):6906.
15. Hori A, Ohira R, Nakamura T, Kimura Y, Ueda S, Torii M, et al. Transarterial chemoembolization for pulmonary or mediastinal metastases from hepatocellular carcinoma. *Br J Radiol.* 2020;93(1110):20190407.
16. Lewandowski RJ, Geschwind J-F, Liapi E, Salem R. Transcatheter intraarterial therapies: rationale and overview. *Radiology.* 2011;259(3):641-657.
17. Chen Y, Li Y, Jia Y, Lei K, Zhang X, Cao Y, et al. Bronchial artery chemoembolization combined with radioactive iodine-125 seed implantation in the treatment of advanced nonsmall cell lung cancer. *J Cancer Res Ther.* 2017;13(4):636-641.
18. Gadaleta CD, Solbiati L, Mattioli V, Rubini G, Fazio V, Goffredo V, et al. Unresectable lung malignancy: combination therapy with segmental pulmonary arterial chemoembolization with drug-eluting microspheres and radiofrequency ablation in 17 patients. *Radiology.* 2013;267(2):627-637.
19. Yang XG, Wu G, Li ZW, Wu H, Sun YY, Wen HH, et al. Efficacy for artery chemoembolization combined with radiofrequency ablation in the treatment of advanced non-small cell lung cancer. *Zhonghua Yi Xue Za Zhi.* 2016;96(7):539-543.
20. Caine M, Zhang X, Hill M, Guo W, Ashrafi K, Bascal Z, et al. Comparison of microsphere penetration with LC Bead LUMI™ versus other commercial microspheres. *J Mech Behav Biomed Mater.* 2018;78:46-55.
21. Gershman E, Guthrie R, Swiatek K, Shojaee S. Management of hemoptysis in patients with lung cancer. *Ann Transl Med.* 2019;7(15):358.
22. Wu B, Zhou J, Ling G, Zhu D, Long Q. Callispheres drug-eluting beads versus lipiodol transarterial chemoembolization in the treatment of hepatocellular carcinoma: a short-term efficacy and safety study. *World J Surg Oncol.* 2018;16(1):69.
23. Dendy MS, Ludwig JM, Stein SM, Kim HS. Locoregional therapy, immunotherapy and the combination in hepatocellular carcinoma: future directions. *Liver Cancer.* 2019;8(5):326-340.