



# Dynamic Anterior Stabilization Using Transosseous Bone Tunnel Technique With the Adjustable Loop Length Cortical Button Incorporating High-Strength Suture Augmentation for Recurrent Shoulder Instability

Ayyappan V. Nair, D.Ortho, D.N.B., M.N.A.M.S., Pramod Kumar Mohan, M.S. Ortho, Ajit Jangale, M.S., M.R.C.S., Vikas Kuntwad, D.N.B. Ortho, M. Praveen Kumar, M.S. Ortho, Naresh Goud, D.Ortho, D.N.B. Ortho, and Shekhar Sreekumar, M.B.B.S.

**Abstract:** Dynamic anterior stabilization using the long head of the biceps tendon is a recently described technique in the management of recurrent shoulder dislocation with subcritical bone loss. This technique involves the transfer of the long head of the biceps to the glenoid, providing sling and hammock effect. The long head of the biceps (LHB) tendon fixation can be accomplished with a variety of implants. We present a modified fixation technique of LHB tendon using transosseous bone tunnel with the adjustable loop length cortical button, incorporating high-strength suture augmentation device in a patient with recurrent glenohumeral instability with limited glenoid bone loss and an engaging Hill-Sachs defect in the humeral head.

## Introduction

**D**ynamic anterior stabilization (DAS) by transfer of long head of biceps tendon fills up the gap in treating the patients with recurrent shoulder instability with subcritical bone defects.<sup>1-4</sup> Dynamic anterior stabilization also provides the sling and hammock effect in preventing further instability.<sup>4</sup> This procedure was initially propagated by Collins et al. with a 2-year follow-up study showed good to excellent results in

shoulder instability management in the patient group having subcritical bone loss.<sup>1,5</sup> Since then, DAS has been a new choice in the armamentarium of shoulder surgeons in treating recurrent shoulder dislocation. There has been various modification in performing DAS by different surgeons from using interference screws to suture anchors in fixation of the long head of the biceps tendon to the glenoid neck, all having their share of advantages and disadvantages.<sup>1-3</sup> The indications and contraindications of dynamic anterior stabilization are listed in [Table 1](#). We demonstrate a modified technique in performing dynamic anterior stabilization with the long head of the biceps (LHB) tendon using a FiberTag TightRope (Arthrex) fixation device with transosseous glenoid tunnel for recurrent glenohumeral instability ([Video 1](#)).

## Surgical Technique (With Video illustration)

### Patient Positioning and Portal Placement

The patient is positioned in the beach chair position under general anaesthesia with an interscalene block. The arm is prepped and draped held by traction cable with the shoulder in 60° anterior elevation, 10° shoulder abduction, and neutral rotation.

Bangalore Shoulder Institute, Bangalore, India  
The authors report no conflicts of interest in the authorship and publication of this article. Full ICMJE author disclosure forms are available for this article online, as [supplementary material](#).

Received April 18, 2022; accepted July 14, 2022.

Address correspondence to Pramod Kumar Mohan, M.S., Bangalore Shoulder Institute, 40, 36th Cross, 23rd Main Road, 4th T Block East, Jayanagar, Bangalore, 560041, Karnataka, India. E-mail: [pramod.stanley@gmail.com](mailto:pramod.stanley@gmail.com)

© 2022 THE AUTHORS. Published by Elsevier Inc. on behalf of the Arthroscopy Association of North America. This is an open access article under the CC BY-NC-ND license (<http://creativecommons.org/licenses/by-nc-nd/4.0/>).

2212-6287/22539

<https://doi.org/10.1016/j.eats.2022.07.007>

## Portal Placement

### A Portal

The A portal is a standard posterior portal known as soft spot, 2 cm medial and inferior from posterolateral corner of the acromion (Fig 1).

### B Portal

The B portal is a lateral portal, made at the level of the midpoint of acromion 1-2 cm distal passing through the deltoid.

### E Portal

The E portal shows the rotator interval made with the outside-in technique just above the lateral half of subscapularis.

### D Portal

The D portal is located 2 cm inferior to anterolateral corner of acromion.

### J Portal

The J portal is the mid-axillary portal, usually used in arthroscopic Latarjet procedure.

## Diagnostic Arthroscopy With Labral Repair

Diagnostic arthroscopy is done with 4-mm, 30° arthroscope (Arthrex) introduced through the soft spot A portal. Anterior labral tear from 3 o'clock to 6 o'clock position with the engaging Hill-Sachs lesion of humeral head documented. Hill-Sachs lesion is addressed with Remplissage using two suture anchors (Stryker) (Fig 2). Bankart labral repair is done in standard manner using D and E portals with two PushLock (Arthrex) and one suture anchor (Arthrex) at 3, 4 and 6 o'clock positions on the glenoid rim, recreating the bumper effect of the glenoid labrum restoring the tension of capsulolabral tissue (Fig 3). Suture limbs are passed through the infraspinatus and the tightening of Remplissage sutures are done as the final step after LHB tendon fixation.

## LHB Tendon Release From Bicipital Groove and Tenotomy

The long head of biceps is secured with a cinch stitch with no. 2 Ethibond suture using a suture passer (Arthrex Scorpion suture passer) introduced through the E portal (Fig 4). The cinch stitch is tightened, and the suture limbs are pulled out through the E portal. Biceps tenotomy is performed with a radiofrequency ablator (Arthrocare) (Fig 5). The arthroscope is shifted to the lateral B portal and LHB tendon release from the bicipital tunnel is done by cutting the transverse humeral ligament laterally and distally to avoid injury to subscapularis insertion working from the anterolateral D portal (Fig 6).

**Table 1.** Indications and Contraindications of Dynamic Anterior Stabilization

Indications	
1)	Recurrent shoulder instability with glenoid bone loss up to 20%
2)	Severe labral soft tissue insufficiency, failed Bankart repair
3)	Young patients-overhead athletes and throwers associated with SLAP tear
4)	Contact athletes, professional athletes with ISIS scores $\geq 6$
Contraindications	
1)	Glenoid bone loss is more than 20%
2)	Associated with poor LHB tendon quality, spontaneous rupture of LHB
3)	Previous LHB tenodesis or tenotomy

LHB, long head of the biceps.

## LHB Tendon Preparation

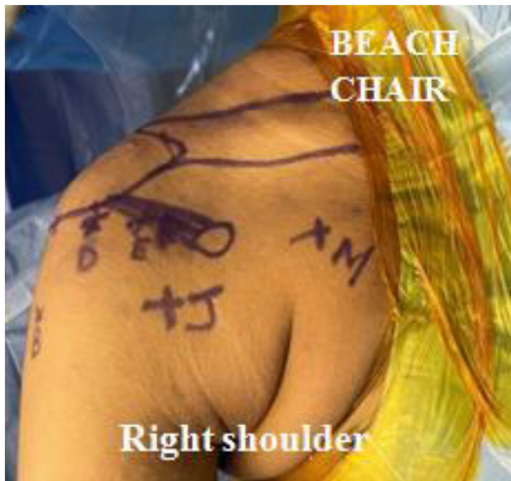The tenotomized end of the biceps is exteriorized through the D portal after the LHB release from the bicipital tunnel, and tendon preparation is done with Arthrex FiberTag TightRope, which facilitates the attachment of the single-ended graft to the Endobutton. LHB tendon end is secured with 4 needle passes through the FiberTag suture (2 up, over the TightRope implant (Arthrex), and 2 more passes down) in order to reinforce the prepared biceps tendon, the prepared LHB tendon is measured to be having 6-mm diameter (Fig 7).

## Subscapularis Split

The arthroscope is shifted to the D portal and a Wis-senger rod (walking stick) is passed from the A portal at the level of 3 o'clock position of the glenoid face and advanced until it pierces the subscapularis muscle belly. The subscapularis split is done usually at superior one-third and inferior two-third levels working from the J portal, the mid-axillary portal, and the split is completed.

## Glenoid Transosseous Tunnel Preparation

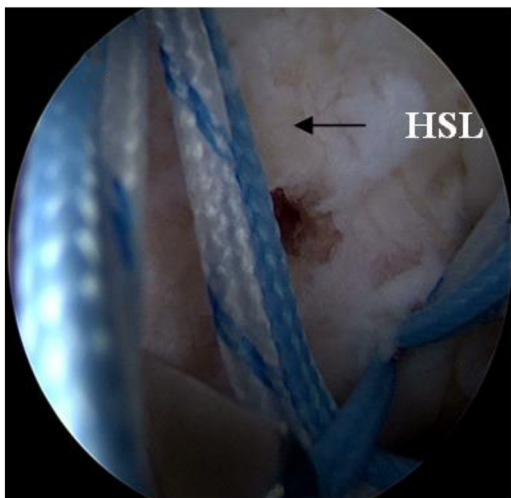
The glenoid transosseous tunnel is made working from the J portal visualizing from the D portal. A plastic transparent tissue-protective sleeve is introduced through the subscapularis split and held tight against the glenoid neck at 3 o'clock position. The transparent plastic sleeve is made from the protective plastic sheath of the used suture anchor, and the sleeve is cut at the level that is appropriate for drilling. The glenoid tunnel is drilled with a fluted drill bit, and the tunnel length is measured. The reaming of the tunnel is done with a 6-mm cannulated reamer for a length of 15 mm drilled over the drill bit (Fig 8). The drill bit is replaced with a shuttling FiberWire suture from the anterior to posterior direction, exiting from the posterior aspect of the shoulder.



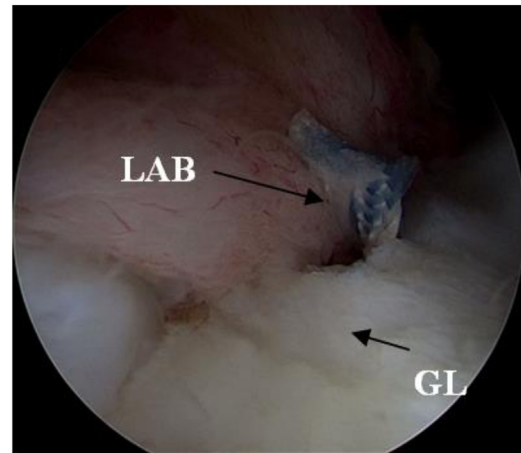
**Fig 1.** Patient is positioned in the beach chair position with arm held by traction cable with portals marked over the right shoulder.

**LHB Tendon Shuttling and Fixation**

The prepared LHB tendon with FiberTag TightRope (Arthrex) is shuttled through the subscapularis split and pulled out from the posterior aspect of the shoulder. The Endobutton of the tightrope is flipped and held firmly against the posterior glenoid neck and checked by giving traction to the tendon (Fig 9). The LHB tendon end is pulled 15 mm into the tunnel by pulling on the FiberTag TightRope (Arthrex), and all of the steps are visualized from the D portal, and the working portal is the J portal. After fixation, the sling effect of the biceps tendon is visualized in the prescapular space and intra-articularly.



**Fig 2.** Hill-Sachs defect (HSL) is visualized from posterior portal (A) and Remplissage done with two suture anchors through an accessory posterior portal.



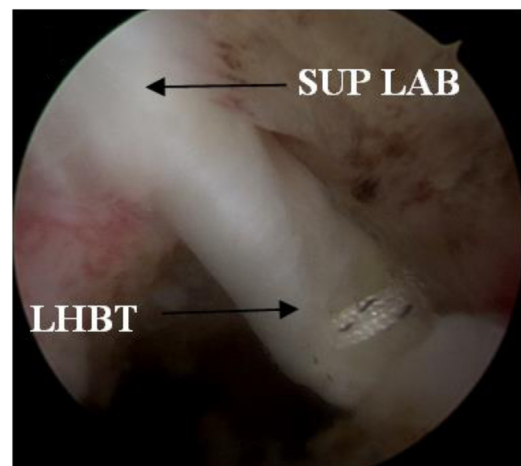
**Fig 3.** Bankart repair of anterior labral tear is done with two PushLock and one suture anchor viewing from Portal D and working from anterior portal E. The Labral tissue (LAB) is anchored at 3, 4, and 6 o' clock position in the glenoid.

**Remplissage of Hill-Sachs (Capsulotenodesis)**

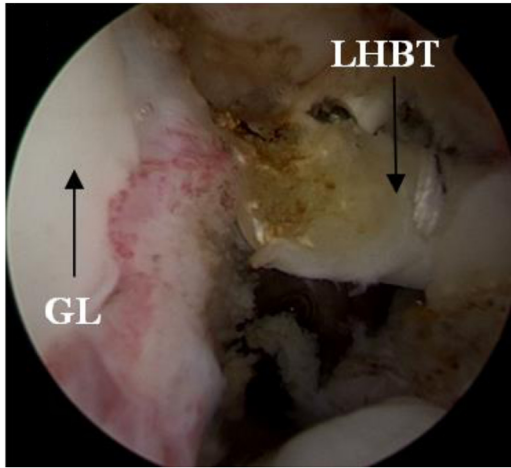The final tightening of the suture limbs is done as the final step from the posterior A portal and capsulotenodesis of Hill-Sachs is done.

**Final Arthroscopic Evaluation**

The final arthroscopic evaluation is done from the D portal, visualizing the LHB tendon in front and back of the subscapularis demonstrating the sling effect of the tendon over the subscapularis and sturdy tunnel fixation inside the joint. Well, centered humeral head is visualized with recreated labral bumper effect, and stability of Remplissage is checked with to and fro movements of the humeral head (Figs 10 and 11).



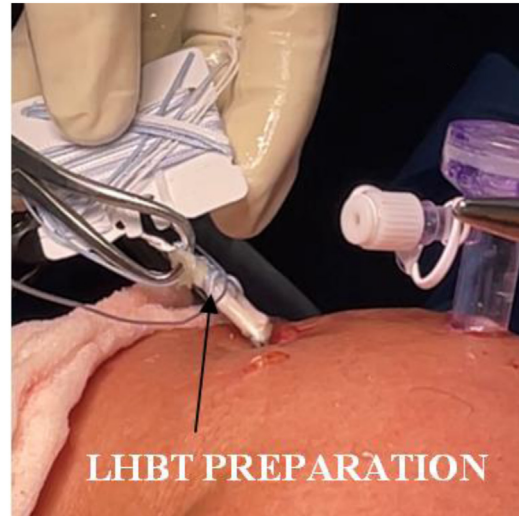**Fig 4.** Biceps tendon (BT) secured with single cinch stitch with no. 2 Ethibond sutures using a suture passer from anterior portal E visualizing from posterior portal A.



**Fig 5.** LHB tendon (LHBT) tenotomy is shown at the level of its origin from superior labrum working from anterior portal E and viewing from posterior portal A using radiofrequency ablator.

### Postoperative Protocol

Postoperatively, patient is immobilized in an arm sling and hand grips, passive elbow flexion, and shoulder shrugs are initiated from the first postoperative day. Passive shoulder movements are started from the 10th day to achieve a full passive shoulder range of movements at the end of the six weeks. The patient is encouraged to do computer work from day 10, being that the patient is a software professional. Active shoulder movements and strengthening exercises are initiated at the end of 6 weeks, and rehabilitation is continued for 3 months. The patient is allowed to do daily activities from the 6th week after sling removal. The patient is allowed to return to occasional sports activities after 3 months and active full intense sporting

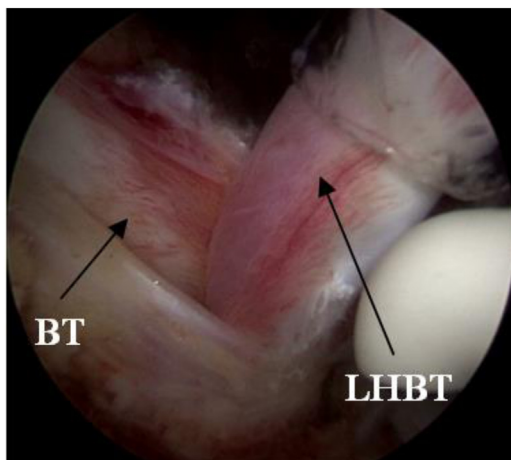


**Fig 7.** The long head of biceps tendon (LHBT) is exteriorized through portal D and tendon preparation is done with FiberTag TightRope.

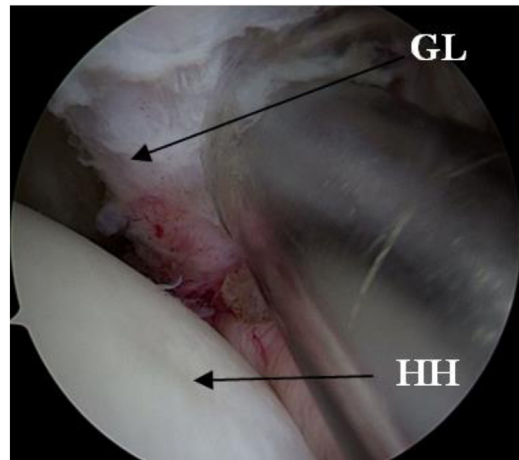
activities at the end of 6 months. The tips and tricks of this surgical procedure ([Video 1](#)) are listed in [Table 2](#).

### Institutional Review Board Approval

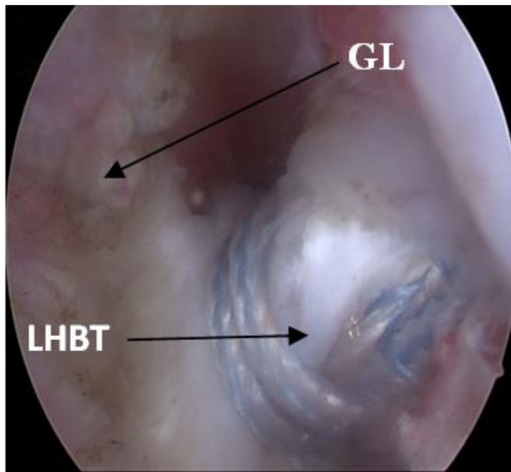
All procedures performed in studies involving human participants were in accordance with the ethical standards of the institutional and national research committee and with the 1964 Helsinki declaration and its later amendments or comparable ethical standards. The patient signed a specific consent accepting that anonymized medical data, including video recording of the surgery, can be used for scientific and educational purposes as long the patient identity and personal data are protected.



**Fig 6.** Complete release of LHB tendon (LHBT) done from the bicipital groove to the upper border of pectoralis major working from anterolateral portal D and viewing from lateral portal B.



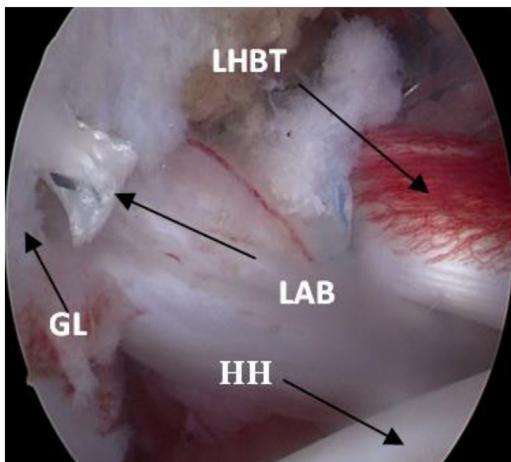
**Fig 8.** Transosseous bone tunnel made in the glenoid at level of 3 o'clock position working from portal J and viewing from portal D and reaming of tunnel made with 6-mm reamer for a distance of 15 mm.



**Fig 9.** LHB tendon (LHBT) passed through the bone tunnel and secured with flipping of Endobutton of the FiberTag TightRope, and the desired level of tendon is pulled into the tunnel working from portal J and visualizing from portal D.

### Discussion

Latarjet procedure is the preferred treatment for recurrent shoulder dislocation with critical bone loss of 20-25%, and glenoid bone loss of less than 20% is managed with soft tissue stabilization procedure like Bankart repair, which is preferred worldwide.<sup>6</sup> Recent studies in the literature show the amount of glenoid bone loss leading to persistent instability even after Bankart repair is as low as 15%.<sup>7</sup> Saha et al. in their study demonstrated in patients with a high level of activity, glenoid bone loss as low as 13.5% led to worsening of WOSI scores, even without recurrent instability.<sup>8</sup> The ideal management of recurrent shoulder instability with associated glenoid bone loss is still under research.<sup>9,10</sup>



**Fig 10.** Final arthroscopic picture with completed LHB tendon (LHBT) transfer to the glenoid and labral (LAB) repair viewing from portal D.



BT- Bicipital tunnel, HH- Humeral head, GL- Glenoid, HSL-Hill sach lesion, LHBT-Long head of biceps tendon, LAB- Labrum, SUP LAB- Superior Labrum.

**Fig 11.** Animation picture depicting final fixation of LHB tendon (LHBT) to the glenoid through the subscapularis split. The flipped endobutton is securely placed over the posterior glenoid surface.

The increasing trend of performing bony stabilization procedures like Latarjet in such patients with subcritical bone loss has its own share of disadvantages. There is a steep learning curve for arthroscopic Latarjet, along with the increased risk of neurovascular injuries, graft and implant-related complications, increased risk of arthrosis following increased stress on humeral cartilage by the coracoid graft, increased risk of superior humeral migration arising from sacrificing of CA ligament, and risk of scapular dyskinesia due to pectoralis minor release, all of which warrants rethinking of performing Latarjet procedures in patients with subcritical bone loss.<sup>11-15</sup>

Shin et al. demonstrated it was not possible to restore the glenohumeral kinematics with anterior glenoid bone loss  $\geq 15\%$  with Bankart repair. They demonstrated a posteroinferior shift of humeral head in the abduction and external rotation position, in addition to glenohumeral translation in such scenarios.<sup>7</sup> Latarjet procedure can reduce the dislocation rates in patients with glenoid bone loss but with increased complication rates when compared to Bankart repairs. Considering the complication rates of Latarjet procedure, this should be judiciously preferred in patients with smaller glenoid defects.<sup>16</sup> Dynamic anterior stabilization with the long head of biceps tendon augmented with Bankart repair can effectively prevent the subsequent instability in patients with subcritical bone loss.<sup>5</sup>

Dynamic anterior stabilization using LHB tendon transfer is less invasive compared to the Latarjet procedure in addition of providing the sling effect. A biomechanical study by Mehl et al. demonstrated decreased anterior glenohumeral translation of humeral head with the DAS technique when compared to Bankart repair in glenoid bone loss of less than 20%. They also demonstrated an increased shift of posterior and inferior humeral head in ABER position when bone loss is greater than 20%.<sup>17</sup> We conclude DAS can be supplemented with Bankart repair as an effective procedure in preventing instability in bone loss of less than 20%.

Considering the option of isolated conjoint tendon transfer as an alternative to the long head of biceps tendon transfer, Bokshan et al. demonstrated

**Table 2.** Tips and Pitfalls of the Technique

Tips	
1)	Adequate rotator interval release helps in proper visualization of LHB release and subscapularis split.
2)	Use of the J portal facilitates ease of working while tunnel drilling and SC split.
3)	Use of plastic tissue-protective sheath avoids soft tissue injury and also proper visualization.
4)	No soft tissue dissection is needed in the posterior aspect of the glenoid when using FiberTag TightRope (Arthrex).
5)	LHB tendon release is performed by cutting THL laterally to the tendon and avoids injury to SC insertion.
6)	Good tendon integration is achieved with the use of the bone tunnel.
7)	Reaming of glenoid tunnel is done up to 15 mm; whole tunnel enlargement makes fixation with FiberTag TightRope difficult.
Pitfalls	
1)	Incorrect placement of D portal, the anterolateral portal impairs adequate visualization of bicipital groove, risking injury to subscapularis insertion.
2)	Risk of soft tissue injury while drilling the glenoid tunnel if a protection sleeve is not used.
3)	Multiple sutures in LHB and usage of bulky penetrating devices risk tendon injury and longitudinal split.

significant resistance to anterior humeral head translation in the case of subcritical glenoid bone loss when compared to conjoint tendon transfer in a cadaveric study.<sup>18</sup>

Tang et al. demonstrated arthroscopic LHB transfer and fixation with suspensory devices and bone tunnel in their study, but the procedure needed soft tissue dissection, exposing the posterior aspect of the glenoid for using the suspensory device.<sup>4</sup> We modified the technique of using FiberTag TightRope (Arthrex), avoiding soft tissue dissection, providing good fixation strength, and also augmenting with labral repair and Remplissage.

The failure strength and tendon healing rates with different fixation devices that are in use for tendon fixation were studied in the past by different authors. Mayr et al. demonstrated lesser tunnel widening with adjustable length loop cortical button when compared to interference screw in ACL reconstruction.<sup>19</sup>

**Table 3.** Advantages and Limitations of DAS

Advantages	
1)	Sling and hammock effect provided
2)	Lower learning curve than arthroscopic Latarjet
3)	Lower complications rate compared to bony procedures
4)	Less soft tissue dissection is required.
5)	Sturdy fixation of LHB tendon with use of FiberTag TightRope (Arthrex)
6)	Early postoperative rehabilitation can be initiated with the bone tunnel technique.
Limitations	
1)	No long-term follow-up of functional recovery and shoulder functions
2)	Good knowledge of shoulder anatomy and skills in arthroscopy are needed.
3)	Weaker sling when compared to Latarjet
4)	No bony restoration of glenoid arc is done.

Rahardja et al. compared the fixation strength of suspensory devices versus interference screw on tibial side graft fixation and found greater revision rates with the usage of an interference screw when compared to suspensory fixation.<sup>20</sup> Tunnel widening is reported with both suspensory devices and interference screws, but tunnel widening has greater consequences in the case of interference screw fixation, as fixation depends on graft compression against the tunnel wall.<sup>19</sup> Although Frank et al. demonstrated superior results of all suture-suture anchors over an interference screw when used for biceps tenodesis, pull-out strength of suture anchors when used for LHB in DAS are unclear.<sup>21</sup> Higher risk of suture pullout is expected in the early postoperative period, which warrants a long period of immobilization and delay in rehabilitation. Considering all of the studies, we advise the use of FiberTag TightRope (Arthrex), a suspensory device, in the fixation of LHB in our modification of the DAS procedure. The advantages and limitations of this surgical technique are listed in Table 3.

## Conclusion

Dynamic anterior stabilization with LHB transfer along with Bankart repair is a viable option in managing recurrent shoulder instability with glenoid bone loss up to 20%. Fixation of LHB tendon to glenoid with transosseous tunnel using FiberTag TightRope (Arthrex) provides a sturdy fixation with less soft tissue dissection and the option of early postoperative shoulder rehabilitation leading to better outcomes.

## References

- Collin P, Lädermann A. Dynamic anterior stabilization using the long head of the biceps for anteroinferior glenohumeral instability. *Arthrosc Tech* 2018;7:e39-e44.
- de Campos Azevedo C, Ângelo AC. All-suture anchor dynamic anterior stabilization produced successful healing of the biceps tendon: A report of 3 cases. *JBJS Case Connect* 2021;11.
- Popescu IA, Neculau DC, Simion C, Popescu D. Modified dynamic anterior stabilization (DAS) and Hill-Sachs Remplissage for the treatment of recurrent anterior shoulder dislocation. *Arthrosc Tech* 2022;11:e147-e152.
- Tang J, Zhao J. Arthroscopic transfer of the long head of the biceps brachii for anterior shoulder instability. *Arthrosc Tech* 2017;6:e1911-e1917.
- Collin P, Nabergoj M, Denard PJ, Wang S, Bothorel H, Lädermann A. Arthroscopic biceps transfer to the glenoid with Bankart repair grants satisfactory 2-year results for recurrent anteroinferior glenohumeral instability in subcritical bone loss. *Arthroscopy* 2022;38:1766-1771.
- Friedman LGM, Lafosse L, Garrigues GE. Global perspectives on management of shoulder instability: Decision making and treatment. *Orthop Clin North Am* 2020;51:241-258.
- Shin SJ, Kim RG, Jeon YS, Kwon TH. Critical value of anterior glenoid bone loss that leads to recurrent

- glenohumeral instability after arthroscopic Bankart repair. *Am J Sports Med* 2017;45:1975-1981.
8. Shaha JS, Cook JB, Song DJ, et al. Redefining “critical” bone loss in shoulder instability: Functional outcomes worsen with “subcritical” bone loss. *Am J Sports Med* 2015;43:1719-1725.
  9. Hurley ET, Matache BA, Wong I, et al. Anterior shoulder instability part I—Diagnosis, nonoperative management, and Bankart repair—An international consensus statement. *Arthroscopy* 2022;38:214-223.e7.
  10. Hurley ET, Matache BA, Wong I, et al. Anterior shoulder instability part II—Latarjet, Remplissage, and glenoid bone-grafting—An international consensus statement. *Arthroscopy* 2022;38:224-233.e6.
  11. Hurley ET, Jamal MS, Ali ZS, Montgomery C, Pauzenberger L, Mullett H. Long-term outcomes of the Latarjet procedure for anterior shoulder instability: A systematic review of studies at 10-year follow-up. *J Shoulder Elbow Surg* 2019;28:e33-e39.
  12. Cerciello S, Corona K, Morris BJ, Santagada DA, Maccauro G. Early outcomes and perioperative complications of the arthroscopic Latarjet procedure: Systematic review and meta-analysis. *Am J Sports Med* 2019;47:2232-2241.
  13. Carbone S, Moroder P, Runer A, Resch H, Gumina S, Hertel R. Scapular dyskinesia after Latarjet procedure. *J Shoulder Elbow Surg* 2016;25:422-427.
  14. Sano H, Komatsuda T, Abe H, Ozawa H, Yokobori TAJ. Proximal-medial part in the coracoid graft demonstrates the most evident stress shielding following the Latarjet procedure: Assimilation study using the 3-dimensional finite element method. *J Shoulder Elbow Surg* 2020;29:2632-2639.
  15. Sano H, Komatsuda T, Abe H, Ozawa H, Kumagai J, Yokobori TAJ. Intra-articular biomechanical environment following modified Bristow and Latarjet procedures in shoulders with large glenoid defects: relationship with postoperative complications. *J Shoulder Elbow Surg* 2021;30:2260-2269.
  16. Rollick NC, Ono Y, Kurji HM, et al. Long-term outcomes of the Bankart and Latarjet repairs: A systematic review. *Open Access J Sports Med* 2017;8:97-105.
  17. Mehl J, Otto A, Imhoff FB, et al. Dynamic anterior shoulder stabilization with the long head of the biceps tendon: A biomechanical study. *Am J Sports Med* 2019;47:1441-1450.
  18. Bokshan SL, Gil JA, DeFroda SF, Badida R, Crisco JJ, Owens BD. Biomechanical comparison of the long head of the biceps tendon versus conjoint tendon transfer in a bone loss shoulder instability model. *Orthop J Sports Med* 2019;7:2325967119883549.
  19. Mayr R, Smekal V, Koidl C, et al. ACL reconstruction with adjustable-length loop cortical button fixation results in less tibial tunnel widening compared with interference screw fixation. *Knee Surg Sports Traumatol Arthrosc Off J ESSKA* 2020;28:1036-1044.
  20. Rahardja R, Love H, Clatworthy MG, Monk AP, Young SW. Suspensory versus interference tibial fixation of hamstring tendon autografts in anterior cruciate ligament reconstruction: Results from the New Zealand ACL Registry. *Am J Sports Med* 2022;50:904-911.
  21. Frank RM, Bernardoni ED, Veera SS, et al. Biomechanical analysis of all-suture suture anchor fixation compared with conventional suture anchors and interference screws for biceps tenodesis. *Arthroscopy* 2019;35:1760-1768.