



Received: 2016.01.13  
Accepted: 2016.01.25  
Published: 2016.08.30

# Whole-Body MRI Screening in Asymptomatic Subjects; Preliminary Experience and Long-Term Follow-Up Findings

Sıla Ulus<sup>1BCDEF</sup>, Erdogan Suleyman<sup>2BCD</sup>, Umit Aksoy Ozcan<sup>1CE</sup>, Ercan Karaarslan<sup>1AEC</sup>

<sup>1</sup> Department of Radiology, Acıbadem University, School of Medicine, Istanbul, Turkey

<sup>2</sup> Department of Radiology, Acıbadem Maslak Hospital, Istanbul, Turkey

**Author's address:** Sila Ulus, Department of Radiology, Acıbadem University, School of Medicine, Kerem Aydınlar Kampusu Kayisdagi Cad. No: 32 Atasehir, Istanbul, Turkey, e-mail: silaulus@hotmail.com

## Authors' Contribution:

- A** Study Design
- B** Data Collection
- C** Statistical Analysis
- D** Data Interpretation
- E** Manuscript Preparation
- F** Literature Search
- G** Funds Collection

## Background:

The aim of this study is to describe the technique and to evaluate the results of whole-body magnetic resonance imaging in an asymptomatic population.

## Material/Methods:

Between March 2009 and December 2011, 118 consecutive subjects undergoing thorough medical check-up were prospectively included in the study. MRI was performed with a 205-cm moving table, parallel imaging and automatic image composing software.

## Results:

In 83 subjects (70%), 103 benign lesions were detected. Two malignant (adrenal and renal carcinoma) lesions and one precancerous (pancreatic mucinous carcinoma) lesion were detected. The most common lesions were renal cysts, liver hemangiomas, liver cysts, thyroid nodules, and uterine leiomyomas.

## Conclusions:

WB-MRI is able to cover area from head to toes in one diagnostic work-up, and besides the anatomic regions evaluated by conventional radiological modalities, i.e. brain parenchyma, bones and extremities, can be evaluated in one examination.

## MeSH Keywords:

Asymptomatic Diseases • Early Detection of Cancer • Incidental Findings • Whole-Body Counting

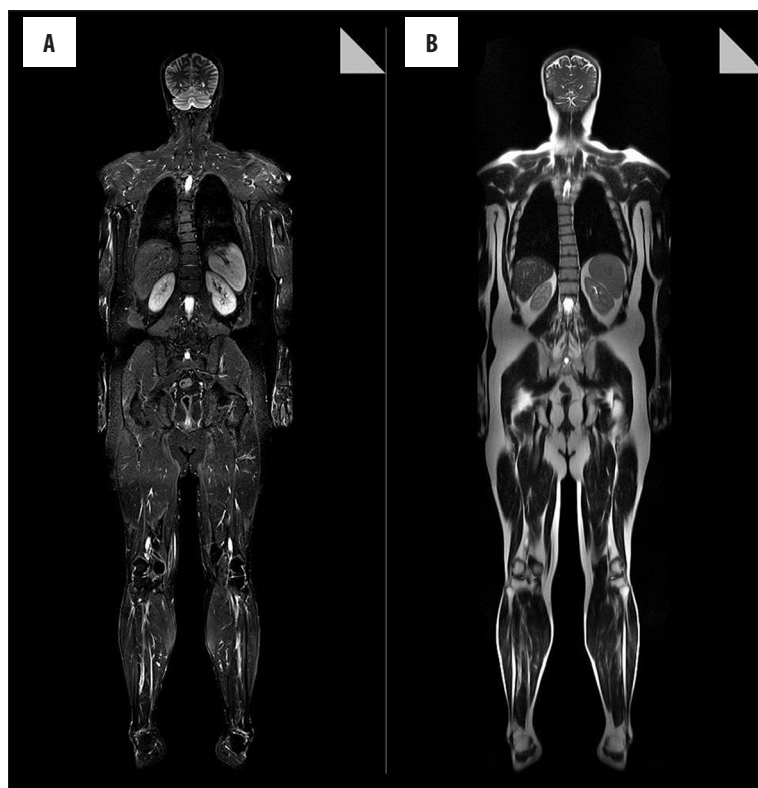## PDF file:

<http://www.polradiol.com/abstract/index/idArt/897570>

## Background

Whole-body magnetic resonance imaging (WB-MRI) has been available for some time, but only recently it has become an efficient method for total body screening from head to toes. The idea of imaging the entire body during one examination has been validated as an effective imaging protocol for a number of conditions. In clinical practice, WB-MRI is increasingly being used in the diagnostics of a variety of diseases, including lymphomas, multiple myeloma, systemic musculoskeletal diseases, and also systemic diseases like diabetes [1] and atherosclerosis [2,3]. WB-MRI has been increasingly used in children with malignant diseases, and also other pathologies, such as infant abuse – non-accidental trauma [4] or musculoskeletal diseases, owing to superior tissue contrast with absence of ionizing radiation. In the recent years, with the developments in magnetic resonance imaging (MRI) technology, another

field of diagnostic imaging, which is screening in asymptomatic subjects, i.e. check-up examination, has been introduced [5–14]. The multiplanar imaging, high spatial resolution, anatomical and functional imaging capabilities make MRI an alternative for computed tomography (CT) in screening [15]. Improvements of the software and hardware enable imaging of the whole body with MRI in a short time. MRI with a continuously moving table (CMT) represents a novel method allowing for the seamless acquisition of an extended field-of-view in the z-direction [16]. This promising method offers an all-in-one diagnosis. Malignant tumors, which are one of the most important health condition in the population, are in the spotlight. WB-MRI is capable of detecting a wide range of malignant diseases including bronchial carcinoma, hepatic malignancies, renal carcinoma, colonic cancer, lymphoma, and also rare malignancies such as bone or soft tissue tumors [12]. Early diagnosis of some of these diseases might have a positive



**Figure 1.** Normal coronal STIR (A) and HASTE (B) images.

**Table 1.** Parameters of the MR sequences.

Sequence	Orientation	Resolution	FOV	Comment
HASTE-T2-W	Coronal-whole body	1.4×1.1×6.0 mm	500 mm	Breath-hold for thorax and abdomen
STIR-T2	Coronal-whole body	1.7×1.3×6.0 mm	500 mm	
T2-TSE	Axial-whole body	1.0×0.7×6.0 mm 1.0×0.8×5.0 mm 1.9×1.4×8.0 mm	230 mm-brain 240 mm-neck 460 mm-body/thigh	Breath-hold for thorax and abdomen
T1-FL 2D in phase out-phase	Axial upper abdomen	1.6×1.5×6.0 mm	380 mm	Breath-hold
DWI	Axial upper abdomen	2.5×2×8.0 mm	380 mm	With diaphragmatic gating

W – weighted; STIR – short TI Inversion Recovery; TSE – turbo spin echo; 2D – two-dimensional; DWI – diffusion-weighted imaging; FOV – field of view.

impact on the prognosis. Lack of side effects is a major obligation for screening and the only sources of side effects in MRI are potentially consequent to intravenous (IV) contrast agents.

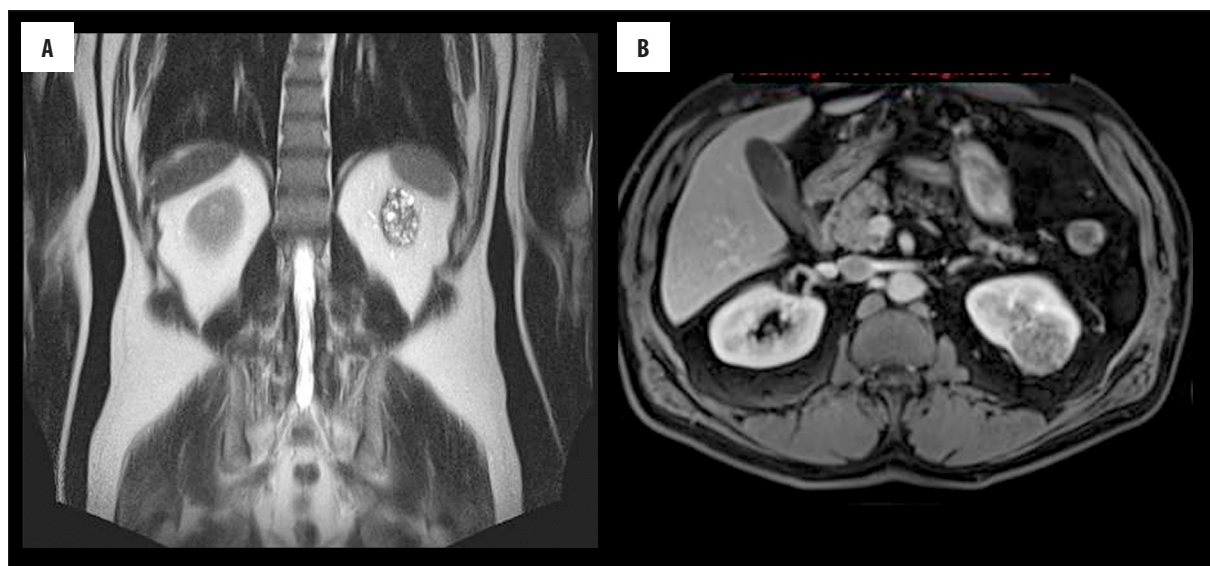
This study is aimed to evaluate the findings of WB-MRI in asymptomatic subjects scanned for check-up examination. Technical aspects are also reviewed.

## Material and Methods

### Study population

Our institution started a special check-up program as an oncologic work-up with WB-MRI in addition to other

standard check-up programs. Standard check-up programs include transabdominal sonography, chest X-ray, and for women mammography and/or breast sonography examinations in our institution. Some programs also include sonography of the thyroid gland, and transvaginal sonography as part of the gynecologic examination. From March 2009 to December 2011, 118 consecutive subjects who self-referred for this program were prospectively included in the study. The financial expense of the examinations was covered by the subjects. The study group consisted of 71 males and 47 females (mean age: 47.4 years; age range: 20–81). A total of 33 subjects were aged <40 years (33.58±5.11), and 85 subjects were ≥40 years (53.30±9.4). The subjects were all asymptomatic with no known disease and they were keen for screening. Informed consent was obtained from



**Figure 2.** A renal mass is detected in the left kidney shown in the coronal HASTE (A) image. Dedicated dynamic contrast-enhanced GRE-T1 (B) image demonstrates a heterogeneously-enhancing mass lesion.

all subjects and the study was approved by the local ethics committee. Before the examination, the procedure was explained in detail to the patient, including the duration of the examination, and the possibility of adding sequences with or without IV contrast agents, immediately following the examination or in an appropriate date.

#### WB-MRI scanning technique

All MRI examinations were performed on a 1.5-T 18-channel MRI scanner (Magnetom Avanto; Siemens Medical Solutions, Erlangen, Germany) SQ engine, 45 mT/sec with 205-cm moving table, parallel imaging and automatic image composing software, using 76 “matrix coils”: two head arrays, one neck array, two body arrays, one peripheral array and one spine array with combinable coil elements to cover the whole body allowing for parallel imaging in three dimensions. Two expert technicians performed the standardized examinations. The region from vertex to crus was scanned with 4–5-step coronal short tau inversion recovery (STIR) and half-fourier acquisition single-shot turbo spin-echo (HASTE) (Figure 1), and 6–7-step axial turbo spin-echo (TSE)-T2-weighted (W) sequences. For the upper abdomen in-and-out of phase T1-W and diffusion sequences were also obtained. The standard unenhanced MRI duration was estimated as  $\pm 30$  minutes (28–35 minutes). Dedicated sequences were added for necessary cases. For 12 subjects IV contrast was used for the characterization of lesions. MRI sequences are summarized in Table 1.

#### Scan interpretation and reporting

All the data were sent to PACS workstation and interpreted by two radiologists (E.K. and E.S) with an experience of approximately 15 years in MRI. All abnormalities were reported according to their origin and clinical significance. Discordant findings were resolved in consensus. Multiple similar findings within one subject (e.g. more than one renal cyst) were counted as a single finding. The findings of our results were not only communicated in written reports, but

also through oral conversation with the screened person. The purpose of this dialogue is to describe the impact of the findings and to permit the person to better comprehend the written report and to reduce fear in view of unknown medical terms, which might be used. Follow-up of the subjects for any significant disease occurrence in the next 3–5 years was performed by review of any performed radiological work-up and medical records and/or telephone interviews.

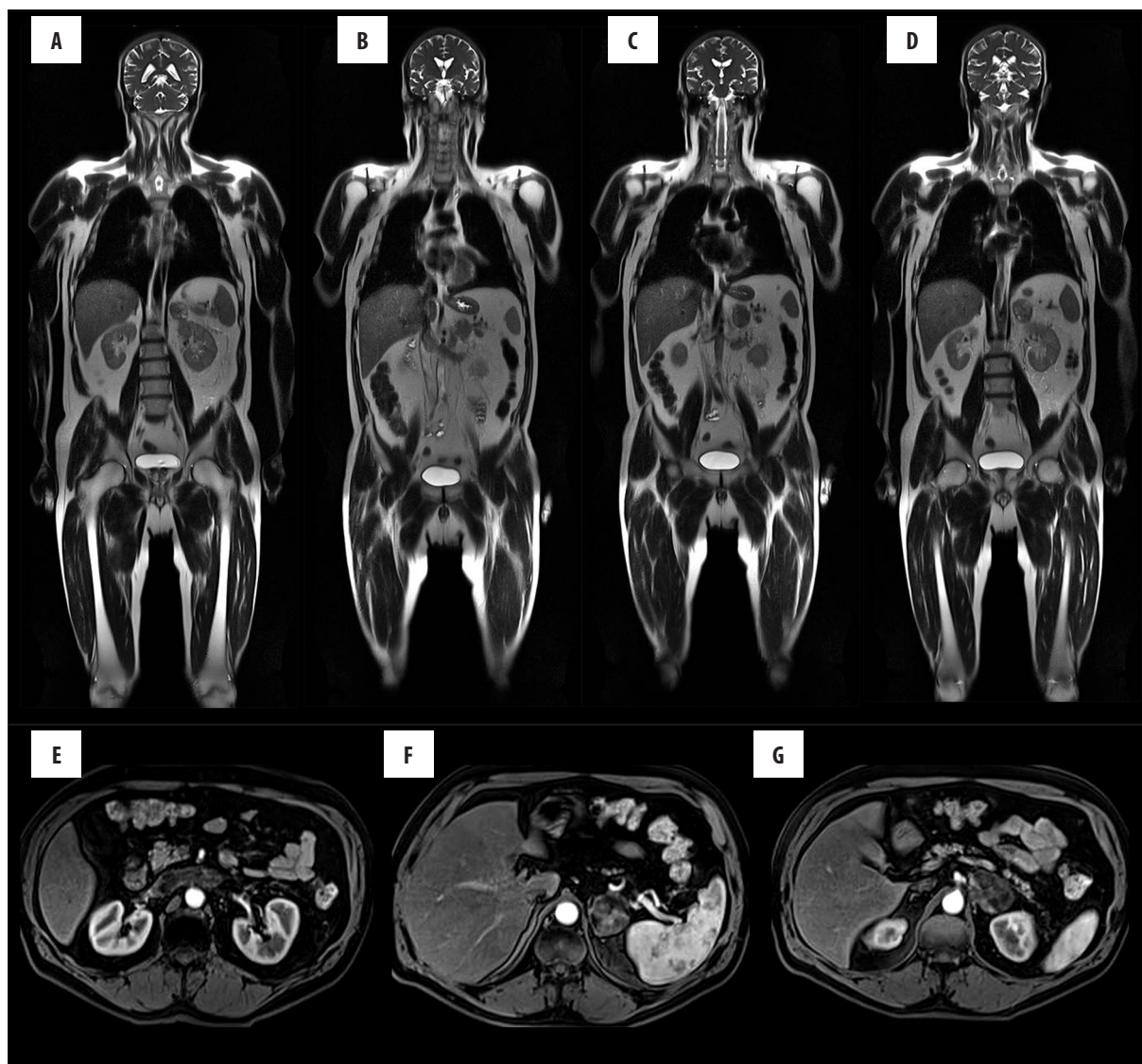
#### Statistical analysis

Statistical analysis was performed with NCCS (Number Cruncher Statistical System; 2007 Statistical Software, Utah, USA). For comparison of quality data, chi-square and odds ratio (OR) were used. Results were considered statistically significant at  $p < 0.05$ .

#### Results

No abnormality was found in 35 (30%) subjects. In the remaining 83 subjects (70%), 103 benign, 2 malignant and 1 precancerous lesions were detected. No malignant lesion was detected in subjects  $< 40$  years of age. In this group, 25 benign (in 18 subjects; 55%) lesions were found and in the remaining 15 subjects (45%) no abnormality was found. In subjects  $\geq 40$  years of age, 89 benign (in 57 subjects; 67%) lesions were detected, while no abnormality was found in the remaining 28 (33%) subjects.

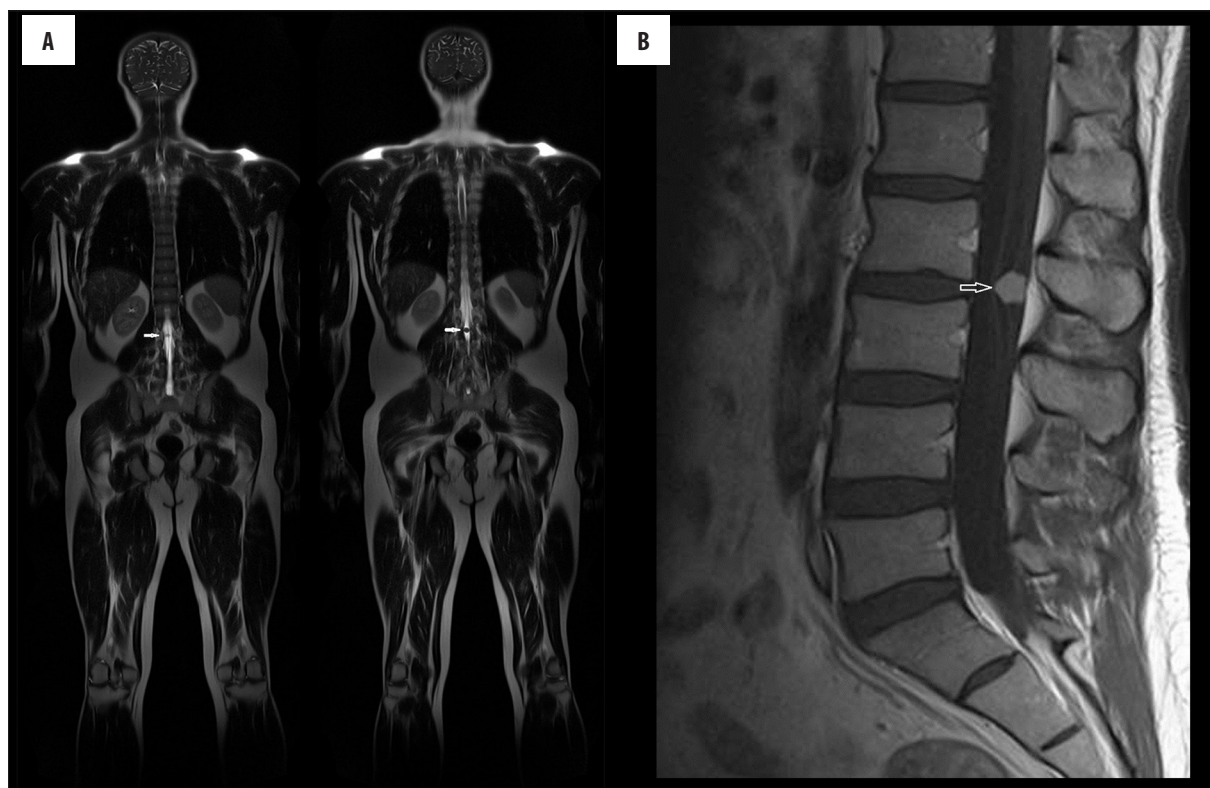
- A solid kidney mass was found in one subject and further evaluation with gadolinium administration confirmed a mass compatible for a renal cell carcinoma (Figure 2A, 2B). The patient underwent surgery and pathology result was consistent with renal cell carcinoma. He is fine and in follow-up.
- A left adrenal mass invading the renal vein and vena cava was detected in one subject (Figure 3A–3D). Dedicated contrast-enhanced sequences (Figure 3A–3G) were added for comprehensive evaluation. The patient was operated on and the pathology result was consistent with adrenal carcinoma.



**Figure 3.** Coronal HASTE-T2-W (A–D) images reveal a left adrenal mass. Dynamic contrast-enhanced abdominal MRI (E–G) images show heterogeneous enhancement of the lesion and invasion of the left renal vein and vena cava inferior.

- A spinal intradural mass was noted in two subjects. The masses were evident on coronal plane images (Figure 4A). Dedicated spinal MRI was performed and strong enhancement in the masses after gadolinium administration was shown (Figure 4B). One patient underwent operation in another center and the pathology confirmed the diagnosis of schwannoma. The other patient is in follow-up with no change in the three-year course.
- A 3-cm cystic pancreatic mass was found in one subject. Dedicated pancreatic MRI revealed an enhancing septation and the patient was operated on. The pathology was consistent with mucinous cystadenoma. Follow-ups were normal.
- A lesion consistent with femoral enchondroma was encountered in one patient. The size of the lesion was a concern for pathologic fractures, so it was curetted and grafted surgically.
- In one subject, tuberculosis pneumonia was detected and she underwent medical treatment.
- In three subjects liver masses consistent with focal nodular hyperplasia (FNH) after dedicated contrast-enhanced sequences were encountered and those lesions were stable for the 36-month follow-up period.
- One mandibular fibrous dysplasia was detected, and no change was seen in the follow-up.
- One unclassified solid mass in the spleen was detected in a patient. The lesion decreased in size in the 18-month follow-up, and disappeared in the 3<sup>rd</sup>-year follow-up. The patient had a history of hydatid cyst in the liver and lung, and most likely the healing lesion was also a hydatid cyst lesion.

The most common incidental lesions in the WB-MRI examinations were renal cysts [17], liver hemangiomas [13], liver cysts [12], thyroid nodules [8], and uterine leiomyomas (5). Also, two adrenal gland adenomas were seen. Furthermore, one lung nodule smaller than 5 mm was detected, confirmed by multidetector computed tomography (MDCT). Follow-up with MDCT revealed no increase in size of the nodule in



**Figure 4.** (A) Coronal HASTE-T2-W images reveal an intradural lesion at the level of L2–3 and (B) dedicated spinal contrast-enhanced T1-W shows the enhancing nodular lesion.

**Table 2.** Number of incidental lesions from WB-MRI.

Benign lesions	Malignant lesions	Precancerous lesions
Renal cyst (17)	Renal cell carcinoma (1)	Pancreatic mucinous cystadenocarcinoma (1)
Liver hemangioma (13)	Adrenal carcinoma (1)	
Liver cyst (12)		
Thyroid nodule (8)		
Uterine leiomyoma (5)		
Liver focal nodular hyperplasia (3)		
Adrenal adenoma (2)		
Schwannoma (2)		
Lung nodule (1)		
Enchondroma (1)		
Fibrous dysplasia (1)		
Tuberculosis pneumonia (1)		

the 24-month follow-up period. The number of the lesions encountered is summarized in Table 2. Hepatomegaly, hepatosteatosis, cholelithiasis, gallbladder polyps smaller than 5 mm, simple over cysts, bladder stones, benign prostate gland enlargement, lumbar, thoracic or cervical disc herniations were other pathologies detected, which may require medical treatment and sometimes interventions. Insignificant soft tissue lesions such as lipoma, elastofibromadorsi and Baker cyst were seen in a few patients.

No significant difference was observed for the incidence of either benign or malignant lesions between subjects aged  $\geq 40$  years and  $< 40$  years. However, all of the malignant lesions were detected in subjects over  $\geq 40$  years. All (benign+malignant) lesions were observed to be 3.3 times more common in subjects over  $\geq 40$  years.

For 75 of 118 patients (64%) no additional finding was detected in the 3–5-year follow-up. Information on 37

patients was not available. One patient had an operation for lumbar disc herniation. In the second-year follow-up, intradural millimetric progressive schwannomas in a more caudal location were detected in the patient who was operated on for schwannoma and the patient was thoroughly examined for the possibility of neurofibromatosis. No additional finding was identified and the patient is still in follow-up. In one patient, millimetric thyroid carcinoma was detected in the subsequent year of her check-up, and one patient was diagnosed with chordoma in the coccyx two years after his WB-MRI examination.

## Discussion

The use of radiological imaging for screening, i.e. targeting the detection of the disease before it becomes symptomatic is limited. MDCT has been suggested for screening especially for the detection of early manifestations of a cardiovascular disease, lung and colon cancer, but risks associated with high radiation exposure and intravenous contrast agents limit its use. With the developments in technology, lack of ionizing radiation and fewer side effects associated with intravenous contrast medium, MRI has emerged as the imaging technique for the evaluation of many organs. The role of MRI as a screening tool has been proposed for the detection of several diseases, such as cerebral aneurysms [17], bone metastases [18], pulmonary diseases [19,20], cardiovascular diseases [2,3], and colonic polyps [21].

Use of WB-MRI for screening in healthy asymptomatic subjects has also been reported [5–14]. The main use of MRI for screening is for malignant tumors and atherosclerosis. Bronchial carcinoma and renal cell carcinoma are the most prevalent tumors detected in WB-MRI studies. Lo et al. found two lesions (1.5%) that were proven malignant; one renal cell and one bronchial carcinoma with a 3-T device on 132 subjects [10]. Ladd et al. reported similar results in a cohort of 216 individuals and the prevalence of renal cell carcinoma and bronchial carcinoma were 0.5% and 1%, respectively [11]. Goehde et al. performed a study on 298 subjects to evaluate early detection of cardiovascular and malignant diseases [7], and their study also revealed one renal cell carcinoma. Hegenscheid et al. found 13 renal cell carcinomas in a study group consisting of 2500 subjects (0.52%) [12]. Tarnoki et al. performed a study with a 3-T device on 22 patients and discovered a suspicious pararectal malignancy in one patient [13]. We detected renal cell carcinoma in one subject (1%). For renal cell carcinomas, it has been shown that the survival time is increased in patients who have been identified by screening compared to symptomatic patients. We did not detect any lung cancer in our study. This could be due to the relatively low number of subjects. In the follow-up period, no lung cancer was discovered in the subjects whose information was available.

### Technical principles

- HASTE-T2-W coronal plane (fast detecting) is obtained for high T2 lesions like cysts and hemangiomas, delineating contours of intestinal structures and lung parenchyma. It is also sensitive for lung lesions, such as nodules [19].

- Coronal plane STIR sequence is acquired for low T2 lesions such as bone lesions, lymph nodes and solid organ metastases.
- Axial T2-W TSE sequence is obtained as a second plane for brain parenchyma, neck, thorax, abdomen, and extremity lesions.
- Axial in- and out-of-phase T1-W sequence for the upper abdomen is acquired for the differential diagnosis of suprarenal lesions and liver lesions.
- Axial diffusion series for the upper abdomen is obtained for lesion detection in the liver parenchyma and lymph node detection.

One of the most important advantages of MRI over other imaging modalities is a higher sensitivity for soft-tissue and bone pathologies. It is the most sensitive technique for the detection of pathologies restricted to the bone marrow, even if the trabecular bone is not destroyed [23,23].

Transabdominal ultrasonography (US) is a widely used imaging method for screening purposes. It depends highly on the experience of the performer and patient's truncal weight and bowel gas. The sensitivity of transabdominal sonography is not very high for pancreas and in the detection of pancreatic cancers sonography has an overall sensitivity of 75% and a specificity of 75% [24]. Differentiating cystic neoplasms from pancreatic adenocarcinomas is important, since the prognosis for malignant cystic neoplasms is better than that for ductal adenocarcinomas [15]. Accurate preoperative characterization of pancreatic lesions guides therapeutic decision-making. Although CT is the first-line imaging modality for initial detection and characterization of pancreatic cysts, MRI can accurately depict the morphologic features of the cyst and have the advantage of demonstrating the relationship of the cyst to the pancreatic duct [25]. One pancreatic cystic lesion was found in our series. Surgery was performed and the lesion was confirmed to be a pancreatic mucinous cystadenoma.

We did not detect any malignant liver masses in this patient population. In our series liver hemangiomas and liver cysts were the most common benign lesions encountered after renal cysts. HASTE imaging is proven to be useful for distinguishing hepatic hemangioma from hepatic cyst even without the use of contrast-enhanced MR images [25]. FNH is the second most common benign liver tumor after hemangioma [15] and MRI is superior to CT and US in the establishment of the diagnosis. In this study three solid liver masses were detected with WB-MRI, which were compatible with FNH in dynamic MRI series.

MRI provides the unique ability to detect and specify adenomas with chemical shift imaging without using gadolinium, which makes it a very patient-friendly imaging modality [27,28]. We detected two adrenal adenomas in our study population. Also, an adrenal tumor invading the renal vein and vena cava was found in one patient.

US was performed for all subjects with thyroid nodules. No nodule was found suspicious and required biopsy. In the follow-up period, control sonography examinations revealed no change in the size or morphology of the nodules.

We detected chordoma in a patient's coccyx two years after the check-up examination. As to improve the imaging protocol we suggest the addition of a sagittal plane STIR sequence for the spine. We routinely use this protocol in our last series.

Our study has some limitations and drawbacks. One of the limitations of our study is the relatively small number of patients in each disease group. This may explain why no significant difference between the two age groups was found. The study population has increased in the last three years with the establishment of a 3-T second MRI device in a department including 850 subjects and we believe more accurate and demonstrative data will be produced. In this study, as our preliminary experience, we wanted to present the findings of the first 118 subjects who were examined in the 1.5-T device and followed up for 3–5 years. The possible effects of increased body mass index (BMI) were not included in our statistical analysis. We did not use contrast agents routinely in our study due to the risk of allergic reactions, the increased duration of the examination, and also the increased cost. The high specificity of MRI is mainly due to the use of a contrast material and for a larger study group; the use of contrast agents may decrease the proportion of unclear findings. Also, MRA was not performed due to the same reasons, and atherosclerosis was not evaluated. We used axial diffusion series only for the upper abdomen. While extending the examination time, the addition of a whole-body diffusion sequence would improve both lesion detection and characterization [29]. The sensitivity and specificity of whole-body MRI is maximized through the combined interpretation of morphologic routine images and functional diffusion weighted imaging [30–32]. Another drawback is for thyroid nodules. It can be difficult to identify small nodules, and especially suspicious microcalcifications in the millimetric nodules with MRI,

and it would be beneficial to complement the examination with US. One of our patients, whose millimetric nodule was missed in the MRI and detected in the sonography examination, was diagnosed with papillary thyroid carcinoma and operated on.

The feasibility of making WB-MRI a part of check-up programs still remains a question, and it needs to be validated by different centers and evaluated with further studies to determine the cost-benefit aspect of the application. Besides, the validation of the findings with other modalities and accurate assessment of positive and negative predictive values needs to be verified with further study groups. We are aware that the use of WB-MRI as a screening test is not agreeable with the guidelines declared by The World Health Organization (Wilson's Criteria) for screening. However, in our study we wanted to indicate the technical aspects and to emphasize that WB-MRI is technically prepared for screening, to report the frequencies of potentially relevant incidental findings that require further medical evaluation in an asymptomatic subject group, and also to present the follow-up outcomes of this group.

## Conclusions

WB-MRI is a useful and non-invasive diagnostic tool for the detection of incidental masses in otherwise healthy patients. As much as 5% of this population screened by WB-MRI underwent further surgical or medical treatment. Our study results show that it is a promising method and reveals variety of abnormalities which would have been revealed in a limited fashion with other modalities.

## Conflicts of interest

The authors declared no conflicts of interest.

## References:

- Weckbach S, Schoenberg SO: Whole body MR imaging in diabetes. *Eur J Radiol*, 2009; 70: 424–30
- Ruehm SG, Goehde SC, Goyen M: Whole body MR angiography screening. *Int J Cardiovasc Imaging*, 2004; 20: 587–91
- Kramer H, Schoenberg SO, Nikolaou K et al: Cardiovascular screening with parallel imaging techniques and a whole-body MR imager. *Radiology*, 2005; 236: 300–10
- Perez-Rossello JM, Connolly SA, Newton AW et al: Whole-body MRI in suspected infant abuse. *Am J Roentgenol*, 2010; 195: 744–50
- Baumgart D, Egelhof T: Preventive whole-body screening encompassing modern imaging using magnetic resonance tomography. *Herz*, 2007; 32: 387–94
- Morin SH, Cobbold JF, Lim AK et al: Incidental findings in healthy control research subjects using whole-body MRI. *Eur J Radiol*, 2009; 72: 529–33
- Goehde SC, Hunold P, Vogt FM et al: Full-body cardiovascular and tumor MRI for early detection of disease: Feasibility and initial experience in 298 subjects. *Am J Roentgenol*, 2005; 184: 598–611
- Ladd SC: Whole-body MRI as a screening tool? *Eur J Radiol*, 2009; 70: 452–62
- Hegenscheid K, Kühn JP, Völzke H et al: Whole-body magnetic resonance imaging of healthy volunteers: pilot study results from the population-based SHIP study. *Rofo*, 2009; 181: 748–59
- Lo GG, Ai V, Au-Yeung KM et al: Magnetic resonance whole body imaging at 3 Tesla: feasibility and findings in a cohort of asymptomatic medical doctors. *Hong Kong Med J*, 2008; 14: 90–96
- Ladd SC, Wanke I, Gizewski ER et al: First results of a prospective whole-body MR screening study. Presented in the Congress of Radiology, Vienna, Austria, Proceedings, 2007; 286
- Hegenscheid K, Seipel R, Schmidt CO et al: Potentially relevant incidental findings on research whole-body MRI in the general adult population: frequencies and management. *Eur Radiol*, 2013; 23: 816–26
- Tarnoki DL, Tarnoki AD, Richter A et al: Clinical value of whole-body magnetic resonance imaging in health screening of general adult population. *Radiol Oncol*, 2015; 49(1): 10–16
- Bamberg F, Kauczor HU, Weckbach S et al.; German National Cohort MRI Study Investigators: Whole-body MR imaging in the German National Cohort: Rationale, design, and technical background. *Radiology*, 2015; 277(1): 206–20
- Dujardin M, Vandenbroucke F, Boulet C et al: Indications for body MRI Part I. Upper abdomen and renal imaging. *Eur J Radiol*, 2008; 65: 214–21
- Schaefer AO, Langer M, Baumann T: Continuously moving table MRI in oncology. *Rofo*, 2010; 182: 954–64
- Dickey PS: Screening for intracranial aneurysm. *Surg Neurol*, 2006; 66: 642
- Walker RE, Eustace SJ: Whole-body magnetic resonance imaging: Techniques, clinical indications, and future applications. *Semin Musculoskelet Radiol*, 2001; 5: 5–20
- Vogt FM, Herborn CU, Hunold P et al: HASTE MRI versus chest radiography in the detection of pulmonary nodules: Comparison with MDCT. *Am J Roentgenol*, 2004; 183: 71–78

20. Wu NY, Cheng HC, Ko JS et al: Magnetic resonance imaging for lung cancer detection: experience in a population of more than 10,000 healthy individuals. *BMC Cancer*, 2011; 11: 242
21. Purkayastha S, Tekkis PP, Athanasiou T et al: Magnetic resonance colonography versus colonoscopy as a diagnostic investigation for colorectal cancer: A meta-analysis. *Clin Radiol*, 2005; 60: 980-89
22. Daldrup-Link HE, Franzius C, Link TM et al: Whole-body MR imaging for detection of bone metastases in children and young adults: Comparison with skeletal scintigraphy and FDG PET. *Am J Roentgenol*, 2001; 177: 229-36
23. Imamura F, Kuriyama K, Seto T et al: Detection of bone marrow metastases of small cell lung cancer with magnetic resonance imaging: Early diagnosis before destruction of osseous structure and implications for staging. *Lung Cancer*, 2000; 27: 189-97
24. Karlson BM, Ekblom A, Lindgren PG et al: Abdominal US for diagnosis of pancreatic tumor: Prospective cohort analysis. *Radiology*, 1999; 213: 107-11
25. Sahani DV, Kadavigere R, Saokar A et al: Cystic pancreatic lesions: A simple imaging-based classification system for guiding management. *Radiographics*, 2005; 25: 1471-84
26. Sasaki K, Ito K, Koike S et al: Differentiation between hepatic cyst and hemangioma: additive value of breath-hold, multisection fluid-attenuated inversion-recovery magnetic resonance imaging using half-Fourier acquisition single-shot turbo-spin-echo sequence. *J Magn Reson Imaging*, 2005; 21: 29-36
27. Savci G, Yazici Z, Sahin N et al: Value of chemical shift subtraction MRI in characterization of adrenal masses. *Am J Roentgenol*, 2006; 186: 130-35
28. Fujiyoshi F, Nakajo M, Fukukura Y et al: Characterization of adrenal tumors by chemical shift fast low-angle shot MR imaging: Comparison of four methods of quantitative evaluation. *Am J Roentgenol*, 2003; 180: 1649-57
29. Attariwala R, Picker W: Whole body MRI: Improved lesion detection and characterization with diffusion weighted techniques. *J Magn Reson Imaging*, 2013; 38: 253-68
30. Kwee TC, van Ufford HM, Beek FJ et al: Whole-body MRI, including diffusion-weighted imaging, for the initial staging of malignant lymphoma: Comparison to computed tomography. *Invest Radiol*, 2009; 44: 683-90
31. Gu J, Chan T, Zhang J et al: Whole-body diffusion-weighted imaging: the added value to whole-body MRI at initial diagnosis of lymphoma. *Am J Roentgenol*, 2011; 197: W384-91
32. Fischer MA, Nanz D, Hany T et al: Diagnostic accuracy of whole body MRI/DWI image fusion for detection of malignant tumours: A comparison with PET/CT. *Eur Radiol*, 2011; 21: 246-55