

## Naïve B cells followed by aquaporin-4 antibodies characterise the onset of neuromyelitis optica: evidence from stem cell transplantation

### INTRODUCTION

Neuromyelitis optica spectrum disorders (NMOSDs) are mediated by antibodies directed against the extracellular domain of aquaporin-4 (AQP4). These antibodies form a key pillar in diagnostic criteria for NMOSD.<sup>1</sup> Yet, the immunological mechanisms underlying the generation of AQP4 antibodies during disease initiation are incompletely understood, principally because this is an asymptomatic period. To date, AQP4 antibodies and symptomatic NMOSD are known to develop several years after myasthenia gravis, typically post-thymectomy,<sup>2</sup> or in the context of bone marrow transplantation.<sup>3</sup> These examples suggest the immunopathogenesis of symptomatic NMOSD typically requires many years to mature.

The duration and nature of the immune response maturation can provide insights into the cellular processes responsible for AQP4 antibody production, in particular the potential relevance of long-lived plasma cells versus germinal centre reactions.<sup>4,5</sup> Hence, the fundamental immunopathogenesis may inform the rational selection of targeted immunotherapeutics.<sup>4,5</sup>

Here, we describe a patient who developed post-transplant NMOSD, and capture the key period of acute clinico-serological disease conversion with serial biological samples. The findings revealed herein provide several unique insights into the immunopathogenesis of NMOSD.

### MATERIALS AND METHODS

*Phenotype and patient samples.* Clinical and radiology data collection was prospectively gathered, along with serial blood samples (both cells and serum), and archived for research purposes.

*AQP4-antibodies.* Live cell-based assays were performed, with minor modifications from published protocols.<sup>6</sup> In brief, HEK293T cells were transfected with cDNA encoding full-length AQP4 and, while live, labelled with patient IgG or IgM which, after fixation, were detected with isotype-specific secondary antibodies (product numbers 709-585-098, Jackson labs, and A-21216, ThermoFisher, respectively). Prior to AQP4-IgM detection, IgGs were fully depleted with protein G beads. All positive results were titrated to endpoint dilutions.

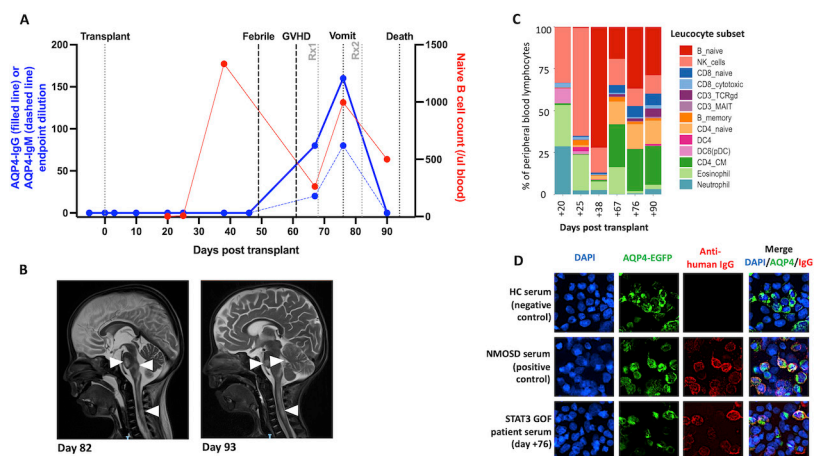
*B cell populations.* From liquid nitrogen archived whole blood, mass cytometry immunophenotyped several populations including B cells (details in online supplemental data). Naïve B cells were defined as CD19<sup>+</sup>CD20<sup>+</sup>CD27<sup>-</sup>IgD<sup>+</sup>.

### RESULTS

#### Clinical features

A boy (between 1 and 2 years of age) with *STAT3* gain-of-function mutation received a matched unrelated donor peripheral blood stem cell transplant to treat severe refractory multisystem autoimmune disease, including neonatal giant cell hepatitis and complete lipodystrophy.

After an unremarkable early post-transplant course, on day 49 he developed a fever and respiratory distress, with no infective cause identified (figure 1A). On day 61, oedema, rash and diarrhoea led to a diagnosis of graft-versus-host disease (GVHD), confirmed on upper gastrointestinal tract biopsy and treated with methylprednisolone (2 mg/kg) from day 68. Subsequently, on day 76, he developed severe vomiting, initially considered secondary to progressive GVHD. However, after 1 week he had slow pupillary reactions, left-sided weakness, a decreased level of consciousness and apnoea. MRI showed T2 hyperintense lesions predominantly affecting the pons, medulla, area postrema and cervical cord (figure 1B), with optic nerve sparing. Serum AQP4-IgG was detected with normal total immunoglobulin levels. He was diagnosed with NMOSD and treated aggressively with 30 mg/kg methylprednisolone, plasmapheresis and alemtuzumab (0.2 mg/kg × 5 doses). On day 93, he developed labile blood pressure and



**Figure 1** Time course of cellular immune reconstitution: naïve B cell repopulation, AQP4 antibody generation and imaging changes following stem cell transplant. (A) Time course of peripheral blood naïve B cell counts (red, right y-axis), and serum AQP4-IgG (blue solid line, left y-axis) and AQP4-IgM (blue dashed line, left y-axis) endpoint dilutions. The first sample obtained was preconditioning. Treatment 1 (Rx1, grey) was methylprednisolone (30 mg/kg); treatment 2 (Rx2, grey) was methylprednisolone (30 mg/kg), plasmapheresis and alemtuzumab (0.2 mg/kg). Vomit=onset of vomiting. (B) Sagittal T2-weighted MRI shows regions of inflammation in the brainstem and cervical cord (arrowheads) at day 82 and day 93 post-transplant. (C) Proportions of peripheral blood leucocyte subsets as measured by mass cytometry (Cytob-Helios). Annotated subsets include naïve B cells (CD19<sup>+</sup>CD20<sup>+</sup>CD27<sup>-</sup>IgD<sup>+</sup>); memory B cells (CD19<sup>+</sup>CD20<sup>+</sup>CD27<sup>+</sup>), natural killer (NK), CD3<sup>+</sup> gamma delta T cells (gdTCR), CD3<sup>+</sup> mucosal-associated invariant T cells (MAIT), dendritic cells (DC, including plasmacytoid DCs; pDC) and both naïve/central memory CD4<sup>+</sup> T cells (CD4\_CM). (D) AQP4-antibody live cell-based assay. AQP4-IgGs (red) from a serum of a patient with neuromyelitis optica spectrum disorder (NMOSD) binds to the surface of live AQP4-expressing HEK293T cells (middle panel), with similar reactivity demonstrated by the STAT3 gain-of-function (GOF) patient serum (bottom panel). Healthy control (HC) serum (top panel) shows no detectable binding to these cells. AQP4 tagged to EGFP (AQP4-EGFP, green); DAPI nuclear staining (blue). Images taken at  $\times 40$  magnification. AQP4, aquaporin-4; DAPI, 4',6-diamidino-2-phenylindole; EGFP, enhanced green fluorescent protein; GVHD, graft-versus-host disease.

fixed-dilated pupils. Repeat MRI showed brainstem lesion extension plus new bithalamic involvement (figure 1B). The neurological disease was considered irreversible and respiratory support withdrawn on day 94.

### Laboratory findings

Retrospective live cell-based assays showed the *de novo* appearance of serum AQP4 antibodies (1:80 endpoint dilution) on day 67, with levels which rose to 1:160 by day 76 (figure 1). After confirmed depletion of IgG, these two samples additionally showed AQP4-IgM reactivities (1:40 and 1:80 endpoint dilutions, respectively). No other samples showed AQP4-IgM or AQP4-IgG. Mass cytometry analysis revealed that these serological findings were preceded by a striking expansion of the naïve B lymphocyte population, between days 25 and 38, rising from 0.8% to 72% of all leucocytes (figure 1A–C). This time course represents a highly accelerated reconstitution of the naïve B cell compartment, which is usually delayed until >6 months post-transplant.<sup>7</sup>

Genotyping on day 83 (a comparison of donor and recipient DNA using PowerPlex 16 HS system) revealed that 70% of CD19<sup>+</sup> cells were donor derived (30% were from the recipient); whereas none of the residual CD3<sup>+</sup> T cells and only 21% of myeloid cells were donor derived.

### DISCUSSION

This tragic case provides a unique opportunity to observe a *de novo* human autoimmunisation directed against AQP4. Below, we synthesise longitudinal clinical, cellular and serological observations from this distinctive case to hypothesise mechanisms of AQP4 antibody synthesis, with both clinical and therapeutic relevance.

The temporal dynamics of this human autoimmunisation identified the generation of AQP4 antibodies over just a few weeks, early after stem cell transplantation and far more acutely than documented in two different clinical scenarios.<sup>2,3</sup> An unusually sharp  $\sim 100$ -fold rise in naïve B cells occurred prior to generation of AQP4 antibodies. This time course may reflect

the exit of donor antigen-inexperienced B cells from the bone marrow (70% of the B cells were donor derived) and their subsequent maturation towards precursors of the serum AQP4 antibodies.

Around 1 month later, both *de novo* serum AQP4-IgG and IgMs were observed and temporally coincided with the development of symptomatic NMOSD. The concurrent AQP4-IgG and IgMs suggest an acute immunisation in this patient (akin to that observed in many infections), and support a germinal centre-based generation of AQP4 antibodies. This germinal centre activity may be fuelled by the reconstituting naïve B cells which, in patients with NMOSD, have been observed to both carry AQP4 reactivities and show deranged regulatory properties.<sup>6,8</sup> Hence, prevention of naïve B cell reconstitution, for example, with anti-CD19 and/or anti-CD20 drugs, may offer an important therapeutic target which represents a potential precursor to relapses in NMOSD.<sup>9</sup> In further support of this mechanism, a few weeks is likely too short a duration to generate a significant population of human long-lived plasma cells. Yet, it remains possible that the AQP4-IgG generation resulted from incomplete depletion of plasma cells prior to transplantation.

STAT3 is a pleotropic transcription factor expressed by the NMOSD-associated Th17 T cell subset,<sup>10</sup> which also drives the differentiation of T follicular cells and inhibits the generation of T regulatory cells. Therefore, it may be that disordered STAT3 signalling, particularly from the recipient's residual T cells, could be implicated in the pathogenesis of their NMOSD.<sup>3</sup>

In summary, by detailing a case with an early, severe neurological complication after stem cell transplantation, we provide an opportunity to observe *in vivo* the development of AQP4 antibodies. Our data support a role for naïve B cells and germinal centres in the initiating pathogenesis of NMOSD. This conclusion has important implications for understanding disease pathogenesis and selecting optimal therapeutics.

Peter McNaughton,<sup>1,2</sup> Rebecca Payne,<sup>1</sup> Sophia Michael,<sup>3,4</sup> Timothy Leahy,<sup>5</sup> Alexander Nicols,<sup>1</sup> Andrew Fower,<sup>6</sup> Sophie Hambleton,<sup>1</sup> Ki Pang,<sup>7</sup> Andrew Gennery,<sup>1</sup> Sarosh R Irani<sup>3,4</sup>

<sup>1</sup>Paediatric Immunology, Newcastle upon Tyne Hospital Trusts, Newcastle upon Tyne, UK

<sup>2</sup>Department of Paediatrics, Queensland Children's Hospital, South Brisbane, Queensland, Australia

<sup>3</sup>Nuffield Department of Clinical Neurosciences, University of Oxford, Oxford, UK

<sup>4</sup>Department of Neurology, Oxford University Hospitals NHS Foundation Trust, Oxford, UK

<sup>5</sup>Children's Health Ireland at Crumlin, Trinity College Dublin, Dublin, Ireland

<sup>6</sup>Nuffield Department of Clinical Neurosciences, John Radcliffe Hospital, Oxford, UK

<sup>7</sup>Department of Paediatric Neurology, Newcastle upon Tyne Hospitals NHS Foundation Trust, Newcastle upon Tyne, UK

**Correspondence to** Prof Sarosh R Irani, Nuffield Department of Clinical Neurosciences, University of Oxford, Oxford OX3 9DS, UK; sarosh.irani@ndcn.ox.ac.uk

**Twitter** Sarosh R Irani @ANG\_Oxford

**Contributors** The corresponding author (SRI) had full access to all the data in the study and takes responsibility for the integrity of the data and the accuracy of the data analysis. Data analysis was conducted by PM, RP, SM, TL, AN, AF, SH, KP, AG and SRI.

**Funding** SRI was supported in whole or in part by a senior clinical fellowship from the Medical Research Council (MR/V007173/1), Wellcome Trust Fellowship (104079/Z/14/Z), BMA Research Grants-Vera Down grant (2013) and Margaret Temple (2017), Epilepsy Research UK (P1201), the Fulbright Association (MS-Society research award) and by the NIHR Oxford Biomedical Research Centre. RP is supported by a Wellcome Career Re-entry Fellowship (204721/Z/16/Z). For the purpose of Open Access, the author has applied a CC BY public copyright licence to any Author Accepted Manuscript (AAM) version arising from this submission.

**Disclaimer** The views expressed are those of the author(s) and not necessarily those of the NHS, the NIHR or the Department of Health. The funders had no role in the design and conduct of the study; collection, management, analysis, and interpretation of the data; preparation, review, or approval of the manuscript; and decision to submit the manuscript for publication.

**Competing interests** SRI is a co-applicant and receives royalties on patent application WO/2010/046716 (UK patent no. PCT/GB2009/051441) entitled 'Neurological Autoimmune Disorders'. The patent has been licensed commercially for the development of assays for LGI1 and other VGKC-complex antibodies. SRI is an inventor on a patent application entitled Diagnostic Strategy to improve specificity of CASPR2 antibody detection (PCT/GB2019/051257, publication number WO/2019/211633 and UK1807410.4). SRI has received honoraria from UCB, MedImmune, ADC therapeutics and Medlink Neurology, and research support from CSL

Behring, UCB and ONO Pharma. PM, RP, SM, TL, AN, AF, SH, KP and AG have no conflicts of interest to declare.

**Patient consent for publication** Parental/guardian consent obtained.

**Ethics approval** This study involves human participants and was approved by Newcastle REC (REC17/NE/0248) and Yorkshire/Humber REC (REC16/YH/0013). Participants gave informed consent to participate in the study before taking part.

**Provenance and peer review** Not commissioned; externally peer reviewed.

This content has been supplied by the author(s). It has not been vetted by BMJ Publishing Group Limited (BMJ) and may not have been peer-reviewed. Any opinions or recommendations discussed are solely those of the author(s) and are not endorsed by BMJ. BMJ disclaims all liability and responsibility arising from any reliance placed on the content. Where the content includes any translated material, BMJ does not warrant the accuracy and reliability of the translations (including but not limited to local regulations, clinical guidelines, terminology, drug names and drug dosages), and is not responsible for any error and/or omissions arising from translation and adaptation or otherwise.



## OPEN ACCESS

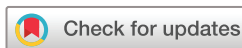**Open access** This is an open access article distributed in accordance with the Creative Commons Attribution 4.0 Unported (CC BY 4.0) license, which permits others to copy, redistribute, remix, transform and build upon this work for any purpose, provided the original work is properly cited, a link to the licence is given, and indication of whether changes were made. See: <https://creativecommons.org/licenses/by/4.0/>.

© Author(s) (or their employer(s)) 2022. Re-use permitted under CC BY. Published by BMJ.

► Additional supplemental material is published online only. To view, please visit the journal online (<http://dx.doi.org/10.1136/jnnp-2022-328982>).

PM and RP are joint first authors.

AG and SRI are joint senior authors.



**To cite** McNaughton P, Payne R, Michael S, *et al.* *J Neurol Neurosurg Psychiatry* 2022;**93**:1234–1236.

Received 4 February 2022

Accepted 20 April 2022

Published Online First 23 May 2022

*J Neurol Neurosurg Psychiatry* 2022;**93**:1234–1236. doi:10.1136/jnnp-2022-328982

## ORCID iD

Sarosh R Irani <http://orcid.org/0000-0002-7667-9748>

## REFERENCES

- 1 Wingerchuk DM, Banwell B, Bennett JL, *et al.* International consensus diagnostic criteria for neuromyelitis optica spectrum disorders. *Neurology* 2015;**85**:177–89.
- 2 Leite MI, Coutinho E, Lana-Peixoto M, *et al.* Myasthenia gravis and neuromyelitis optica spectrum disorder: a multicenter study of 16 patients. *Neurology* 2012;**78**:1601–7.
- 3 Diamanti L, Franciotta D, Berzoro G, *et al.* Late post-transplant anti-aquaporin-4 Ab-positive optic neuritis in a patient with AML. *Bone Marrow Transplant* 2015;**50**:1125–6.
- 4 Sun B, Ramberger M, O'Connor KC, *et al.* The B cell immunobiology that underlies CNS autoantibody-mediated diseases. *Nat Rev Neurol* 2020;**16**:481–92.
- 5 Bennett JL, O'Connor KC, Bar-Or A, *et al.* B lymphocytes in neuromyelitis optica. *Neurology - Neuroimmunology Neuroinflammation* 2015;**2**:e104.
- 6 Wilson R, Makuch M, Kienzler A-K, *et al.* Condition-Dependent generation of aquaporin-4 antibodies from circulating B cells in neuromyelitis optica. *Brain* 2018;**141**:1063–74.
- 7 van der Maas NG, Berghuis D, van der Burg M, der MNGvan, *et al.* B cell reconstitution and influencing factors after hematopoietic stem cell transplantation in children. *Front Immunol* 2019;**10**:782.
- 8 Kim Y, Kim SY, Han S-M, *et al.* Functional impairment of CD19<sup>+</sup>CD24<sup>hi</sup>CD38<sup>hi</sup> B cells in neuromyelitis optica spectrum disorder is restored by B cell depletion therapy. *Sci Transl Med* 2021;**13**:eabk2132.
- 9 Kim S-H, Kim Y, Kim G, *et al.* Less frequent rituximab retreatment maintains remission of neuromyelitis optica spectrum disorder, following long-term rituximab treatment. *J Neurol Neurosurg Psychiatry* 2019;**90**:486–7.
- 10 Varrin-Doyer M, Spencer CM, Schulze-Toppoff U, *et al.* Aquaporin 4-specific T cells in neuromyelitis optica exhibit a Th17 bias and recognize Clostridium ABC transporter. *Ann Neurol* 2012;**72**:53–64.