

Management of antithrombotic therapy in patients at high bleeding risk after percutaneous coronary intervention for acute coronary syndromes: a case report

Hamid Mahmood¹, Farhan Shahid ², Mohaned Eged ^{2*}, and Mohamed Farag ³

¹Cardiology Department, Northwest General Hospital and Research Centre, Peshawar, Pakistan; ²Cardiothoracic Department, Freeman Hospital, Newcastle-Upon-Tyne, UK; and ³Hammersmith Hospital, Imperial College Healthcare NHS Trust, London, UK

Received 12 July 2021; first decision 12 August 2021; accepted 28 May 2022

For the podcast associated with this article, please visit <https://academic.oup.com/ehjcr/pages/podcast>

Background

Choosing antithrombotic therapy for patients at high bleeding risk, particularly those requiring long-term anticoagulant therapy, who have acute coronary syndromes (ACS) and/or undergoing percutaneous coronary intervention (PCI) is becoming increasingly complex.

Case summary

A 78-year-old woman was hospitalized with chest pain and a diagnosis of non-ST-elevation ACS was made. It was decided that the patient should undergo coronary angiogram with a view for angioplasty. Subsequently, she underwent successful PCI to the left anterior descending artery. Shortly after PCI, she was noted to be in atrial fibrillation. Furthermore, she had per rectal bleeding and acute kidney injury, which were managed conservatively. Aspirin and ticagrelor were stopped and she was discharged on dual antithrombotic therapy with clopidogrel and apixaban.

Discussion

Available evidence, driven mainly from expert consensus documents, advocates a case-by-case comprehensive evaluation that integrates patient- and procedure-related factors to assess patients for thrombotic and bleeding tendencies to identify those who may gain most net clinical benefit of antithrombotic combination therapy. In general, if thrombotic drivers prevail, an augmented antithrombotic regime with a view for a longer duration should be planned, and if bleeding drivers prevail, a de-escalated regime with a view for a shorter duration should be sought.

Keywords

Antithrombotic therapy • Acute coronary syndromes • Bleeding • Thrombosis • Case report

ESC Curriculum

3.2 Acute coronary syndrome • 3.1 Coronary artery disease

Learning points

- A one size fits all approach is not ideal for the management of antithrombotic therapy after acute coronary syndromes (ACS).
- In patients with ACS at high bleeding risk, the ultimate goal is to identify a therapeutic window 'sweet spot' of optimal protection and safety, where the combined risk of recurrent thrombosis and bleeding is low.
- After ACS, a dynamic individualized assessment of thrombotic vs. bleeding risks is required as part of a tailored management approach, taking into consideration the patient's preference.

* Corresponding author. Email: mohamedfarag@nhs.net

Handling Editor: Tom De Potter

Peer-reviewers: Rita Pavasini; Claudio Montalto; Joseph Moutiris

Compliance Editor: Rayhan Noah Saiani/Lavanya Athithan

Supplementary Material Editor: Anthony Paulo Sunjaya

© The Author(s) 2022. Published by Oxford University Press on behalf of the European Society of Cardiology.

This is an Open Access article distributed under the terms of the Creative Commons Attribution-NonCommercial License (<https://creativecommons.org/licenses/by-nc/4.0/>), which permits non-commercial re-use, distribution, and reproduction in any medium, provided the original work is properly cited. For commercial re-use, please contact journals.permissions@oup.com

Referencing guideline

Collet JP, Thiele H, Barbato E, et al. 2020 ESC Guidelines for the management of acute coronary syndromes in patients presenting without persistent ST-segment elevation. *Eur Heart J*. 2021;42:1289-1367.

Introduction

Patients who suffer from acute coronary syndromes (ACS) and/or undergo percutaneous coronary intervention (PCI) are usually prescribed dual antiplatelet therapy (DAPT, consisting of aspirin and a P2Y₁₂ inhibitor), with an aim to provide secondary prevention strategy and reduce mortality.¹ The commonest reason for the addition of oral anticoagulation (OAC) to DAPT is the coexistence of atrial fibrillation (AF). Of note, one-fifth of patients who have ACS or PCI would warrant such therapeutic regime.¹⁻³ Withholding OAC to reduce bleeding risk may lead to a higher risk of stroke and attempts to reduce DAPT put the patients at risk of stent thrombosis, recurrent myocardial infarction, and even death. Management of patients with ACS and high bleeding risk remains a clinical challenge. This case study highlights the complexity of treating this cohort, and the different treatment strategies currently evidenced to individualize these patients' care.

Timeline

Day 0	Admission with non-ST-elevation acute coronary syndrome and loading doses of dual antiplatelet therapy (aspirin 300 mg and ticagrelor 180 mg) were given
Day 1	Maintenance doses of dual antiplatelet therapy (aspirin 75 mg daily and ticagrelor 90 mg twice daily) were given. A transthoracic echocardiography showed anterior wall hypokinesia with preserved left ventricular systolic function and no significant valvular heart disease
Day 2	Successful percutaneous coronary intervention (PCI) using one drug-eluting stent to the mid left anterior descending artery. A new diagnosis of atrial fibrillation (AF) with controlled ventricular response on a 12-lead electrocardiogram was made shortly after PCI
Day 3	New episodes of per rectal bleeding secondary to haemorrhoids and Grade II acute kidney injury presumed secondary to contrast-induced nephropathy
Day 4	Ticagrelor was de-escalated to clopidogrel 75 mg daily after a loading dose of 600 mg ~24 h after the last dose of ticagrelor
Day 5	No further per rectal bleeding. Apixaban 5 mg twice daily was started
Day 7	Aspirin was stopped and the patient was discharged on dual antithrombotic therapy with clopidogrel 75 mg daily and apixaban 5 mg twice daily for 12 months, then apixaban monotherapy thereafter
3 months	The patient had a good recovery with no major issues highlighted

Short summary of case (hypothetical)

A 78-year-old Caucasian women with a past medical history of hypertension and Type II diabetes mellitus was hospitalized with chest pain and elevated high-sensitivity troponin tests. She was subsequently diagnosed with non-ST-elevation acute coronary syndrome (NSTEMI-ACS). Her admission electrocardiogram (ECG) was unremarkable. She had loading doses of DAPT (aspirin 300 mg and ticagrelor 180 mg), and maintenance doses were prescribed (aspirin 75 mg daily and ticagrelor 90 mg twice daily). Physical examination was unremarkable including cardiovascular examination. She was planned to have an inpatient coronary angiogram with a view for angioplasty within the next 48 h. A transthoracic echocardiography showed anterior wall hypokinesia with preserved left ventricular systolic function and no significant valvular heart disease. On day 2, she underwent successful PCI using one drug-eluting stent to the mid-left anterior descending artery. There was mild diffuse bystander coronary artery disease that was non-flow limiting. Shortly after PCI, she was noted to be in AF with a controlled ventricular response on a 12-lead ECG. Furthermore, she had episodes of per rectal bleeding secondary to haemorrhoids and Grade II acute kidney injury presumed secondary to contrast-induced nephropathy, which were managed conservatively with good recovery.

Whilst in-hospital for 7 days, the patient received maintenance daily doses of aspirin 75 mg and ticagrelor 90 mg. As she remained in AF, ticagrelor was de-escalated to clopidogrel 75 mg daily after a loading dose of 600 mg ~24 h after the last dose of ticagrelor. She was discharged on dual antithrombotic therapy (DAT) with clopidogrel 75 mg daily and apixaban 5 mg twice daily for 12 months, then apixaban monotherapy thereafter. Other medications included a proton pump inhibitor for gastric protection, in addition to a beta-blocker, an angiotensin-converting enzyme inhibitor and a statin. Aspirin was stopped at hospital discharge on Day 7. An outpatient clinic follow-up was carried out at 3 months from index event and no concerns were highlighted.

Discussion

After ACS, while the emphasis is to prevent morbidity and mortality from future ischaemic events, the risk of high bleeding events translating into mortality is receiving recognition.^{1,2} In ACS patients at high bleeding risk (HBR), especially those requiring long-term OAC, the ultimate goal is to reduce the combined risk of recurrent thrombosis and bleeding events. In the subset of patients with NSTEMI-ACS and/or undergoing PCI, and after DAPT loading doses (ideally with aspirin and clopidogrel), current ESC guidelines recommend DAT with clopidogrel and a non-vitamin K oral anticoagulant (NOAC) at the lowest recommended dose for stroke prevention for at least 12 months, and after an initial short period of up to 1 week of triple antithrombotic therapy (TAT, aspirin, and DAT).³ This recommendation is mainly derived from subgroups of randomized controlled trials (Table 1). Of note, subsequent meta-analyses of these trials have demonstrated significantly lower bleeding with DAT compared with TAT with no increase in overall ischaemic events.^{10,11} However, a higher stent thrombosis rate was observed with DAT containing a

Table 1 Randomized controlled trials including patients with non-ST-segment elevation acute coronary syndrome requiring long-term anticoagulation

Study	Population (n)/duration	DES (%)	ACS (%)	AF (%)	Conclusions
WOEST ⁴	573 Between 2008 and 2011	65	27	69	TIMI bleeding and all-cause mortality lower with DAT (VKA + C) vs. TAT (VKA + A + C) at 1 year. No difference in MI, ST, stroke, or TVR
ISAR-TRIPLE ⁵	614 Between 2008 and 2013	99	32	84	No difference in MACE or TIMI major bleeding at 9 months with TAT (VKA + A + C) for 6 weeks followed by DAT (VKA + A) vs. TAT (VKA + A + C) for 6 months followed by DAT (VKA + A)
PIONEER AF-PCI ⁶	2124 Between 2013 and 2015	66	52	100	Clinically significant bleeding, all-cause death and rehospitalization lower with DAT (rivaroxaban 15 mg/day + C for 12 months) or modified TAT (rivaroxaban 2.5 mg b.i.d. + A + C for 1, 6, or 12 months) vs. TAT (VKA + A + C for 1, 6, or 12 months). No difference in cardiovascular death, MI or stroke
RE-DUAL PCI ⁷	2725 Between 2014 and 2016	83	50	100	Major or clinically relevant non-major bleeding lower with DAT (dabigatran 110 or 150 mg b.i.d. + C or T) vs. TAT (VKA + A + C) up to 3 months. No difference in death, MI, stroke, systemic embolism or unplanned revascularization
AUGUSTUS ⁸	4614 Between 2015–2018	NR	37	100	Major or clinically relevant non-major bleeds lower with DAT (apixaban 5 mg b.i.d. + C or T or P) vs. DAT (VKA + C or T or P) or TAT (apixaban 5 mg b.i.d. + A + C or T or P) or TAT (VKA + A + C or T or P). Death and hospitalization lower with apixaban
ENTRUST-AF PCI ⁹	1506 Between 2017 and 2018	NR	52	100	Major or clinically relevant non-major bleeds non-inferior between DAT (edoxaban 60 mg + C or T or P) or TAT (VKA + A + C or T or P). No difference in cardiovascular death, MI, ST, stroke, or systemic embolism

A, aspirin, ACS, acute coronary syndrome, AF, atrial fibrillation, b.i.d., twice a day, C, clopidogrel, DAT, dual antithrombotic therapy, DES, drug-eluting stent, MI, myocardial infarction, NR, not reported, P, prasugrel, T, ticagrelor, ST, stent thrombosis, TAT, triple antithrombotic therapy, TIMI, Thrombolysis In Myocardial Infarction, TVR, target vessel revascularization, VKA, vitamin K antagonist

NOAC and an antiplatelet.^{10,12} It is important to highlight that these studies were primarily designed to assess bleeding events and therefore may have lacked power to provide meaningful results on ischaemic events.

Choice of antiplatelet agent

No trials have evaluated the comparison of DAT containing aspirin vs. a P2Y₁₂ inhibitor. However, an expert consensus document in 2016 recommended P2Y₁₂ inhibitors over aspirin because of their higher efficacy and better gastrointestinal tolerance.¹³ Currently, there is limited data to support the use of DAT containing either ticagrelor or prasugrel after PCI, as clopidogrel was chosen in >90% of cases in available trials. Therefore, the use of ticagrelor or prasugrel as part of TAT should be avoided due to the absence of safety data. In all patients requiring a combination of antiplatelet and anticoagulant therapy, gastric protection with a proton pump inhibitor is recommended.³

Balancing the risk of ischaemia and bleeding after acute coronary syndrome

In ACS patients at HBR and requiring long-term OAC, an expert consensus document in 2018 recommended shortening DAT duration to 6 months by withdrawing the ongoing antiplatelet therapy, especially with newer generation drug-eluting stents.¹⁴ In contrast, for patients at high thrombotic risk requiring long-term OAC, TAT

(aspirin and DAT) is suggested to continue for up to 1 month, followed by DAT for up to 12 months.¹⁴ Recently, the AFIRE randomized trial of 2236 AF patients treated with PCI discouraged the need to continue with a single antiplatelet agent in combination with rivaroxaban beyond 12 months.¹⁵ However, the trial had several limitations with results that are difficult to explain considering the known biologic effects of antithrombotic therapy.

An individualized approach of shortened vs. extended therapy according to patients' combined bleeding/thrombotic risk profile has therefore been advocated and is probably responsible for the wide variation observed in clinical practice.¹⁶

Atrial fibrillation and acute coronary syndromes

Concomitant AF exists in up to 16% of ACS patients with an increased risk of future stroke and death compared to patients without AF. This is mainly due to lack of OAC prescription in those at high risk of thrombosis [i.e. CHA₂DS₂-VASc (congestive heart failure, hypertension, age ≥75 years, diabetes, stroke, vascular disease, age 65–74, sex category female) ≥2].¹⁷ In AF patients with a relatively low stroke risk (CHA₂DS₂-VASc of 1 in men or 2 in women), an expert consensus document in 2016 suggested treating upfront with only DAPT for the first 4 weeks after ACS/PCI,¹ although numerically more myocardial infarction events occurred when aspirin plus clopidogrel were used.¹⁸ Thus, a more potent P2Y₁₂ inhibitor

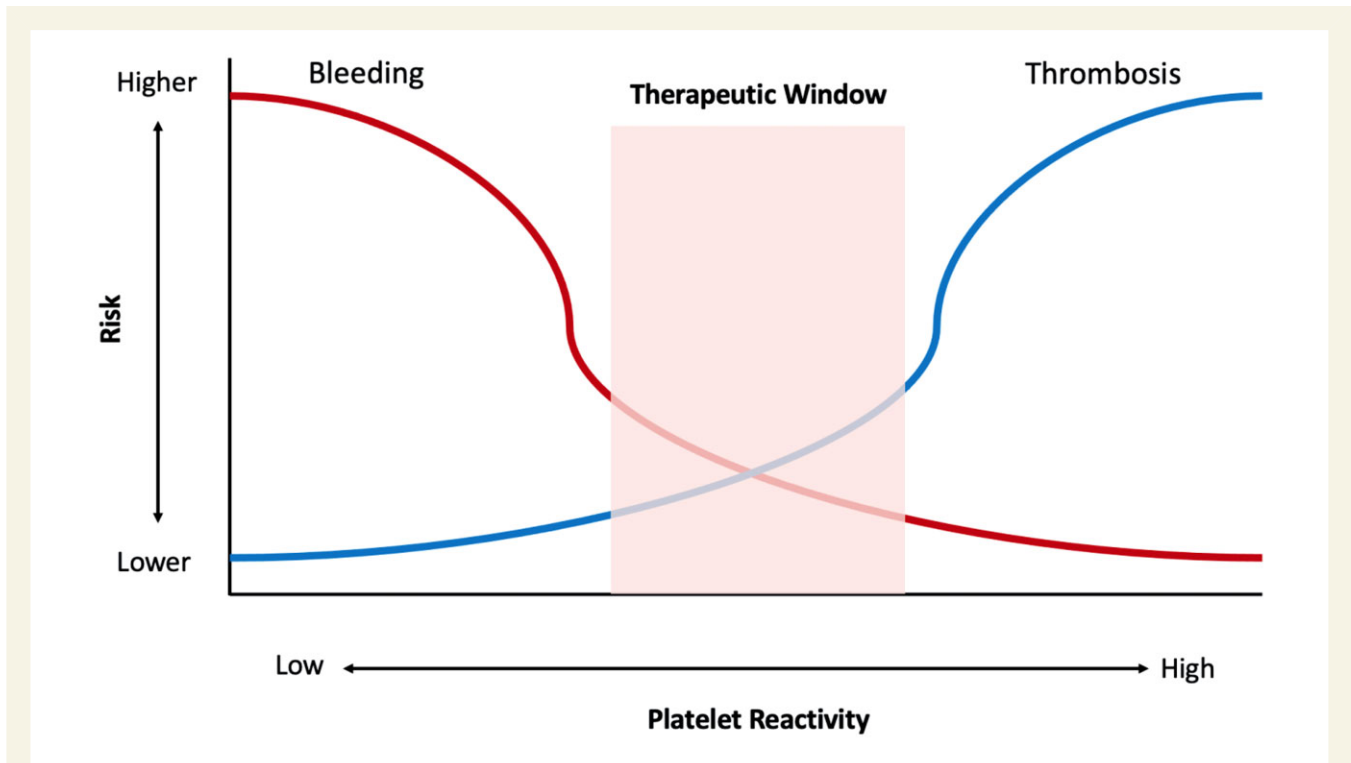


Figure 1 Therapeutic window of platelet inhibition after acute coronary syndromes. **Bleeding risk** is increased with advanced age, uncontrolled hypertension, Stage ≥ 4 chronic kidney disease, combined antiplatelet and anticoagulant use, prior bleeding events or bleeding tendencies/diathesis, active malignancy, low body weight and anaemia. **Thrombotic risk** is increased with advanced age, uncontrolled hypertension, Stage ≥ 4 chronic kidney disease, diabetes, prior myocardial infarction, acute coronary syndromes, extensive coronary artery disease, prior stent thrombosis, suboptimal stenting, greater stent length, small stent diameter, and bifurcation stenting.

(i.e. ticagrelor or prasugrel) may be preferable in this situation. In AF patients with ACS undergoing coronary artery bypass graft surgery, antithrombotic therapy, preferably with DAT, should be resumed as soon as the post-operative bleeding is controlled.

Identifying the ‘sweet spot’

It is important to highlight that the evidence informing ESC practice guidelines generally reflects population-level data. The lack of a reliable individualized risk stratification tool to assess patients for thrombotic and bleeding tendencies to identify a safe therapeutic window, where the net clinical benefit is the highest, has led to limited use of potent antithrombotic drugs in many patients. However, it is important to note that this therapeutic window is likely variable, factorial and patient-specific.¹³ Extremes of on-treatment platelet reactivity are associated with recurrent adverse events. Patients with high on-treatment platelet reactivity are at risk of thrombotic events, whilst those with low on-treatment platelet reactivity are at risk of bleeding. The ultimate goal of any antithrombotic management regime is to identify a therapeutic ‘sweet spot’ of optimal protection and safety, where the risk of thrombotic and bleeding events is low (Figure 1).

Given the trade-off between ischaemic and bleeding risks for antithrombotic medications, the use of risk stratification scores might be useful to guide individualized prescription. However, such scores have yet to be developed or validated for patients with AF and concomitant ACS/PCI. Several scores are mentioned in current ESC

guidelines.³ To assess the bleeding risk, the PRECISE-DAPT score, enclosing a five-item prediction model (age, creatinine clearance, haemoglobin, white blood cell count and prior spontaneous bleeding), or the ARC-HBR score are recommended, with a high risk identified as PRECISE-DAPT ≥ 25 or the ARC-HBR criteria met.¹⁹ For the latter, patients are considered at HBR if they meet at least one major or two minor criteria. Major criteria included anticipated long-term anticoagulation after PCI, severe, or end-stage chronic kidney disease (eGFR < 30 mL/min), anaemia (haemoglobin < 11 g/dL), spontaneous bleeding requiring hospitalization or transfusion in the previous 6 months or at any time, if recurrent, moderate or severe thrombocytopenia (platelet count $< 100 \times 10^9/L$), chronic bleeding diathesis, cirrhosis with portal hypertension, active malignancy in the previous 12 months, presence of brain arteriovenous malformation, previous spontaneous intracranial haemorrhage (ICH) at any time, previous traumatic ICH in the previous 12 months, moderate or severe ischaemic stroke in the previous 6 months, non-deferrable major surgery on DAPT, major surgery or major trauma in the 30 days before PCI. Minor criteria included ≥ 75 years, moderate chronic kidney disease (eGFR, 30–59 mL/min), haemoglobin 11.0–12.9 g/dL for men and 11.0–11.9 g/dL for women, spontaneous bleeding requiring hospitalization or transfusion in the previous 12 months not meeting the major criterion, long-term use of oral non-steroidal anti-inflammatory drugs or steroids, any ischaemic stroke at any time not meeting the major criterion. The HASBLED (Hypertension,

abnormal renal and liver function, stroke, bleeding history or predisposition, labile INR [international normalized ratio], elderly [>65 years], drugs and alcohol) score of ≥ 3 was also incorporated in the guidelines to identify AF patients at HBR but should not be directly used in patients with AF and ACS/PCI. Available scoring systems are derived mainly from clinical characteristics, which often overlap in predicting the risk (e.g. advanced age, uncontrolled hypertension, and chronic kidney disease). Designing risk stratification tools incorporating clinical, procedural, and rheological biomarkers may perhaps better risk-individualize patients.

The AUGUSTUS trial was the only randomized trial offering insight into the use of NOAC therapy (in the form of Apixaban), without aspirin combination, in patients with AF undergoing PCI.⁸ Apixaban monotherapy resulted in less bleeding and fewer hospitalizations without significant differences in the incidence of ischaemic events. Such results were very promising in showing a safety and efficacy benefit of NOAC monotherapy vs. regimens that included a vitamin K antagonist, aspirin, or both. There is a need for further trials to stratify patients based on risk prediction models to tailored treatments vs. standard care taking into consideration the thrombotic and bleeding risks, as well as the patient's values and preferences.

High bleeding risk in the elderly

Another HBR cohort, although not limited to, is that of the elderly. Bleeding risk increases with advanced age, with frequent concomitant comorbidities adding another burden to the choice of antithrombotic therapy following ACS/PCI in this cohort. Although the relationship between age and bleeding risk appears to be continuous, one must bear in mind that biological and chronological age are two separate entities and therefore patients should be assessed on an individualized basis with regards to their bleeding risk. Furthermore, one must acknowledge that bleeding risk must be balanced against thrombotic risk and that a balanced approach should guide the duration of antiplatelet therapy after ACS/PCI in this cohort.

Three randomized trials investigating short DAPT durations were completed in patients undergoing PCI perceived to be at increased bleeding risk.^{20–22} In all three trials involving >5000 patients, advanced age was the commonest factor associated with increased bleeding (64% in LEADERS FREE, 51% in ZEUS, and 100% in SENIOR). To this effect, bleeding risk scores have been incorporated to help risk-stratify these patients, in particular the PRECISE-DAPT and the ARC-HBR.³

Conclusions

Patients with ACS requiring long-term OAC are at high risk of bleeding due to the need for combined antithrombotic therapy, as recommended by current practice guidelines, irrespective of whether invasive or conservative approaches are followed. A careful consideration of thrombotic and bleeding risks as well as the patient's preference is warranted to reduce the combined risk of ischaemic and bleeding events. More comparative randomized trials are needed to evaluate the efficacy and safety of antithrombotic therapies to guide clinical decisions.

Lead author biography



Dr Mohamed Farag is a consultant cardiologist, coronary and structural interventions, at the Lister and Hammersmith hospitals, Hertfordshire and London, UK. He holds an honorary academic appointment as a senior clinical lecturer of cardiovascular medicine at the University of Hertfordshire, UK. He qualified in medicine at Ain-Shams University, Cairo, Egypt and undertook cardiovascular training at the world-class Royal Papworth hospital, Cambridge and Freeman hospital, Newcastle. In addition to clinical training, he undertook a period of dedicated research, leading to a postgraduate MSc from the University of Edinburgh and PhD from the University of Hertfordshire, the latter expanded existing knowledge in predicting future heart attacks in high risk patients. He is actively engaged in research with a special interest in coronary thrombosis and risk stratifying heart attack patients.

Consent: Patient consent has been obtained.

Conflict of interest: The authors have no conflict of interest to declare.

Funding: None declared.

Contributor role: All the authors drafted the manuscript and approved the last version submitted.

References

- Windecker S, Kolh P, Alfonso F, Collet JP, Cremer J, Falk V, Filippatos G, Hamm C, Head SJ, Juni P, Kappetein AP, Kastrati A, Knuuti J, Landmesser U, Laufer G, Neumann FJ, Richter DJ, Schauerte P, Sousa Uva M, Stefanini GG, Taggart DP, Torracca L, Valgimigli M, Wijns W, Witkowski A. 2014 ESC/EACTS Guidelines on myocardial revascularization: the Task Force on Myocardial Revascularization of the European Society of Cardiology (ESC) and the European Association for Cardio-Thoracic Surgery (EACTS) Developed with the special contribution of the European Association of Percutaneous Cardiovascular Interventions (EAPCI). *Eur Heart J* 2014;**35**:2541–2619.
- Valgimigli M, Costa F, Lokhnygina Y, Clare RM, Wallentin L, Moliterno DJ, Armstrong PW, White HD, Held C, Aylward PE, Van de Werf F, Harrington RA, Mahaffey KW, Tricoci P. Trade-off of myocardial infarction vs. bleeding types on mortality after acute coronary syndrome: lessons from the Thrombin Receptor Antagonist for Clinical Event Reduction in Acute Coronary Syndrome (TRACER) randomized trial. *Eur Heart J* 2017;**38**:804–810.
- Collet JP, Thiele H, Barbato E, Barthélémy O, Bauersachs J, Bhatt DL, Dendale Paul, Dorobantu M, Edvardsen T, Folliguet T, Gale CP, Gilard M, Jobs A, Juni P, Lambrinou E, Lewis BS, Mehili J, Meliga E, Merkely B, Mueller C, Roffi M, Rutten FH, Sibbing D, Siontis GCM, Kastrati A, Mamas MA, Aboyans V, Angiolillo DJ, Bueno H, Bugiardini R, Byrne RA, Castelletti S, Chieffo A, Cornelissen V, Crea F, Delgado V, Drexel H, Gierlotka M, Halvorsen S, Haugaa KH, Jankowska EA, Katus HA, Kinnaird T, Klain J, Kunadian V, Landmesser U, Leclercq C, Lettino M, Meinila L, Mylotte D, Ndrepepa G, Omerovic E, Pedretti RFE, Petersen SE, Petronio AS, Pontone G, Popescu BA, Potpara T, Ray KK, Luciano F, Richter DJ, Shlyakhto E, Simpson IA, Sousa-Uva M, Storey RF, Touyz RM, Valgimigli M, Vranckx P, Yeh RW, Barbato E, Barthélémy O, Bauersachs J, Bhatt DL, Dendale P, Dorobantu M, Edvardsen T, Folliguet T, Gale CP, Gilard M, Jobs A, Juni P, Lambrinou E, Lewis BS, Mehili J, Meliga E, Merkely B, Mueller C, Roffi M, Rutten FH, Sibbing D, Siontis GCM. 2020 ESC Guidelines for the management of acute coronary syndromes in patients presenting without persistent ST-segment elevation. *Eur Heart J* 2021;**42**:1289–1367.
- Dewilde WJ, Oirbans T, Verheugt FW, Kelder JC, De Smet BJ, Herrman JP, Adriaenssens T, Vrolix M, Heestermaas AA, Vis MM, Tijssen JG, van't Hof AW, ten Berg JM, WOEST study investigators. Use of clopidogrel with or without aspirin in patients taking oral anticoagulant therapy and undergoing percutaneous coronary

- intervention: an open-label, randomised, controlled trial. *Lancet* 2013;**381**: 1107–1115.
5. Fiedler KA, Maeng M, Mehilli J, Schulz-Schüpke S, Byrne RA, Sibbing D, Hoppmann P, Schneider S, Fusaro M, Ott I, Kristensen SD, Ibrahim T, Massberg S, Schunkert H, Laugwitz KL, Kastrati A, Sarafoff N. Duration of triple therapy in patients requiring oral anticoagulation after drug-eluting stent implantation: the ISAR-TRIPLEx trial. *J Am Coll Cardiol* 2015;**65**:1619–1629.
 6. Gibson CM, Mehran R, Bode C, Halperin J, Verheugt FW, Wildgoose P, Birmingham M, Janus J, Burton P, van Eickels M, Korjian S, Daaboul Y, Lip GY, Cohen M, Husted S, Peterson ED, Fox KA. Prevention of Bleeding in Patients with Atrial Fibrillation Undergoing PCI. *N Engl J Med* 2016;**375**:2423–2434.
 7. Cannon CP, Bhatt DL, Oldgren J, Lip GYH, Ellis SG, Kimura T, Maeng M, Merkely B, Zeymer U, Gropper S, Nordaby M, Kleine E, Harper R, Manasse J, Januzzi JL, Ten Berg JM, Steg PG, Hohnloser SH; RE-DUAL PCI Steering Committee and Investigators. Dual antithrombotic therapy with dabigatran after PCI in atrial fibrillation. *N Engl J Med* 2017;**377**:1513–1524.
 8. Lopes RD, Heizer G, Aronson R, Vora AN, Massaro T, Mehran R, Goodman SG, Windecker S, Darius H, Li J, Averkov O, Bahit MC, Berwanger O, Budaj A, Hijazi Z, Parkhomenko A, Sinnaeve P, Storey RF, Thiele H, Vinereanu D, Granger CB, Alexander JH; AUGUSTUS Investigators. Antithrombotic therapy after acute coronary syndrome or PCI in atrial fibrillation. *N Engl J Med* 2019;**380**:1509–1524.
 9. Vranckx P, Valgimigli M, Eckardt L, Tijssen J, Lewalter T, Gargiulo G, Batushkin V, Campo G, Lysak Z, Vakaliuk I, Milewski K, Laeis P, Reimitz PE, Smolnik R, Zierhut W, Goette A. Edoxaban-based versus vitamin K antagonist-based antithrombotic regimen after successful coronary stenting in patients with atrial fibrillation (ENTRUST-AF PCI): a randomised, open-label, phase 3b trial. *Lancet* 2019;**394**: 1335–1343.
 10. Gargiulo G, Goette A, Tijssen J, Eckardt L, Lewalter T, Vranckx P, Valgimigli M. Safety and efficacy outcomes of double vs. triple antithrombotic therapy in patients with atrial fibrillation following percutaneous coronary intervention: a systematic review and meta-analysis of non-vitamin K antagonist oral anticoagulant-based randomized clinical trials. *Eur Heart J* 2019;**40**:3757–3767.
 11. Lopes RD, Hong H, Harskamp RE, Bhatt DL, Mehran R, Cannon CP, Granger CB, Verheugt FWA, Li J, Ten Berg JM, Sarafoff N, Gibson CM, Alexander JH. Safety and efficacy of antithrombotic strategies in patients with atrial fibrillation undergoing percutaneous coronary intervention: a network meta-analysis of randomized controlled trials. *JAMA Cardiol* 2019;**4**:747–755.
 12. Saglietto A, D'Ascenzo F, Errigo D, Leonardi S, Dewilde WJ, Conrotto F, Omedè P, Montefusco A, Angelini F, De Filippo O, Bianco M, Gallone G, Bruno F, Zaccaro L, Giannini F, Latib A, Colombo A, Costa F, De Ferrari GM. Antithrombotic strategies in patients needing oral anticoagulation undergoing percutaneous coronary intervention: a network meta-analysis. *Catheter Cardiovasc Interv* 2021;**97**:581–588.
 13. Angiolillo DJ, Goodman SG, Bhatt DL, Eikelboom JW, Price MJ, Moliterno DJ, Cannon CP, Tanguay JF, Granger CB, Mauri L, Holmes DR, Gibson CM, Faxon DP. Antithrombotic Therapy in Patients With Atrial Fibrillation Undergoing Percutaneous Coronary Intervention: a North American Perspective-2016 Update. *Circ Cardiovasc Interv* 2016;**9**:e004395.
 14. Lip GYH, Collet JP, Haude M, Byrne R, Chung EH, Fauchier L, Halvorsen S, Lau D, Lopez-Cabanillas N, Lettino M, Marin F, Obel I, Rubboli A, Storey RF, Valgimigli M, Huber K; ESC Scientific Document Group. 2018 Joint European consensus document on the management of antithrombotic therapy in atrial fibrillation patients presenting with acute coronary syndrome and/or undergoing percutaneous cardiovascular interventions: a joint consensus document of the European Heart Rhythm Association (EHRA), European Society of Cardiology Working Group on Thrombosis, European Association of Percutaneous Cardiovascular Interventions (EAPCI), and European Association of Acute Cardiac Care (ACCA) endorsed by the Heart Rhythm Society (HRS), Asia-Pacific Heart Rhythm Society (APHRS), Latin America Heart Rhythm Society (LAHRS), and Cardiac Arrhythmia Society of Southern Africa (CASSA). *Europace* 2018;**21**:192–193.
 15. Yasuda S, Kaikita K, Akao M, Ako J, Matoba T, Nakamura M, Miyauchi K, Hagiwara N, Kimura K, Hirayama A, Matsui K, Ogawa H; AFIRE Investigators. Antithrombotic therapy for atrial fibrillation with Stable coronary disease. *N Engl J Med* 2019;**381**: 1103–1113.
 16. Bhatt DL, Kaski JC, Delaney S, Alasnag M, Andreotti F, Angiolillo DJ, Ferro A, Gorog DA, Lorenzatti AJ, Mamas M, McNeil J, Nicolau JC, Steg PG, Tamargo J, Tan D, Valgimigli M. Results of an international crowdsourcing survey on the treatment of non-ST segment elevation ACS patients at high-bleeding risk undergoing percutaneous intervention. *Int J Cardiol* 2021;**337**:1–8.
 17. Jortveit J, Pripp AH, Langørgen J, Halvorsen S. Poor adherence to guideline recommendations among patients with atrial fibrillation and acute myocardial infarction. *Eur J Prev Cardiol* 2019;**26**:1373–1382.
 18. Connolly S, Pogue J, Hart R, Pfeffer M, Hohnloser S, Chrolavicius S, Pfeffer M, Hohnloser S, Yusuf S. Clopidogrel plus aspirin versus oral anticoagulation for atrial fibrillation in the Atrial Fibrillation Clopidogrel Trial with Irbesartan for prevention of Vascular Events (ACTIVE W): a randomised controlled trial. *Lancet* 2006;**367**: 1903–1912.
 19. Urban P, Mehran R, Collier R, Angiolillo DJ, Byrne RA, Capodanno D, Cuisset T, Cutlip D, Eerdmans P, Eikelboom J, Farb A, Gibson CM, Gregson J, Haude M, James SK, Kim HS, Kimura T, Konishi A, Laschinger J, Leon MB, Magee PFA, Mitsutake Y, Mylotte D, Pocock S, Price MJ, Rao SV, Spitzer E, Stockbridge N, Valgimigli M, Varenne O, Windhoevel U, Yeh RW, Krucoff MW, Morice MC. Defining high bleeding risk in patients undergoing percutaneous coronary intervention: a consensus document from the Academic Research Consortium for High Bleeding Risk. *Eur Heart J* 2019;**40**:2632–2653.
 20. Urban P, Meredith IT, Abizaid A, Pocock SJ, Carrié D, Naber C, Lipiecki J, Richardt G, Iñiguez A, Brunel P, Valdes-Chavarri M, Garot P, Talwar S, Berland J, Abdellou M, Eberli F, Oldroyd K, Zambahari R, Gregson J, Greene S, Stoll HP, Morice MC; LEADERS FREE Investigators. Polymer-free drug-coated coronary stents in patients at high bleeding risk. *N Engl J Med* 2015;**373**:2038–2047.
 21. Valgimigli M, Patialiakas A, Thury A, McFadden E, Colangelo S, Campo G, Tebaldi M, Ungi I, Tondi S, Roffi M, Menozzi A, de Cesare N, Garbo R, Meliga E, Testa L, Gabriel HM, Airolidi F, Ferlini M, Liistro F, Dellavalle A, Vranckx P, Briguori C; ZEUS Investigators. Zotarolimus-eluting versus bare-metal stents in uncertain drug-eluting stent candidates. *J Am Coll Cardiol* 2015;**65**:805–815.
 22. Varenne O, Cook S, Sideris G, Kedev S, Cuisset T, Carrié D, Hovasse T, Garot P, El Mahmoud R, Spaulding C, Helft G, Diaz Fernandez JF, Brugaletta S, Pinar-Bermudez E, Mauri Ferre J, Commeau P, Teiger E, Bogaerts K, Sabate M, Morice MC, Sinnaeve PR; SENIOR investigators. Drug-eluting stents in elderly patients with coronary artery disease (SENIOR): a randomised single-blind trial. *Lancet* 2018;**391**:41–50.