

Histopathology of Head and Neck Lymphomas in Ibadan

Abstract

Background: Lymphomas are a heterogeneous group of tumors of lymphoid tissue in which there is a malignant proliferation of cells of the lymphatic system. They are the most frequent nonepithelial malignancy in the head and neck region. **Objectives:** The aim of this study was to evaluate the histological pattern of the disease in the head and neck region and trends in presentation seen in our center. **Materials and Methods:** This was a retrospective study of cases of head and neck lymphoma (HNL) seen in the Pathology Department of the University College Hospital Ibadan, Nigeria over a period of 37 years (1981–2017). Information extracted from the records included the sociodemographics of the patients, tumor location, and histological type among others. Data were analyzed and results were presented as frequencies and percentages. **Results:** There were a total of 373 cases of histologically and/or cytologically diagnosed HNL seen during the study period (an average of 10 cases per year). The mean age of patients was 33.5 ± 21.9 years with male:female ratio of 1.6:1. Most HNL were non-Hodgkin's lymphomas (NHL), accounting for 91% of cases. Nodal disease was seen in 39% of cases. The bone (prominently, the jaws) predominated (25%) in extranodal lesions. Burkitt's lymphoma was the most common specific subtype of NHL, occurring in 25.5% of cases. **Conclusion:** There has been an apparent upward trend in the prevalence of HNL over the past four decades, although other parameters such as age and sex predilection appear unaffected. Factors responsible for this trend need to be interrogated and ascertained.

Keywords: Head and neck, Hodgkin lymphoma, lymphoma, non-Hodgkin lymphoma

Introduction

Lymphomas comprise a diverse group of malignancies affecting the lymphoreticular system. They originate from cells of the immune system at different stages of their differentiation and eventually result in varying histology, immunophenotypes, genetic abnormalities, and clinical presentations.^[1]

Lymphomas are the most frequent nonepithelial malignant tumors in the head and neck region and they can present as nodal disease, extranodal, or a combination of both.^[2] They are traditionally classified into Hodgkin's and Non-Hodgkin's. The head and neck region is the second most frequent site for extranodal lymphomas second only to the gastrointestinal tract and represents about 5% of malignant neoplasms of the head and neck.^[1,3,4] The World Health Organization (WHO) 2008 classification identified six main groups of lymphomas: precursor B-cell and NK/T-cell lymphoma, mature B-cell lymphoma, mature NK/T-cell lymphoma, post-transplantation lymphoproliferative disorders, Hodgkin's

lymphoma, and neoplasms of histiocytic and dendritic cells.^[5]

While there have been some reports regarding the prevalence and distribution of lymphomas in Ibadan Nigeria, the aim of this study was to review cases of lymphomas within the head and neck region over a period, in the light of previous reports.

Materials and Methods

The review was conducted in accordance with the ethical standards laid down in the 1964 Helsinki Declaration and its later amendments. Records were retrieved from the Cancer Registry in the Department of Pathology of the University College Hospital Ibadan over a period of 37 years (1981–2017). Data including the demographic, clinical, and histological diagnosis for each patient were retrieved. Other variables included the age of patient, gender, site involved, type of lymphoma, and final histological diagnosis. The histopathological classification was done according to the 2008 WHO classification of hematopoietic and lymphatic system tumors and aided immunohistochemistry. Data were analyzed using the Statistical Package for

**Mustapha A. Ajani^{1,2},
Ifeanyichukwu D. Nwanji¹,
Folaranmi O. Olaniran³,
Gabriel O. Ogun^{1,2},
Clement A. Okolo^{1,2},
Victor I. Akinmoladun³**

¹Department of Pathology, University College Hospital,

²Department of Pathology, College of Medicine, University of Ibadan, ³Department of Oral and Maxillofacial Surgery, College of Medicine, University of Ibadan and University College Hospital, Ibadan, Oyo state, Nigeria

Received: 10-Feb-2022

Accepted: 08-Mar-2022

Published: 04-May-2022

Address for correspondence:

Dr. Mustapha Akanji Ajani,
Department of Pathology,
College of Medicine, University
of Ibadan and University College
Hospital, Ibadan, Oyo state,
Nigeria.
E-mail: ajanimustapha42@
gmail.com

Access this article online

Website:

www.jwacs-jcoac.org

DOI: 10.4103/jwas.jwas_39_22

Quick Response Code:



How to cite this article: Ajani MA, Nwanji ID, Olaniran FO, Ogun GO, Okolo CA, Akinmoladun VI. Histopathology of head and neck lymphomas in Ibadan. J West Afr Coll Surg 2020;10:40-4.

This is an open access journal, and articles are distributed under the terms of the Creative Commons Attribution-NonCommercial-ShareAlike 4.0 License, which allows others to remix, tweak, and build upon the work non-commercially, as long as appropriate credit is given and the new creations are licensed under the identical terms.

For reprints contact: reprints@medknow.com

Social Sciences (SPSS), version 23. Tests of association were done using chi-square test and value of statistical significance set at $P < 0.05$. Data were presented as tables and percentages, where applicable.

Results

There were 373 histologically/cytologically confirmed cases of head and neck lymphomas (HNLs) during the period of the study, averaging 10 cases per year. Ages ranged from 1 year to 99 years with a mean of 33.5 (SD± 21.9) years. The 10–19-year age group was the most frequently affected

Table 1: Age distribution of head and neck lymphomas

Age in years	Hodgkin lymphoma	Non-Hodgkin lymphoma	P Value
0–9	1	52	0.233
10–19	11	69	
20–29	8	38	
30–39	5	44	
40–49	2	40	
50–59	5	39	
60–69	3	30	
70–79	1	22	
80–89	0	2	
90–99	0	1	
Total	36	337	

age group [Table 1]. There were 227 males and 146 females giving a male:female ratio of 1.6:1.

A total of 337 (90.1%) cases of NHL and 36 (9.9%) cases of Hodgkin lymphoma were recorded [Figure 1]. Mature B-cell lymphomas accounted for the majority of cases (42.6% of total) with mature T-cell neoplasms accounting for 2.9% of cases. Burkitt’s lymphoma accounted for the majority of specific cases (95, 25%) followed by diffuse large B-cell lymphoma (36, 10%) [Figure 2] and small lymphocytic lymphoma (17, 5%). In 42.9% of cases, NHL could not be further characterized by immunohistochemistry. There was an association between gender and the histological variant of disease ($P = 0.007$) with males showing a particular predisposition to T-cell lymphomas and precursor neoplasms [Table 2].

With respect to location, extra-nodal disease predominated, seen in 228 (61.1%) with nodal lesions recorded in 145 (38.9) cases. Hodgkin lymphoma [Figure 3] showed a predilection for lymph node involvement as compared to NHL and the association between location and category of disease was significant ($P = 0.001$) [Table 3]. The most frequent site for extra-nodal disease was the mandible, particularly for cases diagnosed as Burkitt lymphoma, accounting for 94 (25.2%) cases. This was followed by the nasopharynx (67, 18%) and the oral cavity 53 (14.2%) of all cases.

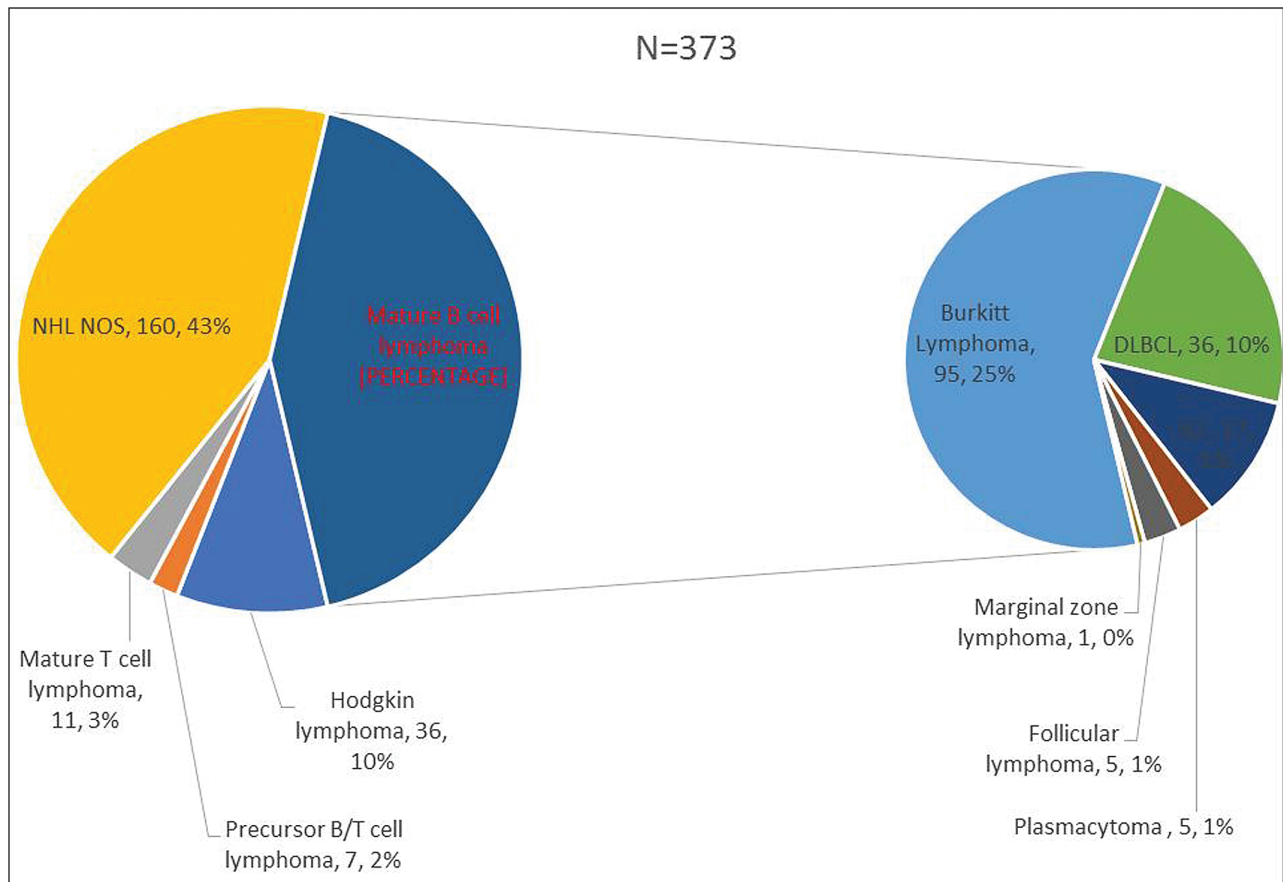


Figure 1: Histological categorization of head and neck lymphomas from 1981 to 2017

There was a trend towards increasing number of cases of HNL diagnosed during the period of the study with 7 cases (1.9%) diagnosed in 1981–1990, 81 cases (21.7%) in 1991–2000, 163(43.7%) cases 2001–2010 and 122 (32.7%) cases within the 2011–2017 period ($R = 0.69$) [Figure 4].

Discussion

Lymphomas are a heterogeneous group of malignancies involving the lymphoreticular system. It accounted for 0.9% of 47,177 surgical biopsies and 1.2% of 17,868 cytology specimens processed in the Department of Pathology, University College Hospital in a review carried out in 2011.^[6] Reports from developed countries have shown that lymphomas constitute about 5% of all head and neck malignancies.^[7,8] A study from Ibadan, Nigeria,^[9] reported that lymphomas constituted 17.5% of all head and neck cancers with a gender ratio of 1.6:1, and a mean age of 35.1 (standard deviation [SD]

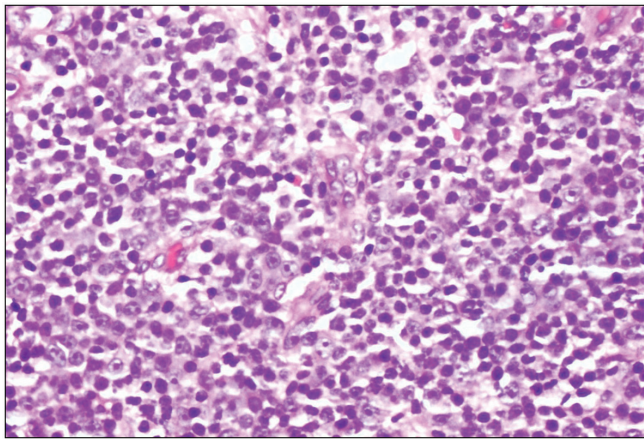


Figure 2: Photomicrograph showing diffuse large B-cell lymphoma (hematoxylin and eosin stains, x400)

± 20.6) years.^[9] The gender ratio and the mean age in our study are concordant with that study.

Both HL and NHL have a wide age range.^[10] While HL has two peaks: 15–35 years and after 50 years,^[11] NHL [Figure 5] affects individuals of any age and its incidence increases throughout life.^[12] However, it is more common in adulthood and peaks in the seventh decade of life.^[11] The peak age of occurrence of NHL and HL in this study was the second decade of life [Table 1].

Lymphomas usually have a slight male predominance^[3,7,13] However, studies have found no sex predilection.^[14,15] Males were more affected with lymphoma in this study with a male-to-female ratio of 1.6: 1 [Table 2]. NHL has also been reported to have a male predominance with the exception of MALT lymphoma which has a female predominance.^[16] This was also corroborated in this study. In our review, the male gender showed predominance in all the NHL subtypes diagnosed except the SLL and follicular lymphoma histological subtype of NHL which showed female predominance.

HL [Figure 6] has an overall male predominance; however, the variants are associated with different age groups and have specific gender predominance.^[16] In a review of 30 cases of HLs in Lagos Nigeria, nodular sclerosis HL predominated, followed by mixed cellularity variant. Most patients were young with a mean age of 37 years, with an M:F ratio of 2.3:1.^[17] In our review, HL was predominant in males with a male to female ratio of 2:1.

NHLs are the prevalent lymphomas in the HN region, representing about 75% of lymphomas in this area.^[18] In this study, NHLs accounted for 350 (91%) of the cases. B-cell type NHLs are especially common in the head and neck. In

Table 2: Gender distribution of head and neck lymphomas

Histological diagnosis	Gender		P Value
	Male	Female	
Hodgkin lymphoma	24 (66.7%)	12 (33.3%)	0.007
Precursor B/T-cell lymphomas	6 (85.7%)	1 (14.3%)	
Mature B-cell lymphoma	82 (51.6%)	77 (48.4%)	
Mature T-cell lymphoma	10 (90.9%)	1 (9.1%)	
Non-Hodgkin lymphoma NOS	105 (65.6%)	55 (34.4%)	
Total	227	146	

Table 3: Distribution of locations of head and neck lymphomas

Location	Hodgkin's lymphoma	Non-Hodgkin's lymphoma	P Value
Bone	0 (0%)	94 (100%)	0.001
Lymph nodes	29 (20%)	116 (80%)	
Mouth	1 (98.1%)	52 (1.9%)	
Nasopharynx	6 (9%)	61 (91%)	
Eye	0 (0%)	11 (100%)	
Soft tissue	0 (0%)	3 (100%)	
Total	36	337	

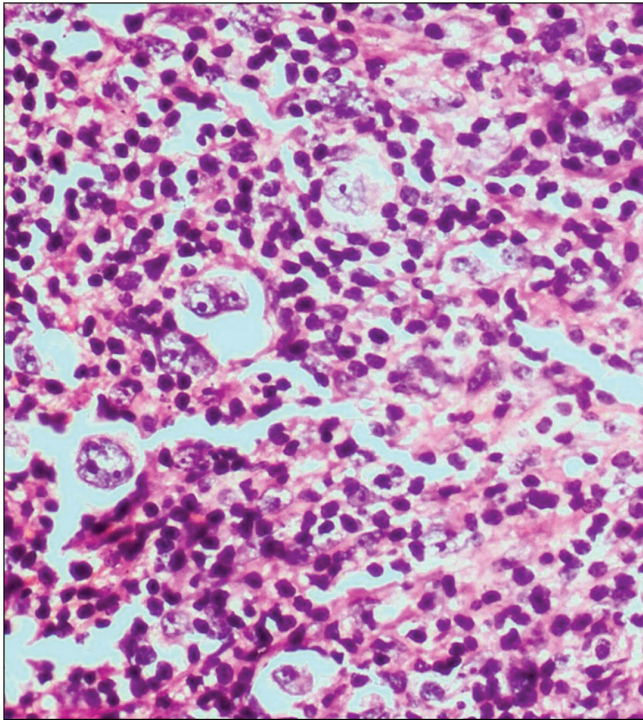


Figure 3: Photomicrograph showing classical Hodgkin lymphoma (hematoxylin and eosin stains, x400)

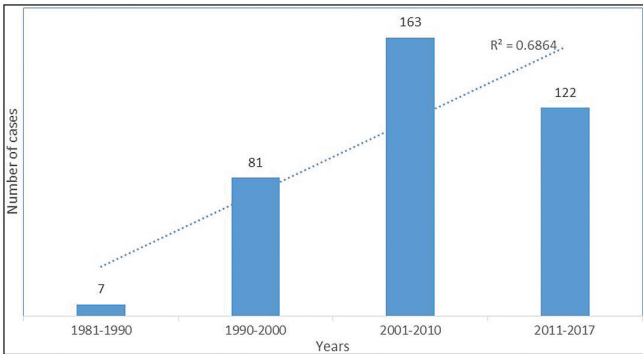


Figure 4: Time trends in the diagnosis of head and neck lymphomas

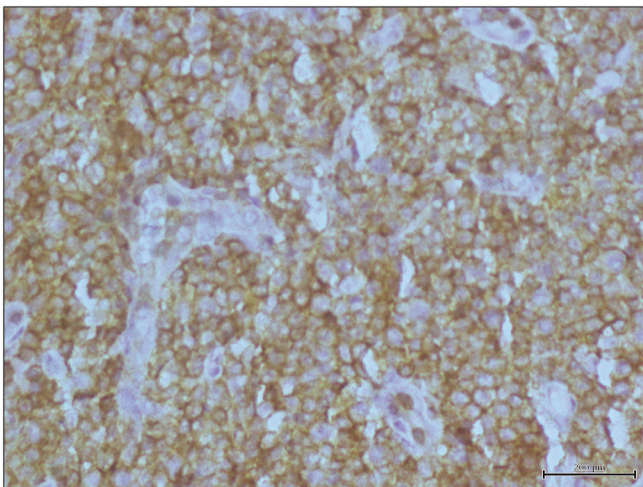


Figure 5: Photomicrograph showing diffuse CD45 membrane positivity in non-Hodgkin lymphoma (immunohistochemical stain, x400)

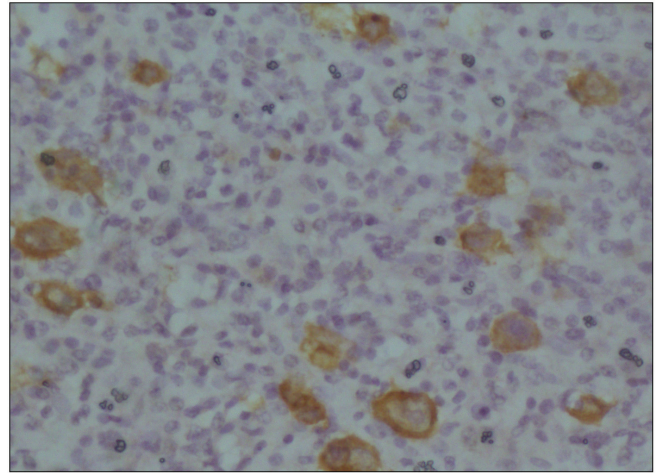


Figure 6: Photomicrograph showing CD30 membrane positivity in Hodgkin lymphoma (immunohistochemical stain, x400)

this review, Burkitt's lymphoma, a B-cell type NHL was the most prevalent NHL seen.

Lymphomas could be nodal or extranodal. Extranodal NHLs are more prevalent than extranodal HLs in the head and neck.^[19] This study demonstrated similar findings with extranodal head and neck NHLs being three times more common than extranodal HLs ($P < 0.001$). Oluwasola *et al.*^[6] reported the jaw as the most common site of extranodal disease, apparently due to cases of Burkitt's reported in the study site, this was also observed in this review. The most common extranodal location documented in the literature for the head and neck region is the Waldeyer's ring.^[8,12,13] Within the ring, the tonsil is found to be the most common subtype.^[11,12]

Anatomic sites have also been seen to show specific gender predominance, for example, the salivary glands and thyroid gland are said to show a predominance of NHL in females.^[20] This could be due to the fact that MALT lymphoma is a common subtype in both these sites.^[19] Majority of extranodal NHLs are of B-cell lineage, for uncertain reasons.^[13] Various authors have found DLBCL to be the most common NHL subtype of the head and neck region.^[7,8,12] In this study, diffuse large B-cell lymphoma was the second most predominant specific subtype of NHL, after Burkitt's lymphoma.

While there appears to be an increase in cases reported over the years, it could not be ascertained if this is an actual increase in disease incidence or due to other factors such as improved competence in diagnosis. Other considerations such as changing risk profiles could not be ascertained due to the retrospective nature of this review.

NHL involvement of the nasopharynx and mouth accounted for more than a third of cases. These sites are recognized as primary sites for squamous cell carcinoma of the head and neck. The frequent presence of NHL within these extra-nodal locations should raise clinical suspicion when evaluating poorly differentiated tumors in these anatomical areas.

Conclusion

This study highlights the valuable role histology still plays in diagnosing and subtyping lymphomas in resource-limited settings. In a majority of cases, immunohistochemistry was not done most commonly due to cost. This explains the disproportionate increase in the NHL not otherwise specified category in this study. The predominance of NHL in extra-nodal sites buttresses the fact that NHLs should be considered when evaluating extra-nodal masses in the head and neck location among Nigerian patients.

Financial support and sponsorship

Nil.

Conflicts of interest

There are no conflicts of interest.

References

1. Agrawal MG, Agrawal SM, Kambalimath DH. Non-Hodgkins lymphoma of maxilla: A rare entity. *Natl J Maxillofac Surg* 2011;2:210-3.
2. Zini A, Atia-Joachim D, Sgan-Cohen HD, Lavie D, Czerninski R. Trends and distribution of oral and pharyngeal lymphoma in Israel. *Oral Dis* 2012;18:700-6.
3. Bussu F, Hohaus S, Bastanza G, Bozzoli V, Tisi MC, Martini M, *et al.* Clinical and prognostic features of lymphomas arising in the head and neck region: Our experience of preferential association of different histotypes with various sites of origin in ninety patients. *Clin Otolaryngol* 2013;38:248-53.
4. Swerdlow SH, Campo E, Harris NL, Jaffe ES, Pileri SA, Stein H, *et al.* WHO Classification of Tumours of Haematopoietic and Lymphoid Tissues. Lyon: IARC Press; 2008.
5. Salplahta D, Comănescu MV, Anghelina F, Ioniță E, Mogoantă CA, Anghelina L. Non-Hodgkin lymphomas of Waldeyer's ring. *Rom J Morphol Embryol* 2012;53:1057-60.
6. Oluwasola AO, Olaniyi JA, Otegbayo JA, Ogun GO, Akingbola TS, Ukah CO, *et al.* A fifteen-year review of lymphomas in a Nigerian tertiary healthcare centre. *J Health Popul Nutr* 2011;29:310-6.
7. Scherfler S, Freier K, Seeberger R, Bacon C, Hoffmann J, Thiele OC. Cranio-maxillofacial non-Hodgkin's lymphoma: Clinical and histological presentation. *J Craniomaxillofac Surg* 2012;40:e211-3.
8. Boring CC, Squires TS, Tong T. Cancer statistics, 1993. *Ca Cancer J Clin* 1993;43:7-26.
9. Adisa AO, Adeyemi BF, Oluwasola AO, Kolude B, Akang EE, Lawoyin JO. Clinico-pathological profile of head and neck malignancies at University College Hospital, Ibadan, Nigeria. *Head Face Med* 2011;7:9.
10. Takano T, Miyauchi A, Matsuzuka F, Yoshida H, Kuma K, Amino N. Diagnosis of thyroid malignant lymphoma by reverse transcription-polymerase chain reaction detecting the monoclonality of immunoglobulin heavy chain messenger ribonucleic acid. *J Clin Endocrinol Metab* 2000;85:671-5.
11. Mishra P, Das S, Kar R, Jacob SE, Basu D. Primary extranodal non-Hodgkin lymphoma: A 3-year record-based descriptive study from a tertiary care center in southern India. *Indian J Pathol Microbiol* 2015;58:296-300.
12. Farman AG, Nortje CJ, Wood RE. Oral and Maxillofacial Diagnostic Imaging. Missouri: Mosby Inc; 1993. p. 297-301.
13. Etemad-Moghadam S, Tirgary F, Keshavarz S, Alaeddini M. Head and neck non-Hodgkin's lymphoma: A 20-year demographic study of 381 cases. *Int J Oral Maxillofac Surg* 2010;39:869-72.
14. Kolokotronis A, Konstantinou N, Christakis I, Papadimitriou P, Matiakis A, Zaraboukas T, *et al.* Localized B-cell non-Hodgkin's lymphoma of oral cavity and maxillofacial region: A clinical study. *Oral Surg Oral Med Oral Pathol Oral Radiol Endod* 2005;99:303-10.
15. van der Waal RI, Huijgens PC, van der Valk P, van der Waal I. Characteristics of 40 primary extranodal non-Hodgkin lymphomas of the oral cavity in perspective of the new WHO classification and the international prognostic index. *Int J Oral Maxillofac Surg* 2005;34:391-5.
16. Kemp S, Gallagher G, Kabani S, Noonan V, O'Hara C. Oral non-Hodgkin's lymphoma: Review of the literature and world health organization classification with reference to 40 cases. *Oral Surg Oral Med Oral Pathol Oral Radiol Endod* 2008;105:194-201.
17. Kolawole, H. The clinicopathologic features of Hodgkin lymphoma in Lagos, Nigeria: An update on biology and histopathology diagnosis. *Am J Clin Pathol* 2018;150:S102-3.
18. Huh J. Epidemiologic overview of malignant lymphoma. *Korean J Hematol* 2012;47:92-104.
19. Vega F, Lin P, Medeiros LJ. Extranodal lymphomas of the head and neck. *Ann Diagn Pathol* 2005;9:340-50.
20. Beasley MJ. Lymphoma of the thyroid and head and neck. *Clin Oncol (R Coll Radiol)* 2012;24:345-51.