

## Case Report

### Adenomatoid hyperplasia of lower lip

Gaganjot Kaur Sharma<sup>1</sup>, Manish Sharma<sup>1</sup>, Srinivas S. Vanaki<sup>2</sup>

<sup>1</sup>Department of Oral and Maxillofacial Pathology, Guru Nanak Dev Dental College, Sunam, Punjab, <sup>2</sup>Department of Oral and Maxillofacial Pathology, PMNM Dental College, Bagalkot, Karnataka, India

#### ABSTRACT

Adenomatoid hyperplasia (AH) is an uncommon, non-neoplastic swelling on the palate caused due to hyperplasia of the mucinous acini. The lesion clinically presents as a sessile tumor-like nodule resembling pleomorphic adenoma. Histopathologic findings include lobules of enlarged mucinous acini which are filled with secretory granules. The nuclei are squeezed to the basal portions, associated with focal inflammation and ductal dilatation, and a history of trauma is often elicited. Here, we report a rare case of AH of the lower lip in a 20-year-old male patient, which mimics a mucous retention cyst or mucocele.

**Key Words:** Adenomatoid hyperplasia, minor salivary glands, mucocele

Received: April 2011

Accepted: July 2011

**Address for correspondence:**  
Dr. Gaganjot Kaur Sharma,  
Department of Oral  
Pathology, Guru Nanak Dev  
Dental College, Sunam-148  
028, Punjab, India.  
E-mail: drmanishsharma2007@  
gmail.com

#### INTRODUCTION

Adenomatoid hyperplasia (AH) is a non-neoplastic enlargement of minor salivary glands. This unusual entity was not well delineated in the literature until described by Giansanti *et al* in 1971.<sup>[1]</sup> Clinically, the lesion presents as an asymptomatic, firm, sessile and nontender, nodular mass that is not ulcerated.<sup>[2,3]</sup> Very few cases of AH have been reported in the literature and most of them were reported to be located in the palate, with a frequency of 67 out of 72 cases as reported by Giansanti (2 cases), Arafat (10 cases), Buchner *et al* (40 cases) and Barret *et al* (20 cases).<sup>[3-6]</sup> Other sites like buccal mucosa, upper lip, retromolar region and lower lip were also found to be affected. Previously, the lesion had been reported as benign minor salivary gland hypertrophy, salivary glandular hyperplasia, adenomatous hyperplasia of minor salivary glands and AH.<sup>[7]</sup> The condition has been regarded as idiopathic, but the role of chronic

trauma has been suggested. It is not associated with factors causing major salivary gland enlargement. The purpose of this report is to present a case of AH of lower lip mucosa and to familiarize the clinicians with this uncommon pathology of minor salivary glands, which should be differentiated from other non-neoplastic (mucocele) and neoplastic lesions (adenoma) of minor salivary glands.

#### CASE REPORT

A 20-year-old male patient presented to P. M. Nadagouda Memorial Dental College with the chief complaint of painless soft tissue swelling in the lower lip [Figure 1]. The history of present illness consisted of the development of a swelling on the lower lip 6 months ago, which had gradually increased to the present size of 2 cm. The patient gave a history of associated trauma at the same region 1 year ago. On clinical examination, a well-circumscribed, single, oval, sessile, soft to firm and nontender swelling was observed on the left side of labial mucosa of lower lip. There was no associated pain and paraesthesia and the color of the overlying mucosa was normal. The clinical diagnosis of mucocele was rendered. The treatment plan consisted of the surgical removal of the lesion by placing a vertical incision, then splitting the overlying mucosa and resecting the lesion from the base to decrease the chances of recurrence.

#### Access this article online

Quick Response Code:



Website: [www.drj.ir](http://www.drj.ir)

DOI: 10.4103/1735-3327.86047

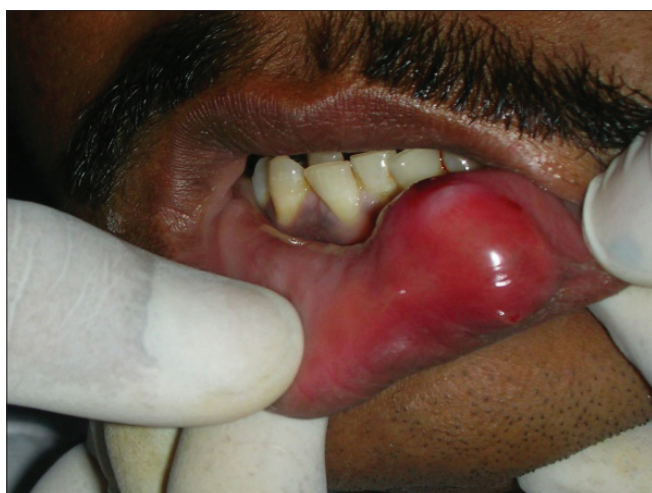Sutures were placed and the excised lesion was sent for histopathologic examination. The differential diagnoses included lymphangioma, hemangioma, AH, benign lymphoepithelial lesion and minor salivary gland neoplasms.

At low power of OLYMPUS CX41 light microscope, hematoxylin and eosin stained tissue section of 5  $\mu$ m thickness showed two large, well-circumscribed lobules of normal appearing mucinous acini and ducts with intervening connective tissue septae [Figures 2 and 3]. Mucinous acini were larger than normal and distended. The filled mucin showed a bubbly appearance. Myoepithelial cells surrounding the acini were also evident. No dysplastic features were observed. Mild chronic inflammatory infiltration was also noticed which consisted of plasma cells

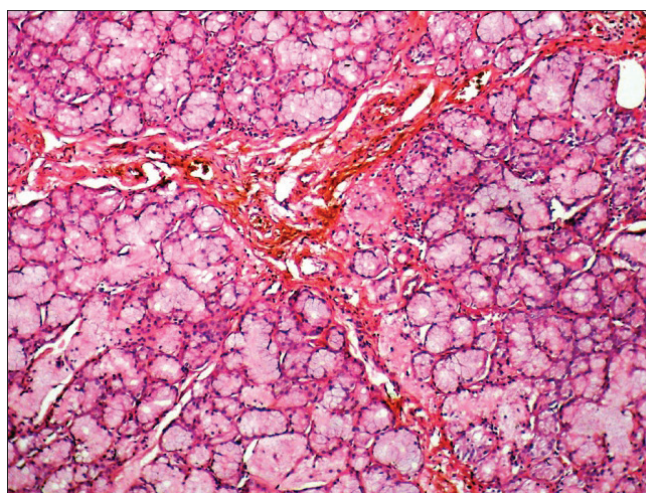
and lymphocytes primarily. Mucicarmine stained histopathologic section of the lesion showed distended mucinous acini filled with mucin [Figure 4]. Mucicarmine stain helps in precise localization of accumulated intracellular and extracellular mucin content. The lesion healed without any complication, and the patient was recalled after 6 months and checked for recurrence of the lesion.

## DISCUSSION

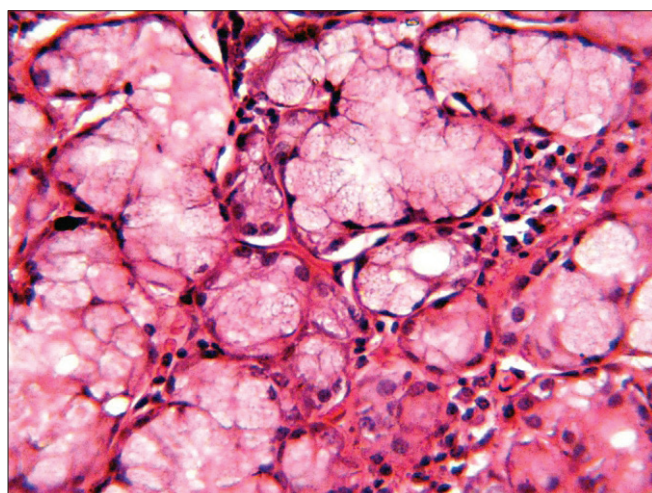
AH is an uncommon lesion of minor salivary glands. The lesion has a predilection for the palatal region and predisposition for males. The average age of onset is reported to be 39 years in the previous series, but Buchner *et al* reported a range of 7–79 years for



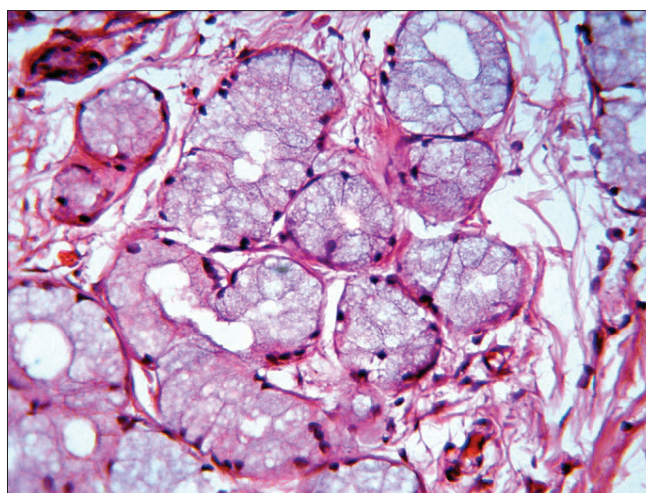
**Figure 1:** A well-defined submucosal nodular swelling of lower lip in a 20-year-old male patient



**Figure 2:** Aggregation of large mucinous acini with intralobular duct. (Hematoxylin and Eosin stain at 10x magnification)



**Figure 3:** Dilated mucinous acini filled with mucin and peripheral myoepithelial cells. (Hematoxylin and Eosin stain at 40x magnification)



**Figure 4:** Mucicarmine stained section showing dilated mucinous acini. (Mucicarmine stain at 40x magnification)

this lesion.<sup>[5]</sup> The clinical significance of this entity lies in its presentation as salivary gland tumor, which has resulted in the description of the lesion as “sheep in wolf’s clothing”.<sup>[6]</sup> Clinically, the lesion appears to be a circumscribed, sessile, soft to firm, palpable and nontender mass. Due to its presence at the palatal site, it can be misdiagnosed as benign or malignant salivary gland tumor, primarily mucoepidermoid carcinoma, or other soft tissue tumors like lymphangioma, hemangioma and neurofibroma.<sup>[3]</sup> Misinterpretation could result in an inappropriate treatment. The present case reported a soft tissue swelling in left lower lip mucosa, which clinically appeared as a mucocele. The history of trauma was also associated. Lower lip is the most favorable site for the mucocele and it generally represents itself with bluish surface, but not all the time,<sup>[8]</sup> as it was not present in our case where the surface mucosa was normal.

Microscopically, normal appearing mucin filled acini and intercalated ducts were found in lobular arrangement supported by connective tissue septae. Both glandular hyperplasia and hypertrophy were present. Mucinous acini were large, crowded and distended.<sup>[3]</sup> Myoepithelial cells were located peripheral to the mucinous acini and mild degree of chronic inflammatory infiltrate was also evident. Barret and Speight have reported focal fibrosis, another prominent feature in their case series, which was absent in the present case.<sup>[6]</sup> Mucin spillage was not seen in any field that is considered as the hallmark of mucocele. Simple adenoma consists of epithelial cells arranged in various forms, i.e. ductal, tubular, cystic, trabecular or basal cell adenomatous masses.<sup>[4]</sup> All aforementioned glandulo-epithelial features were missing in the present case. Low-grade mucoepidermoid carcinoma had been ruled out by the absence of sheets of epithelial cells and intracellular epithelial mucin and also the site was not favorable for mucoepidermoid carcinoma.<sup>[3]</sup>

The etiological factor for this condition is unknown. The causes for asymptomatic, noninflammatory, non-neoplastic swellings of major salivary gland include

endocrine disturbances, nutritional deficiencies, drugs and neuropathies; none of these seems to involve in the minor salivary glands enlargement. Buchner *et al.*,<sup>[5]</sup> suggested a probable role of chronic irritations like local trauma, smoking and prosthesis in this reactive hyperplasia. Our case also had a history of trauma to the lower lip. The lesion is unlikely to be described as hamartoma as it develops in people in their 30s.

## CONCLUSION

AH of lower lip is a rare entity and should be considered in the differential diagnosis of mucocele and other non-neoplastic and neoplastic lesions of minor salivary glands. The consideration of chronic trauma in the etiology of this entity may be appealing as histology marked the reactive hyperplasia of minor salivary gland.

## REFERENCES

1. Giansanti JS, Waldron CA. Intraoral mucinous minor salivary gland lesions presenting clinically as tumors. *Oral Surg Oral Med Oral Pathol* 1971;32:918-22.
2. Devildos LR, Langlois CC. Minor salivary gland lesion presenting clinically as tumor. *Oral Surg Oral Med Oral Pathol* 1976;41:657-9.
3. Ellis GL, Auclair PL, Gnepp DR. Surgical pathology of the salivary glands. Philadelphia: Saunders; 1991. p. 18-21.
4. Arafat A, Brannon RB, Ellis GL. Adenomatoid hyperplasia of mucous salivary glands. *Oral Surg Oral Med Oral Pathol* 1981;52:51-5.
5. Buchner A, Merrell PW, Carpenter WM, Leider AS. Adenomatoid hyperplasia of minor salivary glands. *Oral Surg Oral Med Oral Pathol* 1991;71:583-7.
6. Barret AW, Speight PM. Adenomatoid hyperplasia of oral minor salivary glands. *Oral Surg Oral Med Oral Pathol Oral Radiol Endod* 1995;79:482-7.
7. Petri WH, Carr RF, Khan CS. Adenomatoid hyperplasia of the palate. *J Oral Maxillofac Surg* 1992;51:310-1.
8. Bhavna G, Rajesh A, Sudha P, Mohit G. Mucocele: Two case reports. *J Oral Health Commun Dent* 2007;1:56-8.

**How to cite this article:** Sharma GK, Sharma M, Vanaki SS. Adenomatoid hyperplasia of lower lip. *Dent Res J* 2011;8:226-8.

**Source of Support:** Nil, **Conflict of Interest:** None declared.

### Announcement

#### Android App



Download  
**Android  
application**

FREE

A free application to browse and search the journal’s content is now available for Android based mobiles and devices. The application provides “Table of Contents” of the latest issues, which are stored on the device for future offline browsing. Internet connection is required to access the back issues and search facility. The application is compatible with all the versions of Android. The application can be downloaded from <https://market.android.com/details?id=comm.app.medknow>. For suggestions and comments do write back to us.