

# Combined Anterior Cruciate Ligament Repair and Anterolateral Ligament Reconstruction With a Single-Strand Gracilis Graft



Jean-Marie Fayard, M.D., Alexandre Penet, M.D., Paul-Henri Bauwens, M.D., and Mathieu Thauinat, M.D.

**Abstract:** There has been renewed interest in anterior cruciate ligament (ACL) repair procedures in the past decade. Even though ACL reconstruction is still considered the gold standard, ACL repair is an alternative in selected patients. However, the risk of failure owing to isolated ACL repair remains a concern. Intra-articular augmentation has been proposed to protect the repair during the healing period. In the same way, the protective effect of anterolateral ligament reconstruction on the ACL graft is increasingly recognized. We describe a combined ACL repair and anterolateral ligament reconstruction technique with a single-strand gracilis for the intra-articular portion and as an anterolateral graft to protect the ACL repair during the healing phase.

Open primary repair of anterior cruciate ligament (ACL) ruptures was developed in the 1970s and was considered the main surgical option until the 1980s. Then, these ACL repair procedures were gradually abandoned because of reports of poor functional results and high failure rates in comparison to the emerging ACL reconstruction surgical procedure using an autograft as a substitute for the torn ACL. Feagin and Curl<sup>1</sup> reported a 53% rupture rate 5 years after ACL repair. However, other authors reported a lower failure rate in a specific group of ACL repair patients when an intra- or extra-articular anterolateral augmentation was used to protect the ACL repair.<sup>2</sup> In addition, Sherman et al.<sup>3</sup> suggested that the location of the tears could

explain these unpredictable results, with better results after open primary repair of proximal tears. Clinical outcomes could be further improved by using 2 emerging concepts: (1) the addition of a collagen-based scaffold in the notch to improve the ACL's healing potential<sup>4</sup> and (2) the positioning of an internal splint to protect the ligament biomechanically during the healing phase.<sup>5,6</sup> In this Technical Note, following these principles, we describe an arthroscopic technique for primary ACL suture repair using single-strand gracilis graft for combined intra-ligament and extra-articular anterolateral tenodesis augmentation (Video 1). Proper patient selection is crucial for the success of this technique. Surgical indications and contraindications are presented in Table 1.

## Surgical Technique

### Step 1: Patient Positioning

The patient is placed supine on the operating table. A lateral post is positioned high on the thigh at the level of the tourniquet to prevent the hip from externally rotating; a foot roll is placed distally to maintain the knee in 90° of flexion when required (Fig 1).

### Step 2: Arthroscopic Exploration

Standard anteromedial and anterolateral arthroscopic portals are created. A meticulous arthroscopic exploration is performed. Associated meniscal and/or chondral lesions are assessed and treated if required. The ACL tear is then explored and evaluated. The ACL

From Centre Orthopédique Santy, FIFA Medical Center of Excellence, Ramsay-Générale de Santé, Hôpital Privé Jean Mermoz, Lyon, France.

The authors report the following potential conflicts of interest or sources of funding: J-M.F. receives personal fees from Arthrex, outside the submitted work. M.T. receives personal fees from Arthrex, outside the submitted work. Full ICMJE author disclosure forms are available for this article online, as supplementary material.

Received December 24, 2020; accepted January 31, 2021.

Address correspondence to Mathieu Thauinat, M.D., Centre Orthopédique Santy, FIFA Medical Centre of Excellence, Hôpital Privé Jean Mermoz, Groupe Ramsay GDS, 69008 Lyon, France. E-mail: [mathieuthauinat@yahoo.fr](mailto:mathieuthauinat@yahoo.fr)

© 2021 THE AUTHORS. Published by Elsevier Inc. on behalf of the Arthroscopy Association of North America. This is an open access article under the CC BY-NC-ND license (<http://creativecommons.org/licenses/by-nc-nd/4.0/>). 2212-6287/202075

<https://doi.org/10.1016/j.eats.2021.01.041>

**Table 1.** Indications and Contraindications for Combined ACL Repair and ALL Reconstruction With Single-Strand Gracilis Graft

Indications	Contraindications
Proximal (femoral) avulsion tear (Sherman type I or II)	Midsubstance and intra-ligament ACL tear (Sherman type III or IV)
Partial ACL tear	Complete and retracted proximal tear
Proximal avulsion tear of ACL reattached to PCL	Impossible to reapproximate remnant onto femoral ACL insertion area <sup>7</sup>
Good tissue quality	Poor tissue quality
Isolated ACL tear	ACL revision surgery
Patients who participate in low- to mid-level sports	High-demand patients (intense pivoting sports)

ACL, anterior cruciate ligament; ALL, anterolateral ligament; PCL, posterior cruciate ligament.

remnant is probed to assess the tissue quality required for effective fixation of the remaining ligament on the femoral wall (Fig 2). The length and reducibility of the remnant are tested with the knee in 90° of flexion and with the knee in the figure-of-4 position using the 4 CROSS test (Figure-of-4 Cruciate Remnant Objective Assessment).<sup>7</sup> Patients with a reducible remnant and good tissue quality are eligible for ACL repair and anterolateral ligament (ALL) reconstruction with a single-strand gracilis graft.

### Step 3: Graft Harvesting and Preparation

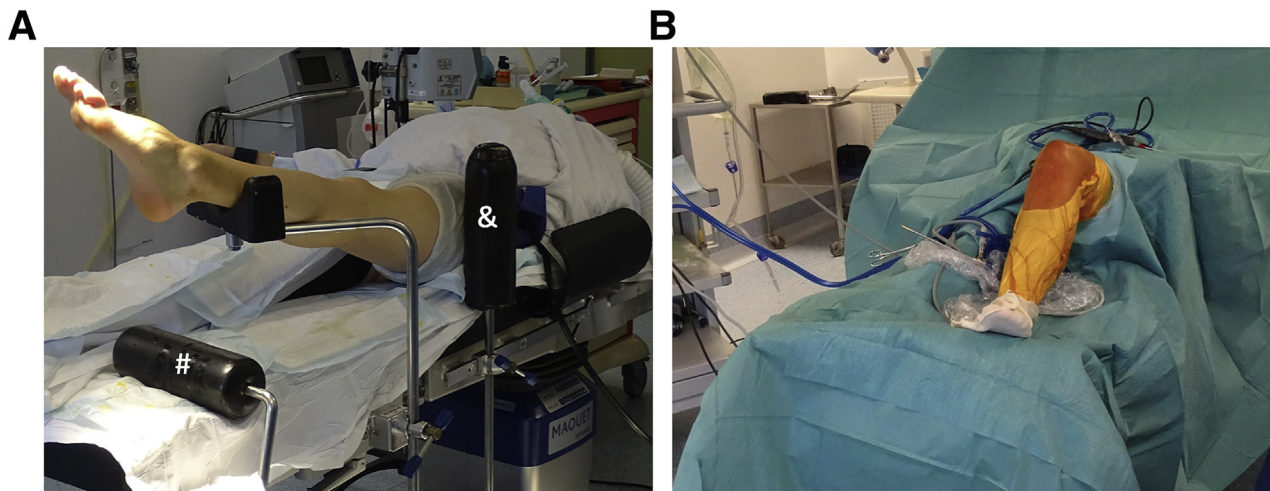
A vertical incision is made medial to the anterior tibial tuberosity. The gracilis is located and individualized from the semitendinosus tendon at its tibial insertion using a right-angled clamp. A second right-angled clamp is used to hook the accessory band of the gracilis, which is then transected to avoid premature truncation of the tendon during the stripping process. The tendon is harvested using an open tendon stripper to preserve its tibial insertion. The length of the harvested tendon is checked; the length is sufficient when the harvested tendon hangs down the tibia to the level of the medial malleolus (Fig 3). The tendon extremity is

then whipstitched over a length of 3 to 4 cm with a nonabsorbable braided No. 0 suture, which will serve as a traction suture for graft passage. If the length is not sufficient, the surgeon has 2 options: detach the tendon from its tibial insertion or perform a 1-strand ALL reconstruction technique.

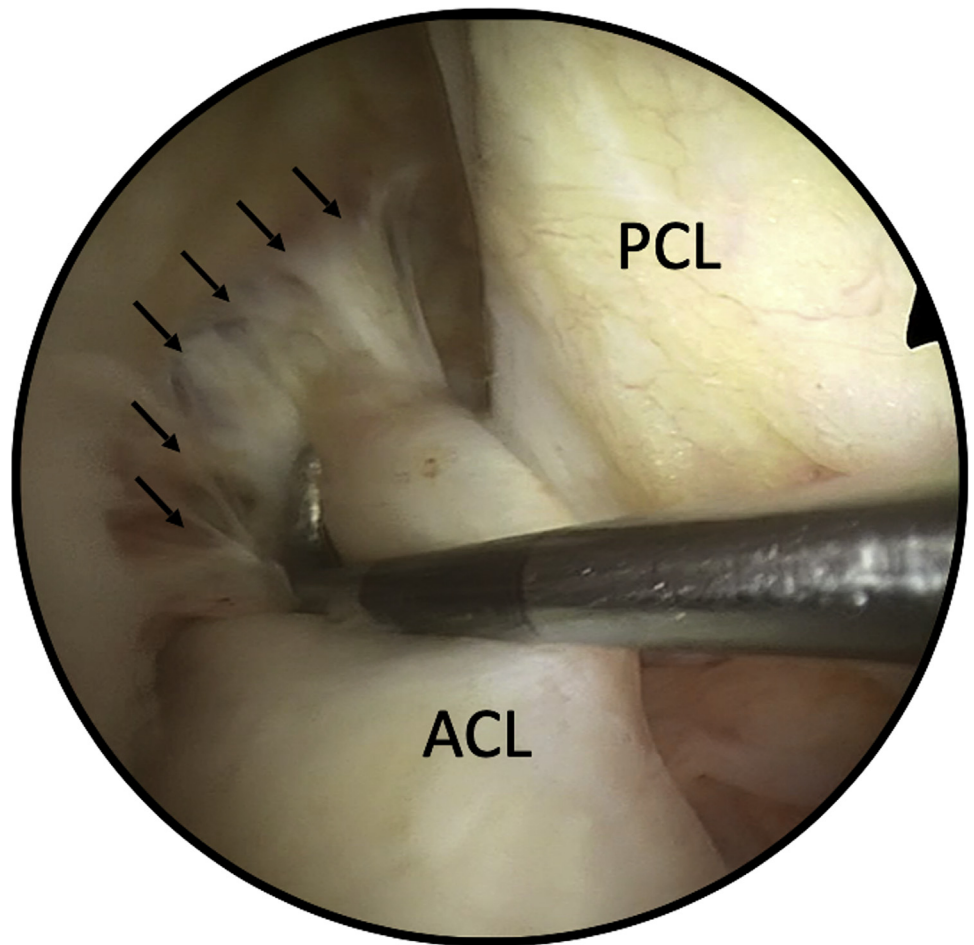
### Step 4: ALL Tibial Tunnel Drilling and Femoral Skin Incision

Three bony landmarks are palpated and marked: the fibular head and Gerdy tubercle on the tibia and the lateral epicondyle on the femur. On the tibia, 2 vertical skin incisions separated by 23 mm are made. These incisions are located 1 cm below the joint line, between the Gerdy tubercle and the fibular head. Two tunnels with 23 mm between them are drilled through the tibial incision with a 5-mm drill and then connected with a right-angled clamp. By use of a No. 2 braided suture with a large needle and a curved suture passer (Arthrex, Naples, FL), a suture loop is created by passing the suture in a retrograde manner from the anterior opening of the tunnel to its posterior opening (Fig 4).

On the femur, a small horizontal skin incision (<10 mm) is made just proximal and posterior to



**Fig 1.** Patient positioning for treatment of left knee. (A) A lateral post (ampersand) is placed high on the thigh, and a foot roll (pound sign) is secured distally on the table to maintain the knee in 90° of flexion when required. (B) Patient setup after surgical draping.



**Fig 2.** Arthroscopic view of proximal tear of anterior cruciate ligament (ACL) in right knee. The ACL has been detached from its femoral insertion; some healed residual fibers (arrows) at the femoral insertion are easily detachable with the probe. (PCL, posterior cruciate ligament.)

the lateral epicondyle. In some cases, when palpation of the lateral epicondyle is challenging, this incision can be enlarged and the iliotibial band (ITB) can be opened to confirm the lateral epicondyle's position.

#### **Step 5: ACL Tunnels and Suture of ACL Remnant**

Debridement of the notch wall is performed carefully with a 4.2-mm shaver. Microperforations of the femoral ACL insertion area are made with an awl (ChondroPick; Arthrex) to improve healing of the repaired ligament.

#### **ACL Tibial Tunnel**

On the tibial side, because the anterior ACL fibers have a curvilinear path, a slightly posterior placement of the guidewire relative to the ACL tibial stump is recommended. A 5-mm tibial tunnel is drilled over the guide pin. A 4.5-mm shaver is passed through the tibial tunnel and through the remnant to emerge at the proximal end of the ACL remnant. Placing the knee close to extension during this step will help to place the

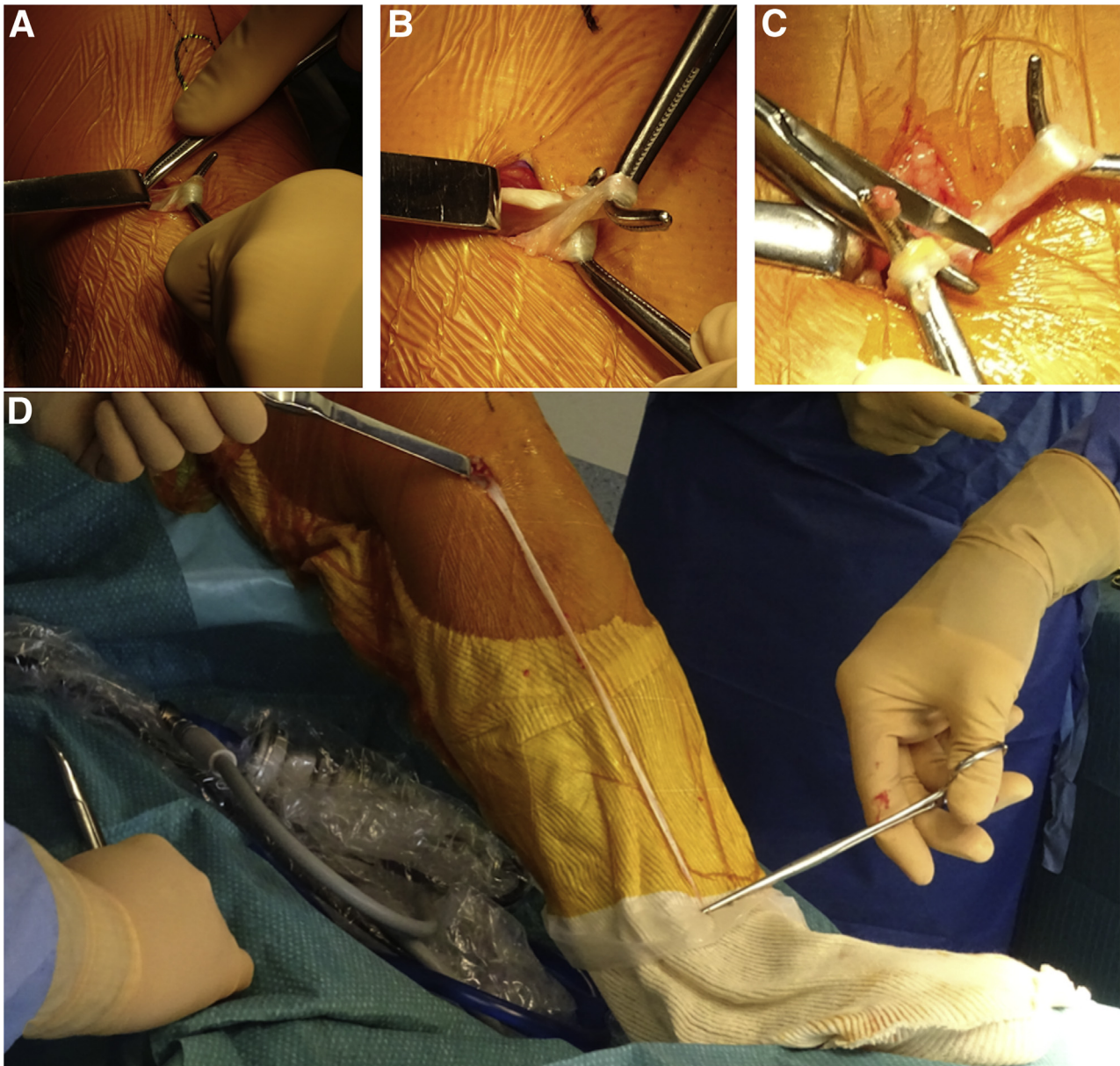
ACL remnant in line with the shaver to hollow out the entire length of the remnant (Fig 5).

#### **ACL Femoral Tunnel**

The outside-in femoral guide is introduced through the anteromedial portal, and the target of the guide is centered on the anteromedial part of the ACL femoral footprint. The guide sleeve is then gently pushed into the femoral incision, posterior and proximal to the lateral epicondyle. The guide's angle can be adjusted as needed to place the sleeve in line with the femoral incision (Fig 6).

The guidewire is introduced, and its intra-articular placement is checked. A 5-mm femoral tunnel is drilled over the guidewire. To facilitate suture relay placement in the femoral tunnel, the 5-mm cannulated drill is left inside the joint with its tip just flush to the intra-articular femoral tunnel outlet. A FiberStick (Arthrex) loaded with 2 different braided sutures is introduced into the cannula of the 5-mm femoral drill. These 2 suture relays are then captured with arthroscopic forceps and externalized through the





**Fig 3.** Gracilis tendon harvesting in left knee. (A) The gracilis is individualized with a right-angled clamp. (B) A second right-angled clamp is used to hook the accessory band of the gracilis tendon. (C) The accessory band is pulled out of the incision and cut with a Mayo scissor. (D) The length of the harvested tendon is checked; the length is sufficient when the extremity of the harvested gracilis hangs down the tibia to the medial malleolus.

anteromedial portals. An arthroscopic suture retriever is introduced through the tibial tunnel and the ACL remnant to capture 1 of the 2 suture relays and to externalize it through the tibial tunnel (Fig 7).

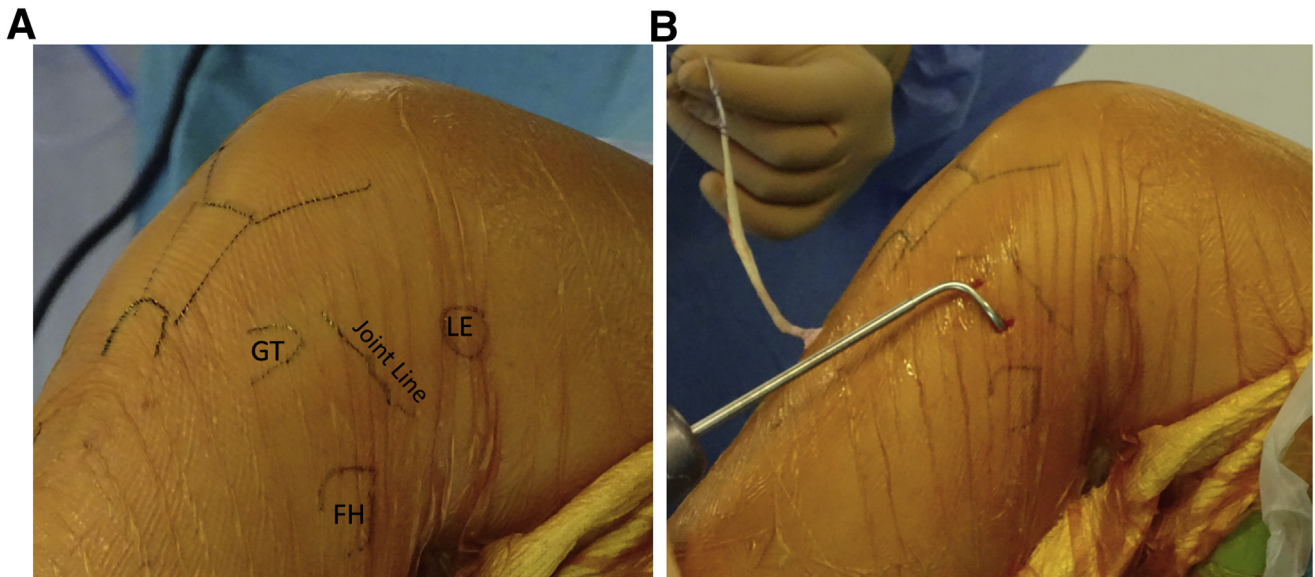
#### Suture Placement in ACL Remnant

A No. 0 FiberLink (Arthrex) is loaded in a Knee Scorpion suture passer (Arthrex). The suture passer is introduced through the anteromedial portal, and the first stitch is placed proximally in the ACL in a lasso-loop configuration. A second stitch is placed distal to the first one with a No. 0 TigerLink suture (Arthrex). To avoid any tissue

interposition during graft and suture link passage, the suture relay and the suture link (FiberLink and TigerLink) are both captured together by a suture retriever and externalized through the anteromedial portal. The management of the different sutures to pass the gracilis into the joint and to pull the ACL remnant back to its femoral insertion is shown in Fig 8.

#### Step 6: Passage and Fixation of ACL-ALL Gracilis Graft and ACL Repair

The 2 limbs of the traction suture from the single-strand gracilis graft are knotted onto the suture relay



**Fig 4.** (A) Anatomic landmark for anterolateral ligament reconstruction in left knee: lateral epicondyle (LE), Gerdy tubercle (GT), and fibular head (FH). (B) A curved suture passer is introduced through the tunnels located 15 mm below the joint line, between the Gerdy tubercle and the fibular head, and then used to place a suture loop in the left knee.

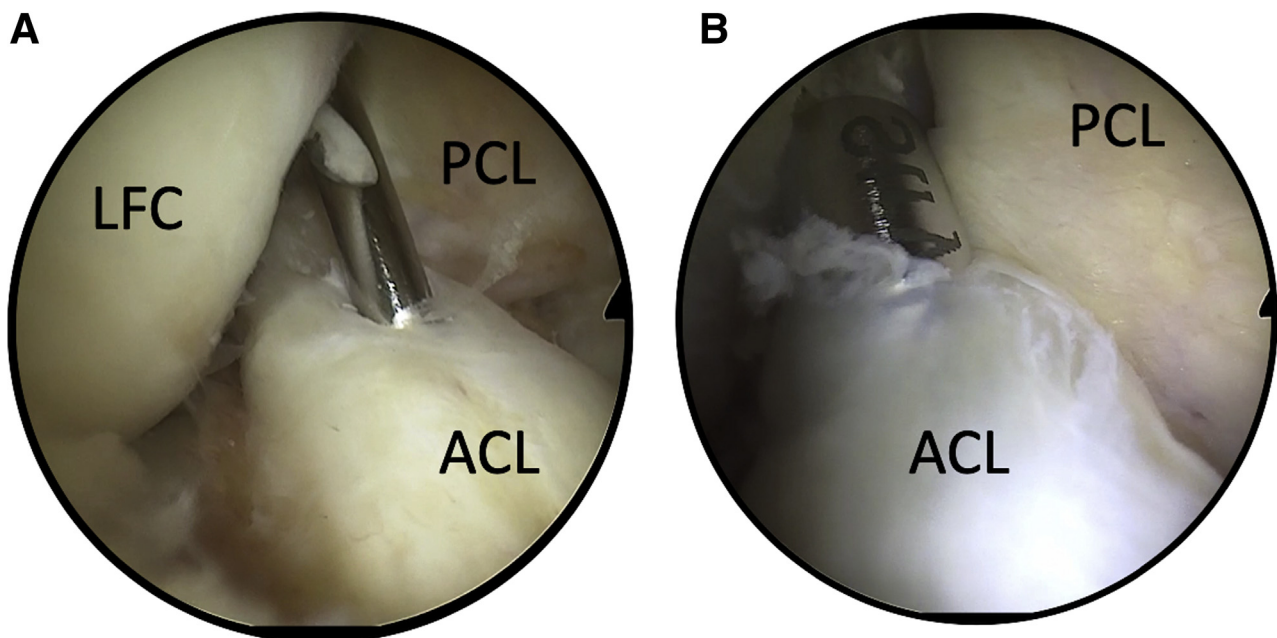
emerging from the ACL tibial tunnel. The gracilis graft is then routed through the joint and pulled out the femoral tunnel (Fig 9).

The FiberLink and TigerLink limbs emerging from the anteromedial portal are knotted with the suture relay coming from the femoral tunnel and routed through it. With the knee in 90° of flexion, a nitinol guide pin is placed in an outside-in manner into the femoral tunnel.

The gracilis graft and suture link limbs are then secured with the knee close to extension with a 5.5-mm interference screw (Tenodesis screw; Arthrex).

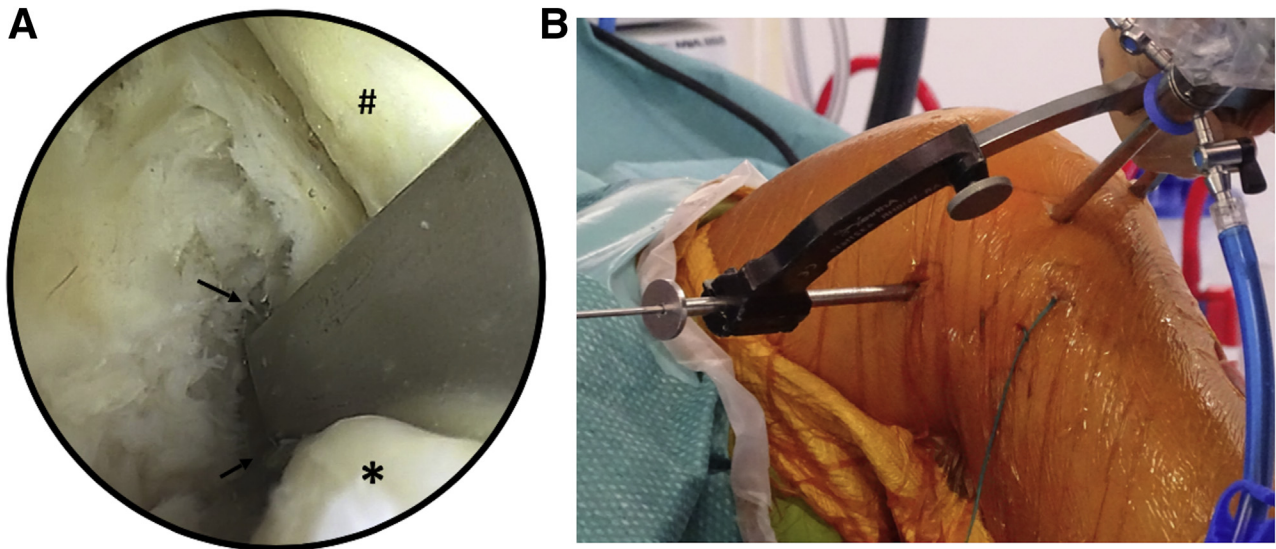
#### **Step 7: Passage and Fixation of ALL Graft**

The traction suture from the gracilis graft is loaded on arthroscopic forceps. The arthroscopic forceps are introduced through the femoral incision, under the ITB,

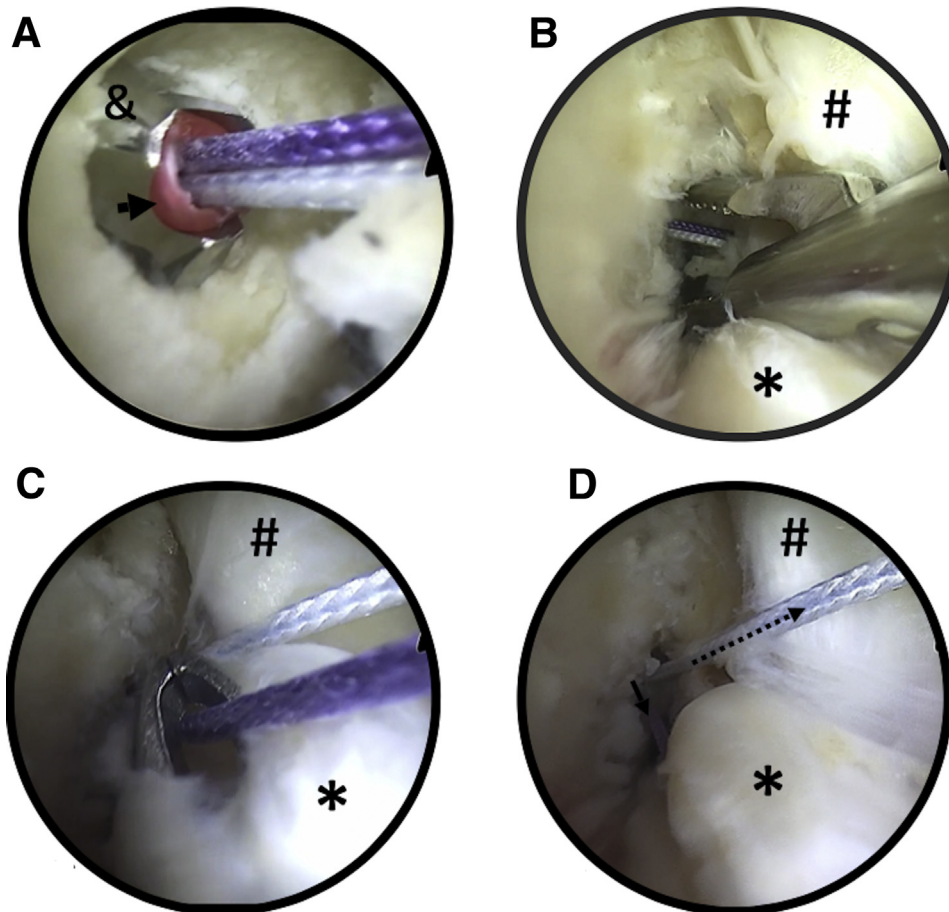


**Fig 5.** Tibial guidewire in anterior cruciate ligament (ACL) remnant (A) and 4.5-mm shaver emerging at proximal end of ACL remnant (B) in right knee. (LFC, lateral femoral condyle; PCL, posterior cruciate ligament.)

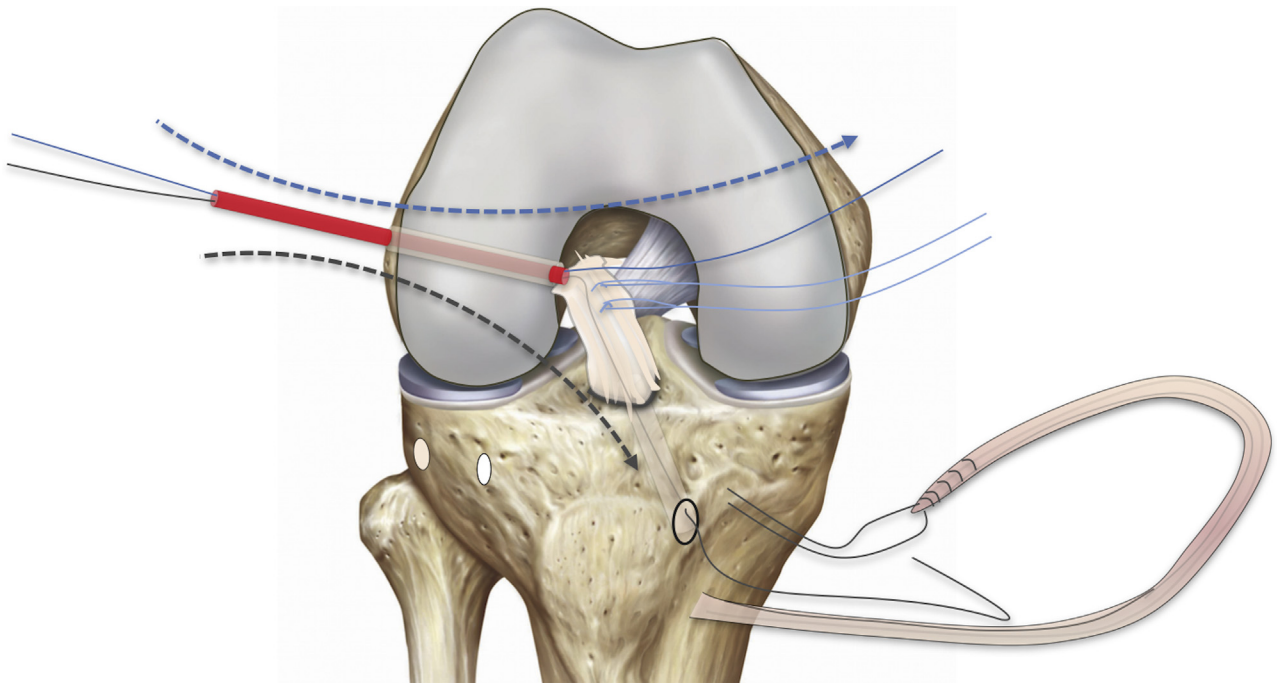




**Fig 6.** (A) Arthroscopic view showing femoral guide placement in right knee. The target of the guide (arrows) is advanced between the anterior cruciate ligament remnant (asterisks) and the posterior cruciate ligament (pound sign) and then centered on the anteromedial area of the anterior cruciate ligament footprint. (B) The sleeve of the outside-in femoral guide is pushed in the femoral incision onto the identified femoral point located posterior and proximal to the lateral epicondyle in the right knee.



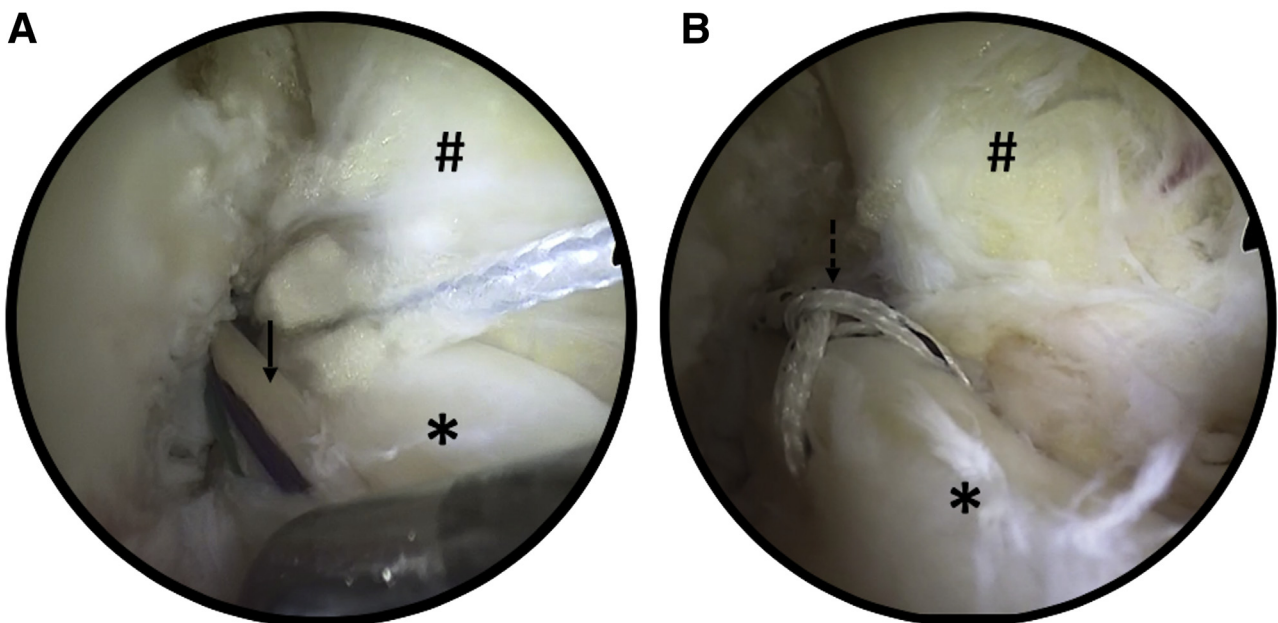
**Fig 7.** Right knee. (A) A Fiber-Stick (arrow), loaded with 2 different braided sutures, is introduced in the cannulated drill (ampersand). (B) The 2 sutures are captured with arthroscopic forceps and externalized through the anteromedial portals. (C) An arthroscopic suture retriever passed through the tibial tunnel and the anterior cruciate ligament remnant is used to capture 1 of the 2 sutures and to externalize it through the tibial tunnel. (D) One of the 2 sutures emerging from the femoral tunnel is externalized through the anteromedial portal (dotted arrow), whereas the other one (solid arrow) is externalized through the tibial tunnel. The asterisks indicate the anterior cruciate ligament remnant; pound signs, posterior cruciate ligament.



**Fig 8.** Suture management. A FiberStick loaded with 2 different suture relays is introduced in the joint through the femoral tunnel. The blue suture relay is retrieved and externalized through the anteromedial portal. This suture relay will serve to route the suture link through the femoral tunnel to reapproximate the anterior cruciate ligament remnant onto its femoral insertion. The black suture relay is retrieved through the tibial tunnel and will be used to pass the gracilis tendon graft into the joint from the tibia to the femur.

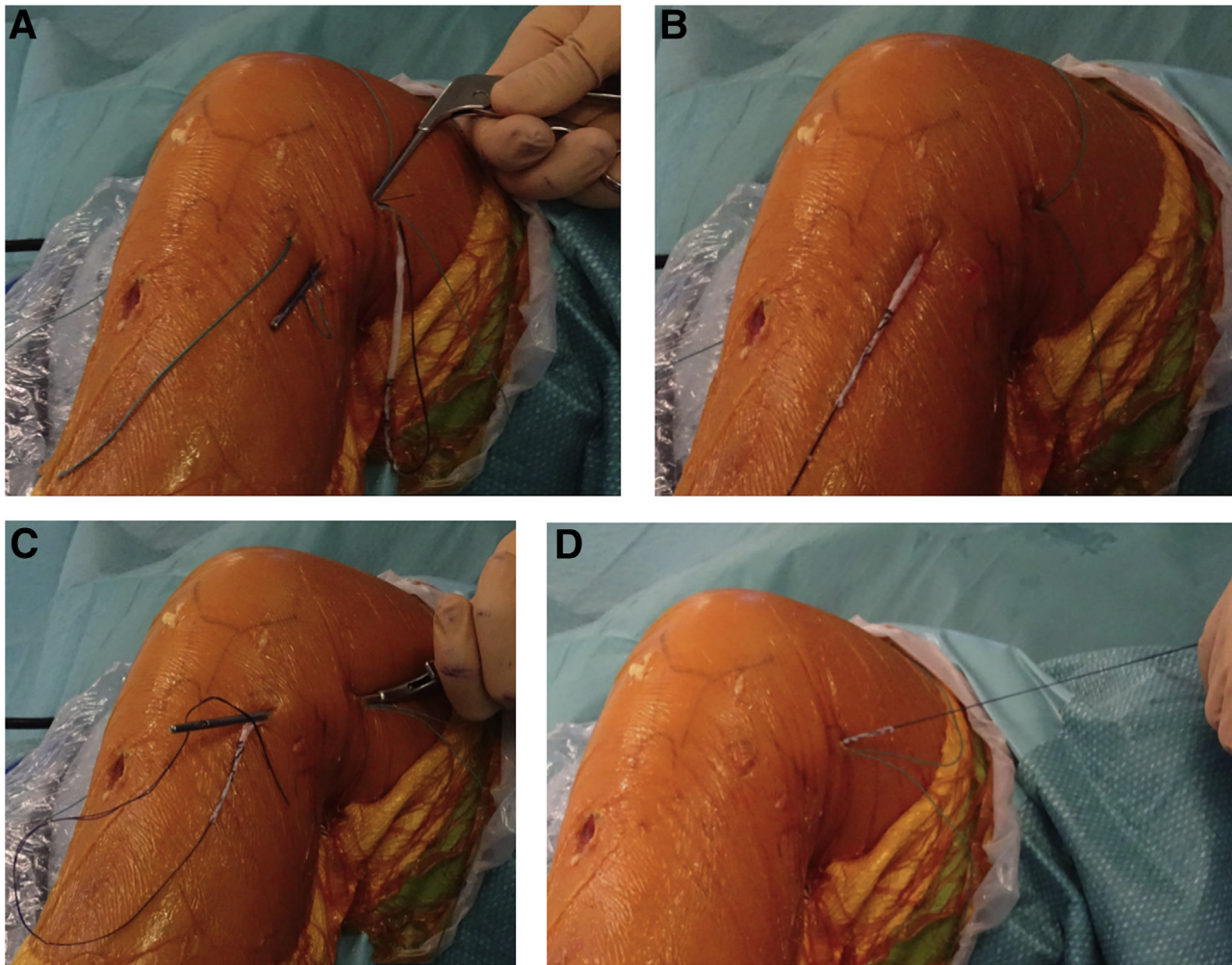
and pushed toward and through the posterior tibial incision. The traction suture limbs are then loaded into the suture loop emerging from the convergent transosseous ALL tibial tunnel and routed from the posterior

to the anterior transosseous tibial tunnel outlet. The forceps are introduced a second time through the femoral incision, under the ITB, toward and through the anterior anterolateral tibial incision. The traction



**Fig 9.** Gracilis graft (solid arrow) routed in joint through anterior cruciate ligament remnant (A) and distal TigerLink stitch in anterior cruciate ligament remnant (dotted arrow) before tensioning (B) in right knee. The asterisks indicate the anterior cruciate ligament remnant; pound signs, posterior cruciate ligament.





**Fig 10.** Anterolateral ligament graft passage in left knee. (A) An arthroscopic suture grasper is introduced through the femoral incision, under the iliotibial band, toward the posterior tibia incision to capture and pull the suture loop toward the femoral incision. (B) The gracilis graft is loaded in the suture loop and then passed under the iliotibial band through the posterior tibial tunnel and pulled out the anterior tibial tunnel. (C) The suture grasper is passed a second time through the femoral incision under the iliotibial band toward the anterior tibial incision to capture the gracilis graft. (D) The gracilis graft is pulled back distally to emerge through the femoral incision.

suture on the gracilis graft is captured with the forceps and pulled through the femoral incision (Fig 10).

At the femoral level, the gracilis graft is secured with the knee in full extension. The suture links holding the ACL remnant are circled around the gracilis graft and tied onto the gracilis. This knotting process is performed 3 times to achieve final fixation; any excessive lengths of suture and gracilis are cut flush before closure (Fig 11). Tips as well as pearls and pitfalls for each step of this procedure are given in Table 2.

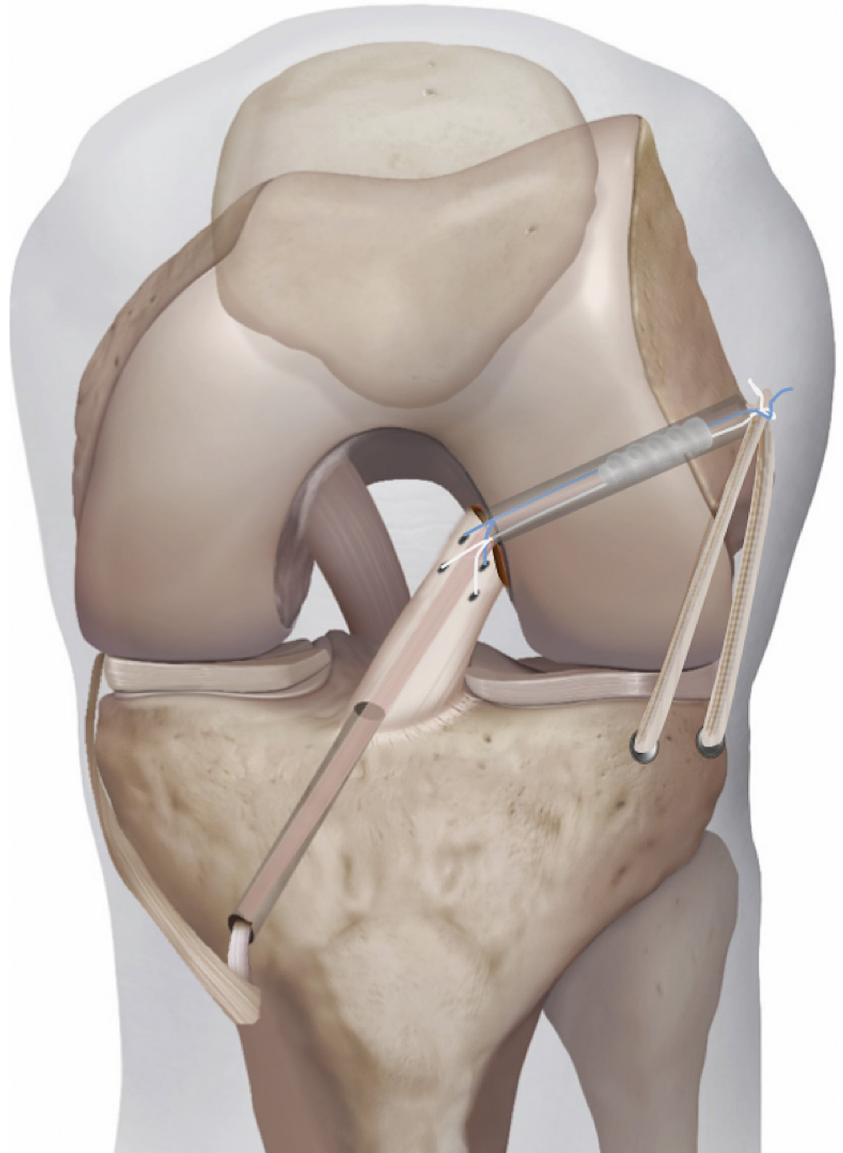
### Discussion

In the recent literature, primary ACL repair to treat acute proximal tears has gained attention. Multiple arthroscopic techniques have been described in the past few years. Sherman et al.<sup>3</sup> highlighted the importance

of patient selection for successful isolated ACL repair. Despite better patient selection and advances in repair techniques, the risk of failure after isolated suture repair of the ACL remains a concern.<sup>8</sup> Intra-articular augmentation has been proposed to protect the repair during the healing period.<sup>6,9</sup>

The originality of the technique described here consists of the use of a single-strand gracilis graft as a “biological” internal brace for intra-articular augmentation of the repair and as an anterolateral graft to protect the repair during the healing phase. This procedure requires harvesting of the gracilis tendon, which can be considered a disadvantage relative to other ACL repair techniques in which graft harvesting is not necessary. However, this disadvantage should be balanced with the potential benefits. In our opinion,





**Fig 11.** Combined anterior cruciate ligament repair and anterolateral ligament reconstruction with single-strand gracilis graft.

adding a lateral tenodesis has major advantages. According to Engebretsen et al.,<sup>10</sup> lateral tenodesis significantly reduces the stress on the ACL by an average of 43%. This would help protect the ACL repair until it heals. Moreover, there is more and more clinical evidence of the protective effect of anterolateral tenodesis when combined with ACL reconstruction, with significant improvement in graft survival.<sup>11</sup>

Relative to standard ACL reconstruction, the main reasons to consider the described ACL repair technique in patients with Sherman type I or II ACL tears are the potential benefits of reduced morbidity owing to gracilis-only harvesting, small-tunnel drilling, and

reduced debridement, in addition to the preserved biological and proprioceptive properties associated with conserving the native ACL. Moreover, this primary repair, combined with lateral tenodesis, burns few bridges in the event of a failure in the future. The advantages and disadvantages of this procedure versus ACL reconstruction and standard ACL repair are presented in [Table 3](#).

In conclusion, the described ACL repair technique offers an alternative to ACL reconstruction for selected patients with a proximal ACL tear. The use of a single-strand gracilis graft provides both intra- and extra-articular augmentation to protect the ACL repair while it heals.

**Table 2.** Tips, Pearls, and Pitfalls for Procedure

Surgical Step	Tips and Pearls	Pitfalls
Graft harvesting and preparation	<ul style="list-style-type: none"> <li>• Collect the hamstring tendons and carefully dissect any band that could divert the tendon stripper and cause premature truncation of the graft.</li> <li>• Check the graft length: Once harvested, pull the gracilis distally toward the ankle; when the gracilis extremity reaches the medial malleolus, the length is sufficient.</li> <li>• Keep the gracilis intact at its tibial insertion.</li> </ul>	<ul style="list-style-type: none"> <li>• If the harvested gracilis is not long enough, it may not be suitable for ALL reconstruction. Detachment of the gracilis from its tibial insertion is required, in addition to its fixation in the tibial tunnel with a 6-mm-diameter interference screw. Another option is to perform a single-strand ALL reconstruction.</li> </ul>
ALL tibial drilling	<ul style="list-style-type: none"> <li>• Use a 5-mm drill to create 2 slightly convergent 15-mm deep sockets. Maintain at least 23 mm between the 2 tunnels. Bear in mind that a guide pin and 5-mm cannulated drill can be used to facilitate tibial socket orientation.</li> <li>• Use braided suture with a large curved needle to pass the suture loop through the tibial transosseous tunnel.</li> </ul>	<p>If the 2 tunnels are too close, the bony bridge between them can collapse.</p>
Notch debridement	<ul style="list-style-type: none"> <li>• Use a 4.2-mm shaver for femoral ACL footprint debridement to avoid damaging the ACL remnant.</li> <li>• During femoral footprint debridement, switch the scope to the AM portal to check and adjust the debridement area.</li> </ul>	<ul style="list-style-type: none"> <li>• Inappropriate tunnel placement may occur owing to a poor view from the AL portal because of the ACL remnant.</li> </ul>
ACL tibial tunnel	<ul style="list-style-type: none"> <li>• Note that the K-wire is positioned slightly more posterior than usual to make it easier to suture the ACL remnant.</li> <li>• Ensure alignment with the ACL path by drilling with the knee close to extension.</li> </ul>	<ul style="list-style-type: none"> <li>• Drilling with poor alignment of the ACL path can damage the remnant.</li> </ul>
ACL femoral tunnel	<ul style="list-style-type: none"> <li>• Center the femoral guide target in the AM area of the ACL femoral footprint.</li> <li>• Place the scope in the AM portal during drilling to verify the 5-mm drill's exit in the notch.</li> <li>• Keep the 5-mm cannulated drill in the joint flush to the femoral tunnel outlet.</li> </ul>	<ul style="list-style-type: none"> <li>• Placing the graft and the suture link in the more anisometric posterolateral femoral footprint area can lead to overstretching of the repair during knee motion.</li> </ul>
Suture management and graft passage	<ul style="list-style-type: none"> <li>• Cut 4 cm of the red plastic tube from the FiberStick and load an additional TigerStick (Arthrex) in the tube; this will allow one to push on the 2 sutures to bring them out the plastic tube and to easily capture them in the notch.</li> <li>• Use a retriever to avoid soft-tissue (fat pad) interposition before graft and suture link passage.</li> </ul>	<ul style="list-style-type: none"> <li>• Fat pad interposition during graft and suture passage will require additional surgical time to fix the issue.</li> </ul>
Suture and graft fixation	<ul style="list-style-type: none"> <li>• Put the knee in 90° of flexion and pull on the gracilis graft toward the ground when inserting the nitinol guide pin to retract the ITB from the femoral tunnel aperture.</li> <li>• Bring the screw in contact with the femoral tunnel aperture with the knee flexed at 90°; then, put the knee close to extension and start screw placement.</li> <li>• With the scope placed in the AM portal, check that the screw does not protrude into the joint space.</li> </ul>	<ul style="list-style-type: none"> <li>• Femoral screw prominence should be avoided. One should be aware that the femoral tunnel is likely to be more horizontal and shorter than the typical tunnel for isolated ACL reconstruction.</li> </ul>

ACL, anterior cruciate ligament; AL, anterolateral; ALL, anterolateral ligament; AM, anteromedial; ITB, iliotibial band.



**Table 3.** Advantages and Disadvantages of Combined ACL Repair and ALL Reconstruction With Single-Strand Gracilis Graft Versus Standard ACL Reconstruction or Standard ACL Repair

ACL reconstruction
Advantages
Relatively short procedure (30-45 min)
Preservation of ACL's biological properties (proprioception and vascularization)
Smaller inflammatory reaction with reduced effusion, pain, stiffness, and arthrogenic muscle inhibition
No bridges are burned in comparison to reconstruction
Disadvantages
Only suitable for proximal avulsions (intraoperative decision after arthroscopic evaluation of the remnant's reducibility with the knee in the figure-of-4 position)
Poor clinical background; long-term outcomes not available
Clinical experience limited to patients with low to medium demands on knee
Standard ACL repair
Advantages
Lateral tenodesis provides additional protection of ACL repair
Disadvantages
Gracilis autograft harvesting required

ACL, anterior cruciate ligament; ALL, anterolateral ligament.

## References

1. Feagin JA, Curl WW. Isolated tear of the anterior cruciate ligament: 5-Year follow-up study. *Am J Sports Med* 1976;4:95-100.
2. Chambat P, Walch G, Deschamps G, Dejour H. Les lésions aiguës du ligament croisé antérieur du genou. A propos de 71 malades revus [Acute lesions of the anterior cruciate ligament of the knee. Apropos of 71 follow-up cases]. *Rev Chir Orthop Reparatrice Appar Mot* 1984;70:152-155 (suppl 2) [in French].
3. Sherman MF, Lieber L, Bonamo JR, Podesta L, Reiter I. The long-term followup of primary anterior cruciate ligament repair. Defining a rationale for augmentation. *Am J Sports Med* 1991;19:243-255.
4. Murray MM, Fleming BC, Badger GJ, et al. Bridge-enhanced anterior cruciate ligament repair is not inferior to autograft anterior cruciate ligament reconstruction at 2 years: Results of a prospective randomized clinical trial. *Am J Sports Med* 2020;48:1305-1315.
5. Jonkergouw A, van der List JP, DiFelice GS. Arthroscopic primary repair of proximal anterior cruciate ligament tears: Outcomes of the first 56 consecutive patients and the role of additional internal bracing. *Knee Surg Sports Traumatol Arthrosc* 2019;27:21-28.
6. Massey P, Parker D, McClary K, Robinson J, Barton RS, Solitro GF. Biomechanical comparison of anterior cruciate ligament repair with internal brace augmentation versus anterior cruciate ligament repair without augmentation. *Clin Biomech (Bristol, Avon)* 2020;77:105065.
7. Moura JL, Kandhari V, Rosenstiel N, et al. Figure-of-4 cruciate remnant objective assessment test reducibility of anterior cruciate ligament stump for feasibility of arthroscopic primary anterior cruciate ligament repair. *Arthrosc Tech* 2019;8:e637-e640.
8. Kösters C, Glasbrenner J, Spickermann L, et al. Repair with dynamic intraligamentary stabilization versus primary reconstruction of acute anterior cruciate ligament tears: 2-Year results from a prospective randomized study. *Am J Sports Med* 2020;48:1108-1116.
9. Bachmaier S, DiFelice GS, Sonnery-Cottet B, et al. Treatment of acute proximal anterior cruciate ligament tears—Part 2: The role of internal bracing on gap formation and stabilization of repair techniques. *Orthop J Sports Med* 2020;8:2325967119897423.
10. Engebretsen L, Lew WD, Lewis JL, Hunter RE, Benum P. Anterolateral rotatory instability of the knee. Cadaver study of extraarticular patellar-tendon transposition. *Acta Orthop Scand* 1990;61:225-230.
11. Hurley ET, Fried JW, Kingery MT, Strauss EJ, Alaia MJ. Antero-lateral ligament reconstruction improves knee stability alongside anterior cruciate ligament reconstruction. *Knee Surg Sports Traumatol Arthrosc* 2021;29:764-771.