

Case Report

Primary hepatic tuberculosis in immunocompetent adults: a UK case series

Moustafa Mabrouk Mourad*, Christos Liossis, Abdullah Algarni, Senthil Kumar and Simon R. Bramhall

The Liver Unit, Queen Elizabeth Hospital Birmingham, Edgbaston, Birmingham, UK

*Correspondence address. The Liver Unit, Queen Elizabeth Hospital Birmingham, Nuffield House 3rd Floor, Edgbaston, Birmingham B15 2TH, UK. Tel: +44-742-736-5931; Fax: +44-121-414-1833; E-mail: moustafa.mourad@nhs.net

Received 29 September 2014; revised 18 November 2014; accepted 22 November 2014

Primary hepatic tuberculosis (TB) is very rare in the UK, but the incidence may be rising. Three cases of primary hepatic TB in immunocompetent patients without evidence of pulmonary involvement are reported. The diagnosis was challenging as two patients had liver space-occupying lesions, and the third patient presented with liver abscess. All of them responded well to standard anti-tubercular treatment. Hepatic TB should be considered in the differential diagnosis of space-occupying lesions of the liver and liver abscesses.

INTRODUCTION

Tuberculosis (TB) is still a worldwide health challenge with high prevalence in the developing regions. Liver involvement occurs in ~10–15% of patients having pulmonary TB. It has been reported more commonly in patients with disseminated TB and in autopsy series [1, 2]. Primary liver TB, however, is a rare form of extra-pulmonary TB, and only few cases have been reported in the literature worldwide.

The clinical presentation of hepatic TB is non-specific [3]. High-grade fever, upper abdominal pain, weight loss and hepatomegaly are the most frequently observed clinical findings. Jaundice is uncommon; it has been reported in 35% of the cases and is usually obstructive in nature, simulating other conditions causing extrahepatic biliary obstruction and makes the diagnosis more challenging [4]. The diagnosis of TB depends on demonstration of caseating epithelioid granuloma or presence of acid-fast bacilli (AFB) in the aspirated pus or biopsy.

To the best of our knowledge, there have been no case series of primary hepatic TB from the UK. We report three patients with primary hepatic TB, two of them presented as a mass lesion and one as pyrexia of unknown origin.

CASE REPORT

Case 1

A 30-year-old Indian lady, who had been a resident of the UK for many years, presented with epigastric pain, nausea and

occasional vomiting of few months duration. There was no past or family history of TB. Chest was clinically and radiologically normal. Magnetic resonance imaging (MRI) and an endoscopic ultrasound (EUS) of the liver showed a 3.8-cm heterogeneous mass in the caudate lobe and porta hepatis (Fig. 1). EUS biopsy of the lesion showed necrotizing granulomatous inflammation in keeping with TB.

Case 2

A 17-year-old Afro-Caribbean lady presented with intermittent high-grade fever and abdominal discomfort for 1 week. She was born and had lived in the UK throughout her life. A cousin has had a diagnosis of pulmonary TB ~2 years before her presentation. Computed tomography (CT) scan abdomen showed a large multi-septated liver abscess in the right lobe of the liver (segments VI and VII), measuring 7.1 × 7.2 × 6.4 cm (Fig. 2). Histopathology of this lesion biopsy revealed necrotizing granulomatous inflammation consistent with TB. There were no AFB on Zeil–Neelson staining and cultures were negative for TB after 10 weeks.

Case 3

A 45-year-old male, immigrant from Philippines who is living in the UK since 2007, presented with postprandial intermittent episodes of right upper abdominal pain. There was no past or

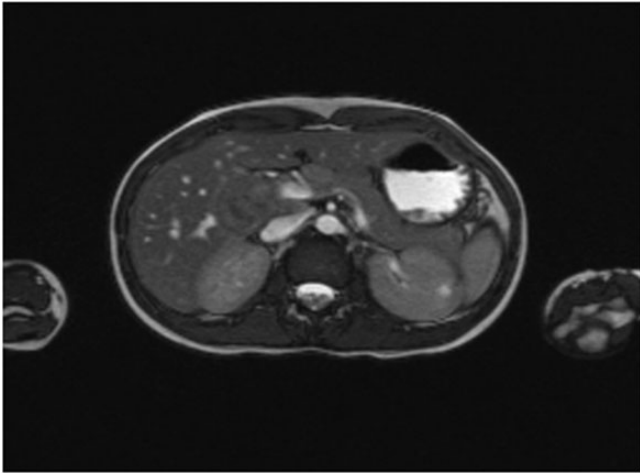


Figure 1: MRI abdomen shows a large irregular solid heterogeneous mass near the hilum of liver (Case 1).

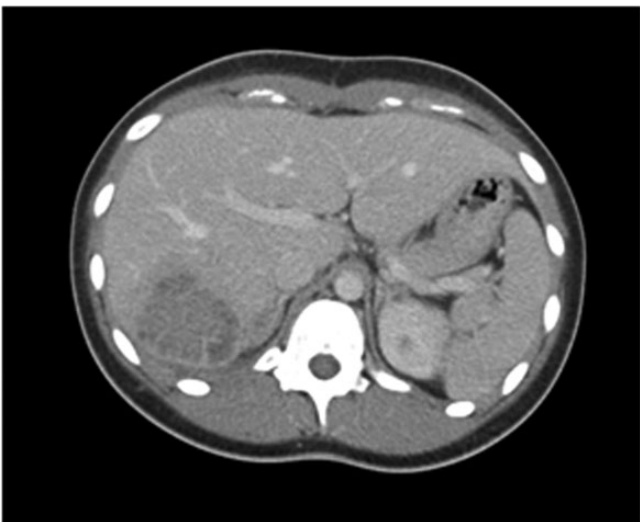

Figure 2: CT scan showed a large multi-septated liver abscess in the right lobe of the liver (Case 2).

family history of TB. CT abdomen showed a 4.5-cm low attenuation lesion in the caudate lobe, compressing the hepatic artery (Fig. 3). EUS biopsy revealed necrotizing granulomatous inflammation. Although Zeil–Neelson stain was negative, culture showed *Mycobacterium tuberculosis* at 4 weeks. CT thorax was done, immunoglobulins measured and human immunodeficiency virus (HIV) status checked for the three patients who responded well and promptly, clinically and radiologically to a standard multi drug anti-tubercular treatment regimen given for 6 months.

DISCUSSION

With an estimated third of the world population being exposed to TB, 2 billion with latent TB and up to 8 million new cases per year, TB is an ever-present global challenge [5]. With immigration and travel, it is not limited to the developing world

alone anymore. It is 30 times more common in the setting of HIV infection, where it is responsible for 25% of deaths [5]. However, isolated hepatic TB is uncommon, especially in the UK. It occurs as twice as often in male gender.

Hepatic TB has five broad clinical–pathological presentations: (i) military TB, (ii) granulomatous TB hepatitis, (iii) nodular TB, (iv) ductal TB and (v) nodal TB [6, 7]. Of these, military TB and granulomatous TB hepatitis are seen in systemically unwell patients with a clinically apparent extra-hepatic focus and have a ‘non-surgical’ clinical course. The latter three often present to surgeons. Nodular TB has two variations: a more solid mass lesion (pseudo-tumour) and an atypical heterogeneous abscess. Ductal TB may present with focal or diffuse strictures (Klatskin-like lesions; or secondary sclerosing cholangitis). TB involving porta hepatis nodes may present with obstructive jaundice and a hilar mass.

In our series, it seems that hepatic TB has a preferential involvement of caudate lobe (cases 1 and 3); it has not been mentioned by others, and this is the first time this observation comes to the scope. We wonder if the preferential presence of TB in the caudate lobe relates in some way to haemodynamics of blood flow in either portal vein, inferior vena cava or short segment 1 veins, but we could not adjust for this correlation in the current report.

The diagnosis classically relied on demonstration of AFB on Zeil–Neelson stain of tissue samples or on the presence of caseating necrotizing granulomas on histology. The incidence rate of positive AFB stain on aspiration and biopsy samples in hepatic TB from large series ranges from 7 to 59% and usually falls in the region of ~20% [7, 8]. Mycobacterial culture, although has a high specificity, has a low positive yield of ~10% [6]. Recently, enzyme-linked immunosorbent assay (ELISA), polymerase chain reaction (PCR) and T-SPOT.TB test have emerged as useful tools to clinch the diagnosis [9, 10]. PCR effectively detects mycobacterial DNA in small samples. The T-SPOT.TB test detects the *in vitro* production of interferon- γ by peripheral blood mononuclear cells in response to *M. tuberculosis*-specific antigens [11]. These tests should be used whenever available, to avoid delays in diagnosis.

In conclusion, the following clinical scenarios should raise the index of suspicion for hepatic TB in a patient with unusual presentation of liver mass lesion or in atypical abscesses (non-pyogenic and non-amoebic) and one of the following: (i) Asian or Afro-Caribbean descent, (ii) young age (20–40 years) and (iii) unexplained weight loss or fever.

Written informed consent was obtained from the patient’s guardian for publication of this case series and accompanying figures. A copy of the written consent is available for review by the Editor-in-Chief of this journal on request.

AUTHORS’ CONTRIBUTIONS

S.R.B.—conceptualized the study; M.M.M., C.L., A.A. and S.K.—responsible for data collection; M.M.M. and

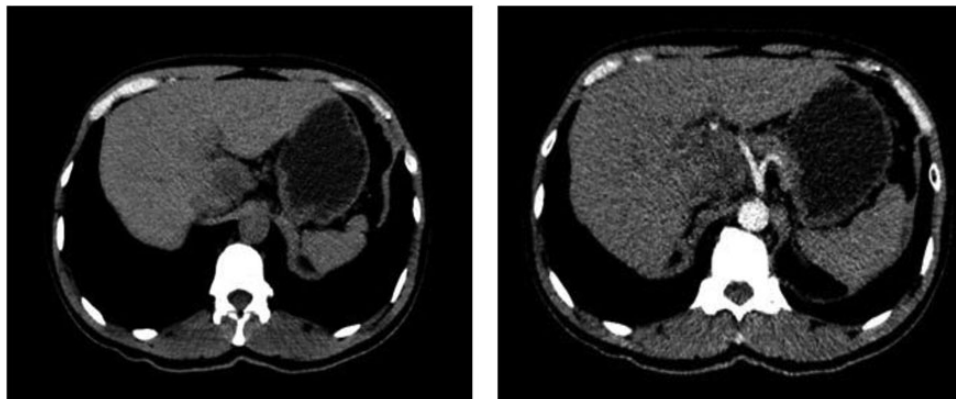


Figure 3: CT scan showed a large lesion arise from the caudate lobe (Case 3).

S.B.R.—study design; M.M.M., S.K. and C.L.—prepared the manuscript. S.R.B. and M.M.M.—data interpretation and critical review of manuscript; all co-authors approved the final manuscript.

CONFLICT OF INTEREST STATEMENT

The investigators have not received any financial support for this case report. None of the authors have any potential conflicting financial interests relevant to this report.

REFERENCES

1. Chong VH, Lim KS. Hepatobiliary tuberculosis. *Singapore Med J* 2010;**51**:744–51.
2. Saluja SS, Ray S, Pal S, Kukeraja M, Srivastava DN, Sahni P, et al. Hepatobiliary and pancreatic tuberculosis: a two decade experience. *BMC Surg* 2007;**7**:10.
3. Malik M, Kurban L, Murray GI, Alkari B. Isolated tuberculosis of the liver: a diagnostic challenge. *BMJ Case Rep* 2011;**2011**: bcr1220103654.
4. Hassani KI, Ousadden A, Ankouz A, Mazaz K, Taleb KA. Isolated liver tuberculosis abscess in a patient without immunodeficiency: a case report. *World J Hepatol* 2010;**2**:354–57.
5. Diagnostic Standards and Classification of Tuberculosis in Adults and Children. This official statement of the American Thoracic Society and the Centers for Disease Control and Prevention was adopted by the ATS Board of Directors, July 1999. This statement was endorsed by the Council of the Infectious Disease Society of America, September 1999. *Am J Respir Crit Care Med* 2000;**161**(4 Pt 1):1376–95.
6. Alvarez SZ. Hepatobiliary tuberculosis. *Phil J Gastroenterol* 2006;**2**:1–10.
7. Essop AR, Posen JA, Hodkinson JH, Segal I. Tuberculosis hepatitis: a clinical review of 96 cases. *Q J Med* 1984;**53**:465–77.
8. Maharaj B, Leary WP, Pudifin DJ. A prospective study of hepatic tuberculosis in 41 black patients. *Q J Med* 1987;**63**:517–22.
9. Alcantara-Payawal DE, Matsumura M, Shiratori Y, Okudaira T, Gonzalez R, Lopez RA, et al. Direct detection of *Mycobacterium tuberculosis* using polymerase chain reaction assay among patients with hepatic granuloma. *J Hepatol* 1997;**27**:620–27.
10. Mori T, Sakatani M, Yamagishi F, Takashima T, Kawabe Y, Nagao K, et al. Specific detection of tuberculosis infection: an interferon-gamma-based assay using new antigens. *Am J Respir Crit Care Med* 2004;**170**:59–64.
11. Simsek H, Alpar S, Ucar N, Aksu F, Ceyhan I, Gozalan A, et al. Comparison of tuberculin skin testing and T-SPOT.TB for diagnosis of latent and active tuberculosis. *Jpn J Infect Dis* 2010;**63**:99–102.