

## Multiple metastases to the bone and bone marrow from a 1p/19q-codeleted and *IDH2*-mutant anaplastic oligodendroglioma: a case report and literature review

Hiroyuki Shimizu, Kazuya Motomura<sup>✉</sup>, Fumiharu Ohka, Kosuke Aoki, Kuniaki Tanahashi, Masaki Hirano, Lushun Chalise, Tomohide Nishikawa, Junya Yamaguchi, Toshihiko Wakabayashi, and Atsushi Natsume

Department of Neurosurgery, Nagoya University School of Medicine, Nagoya, Japan

**Corresponding Author:** Kazuya Motomura, MD, PhD, Department of Neurosurgery, Nagoya University School of Medicine, 65 Tsurumai-cho, Showa-ku, Nagoya 466–8550, Japan ([kmotomura@med.nagoya-u.ac.jp](mailto:kmotomura@med.nagoya-u.ac.jp)).

**A 29-year-old woman was initially diagnosed with anaplastic oligodendroglioma. She underwent surgical resection followed by a radiation therapy and chemotherapy with temozolomide. Following the initial treatment, she underwent 3 more surgeries for local recurrences. Approximately 7 years after the first diagnosis, she presented with pain in the left hip joint. A bone marrow sample was collected from her left iliac bone, which showed tumor components pathologically and immunohistochemically identical to the anaplastic oligodendroglioma of the brain. *IDH2* mutation, 1p/19q codeletion, and homozygous deletion of *CDKN2A* and *CDKN2B* were detected in both primary and metastatic bone marrow tumors.**

We present a case of multiple metastases to the bone and bone marrow from a 1p/19q-codeleted and isocitrate dehydrogenase (*IDH*)2-mutant anaplastic oligodendroglioma. If better intracranial local tumor control could be achieved, distant metastases might become a bigger clinical issue and be observed more frequently in later stages of these diseases.

Oligodendroglioma is an infrequent neoplasm that accounts for 2% to 5% of all primary brain tumors, defined under the 2016 World Health Organization classification of tumors of the central nervous system as a diffusely infiltrating, slow-growing glioma with isocitrate dehydrogenase (*IDH*)1 or *IDH2* mutation and a concomitant codeletion of chromosomal arms 1p and 19q.<sup>1</sup> It is categorized into 2 grades based on its pathological features: grade II (low grade) or grade III (high grade). Oligodendroglioma is known to have a more favorable prognosis than astrocytic glial tumors, including diffuse astrocytoma, anaplastic astrocytoma, and glioblastoma, with a high sensitivity to chemoradiotherapy. Local recurrence is a common biological characteristic of these tumors.

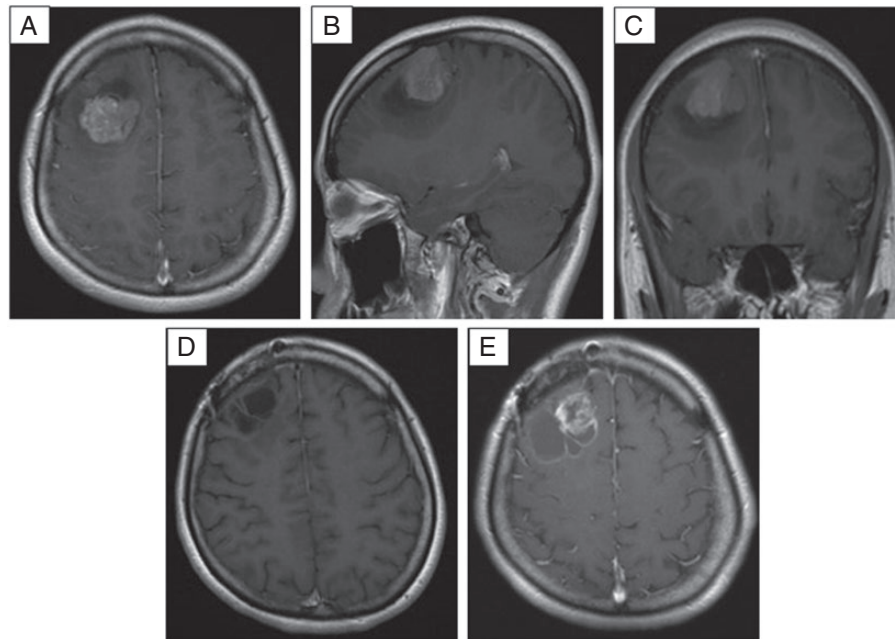
In general, metastases of primary brain tumors are rare events, especially outside of the central nervous system (CNS). In a report of 8000 cases of primary CNS tumors, only 35 cases (0.44%) developed extraneural metastases. Furthermore, Liwnicz et al.<sup>2</sup> reported on 116 cases of extracranial metastasis of CNS tumors, of which 41.4% were glioblastomas, 26.7% medulloblastomas, 16.4% ependymomas, 10.3%

astrocytomas, and 5.25% oligodendrogliomas. Glioblastoma is the most common metastatic brain tumor and is the type of brain tumor from which extraneural metastasis was first reported by Davis et al.<sup>3</sup> Over a hundred cases have been further reported since then. The literature review by Piccirilli et al.<sup>4</sup> demonstrated increased incidence of extra CNS metastases from the 21 cases reported from 1928 to 1967 to 107 cases from 1968 to 2006, showing a fivefold increase. Owing to improvements in diagnosis, better imaging techniques, and advanced treatment of gliomas, the number of these metastatic cases has increased.<sup>4,5</sup> Extra CNS metastases are regarded as a sign of advanced disease, which frequently occur between 8 and 24 months from the initial diagnosis of a primary brain tumor.<sup>5</sup> Nevertheless, extracranial metastases from oligodendrogliomas are much rarer than those from other gliomas.

We report a case of 1p/19q-codeleted and *IDH2*-mutant anaplastic oligodendroglioma with multiple extracranial metastases, including metastases to the bone and bone marrow, 89 months after the first brain tumor diagnosis.

### Case Presentation

In May 2012, a 29-year-old right-handed woman presented with convulsive attacks and was transferred to the emergency room of a nearby hospital. She underwent magnetic resonance imaging (MRI) of the brain, which revealed a heterogeneous gadolinium-enhancing lesion in the right frontal lobe, with a maximum diameter of approximately 40 mm (Figure 1). She underwent her first tumor resection at this hospital. Histological examination of the tumor cells revealed a diagnosis of anaplastic oligodendroglioma. Following this surgery, she was treated with 60 Gy in 30 fractions of radiation therapy with concurrent temozolomide (TMZ) chemotherapy. Moreover, a maintenance regimen of TMZ 200 mg/m<sup>2</sup> days 1–5 every 4 weeks was continued.



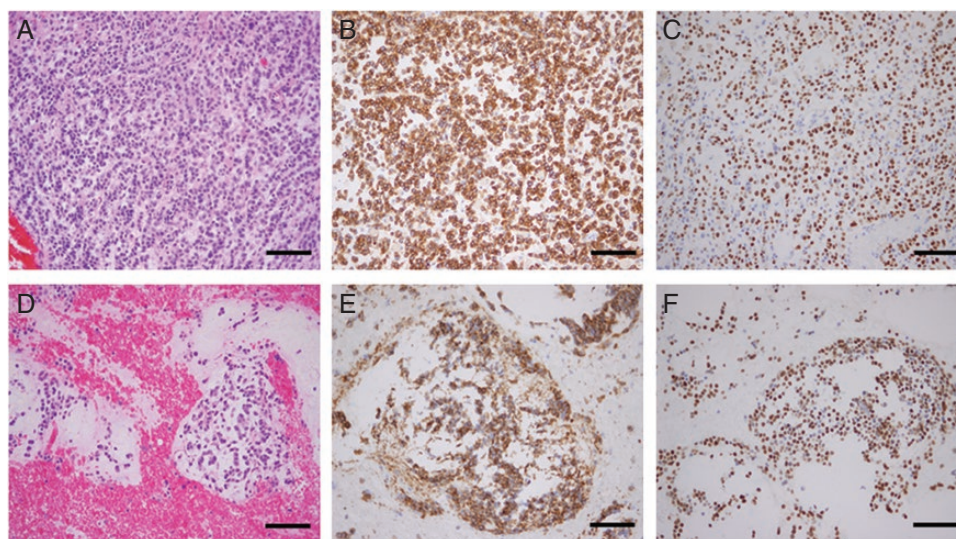
**Figure 1.** Preoperative axial (A), sagittal (B), and coronal (C) T1-weighted MRI with gadolinium enhancement showing a heterogeneous enhancing mass in the right frontal lobe. Axial (D) T1-weighted MRI with gadolinium enhancement performed 2 years after the first surgery showing no residual or recurrent tumors. Axial (E) T1-weighted MRI with gadolinium enhancement performed 6 years after the initial presentation showing the first recurrence.

After the first local recurrence in June 2017, the patient was referred to our neurosurgery department to undergo a second tumor resection, which resulted in a gross-total mass resection. The pathological diagnosis was again anaplastic oligodendroglioma, consistent with the initial diagnosis, and Ki-67 expression was observed in 20% of the tumor cells. The tumor was found to harbor *IDH2* R172K and *TERT* C228T mutations by Sanger sequencing, as well as a 1p/19q codeletion by multiplex ligation-dependent probe amplification (MLPA).<sup>6</sup> Moreover, homozygous deletion of *CDKN2A* and *CDKN2B*, which is an adverse prognostic factor in malignant *IDH*-mutant gliomas,<sup>7</sup> were detected by MLPA. In April 2018, a third surgical resection was performed for local recurrence of the tumor, which also achieved a gross-total mass resection. After the third surgical resection, maintenance TMZ chemotherapy was administered concurrently with bevacizumab every 2 weeks. One year later, however, the tumor again recurred, and the patient underwent a fourth surgical resection with gross-total mass removal. Pathology at this time also showed anaplastic oligodendroglioma (Figure 2A–C). Throughout all recurrences, there were no obvious changes in the Ki-67 expression or morphological features. *IDH2/TERT* mutations and 1p/19q codeletion were confirmed to be the same as those in the tumor specimen obtained in the second surgical resection. To detect the presence of mismatch repair defects, we used standard fluorescence-based polymerase chain reaction with the Microsatellite Instability (MSI) Test Kit (FALCO) (FALCO biosystems, Kyoto, Japan), including 5 mononucleotide microsatellite markers (BAT25, BAT26, NR21, NR24, and MONO27) as well as 2 pentanucleotide repeat markers (Penta C and Penta D). The testing result

showed no MSI-high. A month after the fourth surgery, we decided to perform a second round of radiation therapy using 40 Gy in 20 fractions to the local area around the tumor cavity in order to prevent additional tumor recurrence.

In October 2019, the patient presented with pain in the left hip joint, at which time no significant findings were observed on a neurological examination. A computed tomography (CT) scan revealed multiple osteoblastic lesions in her pelvis, bilateral femurs, sacrum, and left scapula (Figure 3A). An <sup>18</sup>Fluorodeoxyglucose (FDG) positron emission tomography (PET)-CT scan and whole-body bone scintigraphy with (99m) technetium-hydroxymethylene diphosphonate (99mTc-HMDP) both demonstrated high uptake in the same lesions identified on the CT scan (Figure 3B–D). Curiously, however, no recurrent intracranial lesions were detected on the brain MRI. Because the patient presented with pancytopenia, a bone marrow sample was collected from her left iliac bone, which showed tumor components pathologically and immunohistochemically identical to the anaplastic oligodendroglioma of the brain (Figure 2D–F). Furthermore, *IDH2* mutation and 1p/19q codeletion were confirmed in this bone marrow tumor by sanger sequencing and MLPA, respectively. Homozygous deletion of *CDKN2A* and *CDKN2B* were also detected by MLPA.

Following the diagnosis of extracranial oligodendroglioma metastasis, a maintenance chemotherapy regimen of TMZ and bevacizumab was continued in the absence of therapeutic alternatives. Additionally, palliative radiotherapy for pain relief was also performed. Unfortunately, we could not control the tumor progression and the patient's pain due to the progressive worsening of her



**Figure 2.** Photomicrographs (magnification  $\times 200$ ) of oligodendroglial cells in the brain tumor (A–C) and the metastatic bone marrow tumor (D–F). Hematoxylin-eosin staining showed proliferation of tumor cells with relatively round nuclei and a loose, myxoid-like background (A, D). Normal hematopoietic tissue replaced by a malignant tumor (D). Immunohistochemical staining showed positive results for CD56 (B, E) and Olig2 (C, F). Scale bars: 100  $\mu\text{m}$ .

bone metastases. The patient decided to leave the hospital to receive palliative care at home, and she died about 7 months being diagnosed with bone metastases.

## Discussion

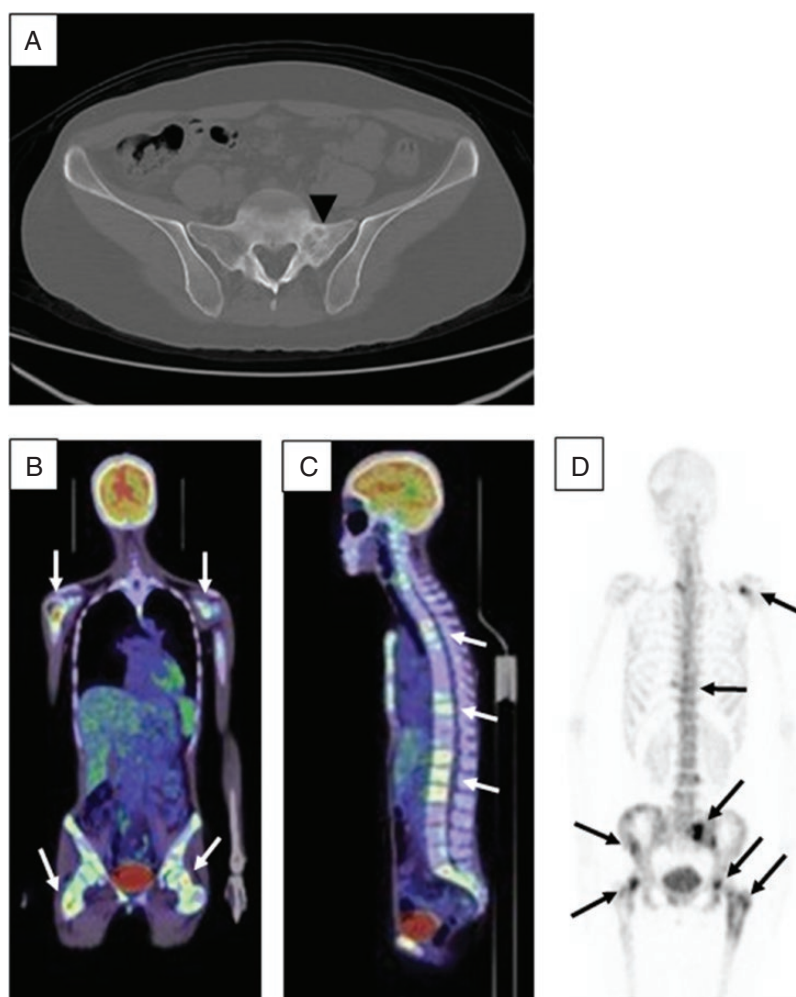
Metastases from primary CNS tumors to extraneural sites are extremely rare. Several hypotheses have been proposed for the rare occurrence of extraneural metastasis relating to the anatomical CNS properties, including the absence of a lymphatic system, the presence of the blood-brain barrier, and the environment of the CNS, which is not sufficiently hostile to select out metastatic clones. Another theory states that it could also be explained by a patient's clinical course, in which death occurred before extraneural metastases could spread. Nonetheless, the exact reasons for the rare occurrence of extraneural metastasis in primary CNS tumors are still unclear.

Of the CNS tumors, oligodendroglioma seems to have the lowest risk of extraneural metastasis.<sup>2</sup> Li et al.<sup>8</sup> reviewed 61 cases of extraneural oligodendroglioma metastases. This study demonstrated that the most frequent metastatic areas outside the CNS were the bone and bone marrow (42.7%), followed by lymph nodes (20.0%), liver (6.4%), scalp (5.5%), and lung (5.5%). Pleura, chest wall, iliopsoas muscle, soft tissue, and parotid gland were other possible areas of metastasis.<sup>8</sup> One study suggested that a high incidence of metastasis to the bone and bone marrow could be explained based on the neural cell adhesion molecule (NCAM). NCAM, also known as CD56, is largely expressed by both gliomas and osteoblasts and is considered to construct NCAM-NCAM binding, thus facilitating the

implantation of oligodendroglioma cells in the bone and bone marrow. Although there are frequent reports of a single metastasis to the bone from oligodendrogliomas, there are very few cases of disseminated bone metastases, such as in the present case.<sup>9–13</sup> [Supplementary Table 1](#) shows the characteristics of the cases of oligodendroglioma with disseminated bone metastases. In 2 of the 5 cases, extraneural metastasis occurred after 4 resection surgeries. Moreover, in 3 of the 5 cases, the metastasis occurred more than 12 months after diagnosis. However, there seems to be no fixed pattern for disseminated bone metastases in oligodendroglioma patients. Furthermore, most studies on the distant extraneural metastasis from anaplastic oligodendroglioma antedate the *IDH1/2* era.

On the other hand, there have been a few reports of bone marrow metastases from *IDH*-mutant astrocytic tumors, including glioblastoma. A study reported that 2 of 4 patients with *IDH1*-mutated glioblastoma developed leptomeningeal metastases.<sup>14</sup> One patient with *IDH1*-mutated secondary glioblastoma had prolonged survival for 11 years, and autopsy showed encasement of the entire bilateral ventricular system through subventricular spread. However, no bone marrow spread was detected despite multiple bone marrow sections examined in the autopsy. Another secondary glioblastoma patient with *IDH1* mutation survived for 10 years but developed thrombocytopenia and bone marrow metastases. Therefore, this study revealed that no conclusions can be drawn regarding the association between *IDH1/2* mutation and bone marrow metastases.

Primary CNS tumors are considered to metastasize through local invasion, cerebrospinal fluid, or hematogenous or lymphogenous pathways. Factors associated with extraneural metastasis have been described, such as multiple craniotomies, shunt surgery, and long-term survival. In



**Figure 3.** CT scan of the pelvis (A) showing an osteoblastic lesion in the left sacral wing (arrowhead). PET-CT scan (B, C) and bone scintigraphy (D) showed multiple high-uptake bony lesions throughout the axial and proximal appendicular skeleton (B, C: white arrows; D: black arrows).

particular, repeat craniotomies seem to be a strong factor for distant metastasis. Hoffman et al. reported 282 cases of CNS tumors with extraneural metastases, including only 24 (8.5%) cases without a previous craniotomy. Similarly, Huang et al.<sup>15</sup> reviewed 247 cases of glioblastoma with extraneural metastases. According to this study, spontaneous extraneural metastasis without previous craniotomy or shunt surgery occurred in only 10 cases. Therefore, surgical interventions could increase the risk of both hematogenous and lymphogenous metastasis by disrupting the blood-brain barrier or by giving tumor cells access to the dura mater or scalp. In the current case, the preceding 4 craniotomies could explain the metastatic spread of the tumor. In addition, the relatively long-term survival in this case following chemoradiotherapy could have allowed for metastasis outside of the CNS. Furthermore, the early multimodal treatment could alter the tumor biology to be more aggressive, and prolonged survival time could allow for the selection of clones that favored distant metastasis. The clinical history of this case supports this hypothesis because the first recurrence happened approximately 5 years after the

initial treatment, whereas the second and third recurrences and bone metastasis occurred within a much shorter period.

## Conclusions

We present a case of 1p/19q-codeleted and *IDH2*-mutant anaplastic oligodendroglioma with multiple metastases to the bone and bone marrow. Although extraneural metastases from oligodendrogliomas are extremely rare, we should bear in mind this rare possibility, especially in patients with prolonged survival time and/or those undergoing more aggressive treatment for the primary tumor. Owing to advancements in the treatment methods for gliomas, longer survivors, particularly patients with *IDH*-mutant gliomas, may possess risk factors for distant metastasis. That is to say, if better intracranial local tumor control could be achieved, distant metastases might become a bigger clinical issue and be observed more frequently in later stages of these diseases.

## Supplementary material

Supplementary material is available online at *Neuro-Oncology Advances* online.

## Keywords

anaplastic oligodendroglioma | bone and bone marrow | *IDH2* mutation | multiple metastases

## Funding

K.M. was supported by grants from the “Grant-in-Aid (C) for Scientific Research” from the Ministry of Health, Labor and Welfare, Japan.

## Acknowledgments

The authors thank Mr. Hiroyasu Yamamoto, Mr. Kyohei Koyama, Mr. Daisuke Hara, and Mr. Yasuyuki Matsui (Department of Rehabilitation, Nagoya University Hospital, Nagoya, Japan) for their excellent technical assistance.

**Conflict of interest statement.** None declared.

## References

1. Louis DN, Perry A, Reifenberger G, et al. The 2016 World Health Organization classification of tumors of the central nervous system: a summary. *Acta Neuropathol.* 2016;131(6):803–820.
2. Liwnicz BH, Rubinstein LJ. The pathways of extraneural spread in metastasizing gliomas: a report of three cases and critical review of the literature. *Hum Pathol.* 1979;10(4):453–467.
3. Davis L. Spongioblastoma multiforme of the brain. *Ann Surg.* 1928;87(1):8–14.
4. Piccirilli M, Brunetto GM, Rocchi G, Giangaspero F, Salvati M. Extra central nervous system metastases from cerebral glioblastoma multiforme in elderly patients. Clinico-pathological remarks on our series of seven cases and critical review of the literature. *Tumori.* 2008;94(1):40–51.
5. Armstrong TS, Prabhu S, Aldape K, et al. A case of soft tissue metastasis from glioblastoma and review of the literature. *J Neurooncol.* 2011;103(1):167–172.
6. Motomura K, Natsume A, Kishida Y, et al. Benefits of interferon- $\beta$  and temozolomide combination therapy for newly diagnosed primary glioblastoma with the unmethylated MGMT promoter: a multicenter study. *Cancer.* 2011;117(8):1721–1730.
7. Appay R, Dehais C, Maurage CA, et al. CDKN2A homozygous deletion is a strong adverse prognosis factor in diffuse malignant IDH-mutant gliomas. *Neuro Oncol.* 2019;21(12):1519–1528.
8. Li G, Zhang Z, Zhang J, et al. Occipital anaplastic oligodendroglioma with multiple organ metastases after a short clinical course: a case report and literature review. *Diagn Pathol.* 2014;9:17.
9. Burgy M, Chenard MP, Noël G, Bourahla K, Schott R. Bone metastases from a 1p/19q codeleted and IDH1-mutant anaplastic oligodendroglioma: a case report. *J Med Case Rep.* 2019;13(1):202.
10. Maloney PR, Yamaki VN, Kumar R, et al. Osteosclerosis secondary to metastatic oligodendroglioma. *Rare tumors.* 2017;9(1):6837.
11. Kural C, Pusat S, Sentürk T, Seçer Hİ, İzci Y. Extracranial metastases of anaplastic oligodendroglioma. *J Clin Neurosci.* 2011;18(1):136–138.
12. Kiko K, Suyama K, Yamamoto K, et al. A case of bone marrow metastasis of oligodendroglioma with IDH mutation and 1p/19q codeletion. *No Shinkei Geka.* 2018;46(8):699–706.
13. Aydemir F, Kardes O, Hasbay B, Sedef AM, Tufan K, Kayaselçuk F. Multiple extraneural metastases of anaplastic oligodendroglioma. *Asian J neurosurg.* 2018;13(3):830–833.
14. Willard N, Kleinschmidt-DeMasters BK. Massive dissemination of adult glioblastomas. *Clin Neuropathol.* 2015;34(6):330–342.
15. Huang P, Allam A, Taghian A, Freeman J, Duffy M, Suit HD. Growth and metastatic behavior of five human glioblastomas compared with nine other histological types of human tumor xenografts in SCID mice. *J Neurosurg.* 1995;83(2):308–315.