

Eosinophilic Cholangitis Without Biliary Stricture After the Treatment of Eosinophilic Esophagitis

Shunta Tanaka, MD¹, Arata Sakai, MD, PhD¹, Atsuhiko Masuda, MD, PhD¹, Shigeto Ashina, MD¹, Kouhei Yamakawa, MD¹, Masahiro Tsujimae, MD¹, Manabu Kurosawa, MD¹, Yuu Satou, MD¹, Ryouta Nakano, MD¹, Takeshi Tanaka, MD¹, Yasutaka Yamada, MD¹, Takuya Ikegawa, MD¹, Seiji Fujigaki, MD, PhD¹, Takashi Kobayashi, MD, PhD¹, Shinwa Tanaka, MD, PhD¹, Hideyuki Shiomi, MD, PhD¹, and Yuzo Kodama, MD, PhD¹

¹Division of Gastroenterology, Department of Internal Medicine, Kobe University Graduate School of Medicine, Kobe, Japan

ABSTRACT

Eosinophilic cholangitis (EC) is an uncommon, benign, self-limiting disease, which typically causes bile duct stricture with eosinophil infiltration. We report the case of a 70-year-old woman who presented with abdominal pain diagnosed with EC after treatment for eosinophilic esophagitis. All previous reported cases of EC had bile duct stricture seen on magnetic resonance cholangiopancreatography or cholangiogram during endoscopic retrograde cholangiopancreatography, but only wall thickness of the common bile duct was noted in our case. Although rare, EC should be considered when wall thickening of the bile duct is observed, even without stricture.

INTRODUCTION

Eosinophilic cholangitis (EC) is a rare disease that can result in biliary obstruction.¹ EC exhibits similar imaging findings, such as biliary stricture and wall thickness of the bile duct, to cholangiocarcinoma, primary sclerosing cholangitis (SC), and immunoglobulin G4 (IgG4)-related SC.² We want to emphasize that EC is a rare entity that is overlooked, but it is important to consider in the differential because EC can be treated with steroids favorably, and unnecessary surgery can be avoided.³

CASE REPORT

A 70-year-old woman was admitted to our hospital with abdominal pain. There was no history of jaundice and no elevation of liver enzymes. She had a past history of eosinophilic esophagitis and had received glucocorticoid therapy (prednisolone: 2.5–7.5 mg/d) for 1 year. On physical examination, she had tenderness on the right-upper-quadrant lesion. The complete blood count revealed a total white cell count of 6,800/ μ L, with a differential of 6.9% eosinophils, hemoglobin level of 12.4 g/dL, hematocrit level of 38.3%, and platelet count of 25.4×10^4 / μ L. Liver function tests (LFTs) demonstrated aspartate transaminase of 159 U/L, alanine transaminase of 400 U/L, gamma-glutamyl transpeptidase of 732 U/L, alkaline phosphatase of 996 U/L, and total bilirubin of 1.9 mg/dL. Hepatitis virus screening and tumor and immunological markers, including carcinoembryonic antigen, antinuclear antibody, anti-mitochondrial antibody, and IgG4, were negative. On contrast-enhanced computed tomography (CT) of the abdomen, diffuse wall thickening, and contrast enhancement of the common bile duct (CBD) and gallbladder without radio-opaque stones were noted (Figure 1). Magnetic resonance cholangiopancreatography demonstrated no obvious CBD stricture.

On the second day of hospitalization, her abdominal pain worsened. gallbladder swelling and wall thickening with debris were observed on abdominal ultrasound. We diagnosed acute cholecystitis and recommended laparoscopic cholecystectomy, but she refused the surgical therapy. Therefore, we performed percutaneous transhepatic gallbladder aspiration. After percutaneous transhepatic gallbladder aspiration, her abdominal pain improved, but LFT values remained elevated. To investigate small choledocholithiasis or other bile duct disease that attributing LFT elevation, we performed endoscopic ultrasound and

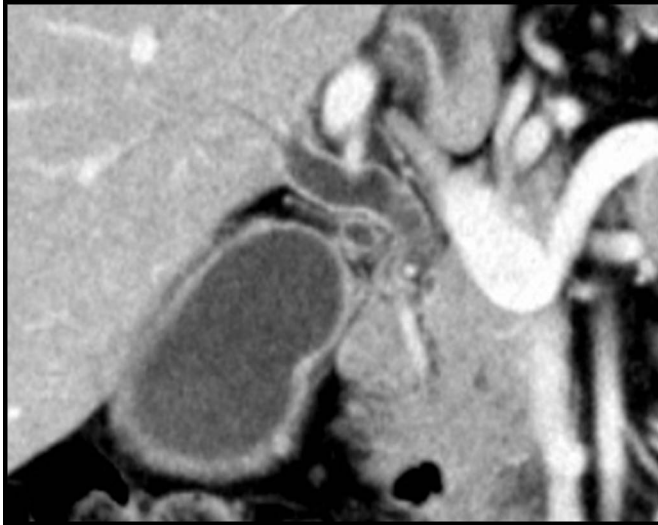

Figure 1. Contrast-enhanced computed tomography of the abdomen showing diffuse wall thickening, and contrast enhancement of the common bile duct and gallbladder without radio-opaque stones.

endoscopic retrograde cholangiopancreatography. Endoscopic ultrasound revealed diffuse gallbladder and CBD wall thickening. No biliary stricture that suspects cholangiocarcinoma was noted on endoscopic retrograde cholangiopancreatography, and intraductal ultrasound indicated diffuse CBD wall thickening (Figure 2). On biliary biopsy of the CBD, marked infiltration of eosinophilic cells, which accounted for more than 60 cells per high-power field, was observed in addition to abundant lymphocytes and plasma cells within the biliary

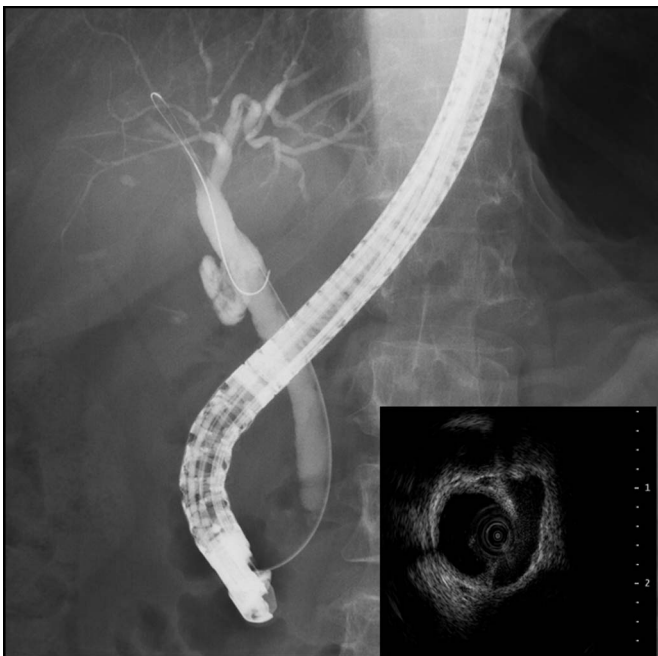

Figure 2. Endoscopic retrograde cholangiography demonstrating no biliary abnormalities. Intraductal ultrasound indicated uniform wall thickening toward the papilla from the hilar, but no biliary pancreatic duct confluence abnormalities.

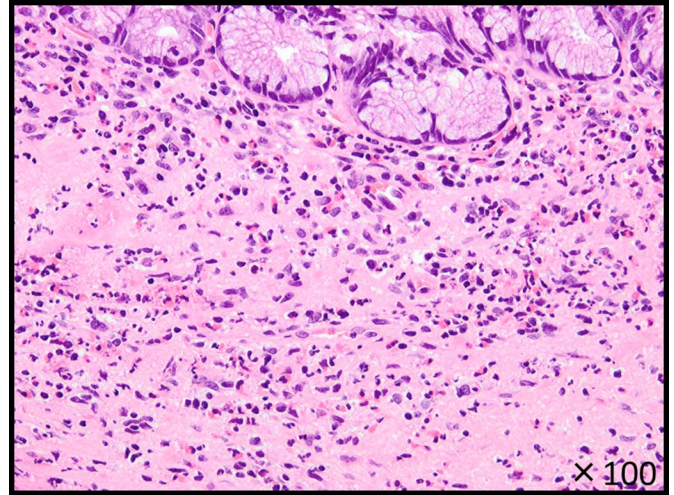


Figure 3. Biliary biopsy showing marked infiltration of eosinophilic cells was observed in addition to abundant lymphocytes and plasma cells within the stroma. There was no evidence of malignancy and immunoglobulin G4 staining was negative.

stroma. There was no evidence of malignancy and IgG4 staining was negative (Figure 3).

Based on pathological and imaging findings, we made a diagnosis of EC and cholecystitis. When we made diagnosis of EC, she was treated with 2.5 mg/d prednisolone for eosinophilic esophagitis. We had increased prednisolone to 30 mg/d, and the LFT values decreased promptly. After that, prednisolone was tapered to 2.5 mg by 4 months. Contrast-enhanced CT of abdomen 2 months after increasing the prednisolone dose revealed the disappearance of wall thickening and contrast enhancement of the CBD and gallbladder (Figure 4).

However, when prednisolone was reduced to 2.5 mg/d, the LFT values became elevated again. Therefore, prednisolone was

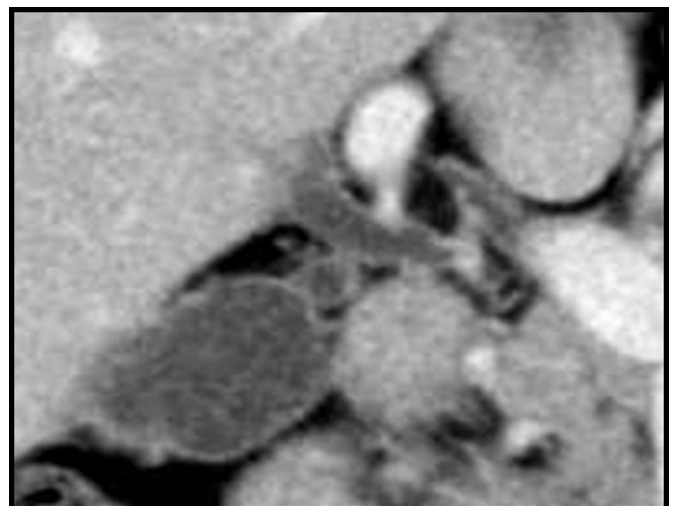


Figure 4. Contrast-enhanced computed tomography of the abdomen after 2 months of increasing the prednisolone dose showing common bile duct and gallbladder thickening.

increased to 20 mg/d, and the LFTs decreased again. Eosinophil counts were also elevated when the LFT values were elevated. The patient is now followed up at our outpatient clinic with prednisolone 2.5 mg/d and is asymptomatic with normal LFT values and has remained without CBD wall thickening on contrast-enhanced CT. We plan to follow the patient with magnetic resonance cholangiopancreatography or contrast-enhanced CT.

DISCUSSION

EC is a rare disease characterized by eosinophil infiltration of the bile duct. In 1985, the disease concept was proposed by Butler et al.⁴ It is referred to cholangiopathy because it is related to cholecystitis.^{4,5} A comprehensive literature review identified only 27 cases of EC in which clinical data are available. The average age was 41.4 years old, and the ratio of men to women was 1.25. The chief complaint was abdominal pain 44.4%, fever 18.5%, and jaundice 29.6%. Among these 27 cases, 15 (55.5%) demonstrated peripheral eosinophilia. As it can result in biliary stricture, the imaging findings and clinical symptoms are often similar to those of cholangiocarcinoma, IgG4 SC, and primary SC.² It is important to be able to distinguish EC from cholangiocarcinoma. Matsumoto et al reported that it is important to diagnose EC based on wall thickening or stenosis of the biliary system, histopathological findings of eosinophilic infiltration, and reversibility of biliary abnormalities without treatment or following steroid treatment. Indeed, most of the cases of EC in previous reports had biliary stenosis.^{6,7} In our case, diffuse wall thickening of the CBD was observed, but biliary stenosis was not noted. However, the biopsy specimen taken from the thickened bile duct wall demonstrated marked infiltration of eosinophilic cells, supporting our final diagnosis of EC. To our knowledge, this is the first report of EC without biliary stricture.

Although infiltration of inflammatory cells, mainly eosinophils, causes thickening and narrowing of the walls of the bile duct, its pathogenesis remains poorly understood.² EC may occur as a manifestation of eosinophilia, such as in hypereosinophilic syndrome, but it is also known to occur secondary to inflammation such as in cholelithiasis, parasitic infection of echinococcosis, and allergies.^{8–11} This case was first thought to be idiopathic EC because it did not meet the diagnostic criteria for hypereosinophilic syndrome, and there were no new drugs or infection present. EC is often associated with eosinophilic gastroenteritis or other allergic diseases.¹² Thus, this is the first reported case of EC coexisting with eosinophilic esophagitis, but it suggests that some common etiologies underlie the development of eosinophilic esophagitis and EC.

The diagnostic criteria and standard treatments for EC have not been established. In our case and as reported by Matsumoto et al, resolution of abnormal imaging findings and LFT values by oral corticosteroid therapy further confirmed our diagnosis of EC.⁶

Although oral corticosteroid therapy is considered to be the first-line treatment based on its favorable response rate, most of the published cases of EC were treated surgically and diagnosed retrospectively.^{3,6} Seow-En et al reported definitive treatment with surgery to be the best option to make a definitive diagnosis and prevent recurrence.¹ However, as in this case without biliary stricture, a definitive diagnosis by endoscopic tissue collection followed by oral corticosteroid therapy should precede surgery. We described a case of EC without biliary stricture. Although rare, EC should be considered when hepatobiliary enzymes are elevated and wall thickening of the bile duct is observed.

DISCLOSURES

Author contributions: All authors wrote and edited the manuscript. Y. Kodama is the article guarantor.

Financial disclosure: None to report.

Informed consent was obtained for this case report.

Received October 29, 2018; Accepted February 28, 2019

REFERENCES

1. Seow-En I, Chiow AK, Tan SS, Poh WT. Eosinophilic cholangiopathy: The diagnostic dilemma of a recurrent biliary stricture. Should surgery be offered for all? *BMJ Case Rep.* 2014; 2014.
2. Nashed C, Sakpal SV, Shusharina V, Chamberlain RS. Eosinophilic cholangitis and cholangiopathy: A sheep in wolves clothing. *HPB Surg.* 2010; 2010:906496.
3. Hoilat JN, Holiat G, AlQahtani S, Alhussaini HF, Alabbad SI. Atypical presentation of a rare disease: Eosinophilic cholangitis posing as a cancer. *Am J Case Rep.* 2018;19:76–81.
4. Butler TW, Feintuch TA, Caine WP. Eosinophilic cholangitis, lymphadenopathy, and peripheral eosinophilia: A case report. *Am J Gastroenterol.* 1985;80:572–4.
5. Tenner S, Roston A, Lichtenstein D, Brooks D, Herlihy E, Carr-Locke D. Eosinophilic cholangiopathy. *Gastrointest Endosc.* 1997;45:307–9.
6. Matsumoto N, Yokogawa K, Nakai K, et al. A case of eosinophilic cholangitis: Imaging findings of contrast-enhanced ultrasonography, cholangioscopy, and intraductal ultrasonography. *World J Gastroenterol.* 2007;13:1995–7.
7. Hokuto D, Yamato I, Nomi T, et al. Eosinophilic cholangitis coexisted with idiopathic thrombocytopenic purpura: Report of a case. *Hepatol Res.* 2015; 45:595–600.
8. Grauer L, Padilla VM III, Bouza L, Barkin JS. Eosinophilic sclerosing cholangitis associated with hypereosinophilic syndrome. *Am J Gastroenterol.* 1993;88:1764–9.
9. Rodgers MS, Allen JP, Koea JB, McCall JL. Eosinophilic cholangitis: A case of “malignant masquerade”. *HPB (Oxford).* 2001;3:235–9.
10. Raptou G, Pliakos I, Hytiroglou P, Papavramidis S, Karkavelas G. Severe eosinophilic cholangitis with parenchymal destruction of the left hepatic lobe due to hydatid disease. *Pathol Int.* 2009;59:395–8.
11. Ureles AL, Alschibaja T, Lodico D, Stabins SJ. Idiopathic eosinophilic infiltration of the gastrointestinal tract, diffuse and circumscribed; a proposed classification and review of literature, with two additional cases. *Am J Med.* 1961;30:899–909.
12. Fragulidis GP, Vezakis AI, Kontis EA, et al. Eosinophilic cholangitis-A challenging diagnosis of benign biliary stricture: A case report. *Medicine (Baltimore).* 2016;95:e2394.

Copyright: © 2019 The Author(s). Published by Wolters Kluwer Health, Inc. on behalf of The American College of Gastroenterology. This is an open-access article distributed under the terms of the Creative Commons Attribution-Non Commercial-No Derivatives License 4.0 (CCBY-NC-ND), where it is permissible to download and share the work provided it is properly cited. The work cannot be changed in any way or used commercially without permission from the journal.