

## Role for Positron Emission Tomography-Computed Tomography in Melioidosis

Sir,  
We read with interest the case series, “18-Fluorine-Fluorodeoxyglucose Positron Emission Tomography-Computed Tomography (PET-CT) in the Evaluation of the Great Masquerader Melioidosis: A Case Series,” by Kulkarni *et al.*, published in the July–September issue of *Indian Journal of Nuclear Medicine*.<sup>[1]</sup> The authors have discussed the diagnostic utility of PET-CT in two patients with pyrexia of unknown origin (PUO), an indication for which PET-CT has been discussed in previously published literature.<sup>[2-4]</sup> The two patients were subsequently diagnosed with melioidosis. The authors have performed PET-CT before achieving a diagnosis of melioidosis, rather than part of evaluation of proven melioidosis, as the title suggests. However, we believe that the authors have raised an interesting point and led us to consider and propose PET-CT as an ideal investigation in the evaluation of proven melioidosis, with the illustration of a patient who recently presented to us.

A 34-year-old male with no significant history presented with 5 days of fever, cough, purulent sputum, and dyspnea. He had fever, tachycardia, tachypnea with room air peripheral saturation of 92%, and bilateral basilar crackles on chest auscultation. Abdominal and neurological examination was normal. Apart from anemia and leukocytosis, the blood hematology and biochemistry were normal. Serology for human immunodeficiency virus and scrub typhus were negative. Peripheral smear did not reveal malarial parasites. Chest radiograph [Figure 1a] showed bilateral lung nodules. He was diagnosed with community-acquired pneumonia, and after sending sputum and blood cultures, he was initiated on intravenous (IV) ceftriaxone and admitted in the ward. His sputum and blood culture [Figure 1b and c] confirmed *Burkholderia pseudomallei*, following which he was switched to IV ceftazidime. PET-CT was performed, which showed bilateral lung nodules with mild FDG uptake, some with feeding vessel sign, and mediastinal lymphadenopathy, with no evidence of uptake elsewhere [Figure 1d]. He improved clinically with 2 weeks of IV ceftazidime and was discharged on oral cotrimoxazole for 3 months. Chest radiograph 3 months later showed complete resolution [Figure 1e].

Although melioidosis commonly presents with pulmonary involvement, it can involve various other organs, including liver, spleen, lymph nodes, bones, joints, skin, and the central nervous system.<sup>[5,6]</sup> Treatment of melioidosis consists of a 2–4-week intensive phase to treat bacteremia, followed by an eradication phase to eliminate any residual

focus of bacteria. The duration of this eradication phase is determined by extent of multifocal involvement and evidence of deep seated infection. The failure of eradication may lead to a future relapse.<sup>[7]</sup> Hence, it becomes important to image various organ systems, including abdomen and the axial and appendicular skeleton, to identify disease involvement elsewhere. Such a multimodality imaging approach, which may include an ultrasound of abdomen and magnetic resonance imaging of spine, may be cumbersome and can be replaced by a whole-body (PET-CT) scan, which can additionally detect disease in less common sites.

The use of PET-CT scan in the management of melioidosis is infrequently reported and was reviewed by the authors. Table 1 summarizes the available literature.<sup>[1,8-11]</sup> The indications for PET-CT in the reviewed publications were varied and included (1) to identify possible malignancy or metastases in a patient with clinical suspicion of malignancy,<sup>[8,10,11]</sup> (2) to look for other sites of organ involvement in a patient with blood culture-proven melioidosis,<sup>[9]</sup> (3) in the evaluation of PUO and to identify an appropriate diagnostic investigation,<sup>[1]</sup> and (4) in the follow-up of patients with melioidosis and multiple site involvement to assess response to treatment.<sup>[8,10]</sup> Except for three, all the patients reported above had chronic symptoms and were being evaluated for possible malignancy or PUO. Two patients, who had symptoms for 4 days and 2 weeks, respectively, had thoracic radiology that was suspicious for malignancy and hence were subjected to PET-CT.<sup>[10,11]</sup> Only in one patient, who had a subacute presentation, PET-CT was done after a positive culture of melioidosis, with the aim of searching for disease involvement in other sites, similar to our indication.<sup>[9]</sup> We believe that this indication has its benefits in avoiding multiple system-specific imaging, helps identify asymptomatic disease sites that may be responsible for future relapse if left untreated, and thus helps decide on duration of eradication therapy.<sup>[8]</sup>

### Declaration of patient consent

The authors certify that they have obtained all appropriate patient consent forms. In the form, the patient has given his consent for his images and other clinical information to be reported in the journal. The patient understands that his name and initials will not be published and due efforts will be made to conceal identity, but anonymity cannot be guaranteed.

### Acknowledgment

We would like to thank Dr. Arunan Murali MD, Professor, Department of Radiology, for his contribution to reporting and interpretation of PET-CT scan.

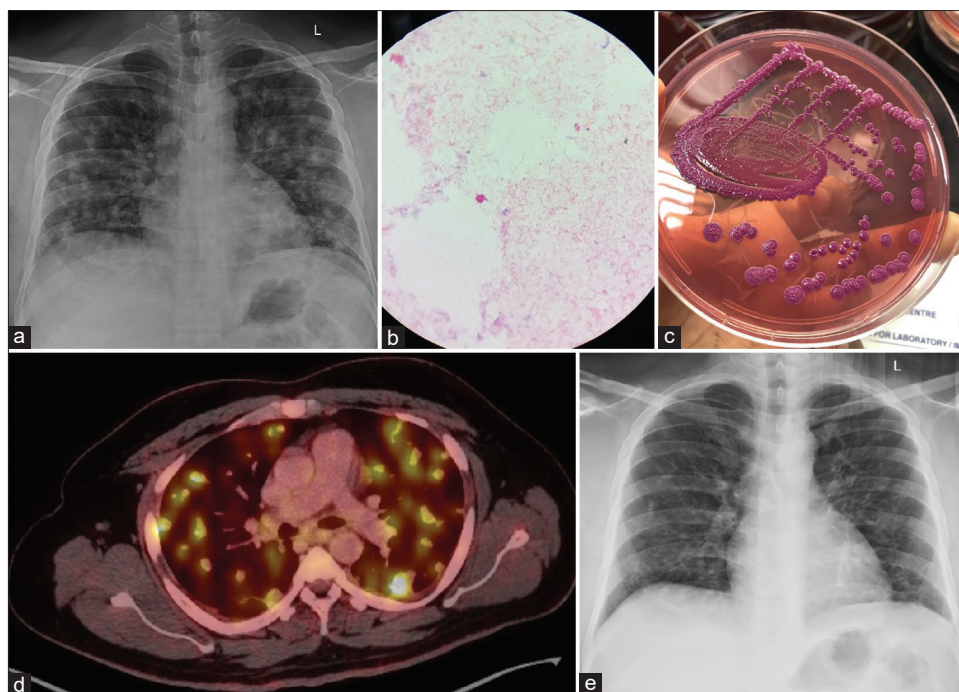


Figure 1: (a) Chest radiograph showing bilateral lung nodules. (b) Gram stain of sputum sample showing Gram-negative rods with beaded ends. (c) Blood culture on MacConkey agar at 72 h of incubation showing colonies with dry, wrinkled, and metallic sheen appearance suggestive of *Burkholderia pseudomallei*. (d) Positron-emission tomography-computed tomography scan of thorax at the level of bifurcation of main pulmonary artery showing bilateral variable sized random lung nodules, some with feeding vessel sign and mediastinal lymphadenopathy. (e) Chest radiograph after 3 months of eradication therapy

**Table 1: Review of previously published literature on positron emission tomography-computed tomography in melioidosis**

Number of patients, nature of publication, year of publication	Age; sex; primary symptoms (s); duration of symptoms, underlying comorbidity	Primary imaging; Indication for PET-CT scan; differential diagnosis	Pulmonary symptoms; lung involvement on PET-CT and SUV uptake; other organ involvement on PET	Diagnostic sample; treatment given; clinical outcome; duration of eradication phase
1, case report, 2013 <sup>[8]</sup>	55 years; male; fever, weight loss, right shoulder pain; 6 months; none	X ray and subsequent MRI identified osteolytic lesion in the right humerus; to study extent of disease and identify other disease sites; malignant metastasis	None, incidental single left lower lobe of lung cavitating nodule with SUV 1.8; right humerus lesion	Bone marrow culture; appropriate antibiotic; improved with repeat PET-CT documenting response to treatment; 6 months
1, case report, 2016 <sup>[9]</sup>	25 years; female; fever, weight loss, painful swelling of right wrist and knee; 3 weeks; none	MRI identified right palmar tenosynovitis, right femoral osteomyelitis and subsequent blood culture diagnostic; To identify other sites of disease involvement; none	None; multifocal involvement with unspecified uptake value; liver, lymph node, skin, muscle	Blood culture; appropriate antibiotic and surgical debridement; improved with repeat PET documenting response to treatment; 12 months
1, case report, 2019 <sup>[10]</sup>	41; female; chest pain; 4 days; smoker	CXR revealed right midzone opacity; to rule out malignancy; malignancy	Chest pain and dyspnea; right lower lobe mass with mild-to-moderate uptake; none	Bronchial brushings and TBLC aided by EBUS guide sheath; appropriate antibiotic; improved; 3 months
1, case report, 2020 <sup>[11]</sup>	57 years; male; fever, cough, chest pain; 2 weeks; systemic hypertension, hyperlipidemia	CXR: Left pleural effusion, lower zone subpleural opacity, hilar enlargement, CT thorax: Left lower lobe mass, pleural effusion, and mediastinal lymphadenopathy; to rule out malignancy; malignancy	Chest pain; left lower lobe lung mass with SUV 7.9, pleural effusion and hilar lymphadenopathy; none	Percutaneous biopsy; appropriate antibiotic; improved; 21 weeks

Contd...

Table 1: Contd...

Number of patients, nature of publication, year of publication	Age; sex; primary symptoms (s); duration of symptoms, underlying comorbidity	Primary imaging; Indication for PET-CT scan; differential diagnosis	Pulmonary symptoms; lung involvement on PET-CT and SUV uptake; other organ involvement on PET	Diagnostic sample; treatment given; clinical outcome; duration of eradication phase
2, case series, 2020 <sup>[1]</sup>	39 years male; fever, weakness, skin lesions; 3 months; diabetes mellitus 46 years male; fever; 4 months; diabetes mellitus	Ultrasound: Splenomegaly, ascites, bilateral pleural effusion, CXR: Right multiple pleural-based nodular lesions; evaluation of PUO; vasculitis, infection PET-CT scan; evaluation of PUO; infection	None; lung nodules with unspecified SUV; lytic lesions of axial and appendicular skeleton, hepatosplenomegaly, lymphadenopathy 2. None; none; multiple abscesses in the left kidney, abdominal lymphadenopathy	Blood culture; unspecified; unspecified Image-guided biopsy and culture; unspecified; unspecified

PET-CT: Positron-emission tomography-computed tomography, SUV: Standardized uptake value, MRI: Magnetic resonance imaging, CXR: Chest X-ray, TBLC: Transbronchial lung cryobiopsy, EBUS: Endobronchial ultrasound, CT: Computed tomography, PUO: Pyrexia of unknown origin

### Financial support and sponsorship

Nil.

### Conflicts of interest

There are no conflicts of interest.

**Irfan Ismail Ayub, Dhanasekar Thangaswamy, Vidya Krishna<sup>1</sup>, Kopula Sathyamoorthy Sridharan<sup>2</sup>**

*Departments of Pulmonary Medicine, <sup>1</sup>Infectious Diseases and <sup>2</sup>Microbiology, Sri Ramachandra Medical College and Research Institute, SRIHER, Chennai, Tamil Nadu, India*

**Address for correspondence:**

*Prof. Irfan Ismail Ayub,*

*Department of Pulmonary Medicine, Sri Ramachandra Medical College and Research Institute, SRIHER, Porur, Chennai, Tamil Nadu, India.*

*E-mail: iia@rediffmail.com*

**Received:** 02-12-2020

**Accepted:** 29-05-2021

**Published:** 23-09-2021

### References

- Kulkarni P, Shelley S, Elangoven IM, Jaykanth A, Ejaz AP, Rao NS. 18-fluorine-fluorodeoxyglucose positron emission tomography-computed tomography in the evaluation of the great masquerader melioidosis: A case series. *Indian J Nucl Med* 2020;35:222-5.
- Kan Y, Wang W, Liu J, Yang J, Wang Z. Contribution of 18F-FDG PET/CT in a case-mix of fever of unknown origin and inflammation of unknown origin: A meta-analysis. *Acta Radiol* 2019;60:716-25.
- Bharucha T, Rutherford A, Skeoch S, Alavi A, Brown M, Galloway J. FDG-PET/CT in fever of unknown origin working group. Diagnostic yield of FDG-PET/CT in fever of unknown origin: A systematic review, meta-analysis, and Delphi exercise. *Clin Radiol* 2017;72:764-71.
- Singh N, Kumar R, Malhotra A, Bhalla AS, Kumar U, Sood R. Diagnostic utility of fluorodeoxyglucose positron emission tomography/computed tomography in pyrexia of unknown origin. *Indian J Nucl Med* 2015;30:204-12.

- Gassiep I, Armstrong M, Norton R. Human melioidosis. *Clin Microbiol Rev* 2020;33:e00006-19.
- Alsaif HS, Venkatesh SK. Melioidosis: Spectrum of radiological manifestations. *Saudi J Med Med Sci* 2016;4:74-8.
- Sullivan RP, Marshall CS, Anstey NM, Ward L, Currie BJ. 2020 Review and revision of the 2015 Darwin melioidosis treatment guideline; paradigm drift not shift. *PLoS Negl Trop Dis* 2020;14:e0008659.
- Subran B, Ackermann F, Watin-Augouard L, Rammaert B, Rivoisy C, Vilain D, *et al.* Melioidosis in a European traveler without comorbidities: A case report and literature review. *Int J Infect Dis* 2013;17:e781-3.
- Conrad A, Valour F, Ferry T, Ader F, Lyon BJI Study Group. Multifocal melioidosis with femoral osteomyelitis in a healthy 25-year-old traveller. *BMJ Case Rep.* 2016 Jul 18;2016:bcr2016216356.
- Zaw KK, Wasgewatta SL, Kwong KK, Fielding D, Heraganahally SS, Currie BJ. Chronic pulmonary melioidosis masquerading as lung malignancy diagnosed by EBUS guided sheath technique. *Respir Med Case Rep* 2019;28:100894.
- Zhao J, Yap A, Wu E, Yap J. A mimic of bronchogenic carcinoma-Pulmonary melioidosis. *Respir Med Case Rep* 2020;29:101006.

This is an open access journal, and articles are distributed under the terms of the Creative Commons Attribution-NonCommercial-ShareAlike 4.0 License, which allows others to remix, tweak, and build upon the work non-commercially, as long as appropriate credit is given and the new creations are licensed under the identical terms.

Access this article online	
<b>Quick Response Code:</b> 	<b>Website:</b> <a href="http://www.ijnm.in">www.ijnm.in</a>
	<b>DOI:</b> 10.4103/ijnm.ijnm_227_20

**How to cite this article:** Ayub II, Thangaswamy D, Krishna V, Sridharan KS. Role for positron emission tomography-computed tomography in melioidosis. *Indian J Nucl Med* 2021;36:354-6.

© 2021 Indian Journal of Nuclear Medicine | Published by Wolters Kluwer - Medknow