

Acute thrombosis of a transplanted renal artery after gastric ulcer bleeding in a patient with a long-term well-functioning renal allograft

A case report and literature review

Chung-Kuan Wu, MD^{a,b}, Jyh-Gang Leu, MD, PhD^{a,c}, Cheng-Chun Wei, MD^d, Shih-Chung Hsieh, MD^{a,*}

Abstract

Background: Acute thrombosis of a transplanted renal artery is a serious vascular complication following renal allograft transplantation, which usually occurs within the first month after transplantation and often results in graft loss. It rarely occurs beyond the first month, except in a rejected kidney or in a kidney with high-grade transplant renal artery stenosis.

Result: A 65-year-old male with a history of type 2 diabetes mellitus, hypertension, pulmonary tuberculosis, and end-stage renal disease was previously treated with hemodialysis (HD). He received a kidney transplant and had a well-functioning graft for 2 years. He presented to our emergency department with gastric ulcer bleeding and received treatment involving an endoscopic submucosal epinephrine injection, a proton pump inhibitor, and blood transfusions. Nine days later, he complained of sudden lower abdominal pain and had acute anuric kidney failure. Renal ultrasonography revealed an absence of blood flow to the allograft kidney. Renal artery angiogram demonstrated complete occlusion of the transplanted renal artery. After thrombectomy and percutaneous transluminal angioplasty (PTA) with stent placement, 60% stenosis of the proximal renal artery with distal perfusion was noted. However, his graft function did not improve, and he received HD again. Histopathology of the transplanted kidney revealed ischemic tubular nephropathy with focal infarction without rejection.

Conclusion: This is the first case of acute thrombosis of the transplanted renal artery following gastric ulcer bleeding in a patient with a long-term well-functioning graft kidney.

Abbreviations: APS = antiphospholipid syndrome, BUN = blood urea nitrogen, Hct = hematocrit, HD = hemodialysis, HUS = hemolytic uremic syndrome, PTA = percutaneous transluminal angioplasty.

Keywords: acute transplant renal artery thrombosis, gastric ulcer bleeding, renal allograft thrombosis

1. Introduction

Arterial thrombosis in a transplanted kidney is a serious complication that often results in graft loss.^[1] It typically occurs within the first month following transplantation, and more than

90% of cases occur within the first year.^[2,3] The incidence of transplant renal artery thrombosis ranges between 0.2% and 3.5%. It is associated with technical surgical problems such as vessel kinking, torsion, and intimal injuries, drugs such as cyclosporine and orthoclone OKT3, hypercoagulable states, and hyperacute and acute rejection.^[1,2,4-7] Beyond the first month after transplantation, transplant renal artery thrombosis rarely occurs, except in a rejected kidney or in a kidney with high-grade arterial stenosis.

Here, we report the case of a patient with a long-term well-functioning renal allograft who suffered from acute graft loss because of transplant renal artery thrombosis after gastric ulcer bleeding.

2. Case report

A 65-year-old male with type 2 diabetes mellitus and hypertension had a history of pulmonary tuberculosis and end-stage renal disease. He had been on hemodialysis (HD) for 6 years before receiving a deceased donor kidney transplant. The transplanted renal artery was anastomized end-to-side to the recipient's external iliac artery. His graft function continued functioning appropriately under immunosuppression therapy for 2 years. His serum creatinine and tacrolimus levels were 0.9 mg/dL (reference range, 0.5–1.3 mg/dL) and 9.4 ng/mL (reference range, 5–20 ng/mL), respectively, in the half-year before admission. Type 2 diabetes mellitus and hypertension were in control, and his past medical regimen included glipizide, bariquinone, carvedilol, and irbesartan.

Editor: Hirohito Ichii.

Ethical statement: Ethical approval was not necessary for this study because our case study was focused on the retrospective observation of a patient's hospital course. Informed consent was obtained from the patient regarding the reporting and publication of this case report.

The authors have no conflicts of interest to disclose.

^a Division of Nephrology, Department of Internal Medicine, Shin-Kong Wu Ho-Su Memorial Hospital, ^b Institute of Clinical Medicine, National Yang-Ming University, Taipei, ^c School of Medicine, Fu-Jen Catholic University, New Taipei City,

^d Division of Cardiology, Department of Internal Medicine, Shin-Kong Wu Ho-Su Memorial Hospital, Taipei, Taiwan.

* Correspondence: Shih-Chung Hsieh, Division of Nephrology, Department of Internal Medicine, Shin-Kong Wu Ho-Su Memorial Hospital, Taipei, Taiwan, 95, Wen Chang Rd., Shih Lin District, Taipei 11101, Taiwan (e-mail: m008533@ms.skh.org.tw).

Copyright © 2016 the Author(s). Published by Wolters Kluwer Health, Inc. All rights reserved.

This is an open access article distributed under the terms of the Creative Commons Attribution-Non Commercial-No Derivatives License 4.0 (CCBY-NC-ND), where it is permissible to download and share the work provided it is properly cited. The work cannot be changed in any way or used commercially.

Medicine (2016) 95:30(e4301)

Received: 18 December 2015 / Received in final form: 23 April 2016 / Accepted: 28 June 2016

<http://dx.doi.org/10.1097/MD.0000000000004301>

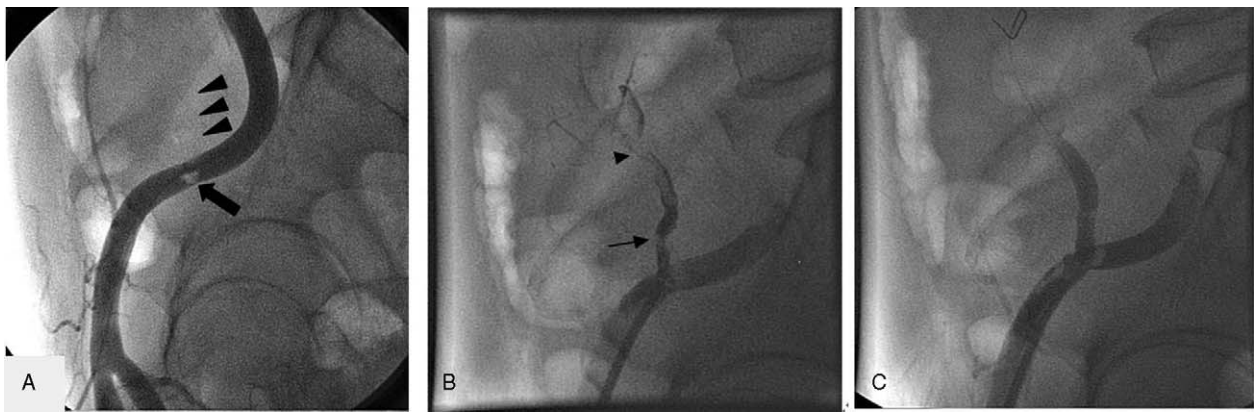


Figure 1. Angiogram of the transplanted renal artery. (A) Thrombus in the anastomosis of the transplanted renal artery and external iliac artery (arrow), and complete occlusion of the transplanted renal artery (arrowheads) before thrombectomy. (B) Significant (60%) stenosis of the proximal transplant renal artery (arrow) after thrombectomy, and still thrombus in the distal transplant renal artery (arrow). (C) Perfusion of the transplanted renal artery after percutaneous transluminal angioplasty with stent placement.

He visited our emergency department because of tarry stool for 1 day. Physical examination revealed a blood pressure of 120/55 mm Hg, pulse rate of 88 beats/min, and temperature of 36.2°C. Hemogram revealed a hematocrit (Hct) of 20.3% (reference range, 35–48%), leukocyte count of $6.1 \times 10^3/\mu\text{L}$ (reference range, $3.8\text{--}10 \times 10^3/\mu\text{L}$), and platelet count of $1.82 \times 10^5/\mu\text{L}$ (reference range, $1.4\text{--}4.5 \times 10^5/\mu\text{L}$). Prothrombin time and activated partial thromboplastin time were 12 (range, 9.4–12.5 seconds) and 32 seconds (range, 26–38 seconds), respectively. Biochemistry assay revealed blood urea nitrogen (BUN) and serum creatinine levels of 36 (range, 7–25 mg/dL) and 1.3 mg/dL, respectively. Panendoscopy revealed a huge gastric ulcer with active bleeding, and 28 mL of diluted epinephrine (1:10,000) was injected locally. He was treated with proton pump inhibitors and transfused with 4 packed red blood units. He was hospitalized thereafter.

On hospital day 1, follow-up panendoscopy showed a giant ulcer 3 cm in diameter with little fresh blood oozing in the antrum; 16 mL of diluted epinephrine was injected locally, and 1 metallic clip was applied. After treatment, the Hct levels increased from 20.3% to 27.2%, and BUN and serum creatinine levels were 31 and 0.9 mg/dL, respectively. On hospital day 4, Hct increased to 31%.

On hospital day 9, he complained of sudden onset of lower abdominal pain followed by anuria and intermittent tarry stool. BUN and serum creatinine levels were 23 and 1.9 mg/dL,

respectively, on hospital day 10, and they were 29 and 3.1 mg/dL, respectively, on hospital day 11. During this period, he had been anuric even after diuretic treatment. His tacrolimus level was 15.0 ng/mL. Renal duplex ultrasonography detected an absence of blood flow to the allograft kidney. Renal artery angiogram revealed complete occlusion of the transplant artery and no distal perfusion. After thrombectomy, 60% stenosis of the orifice of the transplanted renal artery was observed. Distal flow was subsequently detected after percutaneous transluminal angioplasty (PTA) with stent placement (Fig. 1).

After treatment, the daily urine output was 30 mL. BUN and serum creatinine levels increased to 40 and 4.7 mg/dL, respectively, on hospital day 12 and to 64 and 7.6 mg/dL, respectively, on hospital day 13. Other laboratory data revealed anticardiolipin concentration of 4.1 (range: 0–11) $\mu\text{L}/\text{mL}$ and negative lupus anticoagulant. Histopathological examination of the transplanted kidney on hospital day 16 showed ischemic tubular nephropathy with focal infarction (Fig. 2) without antibody-mediated and T-cell mediated rejection. He returned to chronic HD subsequently.

3. Discussion

Acute thrombosis of a transplanted renal artery beyond the first month after transplantation is distinctly uncommon, except in a rejected kidney or in a kidney with high-grade arterial stenosis.

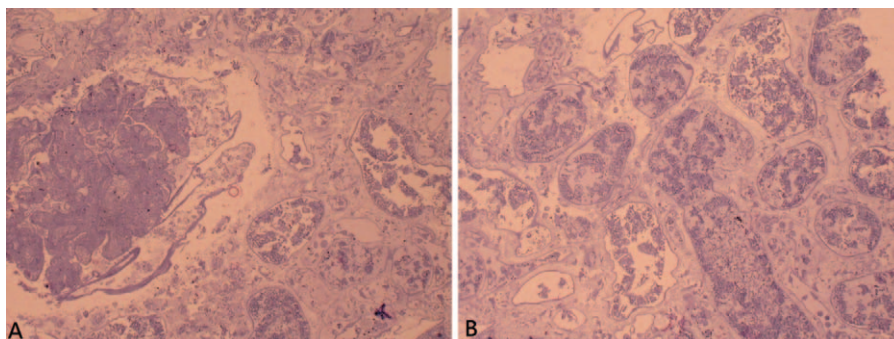


Figure 2. Histopathology of the transplanted kidney. (A) Coagulative necrosis of the glomerulus. (B) Ischemic necrosis of tubules.

The histology of the transplanted kidney in our patient demonstrated ischemic tubular nephropathy with coagulative necrosis without rejection. In addition to no signs of acute rejection, our patient did not interrupt his immunosuppressive therapy because acute rejection usually develops in patients discontinuing immunosuppressive therapy.

An end-to-end anastomosis of the transplanted renal artery to the internal iliac artery and end-to-side anastomosis of the transplanted renal artery to the external iliac artery are the most common techniques for arterial anastomosis in kidney transplantation. The end-to-end anastomosis involves a higher incidence of stenosis compared with end-to-side anastomosis, although the procedure is easier and faster to perform and does not compromise circulation to the leg.^[8] Furthermore, more than 75% stenosis of the transplanted renal artery is called high-grade arterial stenosis.^[9] Here, the renal artery was anastomized end-to-side to the patient's external iliac artery. After thrombectomy, angiogram revealed 60% stenosis of the proximal transplant renal artery. These findings indicate that high-grade transplant renal arterial stenosis is not the etiology of transplant renal artery thrombosis.

Two case studies have reported that patients with long-standing renal transplant developed acute transplant renal artery thrombosis because of late hemolytic uremic syndrome (HUS)^[10] and had increased levels of antiphospholipid antibodies.^[11] A study on a patient with HUS revealed classic findings of renal failure, hemolytic anemia, schistocytes, and thrombocytopenia. Cyclosporin^[12] or tacrolimus-associated HUS^[13] following renal transplantation has been reported. Increased incidence of acute thrombosis of the transplanted renal artery is also associated with increased use of cyclosporin. The underlying mechanism for this may be the effect of this drug on endothelial cells, thus minimizing prostacyclin production and predisposing a patient to thrombosis. Our patient did not have thrombocytopenia, and Hct levels were maintained at approximately 27.2% to 31% before acute thrombosis of the transplanted renal artery. In addition, our patient did not receive cyclosporin treatment, and the tacrolimus dosage was adjusted according to the serum tacrolimus level. HUS seemed unlikely; therefore, we did not perform blood smear to confirm schistocytes.

Antiphospholipid syndrome (APS), which is diagnosed on the basis of the presence of antiphospholipid antibodies, is an acquired disorder associated with vascular thrombosis.^[14] The

most commonly known antiphospholipid antibodies are the lupus anticoagulant and anticardiolipin antibody. Our patient was negative for lupus anticoagulant and IgM anticardiolipin antibody. Moreover, our patient had no history of an autoimmune disorder.

Except for HUS and APS, 4 studies have reported acute thrombosis in patients with long-standing renal transplant. In 2 of these reported cases, the event was associated with significant medical problems such as myocardial infarction and sepsis.^[15,16] In the third case of acute transplant renal artery thrombosis, the patient had severe hypertension.^[17] In the fourth case, the patient developed acute transplant renal artery thrombosis following hip surgery.^[8] We did not encounter the aforementioned situations in our patient.

However, risk factors for arterial thrombosis are not limited to antiphospholipid antibodies and lupus anticoagulants. Other hypercoagulable states include factor V Leiden mutation,^[18] antithrombin deficiency,^[19] and methylene tetrahydrofolate reductase mutation and hyperhomocysteinemia.^[20] Furthermore, infectious and inflammatory states such as polyarteritis nodosa,^[21] Takayasu arteritis,^[22] and Behcet disease^[23] are associated with renal artery thrombosis. These diseases might still possibly endanger acute thrombosis of a transplanted renal artery; hence, careful evaluation and screening of the aforementioned diseases should be required. Our patient did not present any cutaneous or musculoskeletal joint symptoms, and infectious and inflammatory states seemed unlikely. However, we did not perform an activated protein C resistance test or measure for antithrombin and total homocysteine levels in our patient.

One of the pathogenic mechanisms in our patient may be anemia, engendered by bleeding, that enhanced thrombosis because studies have reported a relationship between bleeding and cerebral infarction onset.^[24,25] Hypercatecholaminemia caused by the systemic absorption of submucosal epinephrine injected for gastric ulcer bleeding and acute stress may be another pathogenic mechanism in our patient that may have resulted in thrombosis through vasoconstriction and platelet aggregation.^[26] The patient had a history of hypertension, diabetes mellitus, and kidney disease, which indicated a high risk of a cardiovascular event. However, he was not taking acetylsalicylic acid. This event could be attributed to thrombosis formation of atherosclerotic lesions and plaque rupture.

Table 1

Review of previous and present cases with late transplant renal artery thrombosis.

Reference	Medical problems	Timing of diagnosis	Treatment	Outcomes
Kiykim et al ^[10]	Hemolytic uremic syndrome	1 day after severe local graft pain, anuria, and weakness	PTRA with thrombolysis	Urine output started at once after treatment and renal function returned to baseline after 2 weeks
Karassa et al ^[11]	Antiphospholipid syndrome	The same day after acute local graft pain, high fever, and anuria	PTRA with thrombolysis	Graftectomy; return to HD
Swanson and Sullivan ^[15]	Myocardial infarction	The same day after slight graft pain and anuria	TE and fibrinolytic instillation	Urine output gradually improved after treatment but patient died 1 week postoperatively
Lee et al ^[16]	Pneumonia and sepsis; preexisting stenosis	Over 24 hours after anuria	Renal arteriogram	Anuria; return to HD
Nerstrom et al ^[17]	Severe hypertension	Not available	Not available	Patient died from complications in connection with graftectomy
Groggel ^[8]	Severe hypertension after hip surgery	The next day after surgery	BP control with intravenous nitroprusside and renal angiogram	Graftectomy; return to HD
Our case	Gastric ulcer bleeding	2 days after acute lower abdominal pain and anuria	PTRA with thrombolysis and stent insertion	Anuria; return to HD

BP = blood pressure, HD = hemodialysis, PTRA = percutaneous transluminal renal angioplasty, TE = thromboendarterectomy.

The timing of diagnosis as well as the method of treatment are critical for renal infarction; therefore, previously reported cases of transplanted renal artery thrombosis, medical problems, timing of diagnosis, methods of treatment, and outcomes are reviewed, and are tabulated in Table 1. Graft thrombosis treatment is generally unsatisfactory, and only few cases were effectively rescued by surgical revascularization or intraarterial thrombolytic therapy.^[27]

In summary, we report the first case of a patient with a long-term well-functioning renal allograft who suffered from acute thrombosis of the renal transplant artery after gastric ulcer bleeding.

Acknowledgment

We thank our patient for contributing clinical data to this report.

References

- [1] Bakir N, Sluiter WJ, Ploeg RJ, et al. Primary renal graft thrombosis. *Nephrol Dial Transplant* 1996;11:140–7.
- [2] Penny MJ, Nankivell BJ, Disney AP, et al. Renal graft thrombosis. A survey of 134 consecutive cases. *Transplantation* 1994;58:565–9.
- [3] Kobayashi K, Censullo ML, Rossman LL, et al. Interventional radiologic management of renal transplant dysfunction: indications, limitations, and technical considerations. *Radiographics* 2007;27:1109–30.
- [4] Akbar SA, Jafri SZ, Amendola MA, et al. Complications of renal transplantation. *Radiographics* 2005;25:1335–56.
- [5] Palleschi J, Novick AC, Braun WE, et al. Vascular complications of renal transplantation. *Urology* 1980;16:61–7.
- [6] Abramowicz D, Pradier O, Marchant A, et al. Induction of thromboses within renal grafts by high-dose prophylactic OKT3. *Lancet* 1992;339:777–8.
- [7] Morrissey PE, Ramirez PJ, Gohh RY, et al. Management of thrombophilia in renal transplant patients. *Am J Transplant* 2002;2: 872–6.
- [8] Groggel GC. Acute thrombosis of the renal transplant artery: a case report and review of the literature. *Clin Nephrol* 1991;36:42–5.
- [9] Buturovic-Ponikvar J. Renal transplant artery stenosis. *Nephrol Dial Transplant* 2003;18(suppl 5):v74–7.
- [10] Kiykim AA, Ozer C, Yildiz A, et al. Development of transplant renal artery thrombosis and signs of haemolytic-uraemic syndrome following the change from cyclosporin to tacrolimus in a renal transplant patient. *Nephrol Dial Transplant* 2004;19:2653–6.
- [11] Karassa FB, Avdikou K, Pappas P, et al. Late renal transplant arterial thrombosis in a patient with systemic lupus erythematosus and antiphospholipid syndrome. *Nephrol Dial Transplant* 1999;14:472–4.
- [12] Bren AF, Kandus A, Buturovic J, et al. Cyclosporine-related hemolytic-uremic syndrome in kidney graft recipients: clinical and histomorphologic evaluation. *Transplant Proc* 1998;30:1201–3.
- [13] Neto P, Lopes K, Macario F, et al. De novo tacrolimus-associated hemolytic uremic syndrome after renal transplantation—case report. *Nefrologia* 2013;33:152–4.
- [14] Giannakopoulos B, Krilis SA. The pathogenesis of the antiphospholipid syndrome. *N Engl J Med* 2013;368:1033–44.
- [15] Swanson DA, Sullivan MJ. Thromboendarterectomy for anuria 4 1/2 years post-renal transplant: a case report. *J Urol* 1976;116:799–801.
- [16] Lee HM, Mendez-Picon G, Pierce JC, et al. Renal artery occlusion in transplant recipients. *Am Surg* 1977;43:186–92.
- [17] Nerstrom B, Ladefoged J, Lund F. Vascular complications in 155 consecutive kidney transplantations. *Scand J Urol Nephrol* 1972;6(suppl 15):65–74.
- [18] Klein O, Bernheim J, Strahilevitz J, et al. Renal colic in a patient with anti-phospholipid antibodies and factor V Leiden mutation. *Nephrol Dial Transplant* 1999;14:2502–4.
- [19] Miura K, Takahashi T, Takahashi I, et al. Renovascular hypertension due to antithrombin deficiency in childhood. *Pediatr Nephrol* 2004;19: 1294–6.
- [20] Queffeuilou G, Michel C, Vrtovnik F, et al. Hyperhomocysteinemia, low folate status, homozygous C677T mutation of the methylene tetrahydrofolate reductase and renal arterial thrombosis. *Clin Nephrol* 2002;57: 158–62.
- [21] Templeton PA, Pais SO. Renal artery occlusion in PAN. *Radiology* 1985;156:308.
- [22] Teoh MK. Takayasu's arteritis with renovascular hypertension: results of surgical treatment. *Cardiovasc Surg* 1999;7:626–32.
- [23] Akpolat T, Akkoyunlu M, Akpolat I, et al. Renal Behcet's disease: a cumulative analysis. *Semin Arthritis Rheum* 2002;31:317–37.
- [24] Kim JS, Kang SY. Bleeding and subsequent anemia: a precipitant for cerebral infarction. *Eur Neurol* 2000;43:201–8.
- [25] Takaoka M, Matsusaka M, Ishikawa K, et al. Multiple border-zone infarcts after hemorrhagic shock in trauma victims: three case reports. *J Trauma* 2004;56:1152–5.
- [26] Birk AV, Leno E, Robertson HD, et al. Interaction between ATP and catecholamines in stimulation of platelet aggregation. *Am J Physiol Heart Circ Physiol* 2003;284:H619–25.
- [27] Ponticelli C, Moia M, Montagnino G. Renal allograft thrombosis. *Nephrol Dial Transplant* 2009;24:1388–93.