

Use of a Juvenile Rabbit Animal Model to Evaluate Therapeutic Interventions for Postoperative Inflammation and Fibrin Formation After Lensectomy

Joseph D. Bogaard^{1,2,*}, Jonathon B. Young^{3,*}, Asad Movahedan¹, and Iris S. Kassem¹⁻³

¹ Department of Ophthalmology, University of Illinois-Chicago, Chicago, IL, USA

² Department of Ophthalmology & Visual Sciences, Medical College of Wisconsin, Milwaukee, WI, USA

³ Department of Cell Biology, Neurobiology, & Anatomy, Medical College of Wisconsin, Milwaukee, WI, USA

Correspondence: Iris S. Kassem, Medical College of Wisconsin, The Eye Institute, 925 N 87th St, Milwaukee, WI 53226, USA. e-mail: ikassem@mcw.edu

Received: 8 September 2018

Accepted: 12 November 2018

Published: 9 January 2019

Keywords: fibrin; lensectomy; enoxaparin; triamcinolone

Citation: Bogaard JD, Young JB, Movahedan A, Kassem IS. Use of a juvenile rabbit animal model to evaluate therapeutic interventions for postoperative inflammation and fibrin formation after lensectomy. *Trans Vis Sci Tech.* 2019;8(1):5. <https://doi.org/10.1167/tvst.8.1.5>
Copyright 2019 The Authors

Purpose: We used the juvenile rabbit as a model for investigating therapeutic interventions for postoperative inflammation and fibrin formation following intraocular lens (IOL) insertion for management of pediatric cataracts.

Methods: Twelve 6- to 7-week-old, 600 to 900 g rabbits underwent bilateral clear-cornea lensectomy via irrigation and aspiration with IOL insertion. Following wound closure, enoxaparin 8 mg ($n = 6$ eyes), preservative-free triamcinolone 0.5 mg ($n = 6$), 8 mg enoxaparin plus 0.5 mg triamcinolone ($n = 6$), or balanced salt solution ($n = 6$) was injected into the anterior chamber. Slit-lamp examinations and optical coherence tomography (OCT) scans were performed postoperatively on days 3 through 7, and 14 to characterize levels of inflammation and fibrin. Using 17 additional rabbits, enzyme-linked immunosorbent assays (ELISAs) with 100 μ L of aqueous humor were performed to quantify the amount of fibrinogen and fibrin preoperatively and on postoperative day 3. Immunohistochemistry was performed to confirm the presence of fibrin.

Results: Enoxaparin alone and combined with triamcinolone reduced the amount of fibrin present in the anterior chamber compared to untreated eyes, which corresponded to an increase in OCT signal strength. Despite the clear visual axis shown in clinical images, the combination treatment group had the highest levels of soluble fibrin when assessed by ELISA. Immunohistochemistry confirmed the presence of insoluble fibrin seen clinically.

Conclusions: A combination of enoxaparin and triamcinolone appears to provide the most therapeutic benefit by reducing fibrin formation and postoperative inflammation.

Translational Relevance: The juvenile rabbit is an excellent model to investigate inflammation and fibrin formation following lensectomy with IOL insertion and possibly any intraocular surgery in children.

Introduction

Congenital and infantile cataract is an opacification of the crystalline lens of the eye, estimated to cause 5% to 20% of blindness in children worldwide. Early diagnosis and surgical removal of these cataracts are critical to improving the visual prognosis of the child and preventing amblyopia, which can lead to irreversible vision loss. Unlike adults, pediatric cataract surgery has a far greater risk for complica-

tions due to the enhanced inflammatory response in children.¹

One treatment option for congenital cataract is to remove the cataract and treat the refractive error with glasses or contact lenses. These remain costly and are a considerable burden to caregivers. For a unilateral cataract, the difference in prescription of the eyes can be cosmetically relevant and uncomfortable because of the difference in lens weight. The contact lens must appropriately match the refractive error of the child, leading to multiple appointments and adjustments. In

addition, approximately 18% of patients with aphakia experience a contact lens-related adverse event, including corneal abrasion, ulcer, or keratitis.² Anytime the child is without the appropriate refractive correction, he or she is at risk for amblyopia. Another option is to insert an intraocular lens (IOL), offering continuous refractive correction, but due to the exaggerated immune response, postoperative scarring still can occlude the visual axis, thereby still limiting the child's vision.³

These treatment plans were compared previously in a randomized clinical trial, the Infant Aphakia Treatment Study (IATS).⁴ This study reported that subjects treated with an IOL needed more surgeries in the first postoperative year secondary to complications, many of which were related to scarring and membrane formation.⁵ Although this may encourage physicians to perform lensectomy without IOL implantation, the significant burdens and challenges of contact lenses still result in complicated outcomes for these children. Given these current limitations, our goal is to develop treatments to reduce the postoperative adverse events and additional surgeries associated with use of an IOL for pediatric cataracts, potentially improving visual outcomes and significantly reducing the burden of the caretaker. The IATS reported that pupillary membranes and corectopia accounted for 17 and 11 of the 62 postoperative complications, respectively.⁵ These complications are believed to result from scarring and fibrin membrane formation.

To further investigate these complications, we used a juvenile rabbit animal model of lensectomy with IOL insertion. This model has been used to study many new surgical techniques and tools, including phacoemulsification systems, IOL insertion systems, irrigating solutions, and other novel technologies.⁶ Compared to humans, rabbits have similarities in anterior chamber size and lens diameters that allow them to be an excellent animal model for evaluating the biocompatibility of IOLs in preclinical trials.^{7,8} Similar to human infants, younger rabbits have a more robust response to lensectomy than adults, making juvenile rabbits ideal models for studying the effect of IOL implantation for congenital cataracts. Using this model, we investigated the use of pharmacologic agents triamcinolone and enoxaparin, a low molecular weight heparin, for management of postoperative inflammation and scarring following lensectomy with IOL implantation.

Triamcinolone is a corticosteroid that is five times more potent than the natural compound cortisol,

making it an extremely potent anti-inflammatory agent,⁹ and it is approved by the United States Food and Drug Administration for the management of chronic ocular inflammatory conditions, such as uveitis.¹⁰ Additionally, triamcinolone has been reported previously to prevent postoperative complications after pediatric lensectomy,¹¹ making it an appropriate choice to investigate in this rabbit animal model.

Heparin is an anticoagulant that forms a complex with antithrombin III (AT III). The heparin-AT III complex prevents conversion of prothrombin to thrombin and, hence, decreases the formation of fibrin clots. The heparin-AT III complex also exhibits anti-inflammatory properties.¹² Enoxaparin is a low molecular weight heparin with a longer half-life in the blood than heparin. It functions as an anticoagulant that is administered via subcutaneous injection. Given these therapeutic properties, we investigated the effect of intraocular injection of triamcinolone, enoxaparin, and a combination of these agents into the anterior chamber of the eye of a juvenile rabbit model.

Methods

Animal Preparation & Lensectomy

All experiments were approved and in compliance with the Institutional Animal Care and Use Committee at the University of Illinois at Chicago (UIC) and the Medical College of Wisconsin (MCW). A total of 36 New Zealand White Rabbits between 6 and 7 weeks old from Harlan (Indianapolis, IN) or Covance (Denver, PA), weighing between 600 and 900 g were used in this study. Seven of these rabbits were used for testing surgically naïve eyes. A total of 29 rabbits were anesthetized for bilateral clear-cornea lensectomy surgery with IOL insertion with intravenous ketamine and xylazine 50 to 60/5 mg/kg. The surgical technique, as described below, was standardized for every procedure, and the same surgeon performed all procedures for each experiment. The eye was prepped with 5% betadine solution (Alcon, Fort Worth, TX) into the eye and the surrounding area was prepped with 10% betadine and draped. A clear corneal incision was made just anterior to the limbus using a 20-gauge MVR blade. The anterior chamber was reformed with viscoelastic (Keralon V++; Keragenix, Rapid City, SD). A cystitome needle was used to puncture the anterior capsule followed by micro-Utrata forceps to make a continuous curvilinear capsulorrhexis. The lens then was removed by

irrigation and aspiration with balanced salt solution (BSS; Sterile Irrigating Solution; Alcon Laboratories, Inc., Fort Worth, TX) via a Simcoe double lumen irrigation/aspiration cannula. No additional medications were added to the solution. The anterior chamber and capsular bag then were filled with viscoelastic and the wound was expanded with a 2.4 mm keratome blade. A 10-0 nylon mattress suture was preplaced into the corneal wound. A +30 diopter acrylic foldable IOL (Alcon, Fort Worth, TX), was inserted into the capsular bag. The viscoelastic then was removed with Simcoe irrigation and aspiration. The preplaced suture was tied to close the wound and the knot was buried. Once the wound was deemed watertight, either enoxaparin 8 mg (seven rabbits), preservative-free triamcinolone 0.5 mg (six rabbits), 8 mg enoxaparin plus 0.5 mg triamcinolone (combination therapy; seven rabbits), or BSS (untreated, 9 rabbits) was injected into the anterior chamber. The rabbit then was awakened from anesthesia. The rabbits received topical erythromycin twice daily for 4 days and analgesia with subcutaneous buprenorphine (0.01–0.05 mg/kg) perioperatively twice a day for 3 days as needed. Rabbits then were separated into two sets of postoperative testing, either clinical examinations (12 rabbits) or aqueous humor sampling with pathology (17 rabbits) as described below. These two groups allowed for clinical testing without sampling of the aqueous humor disrupting testing of the postoperative clinical course. An additional seven rabbits did not have any surgery and were examined clinically as described below.

Clinical Examinations

Postoperatively, 19 rabbits were examined under sedation with ketamine and dexmedetomidine 1 to 5/0.5 mg/kg subcutaneously on days 3 through 7 and 14. Twelve rabbits underwent bilateral lensectomy as described above and seven had unoperated eyes examined for baseline testing. Although docile, rabbits were sedated to prevent stress and discomfort during these exams. The examinations consisted of spectral domain optical coherence tomography (OCT) inferior to the optic nerve (Spectralis; Heidelberg Engineering, Heidelberg, Germany), intraocular pressure (IOP), and slit-lamp biomicroscopy examinations with photography. The IOP in each eye was measured using an Icare rebound tonometer (icare USA, Raleigh, NC). Slit-lamp biomicroscopy was used to evaluate each eye in the following categories: iris synechiae, pupil dilation in millimeters, hemorrhage in the anterior chamber, amount of fibrin in the

anterior chamber, cell grade, flare grade, and amount of posterior capsule opacity that was present. Cell and flare grades were measured using the SUN classification system criteria.¹³ The size of the fibrin clot in the anterior chamber was measured as a percentage of the 6 mm optic that was covered.

OCT was used as an objective measure to quantify the clarity of the visual axis following surgery.¹⁴ We approximated visual axis clarity based on signal strength determined by the Spectralis OCT. At each postoperative day, operated eyes underwent OCT (19 b-scan volume), and the average signal strength was calculated from the 19 scans. These average signal strengths then were grouped and compared between control and treatment groups.

Surgical complications, such as posterior capsule tears or dislocated IOLs, could increase postoperative inflammation and fibrin or decrease the OCT signal strength. While there were complications in each treatment group, coincidentally, we experienced no surgical complications in the untreated group. Following clinical examination on postoperative day 14, rabbits then were euthanized with intravenous Fatal Plus (Vortec Pharmaceuticals, Dearborn, MI) until there was an absence of respiration, cardiac function, corneal reflex, muscle tone, and mucus membrane color to confirm death.

Enzyme-Linked Immunosorbent Assay (ELISA)

A total of 17 rabbits undergoing bilateral clear cornea lensectomy with IOL implantation were used for ELISA assays of the aqueous humor. ELISA assays were used to quantify the amount of fibrinogen and fibrin analytes present in aqueous humor preoperatively (Pre) and on postoperative day 3 (POD 3). POD 3 was chosen because it was determined to be the peak of the postoperative response from preliminary studies.¹⁵ On POD 3, a brief clinical exam with a slit-lamp was performed to ensure the findings were consistent with clinical exam data. Following sterile preparation, approximately 100 to 200 μ L of aqueous humor was aspirated from the anterior chamber via paracentesis using a sterile 30-gauge needle on a 1 cc syringe. Aqueous fibrinogen and fibrin levels were quantified using a double-antibody solid-phase sandwich ELISA for rabbit fibrinogen or fibrin (TSZ ELISA; Biotang, Waltham, MA). Briefly, 96-well flat bottom polystyrene plates were coated with an antifibrinogen or antifibrin antibody; 100 μ L of aqueous humor sample then

was loaded onto the plate to bind with the coated antibody. Following the addition of a biotinylated-fibrinogen or fibrin antibody, the HRP-Streptavidin enzyme conjugate was added into the wells. After washing, tetramethylbenzidine substrate was added. Following incubation, the reaction was terminated using an acidic stop solution and the absorbance value was read by a microplate reader. Because the volume of aqueous humor collected was not sufficient to allow for testing of fibrinogen and fibrin levels, all conditions did not have equal sample sizes. The number of aqueous humor samples included in the ELISA fibrinogen analysis preoperatively (Pre) were $n = 8$ eyes, and at POD 3 they were $n = 6$, $n = 7$, $n = 5$, and $n = 8$ for untreated, and enoxaparin-, triamcinolone, and combination therapy-treated eyes, respectively. The number of aqueous humor samples included in the fibrin analysis were as follows: Pre: $n = 10$ eyes, and POD 3 $n = 5$, $n = 7$, $n = 5$, and $n = 8$ for enoxaparin-, triamcinolone-, and combination therapy-treated eyes, respectively.

Following aqueous humor sample collection on POD 3, rabbits then were euthanized with intravenous Fatal Plus (Vortec Pharmaceuticals, Dearborn, MI) until death was confirmed by absence of respiration, cardiac function, corneal reflex, muscle tone, and mucus membrane color.

Pathology and Immunohistochemistry

The eyes of rabbits euthanized on POD 3 then were removed and fixed in 10% neutral buffered formalin for 7 days. After fixation, tissues were dehydrated through graded ethanol, cleared with xylene, paraffin infiltrated, and embedded into tissue blocks. Tissue blocks were cut coronally between the pars plana and equator of the eye to isolate the anterior segment at a thickness of 4 μm and mounted on poly-L-lysine-coated slides. Sections were stained immunohistochemically for detection of fibrin using a 1:1000 dilution of mouse monoclonal antifibrin antibody 59D8¹⁶ purified from ascites (gift from Dr. Sood, Pathology & Laboratory Medicine, Medical College of Wisconsin; Hybridoma Core, Blood Center of Wisconsin, Milwaukee, WI). With standard labeled streptavidin-biotin (LSAB) detection, the tissue sections were deparaffinized, rehydrated, and antigen retrieved with citrate buffer. After application of peroxidase, avidin/biotin, and endogenous protein blocks, the primary antibody was incubated for 60 minutes at ambient temperature. A biotinylated anti-mouse secondary antibody (715-066-151; Jackson ImmunoResearch, West Grove, PA) was applied

before streptavidin-horseradish peroxidase (HRP) and visualized with detection of antibody binding (DAB). High-resolution images were obtained with a Hamamatsu Nanozoomer 2.0-HT high-resolution digital slide scanner (Hamamatsu Corporation, Bridgewater, NJ).

Statistics

Continuous data were compared using a generalized linear mixed model with interactions (R version 3.1.2, R Foundation for Statistical Computing, Vienna, Austria). Categorical data, including assessments of cell, flare, and anterior chamber fibrin, were compared using Fisher's exact tests. $P = 0.05$ was set to determine statistical significance, and a Bonferroni correction was applied for three comparisons. ELISA data were analyzed using GraphPad Prism (GraphPad, La Jolla, CA) with one-way analysis of variance (ANOVA) followed by Tukey's test.

Results

OCT and Slit-Lamp Imaging

In the juvenile rabbit, after lensectomy with IOL implantation, untreated eyes had a large amount of opacification in the anterior chamber that decreased over time (Fig. 1, 2). Treated eyes with injections of enoxaparin or a combination of enoxaparin and triamcinolone increased clarity of the visual axis (Fig. 1). This corresponded to a significant increase in OCT signal strength (Fig. 2, $P < 0.005$). The average OCT signal strength in surgically naïve eyes was 30.15 ± 1.02 ($n = 6$). Examining the average amount of fibrin in the anterior chamber over time in all eyes in each group over time, enoxaparin and the combination of enoxaparin and triamcinolone significantly reduced the amount of fibrin observed in the anterior chamber compared to untreated eyes (Fig. 2, $P < 0.005$). Triamcinolone 0.5 mg did not significantly decrease anterior chamber fibrin ($P = 0.3853$).

Anterior chamber fibrin results correlated with the posterior synechiae, where the iris is adherent to either the anterior capsule or the lens itself. Posterior synechiae were present in the untreated and triamcinolone groups that were not present in the eyes treated with enoxaparin or combination therapy (Fig. 1). Consistent with less synechiae, eyes treated with enoxaparin or combination therapy dilated more, with the entire optic and parts of the haptic being visible compared to either the untreated or triamcinolone-treated eyes (Fig. 1). Mean \pm standard

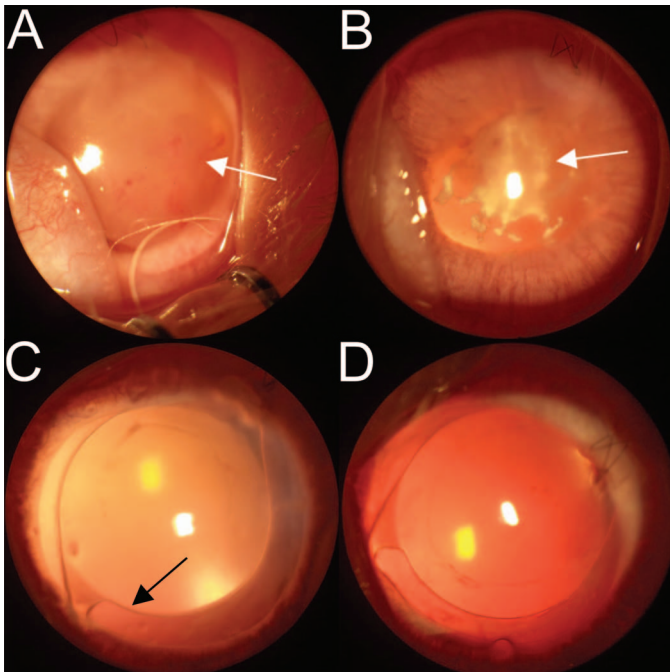


Figure 1. Clinical examinations following lensectomy with IOL insertion in a juvenile rabbit model. Representative color pictures of rabbit eyes demonstrating quality of visual axis following lensectomy with IOL insertion and injection after wound closure of (A) BSS (untreated eye). (B) 0.5 mg triamcinolone. (C) 8 mg enoxaparin. (D) 8 mg enoxaparin and 0.5 mg triamcinolone. *White arrows* indicate the fibrin formed in the anterior chamber, and the *black arrow* points to the edge of the optic of the IOL.

deviation (SD) pupil dilation size on POD 3 was 5.95 ± 0.373 mm for untreated eyes and 7.65 ± 0.273 mm for eyes treated with combination therapy ($P = 0.00426$).

Next, we examined the anterior chamber for the two measures of anterior chamber inflammation, cell and flare, in addition to IOP (Fig. 3). Combination therapy significantly reduced the amount of flare on POD 3. Eyes treated with combination therapy had a higher IOP compared to untreated eyes, which was closer to eyes that did not have any surgical intervention.

Enzyme-Linked Immunosorbent Assay (ELISA)

ELISAs revealed significant differences in fibrinogen levels when comparing untreated eyes with Pre samples and eyes treated with combination therapy (Fig. 4A). Interestingly, despite a clinical appearance of a large membranous component we suspected to be fibrin, the amount of fibrin detected by ELISA was not statistically different between eyes preoperatively

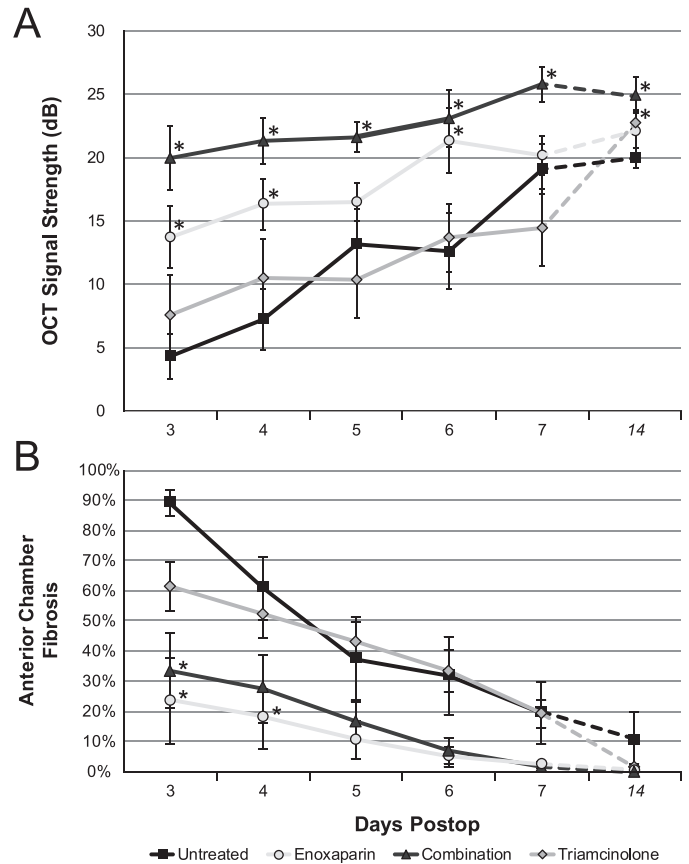


Figure 2. OCT signal strength following lensectomy with IOL. (A) OCT signal strength (mean \pm standard error of mean [SEM]) assessed at PODs 3 to 7 and 14. Eyes treated with enoxaparin or combination therapy had significantly greater signal quality compared to untreated eyes, or eyes treated with triamcinolone ($P < 0.005$). (B) Percentage of anterior chamber fibrin (mean \pm SEM) postoperatively. Enoxaparin and combination therapy had significantly reduced anterior chamber fibrin at PODs 3 and 4 compared to triamcinolone and untreated eyes ($P < 0.005$, Fisher's exact test). *Indicate statistical significance.

and untreated eyes on POD 3. In fact, the only significant differences observed in fibrin levels were identified between eyes treated with combination therapy compared to enoxaparin-treated eyes and eyes before surgical intervention (Pre) (Fig. 4B). No apparent complications or iris trauma occurred during these sample collections. Despite the clear visual axis shown in clinical images (Fig. 1D), the combination treatment group had the highest levels of fibrin.

Immunohistochemistry Staining

Antibody testing using a fibrin-specific antibody was not observed in an unoperated eye (Fig. 5A). Sections of fibrin could be observed in the untreated

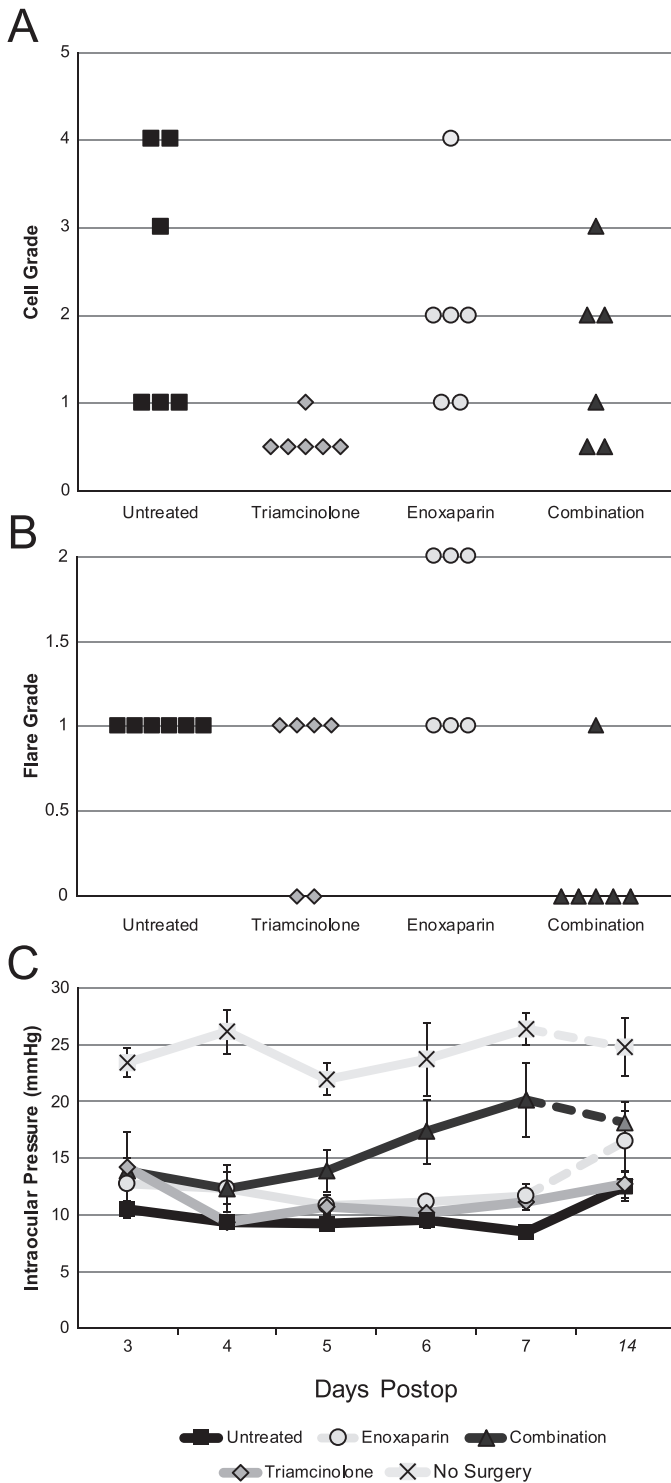


Figure 3. Cell grade, flare grade, and IOP measurements for each eye following lensectomy with IOL. Each *symbol* represents one eye per surgical group. (A) Cell grade measurements. (B) Flare grade measurements at POD 3 following lensectomy with IOL. Enoxaparin showed no beneficial effect on cell or flare compared to controls (Fisher's Exact test, $P > 0.1$). 0.5 mg triamcinolone showed a trend towards reducing the number of cells in the

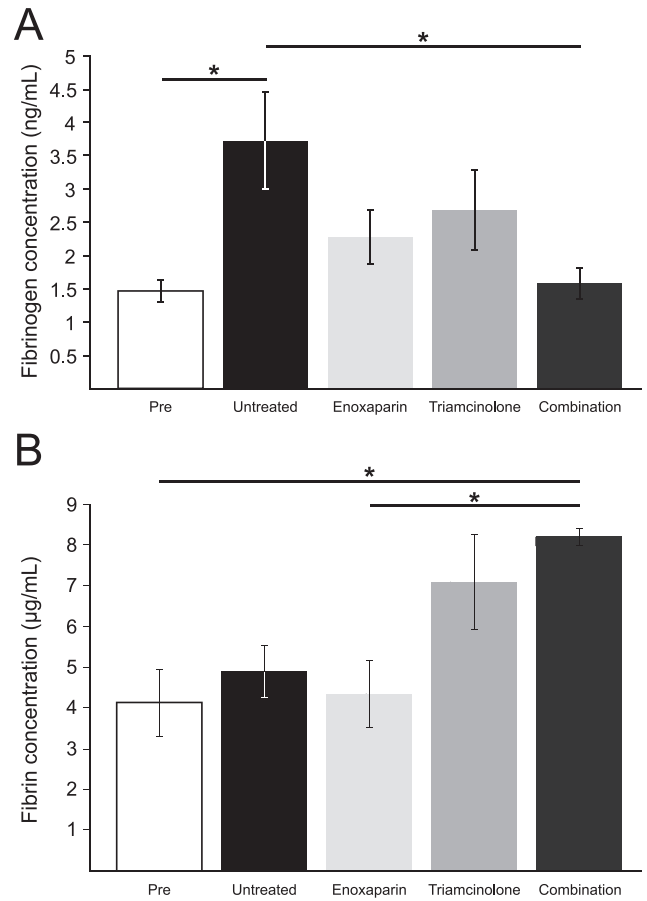


Figure 4. Fibrinogen and fibrin ELISA data. Mean \pm SEM shown for all measurements. $*P < 0.01$. (A) Fibrinogen concentration (ng/mL) in aqueous samples assessed preoperatively (Pre) and on POD 3 with the corresponding treatment. An ANOVA test on these concentrations revealed a statistically significant difference among the samples ($F_{[4,29]} = 4.66$, $P < 0.05$). A post hoc Tukey test ($\alpha = 0.05$) revealed statistical differences between the Pre versus untreated ($P < 0.01$) and the untreated versus combination therapy ($P < 0.01$) groups. (B) Fibrin concentration ($\mu\text{g/mL}$) in aqueous samples assessed Pre and then at POD 3 with the corresponding treatment. An ANOVA test on these concentrations revealed a statistically significant difference among the samples ($F_{[4,30]} = 5.88$, $P < 0.05$). A post hoc Tukey test ($\alpha = 0.05$), revealed statistical differences between the Pre versus combination therapy ($P < 0.01$) and the Enoxaparin versus combination therapy ($P < 0.01$) groups.

anterior chamber ($P = 0.0601$). The combination of triamcinolone and enoxaparin significantly decreased the number of eyes with flare (POD 3, $P = 0.01515$). (C) IOP (mean \pm SEM) in surgical eyes was reduced compared to eyes that did not undergo surgical intervention. Significantly increased IOP following injection of a steroid did not occur in our procedures.

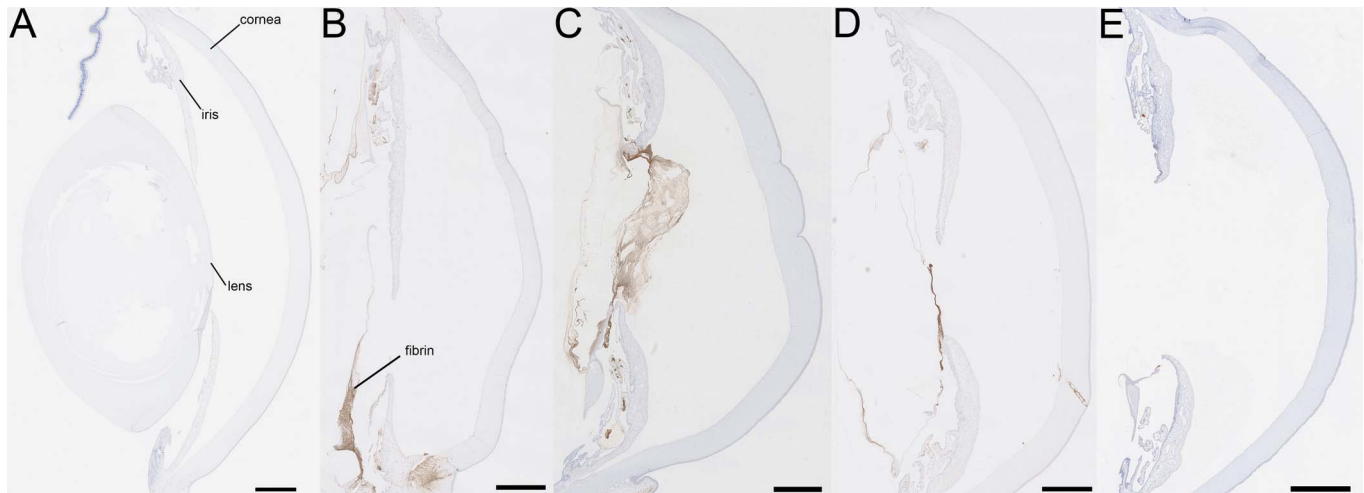


Figure 5. Histologic evaluation using mouse monoclonal anti-fibrin antibody 59D8 of fibrous membrane. Fibrin was not observed in (A) an unoperated eye. The presence of fibrin was greatest in the (B) untreated eye and (C) triamcinolone treatment groups. Significantly less fibrin was detected in (D) the enoxaparin group, with no fibrin present in (E) the combination treatment group, corresponding with the slit-lamp images (Fig. 1). Scale bar: 1 mm.

(Fig. 5B) and triamcinolone-treated eyes (Fig. 5C) and appeared reduced in enoxaparin-treated (Fig. 5D), and combination-treated (Fig. 5E) eyes.

Discussion

The surgical and postoperative management of pediatric cataracts remain a challenge in ophthalmology. Treatment decisions made by pediatric ophthalmologists have lifelong implications regarding the visual potential of the child. By reducing the incidence of adverse events with implantation with an IOL, it is possible that children may have improved visual acuities and a lower influence of socioeconomic disparities on the visual outcomes of children who need cataract surgery. To investigate potential pharmacotherapies that could be used to address this problem, we performed a similar operation in a rabbit animal model. In this model, the inflammatory response and fibrin formation is more severe than that typically observed in a child. By addressing exaggerated cases of inflammation and fibrin formation with our rabbit model, our study showed the pharmacotherapies we evaluated may yield promising outcomes in children as well.

Our results showed a significant reduction in the formation of postoperative fibrin with enoxaparin alone and combined with a low dose of triamcinolone (Fig. 1). At the low dose, triamcinolone alone did not significantly improve fibrin in the anterior chamber (Figs. 1C, 5C), grading scores of cell or flare, or OCT

signal strength (Figs. 2, 3). Although all groups did show some improvement in OCT signal strength, they did not reach the signal strength of surgically naïve eyes at day 14, although enoxaparin and combination therapy were closest to naïve eyes. These data correlated with other studies where a lower dose of only 1.2 mg triamcinolone had no effect on postoperative outcomes in patients undergoing congenital cataract surgery.¹ The triamcinolone dose of 0.5 mg is relatively low, with other studies using up to 4 mg with observed postoperative benefits.^{17,18} We intentionally chose a lower dose of the corticosteroid, triamcinolone, to determine if there was a synergistic effect when used combined with the low molecular weight heparin, enoxaparin, because of their different mechanisms of action. There also is the potential added benefit of decreasing the risk of steroid response glaucoma with a lower dose of triamcinolone. Given the benefits that we observed in using a combined dose, we would suspect a higher dose of triamcinolone may provide even better clinical outcomes. Enoxaparin alone also did not demonstrate the same anti-inflammatory properties when compared to combination therapy, as the cell and flare grades after treatment with enoxaparin remained high in several eyes (Figs. 3B, 3C). Combining enoxaparin and triamcinolone appears to provide a synergistic therapeutic benefit by decreasing fibrin (Figs. 1D, 5D) and inflammation.

The use of enoxaparin has been reported previously for cataract surgical management, with mixed results observed in postoperative inflammation.^{19–22}

We chose enoxaparin over heparin in this study due to the longer half-life of enoxaparin to increase the duration of action. Prior studies investigated enoxaparin or heparin in the irrigating solution used during human congenital cataract surgery. However, the solution was present at a relatively dilute dose during surgery in the irrigating solution. The dose of enoxaparin in this study is 500-fold more concentrated than that used in the irrigation fluid for the randomized study of children (0.08 mg/mL in previous studies versus 40 mg/mL in this study).

Previous studies have investigated coating IOLs in heparin to decrease intraocular inflammation in children²³ and adults,^{24,25} but the studies have yielded inconsistent outcomes. Furthermore, all of these trials previously performed in humans were done with consistent treatment of topical steroids. Our study involved a single therapeutic dose with no additional treatment of topical steroids, easing the requirements of postoperative management.

We used ELISA assays to compare the clinical efficacy of the therapies tested with the concentrations of aqueous fibrinogen and fibrin. The concentration of fibrinogen was higher in the untreated group at POD 3 compared to treated groups and preoperatively. Treatment with a combination of enoxaparin and triamcinolone significantly reduced the amount of fibrinogen present in the aqueous compared to untreated rabbits. Surprisingly, the combination therapy, which resulted in the highest fibrin concentration in the anterior chamber (Fig. 4B), did not correlate with the slit-lamp images of the anterior chamber fibrin clot (Fig. 1D). We also anticipated the levels of fibrin to be higher in the untreated rabbits compared to eyes preoperatively, yet this difference was not statistically significant. It is possible that this difference is due to fibrin becoming insoluble in the eyes to become fibrin clots; therefore, reducing the soluble fibrin detected in the aqueous with ELISA. Histology staining (Fig. 5) confirmed that the anterior chamber clot was composed of fibrin. It is possible that the combination therapy makes this fibrin more soluble, so it is present in the aqueous via paracentesis on POD 3. It is possible that paracentesis of the aqueous humor of untreated eyes, which could not withdraw portions of the insoluble clot, would miss the fibrin mass; thus resulting in a low fibrin concentration reading despite visually significant fibrin appearing on clinical examination.

Although informative, our study had several limitations. Given the inclusion of rabbits with complications in the treated groups, it is possible that

the effect would be even more apparent in the absence of surgical complications. An additional limitation is the rather limited number of eyes ($n = 6$) used in clinical evaluations. Lastly, we did not evaluate the postoperative course beyond 2 weeks, so the effect of therapies on posterior capsule opacity formation cannot be determined from this study. Larger and long-term studies are needed to help confirm these observations.

The injection of both drugs used in this study carries inherent risks. Enoxaparin, a potent anticoagulant, increases bleeding risk. Bleeding was not observed at an increased frequency in any treatment group. It is possible that by injecting the enoxaparin after the wound was closed and the anterior chamber was stable, the risk of bleeding was minimized. Triamcinolone, a corticosteroid, can result in steroid-response elevations in IOP, which also was not observed in our treatment groups. Steroids also can reduce the immune response from triamcinolone and can make the eye more prone to infection, which was not seen in this study.²⁶

Our study demonstrated the therapeutic efficacy of a combination of enoxaparin and triamcinolone in this juvenile rabbit model after lensectomy with IOL insertion. More studies must be done to determine its potential use in humans. Additional studies must examine the effect of different drug doses, such as higher amount of triamcinolone alone, and combined with a lower dose of enoxaparin, on postoperative fibrin and inflammation. Furthermore, determining the duration of half-life and clearance in the anterior chamber will help us further titrate the most effective intraocular dose of combination therapy in the context of lensectomy. Understanding the effect of enoxaparin and/or triamcinolone on the inflammatory cascade of the eye may give us clues about the mechanism of action and synergy as well as other potential therapeutic targets. Nevertheless, establishing this procedure in a juvenile rabbit model is a critical first step as we work towards reducing fibrin formation and inflammation associated with pediatric lensectomy with IOL implantation.

Acknowledgments

The authors thank Deborah Conklyn, Herbert Whitely, D.V.M, PhD, and Christine Skumatz for technical assistance and helpful discussion; the lab of Rasmi Sood, PhD, for the 59D8 fibrin antibody; Qiuhui Yang for helping to facilitate access to the

antibody; and the Children's Research Institute Histology core for all of their assistance, specifically Tatunya Bufford and Christine Duris.

Supported in part by the National Eye Institute of the National Institutes of Health (Bethesda, MD) under awards K08EY024645 (ISK), P30EY001931, and P30EY001792, and by an unrestricted departmental grant from Research to Prevent Blindness and Children's Research Institute grants. The sponsor or funding organization had no role in the design or conduct of this research.

Disclosure: **J.D. Bogaard**, None; **J.B. Young**, None; **A. Movahedan**, None; **I.S. Kassem**, None

*JDB and JBY contributed equally to the work presented here and therefore should be regarded as joint first authors.

References

- Ventura MC, Ventura BV, Ventura CV, Ventura LO, Arantes TE, Nose W. Outcomes of congenital cataract surgery: intraoperative intracameral triamcinolone injection versus postoperative oral prednisolone. *J Cataract Refract Surg.* 2014;40:601–608.
- Plager DA, Lynn MJ, Buckley EG, Wilson ME, Lambert SR, Infant Aphakia Treatment Study G. Complications in the first 5 years following cataract surgery in infants with and without intraocular lens implantation in the Infant Aphakia Treatment Study. *Am J Ophthalmol.* 2014;158:892–898.
- Gremida A, Kassem I, Traish A. Anterior capsular rupture following blunt ocular injury. *Digit J Ophthalmol.* 2011;17:66–68.
- Infant Aphakia Treatment Study G, Lambert SR, Buckley EG, et al. The infant aphakia treatment study: design and clinical measures at enrollment. *Arch Ophthalmol.* 2010;128:21–27.
- Plager DA, Lynn MJ, Buckley EG, Wilson ME, Lambert SR, Infant Aphakia Treatment Study G. Complications, adverse events, and additional intraocular surgery 1 year after cataract surgery in the infant Aphakia Treatment Study. *Ophthalmology.* 2011;118:2330–2334.
- Gwon A. The rabbit in cataract/IOL surgery. In: Tsonis P, ed. *Animal Models in Eye Research*: New York, NY: Elsevier; 2008:184–204.
- Koura Y, Fukushima A, Nishino K, et al. Inflammatory reaction following cataract surgery and implantation of acrylic intraocular lens in rabbits with endotoxin-induced uveitis. *Eye (Lond).* 2006;20:606–610.
- Kleinmann G, Apple DJ, Chew J, et al. Hydrophilic acrylic intraocular lens as a drug-delivery system: Pilot study. *J Cataract Refract Surg.* 2006;32:652–654.
- Adrenal Cortical Steroids. *Drug Facts and Comparisons*. St. Louis, MO: Facts and Comparisons, Inc.; 1997:122–128.
- Bucolo C, Grosso G, Drago V, Gagliano C. Intravitreal triamcinolone acetonide in the treatment of ophthalmic inflammatory diseases with macular edema: a meta-analysis study. *J Ocul Pharmacol Ther.* 2015;31:228–240.
- Dixit NV, Shah SK, Vasavada V, et al. Outcomes of cataract surgery and intraocular lens implantation with and without intracameral triamcinolone in pediatric eyes. *J Cataract Refract Surg.* 2010;36:1494–1498.
- Lever R, Page CP. Non-anticoagulant effects of heparin: an overview. *Handb Exp Pharmacol.* 2012;281–305.
- Jabs DA, Nussenblatt RB, Rosenbaum JT, Standardization of Uveitis Nomenclature Working Group. Standardization of uveitis nomenclature for reporting clinical data. Results of the First International Workshop. *Am J Ophthalmol.* 2005;140:509–516.
- Keane PA, Karampelas M, Sim DA, et al. Objective measurement of vitreous inflammation using optical coherence tomography. *Ophthalmology.* 2014;121:1706–1714.
- Bogaard J, Kassem IS. Evaluation of therapeutic interventions for postoperative inflammation and fibrosis in a juvenile rabbit animal model of lensectomy with intraocular lens insertion. *Invest Ophthalmol Vis Sci.* 2015;56:3217.
- Hui KY, Haber E, Matsueda GR. Monoclonal antibodies to a synthetic fibrin-like peptide bind to human fibrin but not fibrinogen. *Science.* 1983;222:1129–1132.
- Allam G, Ellakkany R, Ellayeh A, Mohsen T, Abouelkheir HE, Gaafar W. Outcome of pediatric cataract surgery with intraocular injection of triamcinolone acetonide: randomized controlled trial. *Eur J Ophthalmol.* 2018;28:633–638.
- Tatsumi T, Oshitari T, Ando T, et al. Comparison of the efficacy of sub-tenon versus intravitreal triamcinolone acetonide injection during cataract surgery for diabetic macular edema. *Ophthalmologica.* 2018;1–7.
- Caca I, Sahin A, Cingu AK, Ari S, Alakus F, Cinar Y. Effect of low molecular weight heparin

- (enoxaparin) on congenital cataract surgery. *Int J Ophthalmol*. 2012;5:596–599.
20. Rumelt S, Stolovich C, Segal ZI, Rehany U. Intraoperative enoxaparin minimizes inflammatory reaction after pediatric cataract surgery. *Am J Ophthalmol*. 2006;141:433–437.
 21. Ozkurt YB, Taskiran A, Erdogan N, Kandemir B, Dogan OK. Effect of heparin in the intraocular irrigating solution on postoperative inflammation in the pediatric cataract surgery. *Clin Ophthalmol*. 2009;3:363–365.
 22. Vasavada VA, Praveen MR, Shah SK, Trivedi RH, Vasavada AR. Anti-inflammatory effect of low-molecular-weight heparin in pediatric cataract surgery: a randomized clinical trial. *Am J Ophthalmol*. 2012;154:252–258 e254.
 23. Basti S, Aasuri MK, Reddy MK, et al. Heparin-surface-modified intraocular lenses in pediatric cataract surgery: prospective randomized study. *J Cataract Refract Surg*. 1999;25:782–787.
 24. Krall EM, Arlt EM, Jell G, et al. Intraindividual aqueous flare comparison after implantation of hydrophobic intraocular lenses with or without a heparin-coated surface. *J Cataract Refract Surg*. 2014;40:1363–1370.
 25. Maedel S, Hirnschall N, Chen YA, Findl O. Effect of heparin coating of a foldable intraocular lens on inflammation and capsular bag performance after cataract surgery. *J Cataract Refract Surg*. 2013;39:1810–1817.
 26. Veritti D, Di Giulio A, Sarao V, Lanzetta P. Drug safety evaluation of intravitreal triamcinolone acetate. *Expert Opin Drug Saf*. 2012;11:331–340.