

Prognosis of closure of large sinus membrane perforations using pedicled buccal fat pads and a resorbable collagen membrane: case series study

Young-Kyun Kim¹, Pil-Young Yun¹, Ji-Su Oh², Su-Gwan Kim²

¹Department of Oral and Maxillofacial Surgery, Seoul National University Bundang Hospital,
Section of Dentistry, Seoul National University, Seongnam,

²Department of Oral and Maxillofacial Surgery, School of Dentistry, Chosun University, Gwangju, Korea

Abstract (J Korean Assoc Oral Maxillofac Surg 2014;40:188-194)

For large membrane perforations that develop during sinus-bone grafting, we performed repairs using a pedicled buccal fat pad and a resorbable collagen membrane simultaneously with the bone graft. This study included eight patients. Postoperative maxillary sinusitis developed in two patients, which we managed with incision and drainage, and antibiotics. Ultimately, six patients received 12 implants, three of which failed (75% success). Implant replacement was performed after the removal of the failed replacement, at which point the prosthetic treatment was considered complete. In all of the six cases that we were able to follow-up with, the sinus-bone graft was healing favorably. We observed that the sinus bone height decreased gradually with time. Based on these case series, we conclude that our procedure of repairing large sinus-membrane perforations with a pedicled buccal fat pad and a collagen membrane is a reliable technique.

Key words: Sinus floor augmentation, Maxillary sinus, Adipose tissue

[paper submitted 2014. 4. 22 / revised 2014. 5. 12 / accepted 2014. 5. 22]

I. Introduction

Sinus membrane perforation is one of the most common complications to occur during sinus-bone grafts. Perforations are classified according to their size: small (5-10 mm) or large (>10 mm)¹. For a small perforation, closure with a collagen membrane or other biomaterial is recommended¹⁻³. For large perforations, it is recommended to stop the surgery and perform an additional surgery after the perforation is fixed. Newly introduced repair methods for large perforations include local flaps, collagen membranes, or autogenous block-bone grafts^{4,5}. Herein, we report 8 cases in which a large perforation in the sinus membrane was closed with a pedicled buccal fat pad graft⁶. A buccal fat pad is an autogenous graft

material that has been widely used as an alternative method for the repair of small-sized intraoral defects caused by oral and maxillofacial surgeries. This study was conducted to assess the clinical prognosis and long-term changes for bone grafts that were performed simultaneously with repair of large sinus membrane perforations using a pedicled buccal fat pad.

II. Cases Report

From among the patients for whom a perforation larger than 1 cm developed during sinus membrane elevation from January 2004 to December 2007, those for whom the reconstruction was performed using a pedicled buccal fat pad were selected for this study. Eight patients were included. The ages of the patients ranged from 41-65 years, with an average age of 53. Six patients were male, and two patients were female. The perforation area was located in the right maxillary sinus in seven cases, and the left maxillary sinus in one case. Four patients had systemic diseases, such as diabetes, hypertension, or bronchial asthma, all of which were well controlled with medications.

Su-Gwan Kim

Department of Oral and Maxillofacial Surgery, School of Dentistry, Chosun University, 309 Pilmun-daero, Dong-gu, Gwangju 501-759, Korea
TEL: +82-62-220-3819 FAX: +82-62-228-7316
E-mail: sgckim@chosun.ac.kr

© This is an open-access article distributed under the terms of the Creative Commons Attribution Non-Commercial License (<http://creativecommons.org/licenses/by-nc/3.0/>), which permits unrestricted non-commercial use, distribution, and reproduction in any medium, provided the original work is properly cited.

Copyright © 2014 The Korean Association of Oral and Maxillofacial Surgeons. All rights reserved.

All patients received surgery while under general anesthesia. After performing a crestal incision and a mucoperiosteal flap elevation, the lateral wall of the sinus becomes exposed. During the process of forming an oval bony window using a round bur, the membrane is elevated and perforations larger than 1 cm were able to develop. We exposed a pedicled buccal fat pad on the inside of the mucoperiosteal flap by performing a blunt dissection toward the posterior, superior, and lateral directions using a curved hemostat.(Fig. 1) By moving the perforation area to the sinus roof area, we partially closed it while it was in a tension-free state. We also performed additional closures of the internal perforation area by inserting a resorbable collagen membrane (Ossix Plus; OraPharma, Louis Drive Horsham, PA, USA). For bone-graft materials, we used a mixture of autogenous bone and allogenic bone (OrthoBlast II; Stryker Orthobiologics, Kalamazoo, MI, USA) and/or xenogenic bone (Bio-Oss; Geistlich Pharma, Wolhusen, Switzerland). Block bones and particulated bones that were harvested from the ramus and the maxillary tuberosity were used for autogenous bones. Four patients received a bone graft only during the primary surgery, and 4-6 months later, implants were placed secondarily. Two patients received their implants and bone graft simultaneously. The remaining two patients received only a bone graft and follow-up observation was terminated early.

We examined, the postsurgical complications, treatment procedures, and the outcomes from each implant. The follow-up observation period after sinus-bone graft ranged from 41-78 months, with an average of 56 months. Follow-up was terminated early for two patients. Using panoramic radiographs, we measured bone height at three time points: preoperatively

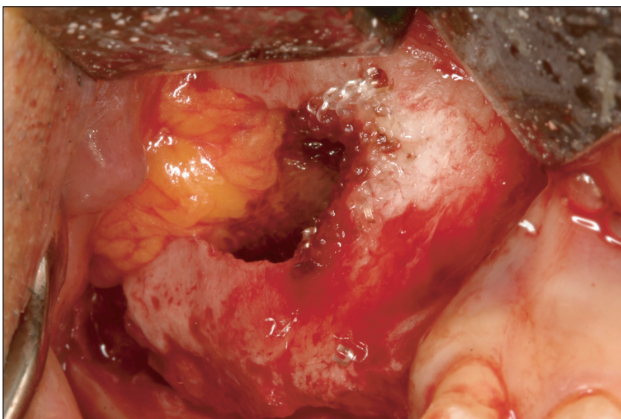


Fig. 1. A large sinus membrane perforation was covered using a pedicled buccal fat pad.

Young-Kyun Kim et al: Prognosis of closure of large sinus membrane perforations using pedicled buccal fat pads and a resorbable collagen membrane: case series study. J Korean Assoc Oral Maxillofac Surg 2014

(residual bone), immediately postsurgery, and at final follow-up. The preoperative height of remaining alveolar bone was measured from the crest to the sinus floor. To document any increases in bone height, the postoperative measurement was taken from the alveolar crest of each implant to the top-most part of the sinus-bone graft. The magnification of the radiograph was measured and evaluated based on the length of each implant. The panoramic radiographs taken one year after surgery and at the final follow-up were used to measure the volume of resorbed graft material.(Fig. 2)

1. Case 1

A right maxillary sinus bone graft was performed in a healthy 46-year-old male patient. Residual alveolar bone height was about 4-6 mm. A large perforation occurred during sinus membrane elevation. The perforation was closed using a pedicled buccal fat pad and a collagen membrane and the sinus was grafted using a block bone from the mandibular ramus and xenogenic bone (Bio-Oss). The postoperative alveolar bone height was about 19-23 mm. No specific postoperative complications appeared. Two implants were installed at areas #16 and #17 six months after the graft surgery. A final prosthesis was installed an additional six months later.(Fig. 3)

2. Case 2

A right maxillary sinus bone graft was performed on a

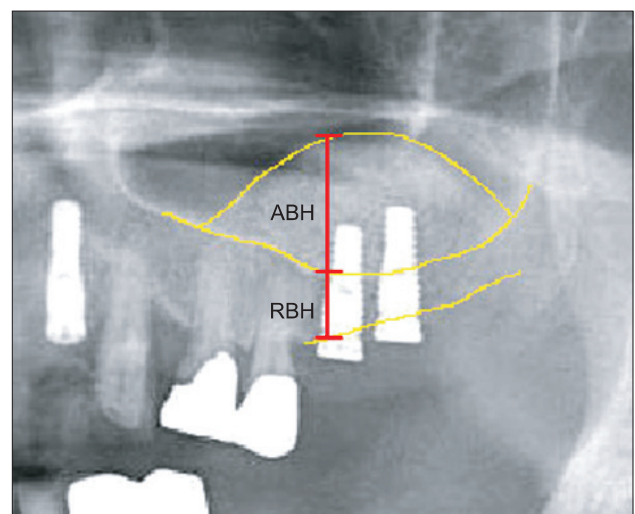


Fig. 2. Measurement of alveolar bone height. (ABH: augmented bone height, RBH: residual bone height)

Young-Kyun Kim et al: Prognosis of closure of large sinus membrane perforations using pedicled buccal fat pads and a resorbable collagen membrane: case series study. J Korean Assoc Oral Maxillofac Surg 2014

healthy 65-year-old male patient. The residual alveolar bone height was about 2-9 mm. The sinus was grafted using a mandibular ramus block bone and Bio-Oss. No specific postoperative complications arose and three implants were installed in areas #15, #16, and #17, four and half months later. An additional six months later, a final prosthesis was installed.(Fig. 4)

3. Case 3

A right maxillary second-molar extraction and right sinus-bone graft were performed on a 54-year-old male patient who

was diagnosed with diabetes mellitus but was in good condition; he was also a smoker (one pack of cigarettes per day). His residual alveolar bone height was 4.8 mm. Bone chips of maxillary tuberosity, Bio-Oss, and OrthoBlast II were grafted at the site. The patient healed well with no sinusitis. After approximately four to five months, one implant was installed at area #17. After eight months, the second operation was performed but osseointegration was not successful. Therefore, the implant was removed and replaced simultaneously. The implant was successful and a permanent prosthesis was installed after another eight months.(Fig. 5)

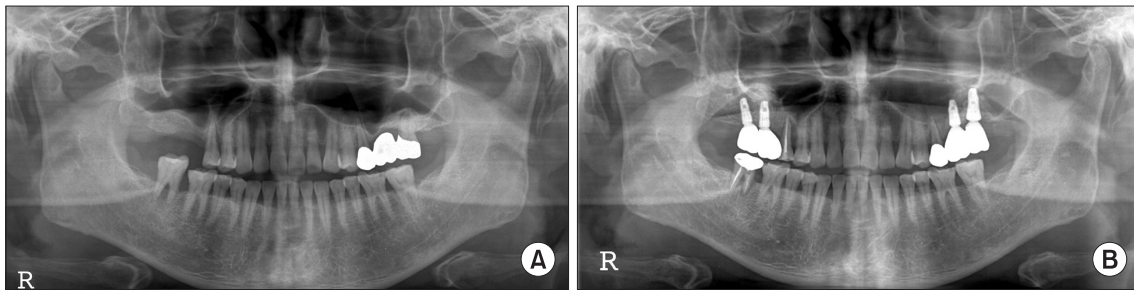


Fig. 3. Change in alveolar bone height (Case 1). A. Preoperative panoramic radiograph. B. Panoramic radiograph 78 months after sinus-bone graft.

Young-Kyun Kim et al: Prognosis of closure of large sinus membrane perforations using pedicled buccal fat pads and a resorbable collagen membrane: case series study. J Korean Assoc Oral Maxillofac Surg 2014

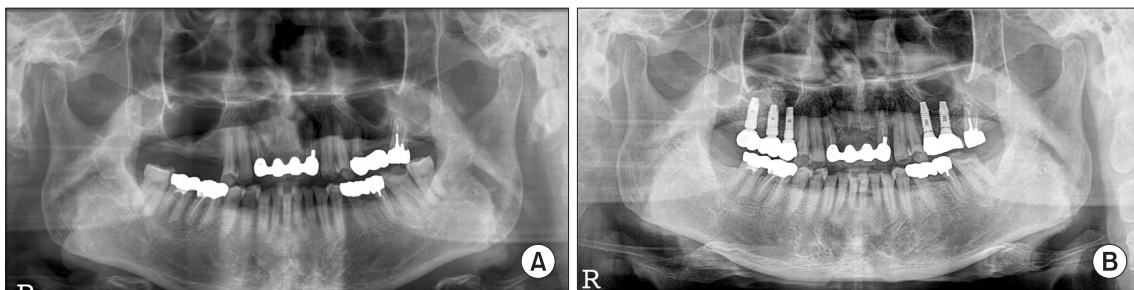


Fig. 4. Change in alveolar bone height (Case 2). A. Preoperative panoramic radiograph. B. Panoramic radiograph 59 months after sinus-bone graft.

Young-Kyun Kim et al: Prognosis of closure of large sinus membrane perforations using pedicled buccal fat pads and a resorbable collagen membrane: case series study. J Korean Assoc Oral Maxillofac Surg 2014

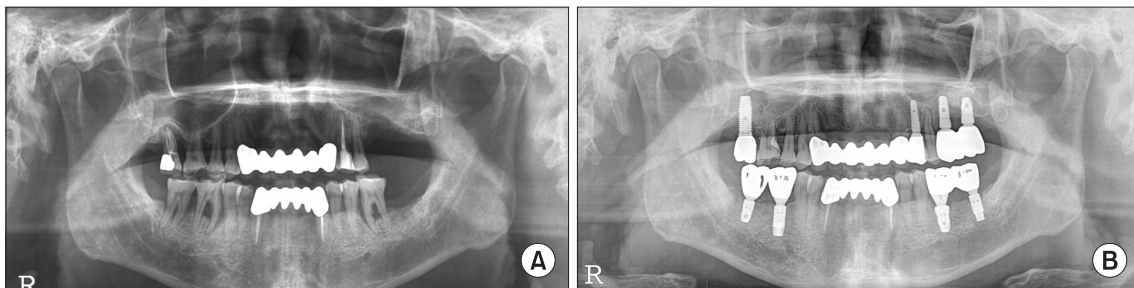


Fig. 5. Change in alveolar bone height (Case 3). A. Preoperative panoramic radiograph. B. Panoramic radiograph 53 months after sinus-bone graft: The failed implant was removed and replaced with a wide and long implant.

Young-Kyun Kim et al: Prognosis of closure of large sinus membrane perforations using pedicled buccal fat pads and a resorbable collagen membrane: case series study. J Korean Assoc Oral Maxillofac Surg 2014

4. Case 4

A left maxillary sinus-bone graft and a simultaneous implant placement at area #26 were performed on a 59-year-old male patient. The residual alveolar bone height was 4 mm. Although the patient had bronchus asthma and hypertension, he remained in good condition. We used a mandibular ramus-block bone, Bio-Oss, and OrthoBlast II, as our bone graft material. The height of the alveolar bone increased to 20 mm after surgery. Two weeks after the operation, left rhinorrhea and fluctuant swelling occurred. Maxillary sinusitis was diagnosed, and we treated it with incision and drainage, followed by a course of antibiotics; subsequently, all infection symptoms abated. Two months after the operation, the implant began to shift and was removed. We placed another implant two months later, and a permanent prosthesis was installed 14 months after the bone graft. However, even the permanent implant began to shift 51 months after its installation. The implant was removed, and another implant was re-installed at area #27: the alveolar bone height after this prosthesis was 14.2 mm.(Fig. 6)

5. Case 5

A right maxillary sinus-bone graft and delayed implant placement were performed on a 50-year-old male patient with diabetes mellitus who remained in good condition. He was also a smoker (1.5 packs per day). His residual alveolar bone height was 1.6 mm and bone chips of maxillary tuberosity, Bio-Oss, and OrthoBlast II were grafted to the site. No specific complications appeared. One implant was installed

at area #16 six months later. A final prosthesis was installed after a six-month healing period; alveolar height after this period was 16 mm.

6. Case 6

A right maxillary sinus-bone graft and simultaneous implant placement were performed on area #16 in a 52-year-old male patient with hypertension who was in good condition. This patient smoked one pack of cigarettes per day. The residual alveolar bone height was 1.6 mm and the bone-graft material was a mixture of maxillary tuberosity bones, Bio-Oss, and DBX. No specific complications arose. A permanent prosthesis was installed eight months after the grafting operation.

7. Case 7

A right maxillary sinus-bone graft was performed on a healthy 58-year-old female patient. A bone graft was performed using a maxillary tuberosity, Bio-Oss, and DBX. Although a severe hematoma developed after the operation, this symptom abated over time. Implant placement and prosthodontic treatment were performed in a local clinic.

8. Case 8

A right maxillary sinus bone graft was performed in a healthy 41-year-old female patient. A mucous retention cyst was exposed and a large sinus membrane perforation occurred. The sinus was grafted with maxillary-tuberosity bone,

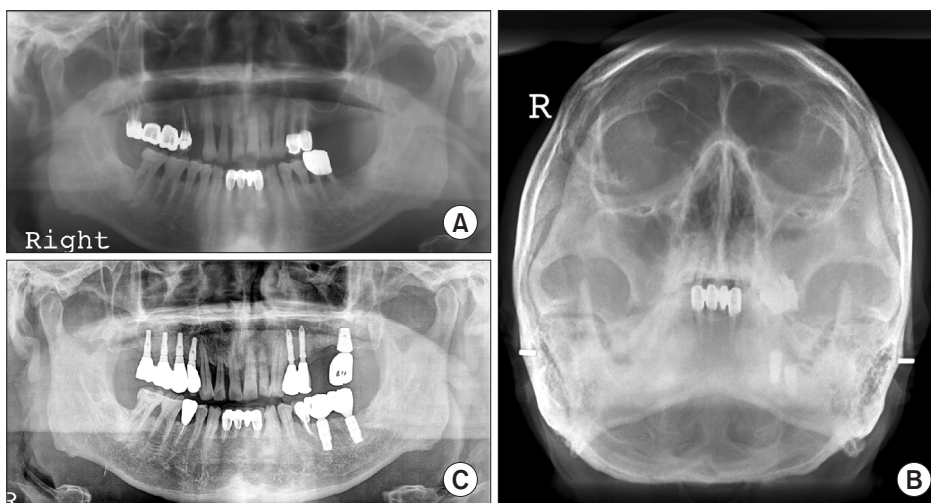


Fig. 6. Change in alveolar bone height (Case 4). A. Preoperative panoramic radiograph. B. Water's view two weeks after bone graft: left maxillary sinusitis developed. C. Panoramic radiograph 53 months after sinus bone graft: the second molar implant was removed and a new implant was placed at a distal area. The first molar implant was also removed.

Young-Kyun Kim et al: Prognosis of closure of large sinus membrane perforations using pedicled buccal fat pads and a resorbable collagen membrane: case series study. J Korean Assoc Oral Maxillofac Surg 2014

Table 1. Summary of cases

Case No.	Age (yr)	Sex	Smoking status	Perforation area	Implant placement timing (mo)	Complications	Implant status	Follow-up (mo)
1	46	M	No	Right	Delayed (6)	None	Success	78
2	65	M	No	Right	Delayed (4.5)	None	Success	59
3	54	M	Yes	Right	Delayed (4.5)	None	Failure	53
4	59	M	No	Left	Simultaneous	Sinusitis	Failure	53
5	50	M	Yes	Right	Delayed (6)	None	Success	51
6	52	M	Yes	Right	Simultaneous	None	Success	41
7	58	F	No	Right	-	Hematoma	-	Dropout
8	41	F	No	Right	-	Sinusitis	-	Dropout

(M: male, F: female)

Young-Kyun Kim et al: Prognosis of closure of large sinus membrane perforations using pedicled buccal fat pads and a resorbable collagen membrane: case series study. J Korean Assoc Oral Maxillofac Surg 2014

Table 2. Change in residual bone height in survived implants (mm)

Case No.	Area	Preoperative	Postoperative	1 Year	Final follow-up
1	#16	4	19	17.6	16.4
	#17	5.6	22.4	20	16.8
2	#15	8.8	16	12.8	12.2
	#16	2	22.8	21	19.3
3	#17	2	18.4	15.1	14.7
	#17	4.8	18.9	17.8	17.8
4	#27	4	20	16.8	14.2
5	#16	1.6	20	16	14.4
6	#16	1.6	17.6	16	16
Mean		3.8	19.5	17.0	15.8

Young-Kyun Kim et al: Prognosis of closure of large sinus membrane perforations using pedicled buccal fat pads and a resorbable collagen membrane: case series study. J Korean Assoc Oral Maxillofac Surg 2014

Bio-Oss and OrthoBlast II. Two weeks after the operation, the patient complained of tenderness when she touched the right side of her nose and of nasal-obstruction symptoms. Therefore, we suspected a case of sinusitis and performed incision and drainage. There was a thick pus discharge in the sinus cavity, so we performed a pus culture and an antibiotic-sensitivity test. Sinus irrigation was performed daily. A two-week course of minocycline was prescribed. The patient's infection symptoms abated completely two weeks after we performed incision and drainage. At this point, the follow-up observation period ended.

A total of 12 implants were placed, three of which failed to osseointegrate in two patients. We removed the failed implants and replaced them with wider implants, and after a healing period, the prosthetic treatments were completed. (Table 1) Among the case patients, the average height of the preoperative residual bone from the sinus floor was 3.8 mm; this height increased to 19.5 mm immediately after surgery, decreased slightly to 17.0 mm one year after surgery, and was 15.8 mm at the final follow-up visit. (Table 2, Figs. 2, 3)

III. Discussion

Reported rates of sinus membrane perforation during graft surgery range from 0%-58%⁷⁻⁹. Risk factors for perforation include greater height of residual bones, having a large edentulous area, presence of a septum, maxillary sinus lateral wall thickness, maxillary sinus mucosal thickness, smoking, presence of cystic lesions in the maxillary sinus, and previous maxillary allergy¹⁰⁻¹⁴. Ardekian et al.¹⁰ found that when the height of the residual bone to the maxillary sinus floor is low, risk of perforation increases. In cases where the residual bone height was less than 3 mm, an 85% perforation rate was reported. In cases where the residual bone height was 6 mm, the perforation rate dropped to 25%.

When the size of the perforation is very small (approximately 1-2 mm), the space can be closed by lifting the mucosa and overlapping it with the perforation. However, if the perforation is greater than 2 mm wide, it is better to close the perforation area using absorbable biomaterials, tissue adhesives, or platelet-rich plasma (PRP) gel¹⁵. It is well established that risk of bone-graft material loss and implant failure is higher in cases with a perforation complication than without^{14,16}.

The clinical significance of sinus perforation is controversial. Hernández-Alfaro et al.¹⁷ examined the incidence of maxillary sinus perforation during maxillary sinus lifting and evaluated a variety of treatment methods. Among 474 cases of maxillary sinus elevation, sinus perforations occurred in 104 cases (25.15%). The perforation cases included a total of 272 implants, of which 247 were successful (90.91%). As the perforation area became larger, the success rate of implants decreased.

Many authors have reported that sinus perforations do not affect the complication rate after bone graft surgery^{18,19}, but

Proussaefs et al.^{20,21} reported that even if the perforated mucosa was repaired, new bone formation and the success rate of the implants decreased. Also, Schwartz-Arad et al.²² reported that maxillary sinus perforations were strongly associated with the development of other complications, such as post-surgical infections or cysts. Nevertheless, studies have shown that maxillary sinus perforations or postsurgical complications did not strongly influence the implant survival rate¹⁻⁵.

The buccal fat pad (BFP) is special fat tissue that differs from subdermal fat. Anatomically, the BFP is easy to harvest during the course of dental surgery. In 1802, Bichat identified and described BFP. Since Egyedi²³ used a pedicled buccal fat pad (PBFP) to close an oroantral fistula and an oronasal fistula in 1977, it has been widely used as an alternative method for the reconstruction of small- to medium-sized intraoral defects during oral and maxillofacial surgery²⁴. Kim and colleagues^{6,25} reported successful results from using PBFP to cover a denuded bony surface during primary palatorrhaphy and in the reconstruction of large sinus membrane perforations. The excellent clinical outcomes from using PBFP, including rapid epithelialization and a high success rate, are partially due to its rich blood supply, which it gets from the maxillary, superficial temporal, and facial arteries. PBFP has many other advantages, including less necrosis and absorption than fat-free grafts. Furthermore, preoperative chemotherapy and postoperative radiotherapy did not seem to jeopardize survival of the graft, although these treatments do delay epithelialization²⁶.

We repaired several large sinus-membrane perforations that developed during graft surgery using a PBFP and collagen membranes; we simultaneously performed a bone graft with a mixture of autogenous bone and other bony substitutes. In this study, the change in volume of the sinus bone graft was measured and we established that repneumatization developed slowly. At the time of follow-up (after an average of 56 months, postsurgery), sinus-bone volume decreased by an average of 3.9 mm. Two implants failed to osseointegrate in a 59-year-old male patient who developed sinusitis after surgery. The implants required removal and, although healing of the residual sinus-bone graft was eventually achieved, greater sinus-bone graft loss was noted during his final follow-up visit.

Large membrane perforations that develop during sinus-bone grafting can be reconstructed immediately using a PBFP graft and resorbable collagen membrane. Implants can be placed simultaneously with the bone-graft surgery or after a certain healing period, depending on the residual bone height.

The height of the transplanted bone graft material shows a steadily decreasing pattern slowly over time. Based on this case series, we can confirm that the transplanted bone graft materials provide sufficient support for the implants.

Conflict of Interest

No potential conflict of interest relevant to this article was reported.

References

1. Pikos MA. Maxillary sinus membrane repair: report of a technique for large perforations. *Implant Dent* 1999;8:29-34.
2. Kim YK, Choe GY, Yun PY. Management of perforated sinus membrane using absorbable hemostat and fibrin adhesive for sinus lift procedure. *Asian J Oral Maxillofac Surg* 2008;20:129-34.
3. Testori T, Wallace SS, Del Fabbro M, Taschieri S, Trisi P, Capelli M, et al. Repair of large sinus membrane perforations using stabilized collagen barrier membranes: surgical techniques with histologic and radiographic evidence of success. *Int J Periodontics Restorative Dent* 2008;28:9-17.
4. Kim YK, Yi YJ, Yun PY, Yeo IS, Lee HJ, Kim SG, et al. All about implants in Q&A. *Yongin: Quint Korea*; 2010:300-7.
5. Proussaefs P, Lozada J. The "Loma Linda pouch": a technique for repairing the perforated sinus membrane. *Int J Periodontics Restorative Dent* 2003;23:593-7.
6. Kim YK, Hwang JW, Yun PY. Closure of large perforation of sinus membrane using pedicled buccal fat pad graft: a case report. *Int J Oral Maxillofac Implants* 2008;23:1139-42.
7. Krennmair G, Ulm C, Lugmayr H. Maxillary sinus septa: incidence, morphology and clinical implications. *J Craniomaxillofac Surg* 1997;25:261-5.
8. Peleg M, Mazor Z, Chaushu G, Garg AK. Sinus floor augmentation with simultaneous implant placement in the severely atrophic maxilla. *J Periodontol* 1998;69:1397-403.
9. Kasabah S, Krug J, Simůnek A, Lecaro MC. Can we predict maxillary sinus mucosa perforation? *Acta Medica (Hradec Kralove)* 2003;46:19-23.
10. Ardekian L, Oved-Peleg E, Mactei EE, Peled M. The clinical significance of sinus membrane perforation during augmentation of the maxillary sinus. *J Oral Maxillofac Surg* 2006;64:277-82.
11. Betts NJ, Miloro M. Modification of the sinus lift procedure for septa in the maxillary antrum. *J Oral Maxillofac Surg* 1994;52:332-3.
12. Cho SC, Wallace SS, Froum SJ, Tarnow DP. Influence of anatomy on Schneiderian membrane perforations during sinus elevation surgery: three-dimensional analysis. *Pract Proced Aesthet Dent* 2001;13:160-3.
13. Ulm CW, Solar P, Krennmair G, Matejka M, Watzek G. Incidence and suggested surgical management of septa in sinus-lift procedures. *Int J Oral Maxillofac Implants* 1995;10:462-5.
14. van den Bergh JP, ten Bruggenkate CM, Disch FJ, Tuinzing DB. Anatomical aspects of sinus floor elevations. *Clin Oral Implants Res* 2000;11:256-65.
15. Thorn JJ, Sørensen H, Weis-Fogh U, Andersen M. Autologous fibrin glue with growth factors in reconstructive maxillofacial surgery. *Int J Oral Maxillofac Surg* 2004;33:95-100.
16. van den Bergh JP, ten Bruggenkate CM, Krekeler G, Tuinzing DB. Maxillary sinus floor elevation and grafting with human demineralized freeze dried bone. *Clin Oral Implants Res* 2000;11:487-93.
17. Hernández-Alfaro F, Torradeflot MM, Marti C. Prevalence and

- management of Schneiderian membrane perforations during sinus-lift procedures. *Clin Oral Implants Res* 2008;19:91-8.
18. Jensen J, Sindet-Pedersen S, Oliver AJ. Varying treatment strategies for reconstruction of maxillary atrophy with implants: results in 98 patients. *J Oral Maxillofac Surg* 1994;52:210-6.
 19. Karabuda C, Arisan V, Özyuvaci H. Effects of sinus membrane perforations on the success of dental implants placed in the augmented sinus. *J Periodontol* 2006;77:1991-7.
 20. Proussaefs P, Lozada J, Kim J. Effects of sealing the perforated sinus membrane with a resorbable collagen membrane: a pilot study in humans. *J Oral Implantol* 2003;29:235-41.
 21. Proussaefs P, Lozada J, Kim J, Rohrer MD. Repair of the perforated sinus membrane with a resorbable collagen membrane: a human study. *Int J Oral Maxillofac Implants* 2004;19:413-20.
 22. Schwartz-Arad D, Herzberg R, Dolev E. The prevalence of surgical complications of the sinus graft procedure and their impact on implant survival. *J Periodontol* 2004;75:511-6.
 23. Egyedi P. Utilization of the buccal fat pad for closure of oro-antral and/or oro-nasal communications. *J Maxillofac Surg* 1977;5:241-4.
 24. Neder A. Use of buccal fat pad for grafts. *Oral Surg Oral Med Oral Pathol* 1983;55:349-50.
 25. Kim YK. The use of a pedicled buccal fat pad graft for bone coverage in primary palatorrhaphy: a case report. *J Oral Maxillofac Surg* 2001;59:1499-501.
 26. Loh FC, Loh HS. Use of the buccal fat pad for correction of intra-oral defects: report of cases. *J Oral Maxillofac Surg* 1991;49:413-6.