

Available online at www.sciencedirect.com

ScienceDirect

journal homepage: www.elsevier.com/locate/radcr

Case Report

Sino-nasal low-grade chondrosarcoma revealed by isolated bilateral loss of sight: an unprecedented presentation of a rare tumour [☆]

Soufiane Berhili, MD^{a,b,*}, Mohammed Amine Guerrouaz, MD^a, Yassine Oulhouq, PhD^{a,c},
Fatima Zahra Terrab, MD^a, Mohammed Moukhliissi, MD^{a,b},
Fahd El Ayoubi El Idrissi, MD^{b,d}, Loubna Mezouar, MD^{a,b}

^aDepartment of Radiation Oncology, Hassan II Oncology Centre, Mohammed VI University Hospital, PK 8 Jerada Road, 60000, Oujda, Morocco

^bFaculty of Medicine and Pharmacy, Mohammed Premier University, Oujda, Morocco

^cLPMR, Faculty of Sciences, Mohammed Premier University, Oujda, Morocco

^dDepartment of Otorhinolaryngology, Mohammed VI University Hospital, Oujda, Morocco

ARTICLE INFO

Article history:

Received 8 April 2022

Revised 12 April 2022

Accepted 13 April 2022

Keywords:

Low-grade chondrosarcoma
sino-nasal tumor
ophthalmological signs
radiotherapy

ABSTRACT

Chondrosarcomas are malignant cartilage-forming tumors representing less than 0.1% of all head and neck malignancies, and nasal cavity is an exceptional location among them. Clinical presentation could be consisting of either rhinological signs or asymptomatic endonasal mass. None of the previous reports mentioned ophthalmological symptoms at the forefront of the initial presentation. We report a case of sino-nasal low-grade chondrosarcoma in a patient who presented initially with isolated bilateral subtotal blindness, managed by endoscopic resection and adjuvant radiotherapy.

© 2022 The Authors. Published by Elsevier Inc. on behalf of University of Washington.

This is an open access article under the CC BY-NC-ND license
(<http://creativecommons.org/licenses/by-nc-nd/4.0/>)

Introduction

Chondrosarcoma (CS) is a malignant mesenchymal cartilage-forming tumor occurring most frequently in the long bones, pelvis, and ribs, where it represents approximately 15% of primary bone cancers [1]. The majority of patients are older than

50 years of age at diagnosis, with a slight male predominance [2].

In head and neck location, CS represents less than 10% of all sarcomas [3]; and among all CSs of the whole body, approximately 3–10% occur in the head and neck region [4,5]. These tumors are characterized by a slow growing evolution, but their etiopathogenesis remains unknown [6].

[☆] Competing Interest: The authors have no conflict of interest to declare.

* Corresponding author.

E-mail address: berhili.soufiane@gmail.com (S. Berhili).

<https://doi.org/10.1016/j.radcr.2022.04.026>

1930-0433/© 2022 The Authors. Published by Elsevier Inc. on behalf of University of Washington. This is an open access article under the CC BY-NC-ND license (<http://creativecommons.org/licenses/by-nc-nd/4.0/>)

Sino-nasal location of CS is very rare, and approximately 60 cases of CS originating from the nasal septum have been reported in the English-written literature from 1927 to 2020 [7,8]. Their Initial clinical presentation was either the discovery of asymptomatic endonasal mass or rhinological signs, consisting mainly of nasal obstruction and epistaxis [6,7]. To date, no patient presenting initially with isolated ophthalmological symptoms as primary clinical sign has been published.

We are reporting here a case of low-grade CS of the nasal cavity extended up to skull base sinuses, initially presented with isolated bilateral subtotal blindness, and managed by endoscopic resection and adjuvant radiotherapy.

Case presentation

A 55-year-old female patient was admitted to the ophthalmology department complaining of a progressive and painless bilateral loss of sight lasting for 5 months. The patient had no previous medical history, and a secondary recent onset of right nasal obstruction of 1 week was noted. Ophthalmological examination found bilateral exophthalmos, visual acuity of 1 of 10 in both eyes, with bilateral papillary pallor at dilated-pupil fundus examination.

Cerebral and orbital Magnetic Resonance Imaging (MRI) found a large lobulated lesion centred on the nasal cavity and ethmoidal cells, 61*60*68 mm in size, having a predominantly cystic architecture, hypo-signal intensity in T1 and heterogeneous hyper-signal intensity in T2, with high-signal intensity on diffusion-weighted imaging and low ADC, and showing heterogeneous enhancement after gadolinium injection (Fig. 1A).

This process invaded the nasal turbinates and ethmoidal cells, as well as the inner walls of the orbits with bilateral intra-orbital extension and displacement (without infiltration) of the medial rectus muscles and optic nerves of both eyes, responsible for grade 3 and 2 exophthalmos of the right and left eyes, respectively. The tumour was extending superiorly to the sphenoidal and frontal sinuses with endocranial extension on the olfactory region, and inferiorly to maxillary sinuses and the hard palate (on the right side).

Pathology examination of the tumor biopsy showed a malignant well-differentiated cartilage proliferation, of nodular architecture with lobules of high cell density, whose chondrocytes showed cytonuclear atypia with moderate anisokaryosis and hyperchromasia. Focal areas of myxoid remodelling and necrosis were also noted (Fig. 2). Immunohistochemistry found positive staining of tumour cells with P100 antibodies, and negative staining with Cytokeratin and EMA antibodies. These findings led to a diagnosis of low-grade CS according to the O'Neil & Ackerman classification.

The patient underwent piecemeal endoscopic tumour resection surgery without lymph node dissection. Pathological and immunohistochemical results were similar to those of the initial biopsy. Then she was referred to our oncology center to receive adjuvant Radiotherapy (RT).

Physical examination at our department found bilateral loss of sight with no other clinical signs, particularly no epistaxis or nasal obstruction were noted. Post-operative MRI showed reduction of tumor mass from its central parts, with gross residual disease at the tumor outlines (Fig. 1B)

The patient received 70 Gy in 35 fractions (2 Gy per fraction, daily, 5 fractions per week) to the planning target volume, by 3 dimension conformal RT technique, using multiple fields to maintain irradiation doses of surrounding normal tissues below their respective tolerance threshold (Fig. 3). The inter-orbital and endo-cranial parts of the tumour received only a dose of 60 Gy due to the proximity of radiation-sensitive optical and nerve structures that were at less than 1 mm from the target volume. RT took 53 days and was globally well tolerated; only grade 1-2 nasal and conjunctival acute radio-mucositis and facial radiodermatitis occurred during treatment, successfully palliated symptomatically.

Eight months after the end of RT, the patient had a clinical marked improvement in visual acuity assessed at 7 of 10 in both eyes, with endonasal desquamation as the only therapeutic sequelae. MRI evaluation showed important decrease in tumor dimensions and signal intensity, except for the inter-orbital and endocranial parts where the tumour size and aspect have remained almost unchanged (Fig. 1C). No distant metastases have been detected in thoracic-abdominal-pelvic computed tomography follow-up.

Discussion

CSs are malignant cartilage forming tumours accounting for less than 0.1% of all head and neck malignancies [3]. Nasal cavity is an exceptional location of this tumour type, with only few published cases of CSs originating from the nasal septum, and none of them has mentioned ophthalmological signs as the primary symptomatology [6–8]. This makes the present case the first in the English-written literature to report ophthalmological signs at the forefront of the clinical presentation of sino-nasal CS.

Histological characteristics of CS are easily recognized in hematoxylin and eosin staining [9]. Based on the cellularity, nuclear size and rate of mitoses, CSs are graded from 1 to 3 corresponding to low-grade (well-differentiated) to high-grade (poorly or undifferentiated) tumour [9,10]. Sufficient biopsy specimens are necessary to avoid sampling errors since there are differential diagnoses such as Enchondroma, Chondromyxoid fibroma and Chondroblastic osteosarcoma that must be ruled out before establishing the diagnosis of CS [10,11].

At times, low-grade CSs may appear very similar to chondromas. Indeed, the absence of mitoses does not eliminate the diagnosis of a malignancy, and certain characteristics such as increased nuclei size, multinucleation and irregular hyperchromatic nuclei are useful to eliminate differential diagnoses [9,10]. In general, lesions greater than 2 cm are considered CSs despite benign histological appearance [9].

CS similarity with benign histology is clinically reflected by the insidious slow growth, and patients are most often asymptomatic when the tumor displace adjacent structures before invading them [9]. This could explain why our patient had isolated ophthalmological signs 5 months before the onset of nasal obstruction.

As for other head and neck malignancies, wide excision with a cuff of normal tissue is the treatment cornerstone of CS

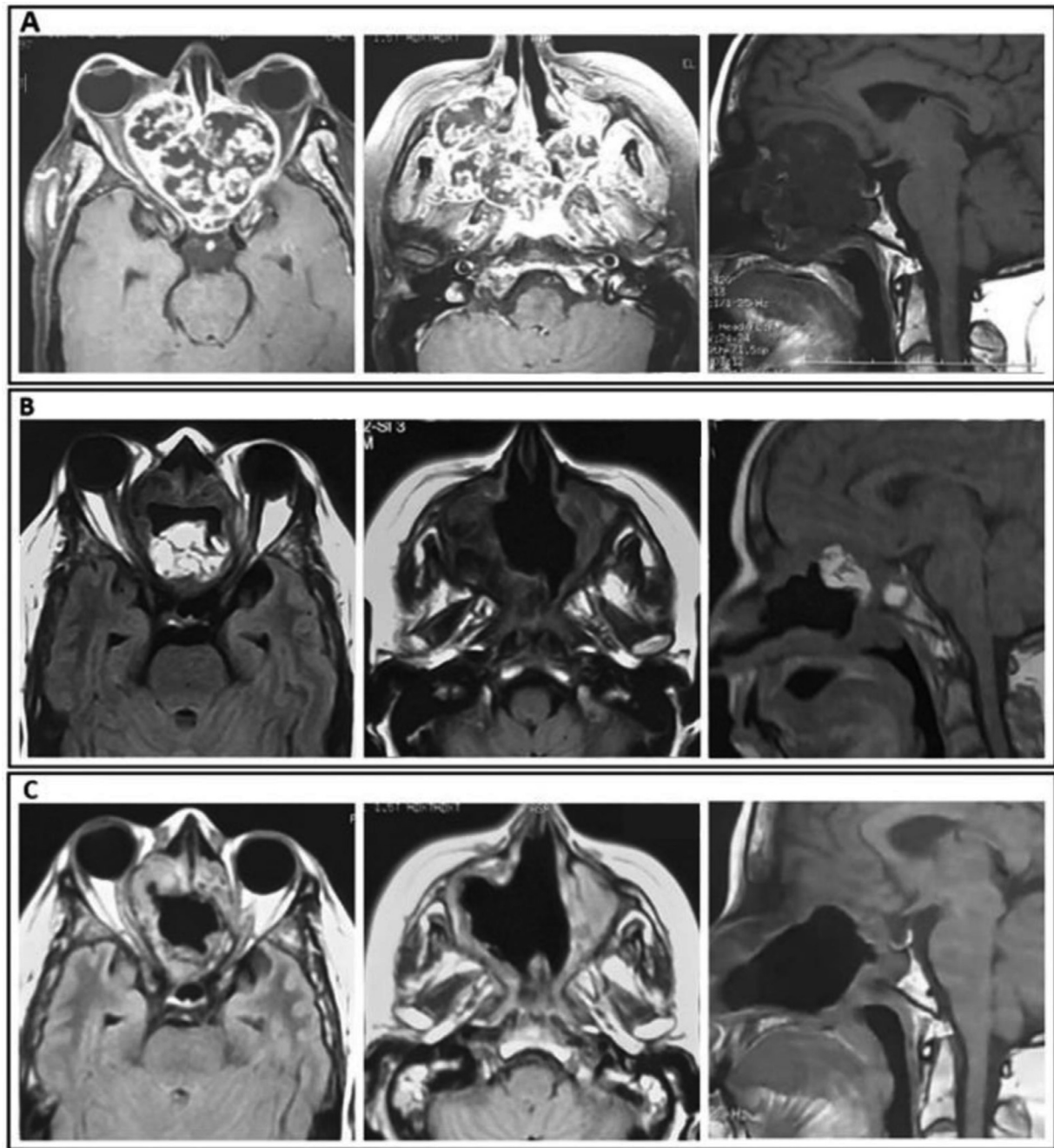


Fig. 1 – Axial and sagittal T2-weighted MRI showing the tumor extension: (A) before any treatment; (B) 3 weeks after surgery and before RT; (C) 8 months after RT

of the nasal cavity [12]. However, complete carcinological resection in locally advanced sino-nasal tumours is frequently challenging, and adjuvant therapy is usually indicated.

From a biological point of view, low-grade CSs have relatively low fraction of dividing cells and low α / β ratio of about 2.5, which make them widely considered as radio-resistant tumors [13–15]. Nevertheless, although RT was reluctantly indicated in our case, 70 Gy in 35 fractions achieved good local control at the post-operative residual tumour as demonstrated clinically by the improvement in visual acuity, and radiologically by the MRI performed 8 months later (Fig. 1C).

In addition to the observed beneficial effect of RT, our case confirmed that the tumour response in case of CS is dose-dependent, as suggested by some previous authors [15]. Indeed, the tumor areas that received a dose <60 Gy (inter-orbital and endo-cranial tumour extensions) kept a stable aspect at eight months after the end of RT, contrary to the parts that received the therapeutic dose of 70 Gy where a clear decrease in size and intensity of the MRI signal was obtained.

Because of its tendency for progressive spread and recurrences, the prognosis of CS remains poor, and 5-year survival rate ranges between 55% and 80% [15,16]. Therefore, fearing recurrences after long disease-free intervals, clinical controls

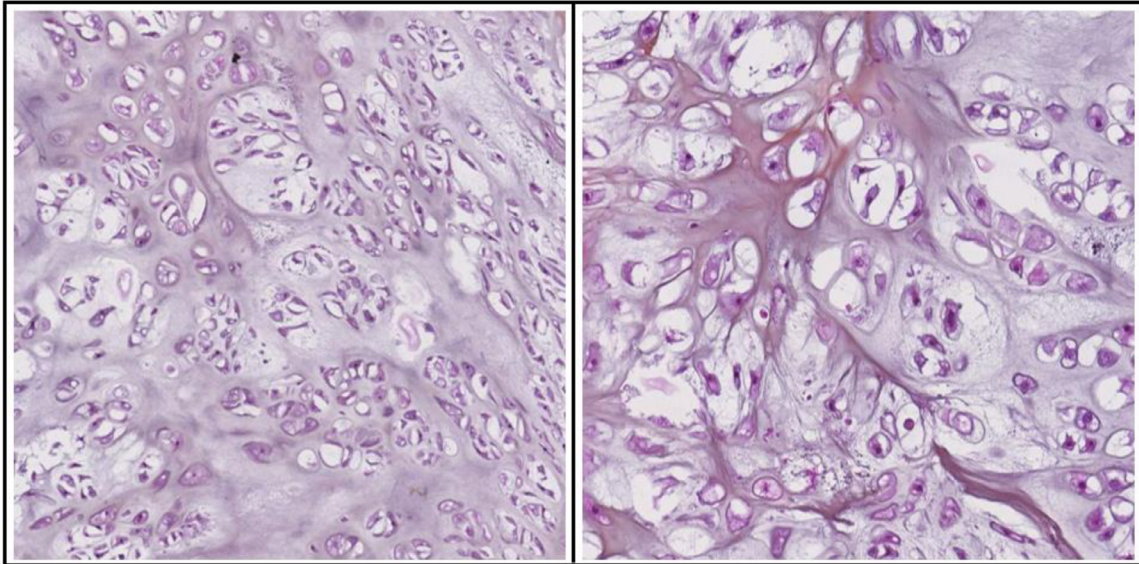


Fig. 2 – Microscopic examination with hematoxylin & eosin staining x10 (left) and x40 (right), showing malignant well-differentiated cartilage proliferation made of chondrocytes with cytonuclear atypia, moderate anisokaryosis and hyperchromasia

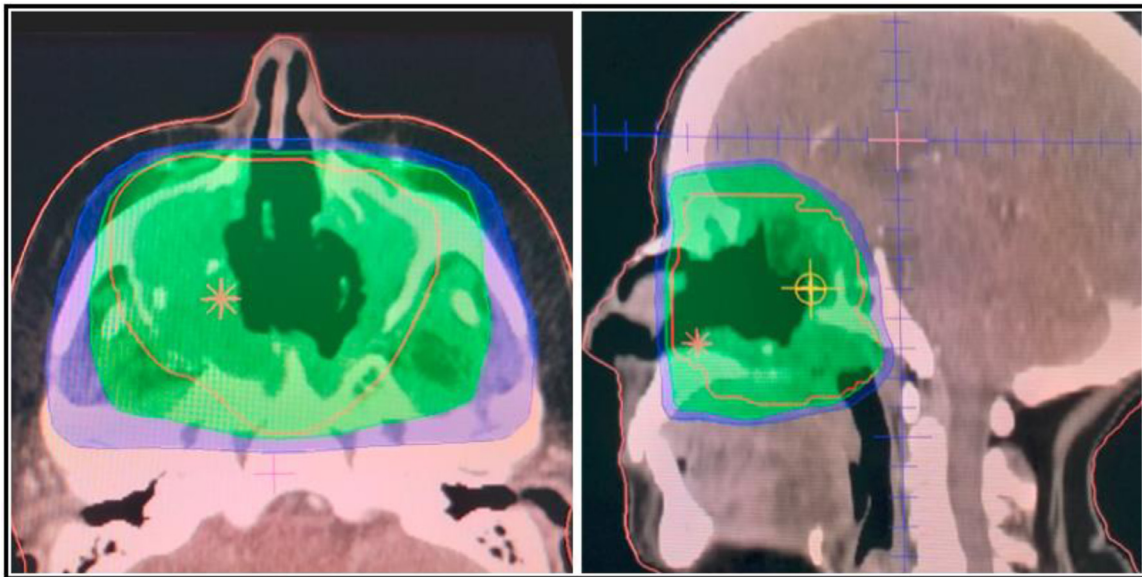


Fig. 3 – Dosimetric planification of RT in axial (left) and sagittal (right) views, with the therapeutic isodose area (in green) covering the planning target volume (in red). (Color version of figure is available online.)

with radiological and endoscopic examinations must be regularly carried out in a lifelong monitoring.

grade sino-nasal CS leads to satisfactory results, especially when high radiation doses can be safely delivered.

Conclusion

Isolated ophthalmological signs may cause delay in the diagnosis of sino-nasal tumours, leading to very locally advanced presentations. Adjuvant RT after incomplete resection of low-

Patient consent

Written, informed consent for publication of this case was obtained from the patient.

REFERENCES

- [1] Downey TJ, Clark SK, Moore DW. Chondrosarcoma of the nasal septum. *Otolaryngol Head Neck Surg* 2001;125(1):98–100 PMID: 11458223. doi:10.1067/mhn.2001.116236.
- [2] van Praag Veroniek VM, Rueten-Budde AJ, Ho V, Dijkstra PDS, Fiocco M, et al., Study group Bone and Soft tissue tumours (WeBot) Incidence, outcomes and prognostic factors during 25 years of treatment of chondrosarcomas. *Surg Oncol* 2018;27(3):402–8 Epub 2018 May 6. PMID: 30217294. doi:10.1016/j.suronc.2018.05.009.
- [3] Koch BB, Karnell LH, Hoffman HT, Apostolakis LW, Robinson RA, Zhen W, et al. National cancer database report on chondrosarcoma of the head and neck. *Head Neck* 2000;22(4):408–25 PMID: 10862026. doi:10.1002/1097-0347(200007)22:4<408::aid-hed15>3.0.co;2-h.
- [4] Bahgat M, Bahgat Y, Bahgat A, Elwany Y. Chondrosarcoma of the nasal septum. *BMJ Case Rep* 2012;2012 bcr2012006266 PMID: 22669930; PMCID: PMC4543308. doi:10.1136/bcr-2012-006266.
- [5] Burkey BB, Hoffman HT, Baker SR, Thornton AF, McClatchey KD. Chondrosarcoma of the head and neck. *Laryngoscope* 1990;100(12):1301–5 PMID: 2243522. doi:10.1288/00005537-199012000-00010.
- [6] Belgioia L, Vaccara EM, Bacigalupo A, Corvò R. Management of nasal septum chondrosarcoma occurring in elderly: a case report. *Cureus*. 2017;9(7):e1497 PMID: 28948117; PMCID: PMC5606711. doi:10.7759/cureus.1497.
- [7] Saito K, Unni KK, Wollan PC, Lund BA. Chondrosarcoma of the jaw and facial bones. *Cancer* 1995;76(9):1550–8 PMID: 8635057. doi:10.1002/1097-0142(19951101)76:9<1550::aid-cnrcr2820760909>3.0.co;2-s.
- [8] Sahu PK, Goyal L, Bothra J, Shashivadhanan Sharma P. Chondrosarcoma of nasal cavity: a rare entity. *Indian J Surg Oncol* 2020;11(Suppl 2):288–92 Epub 2020 Aug 28. PMID: 33364722; PMCID: PMC7732946. doi:10.1007/s13193-020-01202-7.
- [9] Carrau RL, Aydogan B, Hunt JL. Chondrosarcoma of the sphenoid sinus resected by an endoscopic approach. *Am J Otolaryngol* 2004;25(4):274–7 PMID: 15239037. doi:10.1016/j.amjoto.2003.12.007.
- [10] Limaïem F, Davis DD, Sticco KL. Chondrosarcoma. 2021 Aug 25. *StatPearls [Internet]*, Treasure Island (FL): StatPearls Publishing; 2022. PMID: 30844159.
- [11] Maingi S, Padiyar BV, Sharma N. Chondrosarcoma of the nasal septum: a case report. *Dubai med J* 2019;2:107–10 Doi: doi:10.1159/000501450.
- [12] Lee DH, Jung SH, Yoon TM, Lee JK, Joo YE, Lim SC. Low grade chondrosarcoma of the nasal septum. *World J Clin Cases* 2013;1(1):64–6 PMID: 24303467; PMCID: PMC3845920. doi:10.12998/wjcc.v1.i1.64.
- [13] Kaufman JK, Pritz MB, Righi PD, Bizal JC. Craniofacial resection of a nasoseptal chondrosarcoma: case report and review of the literature. *Surg Neurol* 1999;52(3):265–8 discussion 268–9 PMID: 10511084. doi:10.1016/s0090-3019(99)00085-3.
- [14] Riedel RF, Larrier N, Dodd L, Kirsch D, Martinez S, Brigman BE. The clinical management of chondrosarcoma. *Curr Treat Options Oncol* 2009;10(1-2):94–106 Epub 2009 Feb 24. PMID: 19238552. doi:10.1007/s11864-009-0088-2.
- [15] Kamal AF, Husodo K, Prabowo Y, Hutagalung EU. Correlation between survival and tumour characteristics in patients with chondrosarcoma. *J Orthop Surg (Hong Kong)* 2015;23(3):365–9 PMID: 26715720. doi:10.1177/230949901502300323.
- [16] Jaswal A, Jana AK, Sikder B, Jana U, Nandi TK. Chondrosarcoma of nose and paranasal sinus - a rare presentation. *Indian J Otolaryngol Head Neck Surg* 2008;60(3):284–6 Epub 2008 Oct 22. PMID: 23120565; PMCID: PMC3450645. doi:10.1007/s12070-008-0095-9.