



Clinico-basic Convergence

Morphometry of the triangle of Koch and position of the coronary sinus opening in cadaveric fetal hearts

Sharan Shanubhogue^a, Thuslima Mohamed^b, Nachiket Shankar^{b,*}^a Intern, St. John's Medical College, Bangalore, Karnataka, India^b Department of Anatomy, St. John's Medical College, Bangalore, Karnataka, India

ARTICLE INFO

Article history:

Received 27 June 2015

Accepted 2 July 2016

Available online 11 July 2016

Keywords:

Coronary sinus ostium

Triangle of Koch

Near-term fetuses

ABSTRACT

Aims: The aim of the present study was to determine the variations in the position of the coronary sinus (CS) ostium in normal cadaveric fetal (28 weeks or more) hearts and to assess the impact that these variations had on the dimensions of the triangle of Koch (TK).

Methods: This cross-sectional analytical study was conducted on 28 fetal hearts. The dimensions and area of the TK were calculated by two methods, M1 (anatomical) and M2 (clinical). The position of the CS was defined with respect to the tendon of Todaro. Differences between M1 and M2 were estimated using the paired *T* test. Pearson's correlation coefficient and the adjusted correlation coefficient were used to estimate the strength of association between measurements made by the methods.

Results: Ten (35.7%) cadavers were male and 18 (64.3%) female. The mean gestational age was 32.4 ± 3.3 weeks. Using M1, the mean dimensions of the triangle in millimeters (mm) were 9.2 ± 2.2 , 6.6 ± 1.8 , and 6 ± 2.4 respectively for *a*, *b* and *c*. Similarly, the dimensions using M2 were 7 ± 2.1 , 4.7 ± 1.5 , and 4.8 ± 2.2 . The area in mm^2 was 20.4 ± 10.4 and 11.7 ± 6.7 using M1 and M2 respectively. All measurements were significantly greater with M1. All correlation coefficients were high and significant. The CS ostium and tendon of Todaro maintained a relatively constant positional relationship.

Conclusions: Significantly higher values were noted in the dimensions of TK using M1. High significant positive correlations were observed in measurements made by the two methods. The CS ostium was relatively constantly placed within the TK.

© 2016 Published by Elsevier B.V. on behalf of Cardiological Society of India. This is an open access article under the CC BY-NC-ND license (<http://creativecommons.org/licenses/by-nc-nd/4.0/>).

What is already known?

- The dimensions of the triangle of Koch in adults and older children

What this study adds

- The dimensions of the triangle of Koch and position of the coronary sinus ostium in near-term fetuses

1. Introduction

The coronary sinus (CS) is the major vein of the heart which opens into the right atrium. The CS is one of the landmarks that is used to define the triangle of Koch (TK). The TK is situated in the inter-atrial septum of the right atrium. The septal leaflet of the tricuspid valve and the tendon of Todaro are the other anatomical landmarks that are used to define the TK. The atrio-ventricular (AV) node is located at the apex of this triangle.¹

Accessory conducting tissue responsible for supraventricular arrhythmias may course within the boundaries of the TK. The ostium of the CS is used as a site of entry into the right atrium during catheter ablation procedures used in the treatment of resistant supraventricular arrhythmias. Variations in the dimensions of the TK are likely to impact the outcomes of these procedures, especially in children.² With advances in technology, ablation procedures are increasingly being performed in neonates.^{3,4} In children, unlike adults the size of the TK is proportional to body size. Therefore, during ablation of a lesion of fixed size,

* Corresponding author at: Department of Anatomy, St. John's Medical College, Sarjapur Road, Bangalore 560034, Karnataka, India. Tel.: +91 80 22065061/62; fax: +91 80 25520777.

E-mail address: nachiket76@gmail.com (N. Shankar).

there is a greater likelihood of damaging vital neighboring structures as compared to adults.⁵

While there have been a number of studies regarding the dimensions of the TK in older children, there is a paucity of data in neonates.^{2,6,7} With catheter ablation procedures being increasingly carried out in neonates, it becomes imperative to have normative data in this age group. The CS ostium is one of the key landmarks in this region.⁸ Though its morphometric characteristics have been reported in studies conducted in adults, the variability of its location relative to the other boundaries of the TK has not.^{8–11} This calls for a better understanding of the morphometry of the TK for ensuring successful ablation. Variations in the position and size of the CS ostium are likely to have a greater impact on the dimensions of the TK, as the other two boundaries are relatively constant in position.

A previous study compared the dimensions of the TK using two methods, one anatomical and the other used by interventional cardiologists, in postmortem adult hearts.¹ Significant differences were noted in the measurements made by the two methods.¹ The aim of the present study was to determine the variations in the position of the CS ostium in cadaveric fetal (28 weeks or more) hearts and to assess the impact that these variations had on the dimensions of the TK. The objectives of the study were to estimate the following: (1) position of the CS ostium with respect to the tendon of Todaro; (2) difference in the dimensions of the TK by two different methods (M1 and M2); (3) strength of association between the dimensions of the TK using M1 and M2; (4) strength of association between the dimensions of the TK using M1 and M2 after adjusting for the position of the CS.

2. Materials and methods

2.1. Study design and sampling

This was a cross-sectional, analytical study conducted at the Department of Anatomy in a medical college attached to a tertiary care hospital in South India. Ethical clearance was obtained from the Institutional Ethics Committee before commencement of the study. Cadavers of fetuses already available in the department with a gestational age (estimated using crown-rump length) more than or equal to 28 weeks were included.¹² Fetuses with cardiovascular anomalies were excluded. Data available from an earlier pilot study in 16 fetal cadaveric hearts were used to calculate the sample size. The sample size was calculated for hypothesis testing for a difference between paired means. A final sample size of 28 was arrived at assuming a difference of 8 mm² in the area measurements between M1 and M2, a standard deviation of 12 mm² for each method, with the α error set at 5% and power at 90%.

2.2. Dissection technique and measurements

The fetal hearts were dissected out from the cadavers and separated of all their vascular connections. The right atrium was opened along the sulcus terminalis. The TK was defined and photographed from above in a standardized manner, along with a scale for calibration and a pointer in the CS opening. All measurements were subsequently made on the photographs so obtained.

The methods M1 and M2 used to estimate the sides and area of the TK are shown in Fig. 1.¹ For measurements by M1, line a_1 was the tendon of Todaro. Line b_1 was drawn through the CS opening, joining the tendon of Todaro and septal leaflet of the tricuspid valve line c_1 was drawn along the septal leaflet of the tricuspid valve extending from the central fibrous body to the line b_1 (Fig. 1a).¹ Using M2, line a_2 was the tendon of the Todaro. Line b_2 was formed by joining the nearest point on the CS opening toward the side of the tendon, to the septal leaflet of the tricuspid

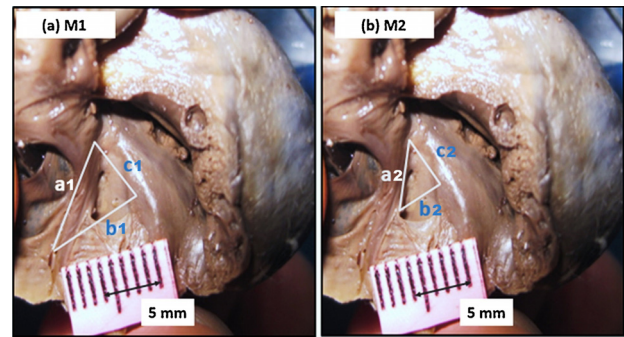


Fig. 1. A superior view photograph of the TK, after opening the anterior wall of the right atrium with a scale for calibration. The sides of the TK using M1 (a) and M2 (b) are marked. a_1, b_1, c_1 – sides of the TK using method 1; a_2, b_2, c_2 – sides of the TK using method 2; M1 – method 1; M2 – method 2.

valve. Line c_2 was drawn from the central fibrous body along the septal leaflet of the tricuspid valve to join line b_2 (Fig. 1b).¹ When the tendon of Todaro was not prominent, traction was applied to the valve of the inferior vena cava and the linear prominence so formed was taken to be the tendon of Todaro. The length of the sides of the TK and its area by M1 and M2 were then estimated using ImageJ, an open source image analysis software.

The position of the CS with respect to the central fibrous body and the tendon of Todaro was estimated as shown in Fig. 2. A line K was drawn from the central fibrous body to the nearest margin of the CS opening. The angle subtended by line K with side a (angle k) was measured. A perpendicular (p) line was drawn from the CS end of line K to side a , and the length of this line was measured. The magnitude of angle k and the length of p were used to define the position of the CS ostium.

2.3. Statistical analysis

The paired T test was used to estimate any differences in the measurements between M1 and M2. The strength of association

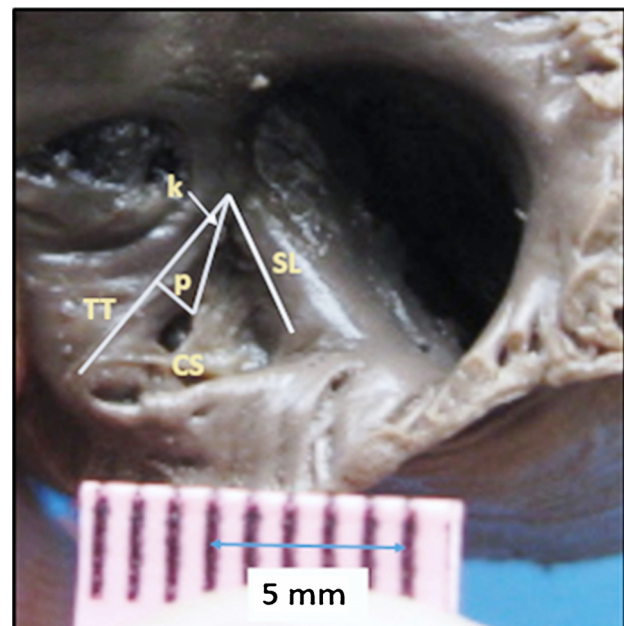


Fig. 2. A superior view photograph of the TK showing the method used to define the position of the CS ostium in relation to the tendon of Todaro. CF – central fibrous body; CS – coronary sinus ostium; SL – septal leaflet of the tricuspid valve; TT – tendon of Todaro; K – line joining the nearest margin of the CS ostium and the central fibrous body; k – angle subtended by K with side a ; p – perpendicular drawn from K to side a .

Table 1
Dimensions of the TOK using M1 and M2.

Triangle of Koch (n=28)	M1 (Mean ± SD mm/mm ²)	M2 (Mean ± SD mm/mm ²)	P value
Side – a	9.2 ± 2.2	7 ± 2.1	<0.001
Side – b	6.6 ± 1.8	4.7 ± 1.5	<0.001
Side – c	6 ± 2.4	4.8 ± 2.2	<0.001
Area	20.4 ± 10.4	11.7 ± 6.7	<0.001

Table 2
Strength of association between the dimensions of the TK before and after adjusting for the position of the CS.

Triangle of Koch (n=28)	Correlation coefficient (r) Before adjustment	P value	Correlation coefficient (r) After adjustment	P value
a1 and a2	0.844	<0.001	0.530	0.035
b1 and b2	0.819	<0.001	0.687	0.003
c1 and c2	0.945	<0.001	0.814	<0.001
Area1 and area2	0.894	<0.001	0.758	0.001

between the dimensions and area, between M1 and M2 was estimated using Pearson's correlation coefficient. Adjusted correlation coefficients were used to estimate the effect of the position of the CS on the strength of association between the values obtained by M1 and M2. A P value less than 0.05 was considered statistically significant.

3. Results

Of the 28 fetal cadavers studied, 10 (35.7%) were male and 18 (64.3%) were female. The mean gestational age was 32.4 ± 3.3 weeks. Using M1, the mean dimensions of the triangle in millimeters (mm) were 9.2 ± 2.2 , 6.6 ± 1.8 , and 6 ± 2.4 respectively for a, b, and c. Similarly, the dimensions using M2 were 7 ± 2.1 , 4.7 ± 1.5 , and 4.8 ± 2.2 . The area in mm² was 20.4 ± 10.4 and 11.7 ± 6.7 using M1 and M2 respectively (Table 1). All the above parameters were normally distributed according to the Kolmogorov–Smirnov test. The paired T test showed that the dimensions of the TK and its area were significantly greater using M1 as compared to M2. All the correlation coefficients before adjusting for the position of the CS were high and significant (Table 2). On adjusting for the position of the CS all the correlation coefficients were reduced, but were still high and

significant. The mean perpendicular distance (p) of the CS ostium from the tendon of Todaro was 1.8 ± 0.45 mm. The mean angle (k) subtended by the line joining the central fibrous body and nearest point of CS ostium and the tendon of Todaro was $21.1 \pm 6.6^\circ$.

4. Discussion

In the present study, all the sides and area of the TK measured by M2 were significantly less compared to M1. A previous study conducted on cadaveric adult hearts also showed similar results.¹ Method M1 more closely represents the TK as defined by anatomists in cadavers. When interventional cardiologists approach the heart through the CS, the TK that is accessible to them corresponds more closely with M2.¹ There have been a number of studies on the dimensions of the TK in children.^{2,6,7,13} However, the number of neonates, if present, in these studies was small. This study attempted to provide morphometric data regarding the TK in near-term fetuses using M1 and M2, and comparing them.

A previous study compared the dimensions of the TK in perinatal hearts with and without Ebstein's anomaly.¹³ A comparison between the measurements of that study and the present study is shown in Table 3.¹³ It is to be noted that while differences in the lengths of a and b are minimal, the length of c and the area are considerably lower in the present study. It is possible that the size of the CS ostium has a role to play in explaining these differences. It is likely that the CS ostium is relatively larger in fetuses as compared to the other anatomical landmarks used to define the TK.

The relative difference between the dimensions and area by M1 and M2 seen in adult hearts was compared with that of our study (Table 4).¹ Similar differences were noted between sides a and c. However, there were greater differences in side b and the area in the present study. These differences could possibly be explained by the differential growth of the boundaries of the TK till the heart reaches its full adult size. The main difference between M1 and M2 was the position of the perpendicular (side b) drawn from or through the opening of the coronary sinus. Thus, it was hypothesized that variability in the position and size of the CS opening was likely to have an impact on the dimensions as measured by the two different methods. This is the likely explanation for the base of the triangle (b) having the least correlation coefficient as compared to the other two sides. On adjusting for the dimensions of the TK with the position of the CS,

Table 3
Comparison of the dimensions of TK by M1.

Authors	Study group	Dimensions of the TOK by M1 (Mean ± SD mm/mm ²)			
		a	b	c	Area
Sánchez-Quintana et al. ¹³ (n=6)	Perinatal hearts (35 weeks to 2 days after birth)	9.5 ± 2.6	6.1 ± 1.5	7.5 ± 1.5	25.5 ± 6.5
Present study (n=28)	Fetal hearts (28–38 weeks)	9.2 ± 2.2	6.6 ± 1.8	6 ± 2.4	20.4 ± 10.4

a, b, c – sides of the TK.

Table 4
Comparison of the relative difference in dimensions and area of the TK between adult and fetal hearts using M1 and M2.

Authors	Study group	Relative decrease (%) in mean dimensions and area of TK by M2 as compared to M1			
		a	b	c	Area
Zhivadinovik et al. ¹ (n=50)	Adults (20–88 years)	18	40	19	52
Present study (n=28)	Fetal hearts (28–38 weeks)	22	29	20	43

a, b, c – sides of the TK.

the correlation coefficients obtained were lower than those without the adjustments. This indicates that variations in the position of the CS are not an important factor to explain the differences noted between M1 and M2. Further studies are necessary for elaborating the factors which affect the dimensions of the TK including the size of the CS ostium.

The position of the CS ostium is vital importance to the cardiac electrophysiologist.⁸ This study adds data regarding the position of the CS with respect to the tendon of Todaro and central fibrous body. When data from the present study were compared with previous studies (Tables 3 and 4), the border that showed the most consistent dimensions across the studies was the tendon of Todaro (side a). This is in concurrence with a previous study which concluded that the tendon of Todaro was a reliable border for the TK and could serve as a landmark to locate the atrial components of the AV conduction axis.¹⁴ By far the most common tachyarrhythmia seen in pediatric patients is supraventricular tachycardia.³ While most of these children can be treated conservatively, a small proportion require catheter ablation.³ One of the complications of this procedure is AV block.⁵ This is more common in children with aberrant pathways in the atrial septum. During ablation of these pathways, the TK can be used as anatomical landmark. This study may thus aid by providing morphometric data about the TK which can be applied in neonates requiring catheter ablation.

This study has a number of limitations. The identification of the tendon of Todaro was based on gross appearance which may not be as reliable as a histological confirmation of its location. The conversion of the three dimensional nature of the TK into a two dimensional picture necessarily introduces some inaccuracies in the measurements. This study was done on formalin fixed hearts of cadavers in which the process of fixation could alter the dimensions of the TK. As the size of the CS ostium could not be accurately measured from the pictures, these data were not collected. These data could have provided additional valuable insight into the factors altering the dimensions of the TK. In the future, this study can be extended to locate the exact position of the AV node and AV nodal artery within the TK using histological methods.¹³ It could be supplemented by reliability testing of the method (both intra- and inter-observer) and electro-physiological mapping studies.¹⁵

5. Conclusions

The present study was conducted with the intention of measuring the dimensions of the TK in the hearts of fetuses that crossed the period of viability by two methods (M1 and M2). Additionally, the location of the CS ostium was defined with respect to the tendon of Todaro and central fibrous body. Significantly higher values were noted in dimension and area measurements using M1 as compared to M2. High significant positive correlations were observed in the side and areas

measurements between the two methods. The CS ostium was relatively constantly placed in relation to the tendon of Todaro.

Conflicts of interest

The authors have none to declare.

Acknowledgments

This study was made possible only because of the parents who donated the bodies of their still-born children to the Department of Anatomy. The authors are immensely grateful to them. This was not a funded project.

References

- Zhivadnovik J, Lazarova D, Gjorgov N. Dimensions of the triangle of Koch. *Bratisl Lek Listy*. 2006;107:107–109.
- Sumitomo N, Tatenos S, Nakamura Y, et al. Clinical importance of Koch's triangle size in children: a study using 3-dimensional electroanatomical mapping. *Circ J*. 2007;71:1918–1921.
- Akdeniz C, Ergul Y, Kiplapinar N, Tuzcu V. Catheter ablation of drug resistant supraventricular tachycardia in neonates and infants. *Cardiol J*. 2013;20:241–246. <http://dx.doi.org/10.5603/cj.2013.0068>.
- Blafox AD, Felix G, Blafox AD, et al. Radiofrequency catheter ablation in infants <18 months old. *Distribution*. 2001;104:2803–2808 <http://www.ncbi.nlm.nih.gov/pubmed/11733398>.
- Blafox AD. Catheter ablation of tachyarrhythmias in small children. *Indian Pacing Electrophysiol J*. 2005;5:51–62.
- Francalanci P, Drago F, Agostino DA, et al. Koch's triangle in pediatric age: correlation with extra- and intracardiac parameters. *Pacing Clin Electrophysiol*. 1998;21:1576–1579. <http://dx.doi.org/10.1111/j.1540-8159.1998.tb00245.x>.
- Goldberg CS, Caplan MJ, Heidelberger KP, Dick M. The dimensions of the triangle of Koch in children. *Am J Cardiol*. 1999;83:117–120. [http://dx.doi.org/10.1016/S0002-9149\(98\)00794-2](http://dx.doi.org/10.1016/S0002-9149(98)00794-2).
- Mlynarski R, Mlynarska A, Tendera M, Sosnowski M. Coronary sinus ostium: the key structure in the heart's anatomy from the electrophysiologist's point of view. *Heart Vessels*. 2011;26:449–456. <http://dx.doi.org/10.1007/s00380-010-0075-3>.
- Weiss C, Cappato R, Willems S, Meinertz T, Kuck KH. Prospective evaluation of the coronary sinus anatomy in patients undergoing electrophysiologic study. *Clin Cardiol*. 1999;22:537–543.
- Ong MGY, Lee PC, Tai CT, et al. Coronary sinus morphology in different types of supraventricular tachycardias. *J Interv Card Electrophysiol*. 2006;15:21–26. <http://dx.doi.org/10.1007/s10840-006-7619-6>.
- Randhawa A, Saini A, Aggarwal A, Rohit MK, Sahni D. Variance in coronary venous anatomy: a critical determinant in optimal candidate selection for cardiac resynchronization therapy. *Pacing Clin Electrophysiol*. 2013;36:94–102. <http://dx.doi.org/10.1111/pace.12026>.
- Busuttill A, Keeling J, eds. In: *Paediatric Forensic Medicine and Pathology* 1st ed. 2008. <http://dx.doi.org/10.2350/09-03-0629-BR.1>.
- Sánchez-Quintana D, Picazo-Angelín B, Cabrera A, Murillo M, Cabrera JA. Koch's triangle and the atrioventricular node in Ebstein's anomaly: implications for catheter ablation. *Rev Esp Cardiol*. 2010;63:660–667. [http://dx.doi.org/10.1016/S1885-5857\(10\)70140-7](http://dx.doi.org/10.1016/S1885-5857(10)70140-7).
- Ho SY, Anderson RH. How constant anatomically is the tendon of Todaro as a marker for the triangle of Koch? *J Cardiovasc Electrophysiol*. 2000;11:83–89.
- Yamaguchi T, Tsuchiya T, Nagamoto Y, et al. Anatomical and electrophysiological variations of Koch's triangle and the impact on the slow pathway ablation in patients with atrioventricular nodal reentrant tachycardia: a study using 3D mapping. *J Interv Card Electrophysiol*. 2013;37:111–120. <http://dx.doi.org/10.1007/s10840-012-9769-z>.