

# Minimally Invasive Nerve- and Muscle-Sparing Surgical Decompression for Occipital Neuralgia

Giorgio Pietramaggiore, MD,  
PhD<sup>1,2</sup>

Saja Scherer, MD<sup>1,2</sup>

Lausanne, Switzerland; and  
Padua, Italy



**Background:** Occipital neuralgia is a well-defined type of headache, and its treatment algorithm is still debated across medical specialties. From the analysis of the literature, it appears that surgical decompression of the occipital nerves is the most effective invasive approach to improve the quality of life of patients with occipital neuralgia refractory to medications. The authors describe here a minimally invasive nerve- and muscle-sparing technique to decompress the occipital nerves.

**Methods:** The results in terms of reduction of migraine days per month, use of medications, pain evaluation, and decrease in Migraine Headache Index were analyzed by means of a retrospective chart review of 87 patients who underwent nerve- and muscle-sparing surgical decompression of the greater and lesser monolateral or bilateral occipital nerves in their institution and were followed up for at least 12 months. The surgical technique is described in detail.

**Results:** Surgical decompression significantly reduced occipital neuralgia burden (at least 50% improvement) in 91% of patients, with 45% reporting a complete remission of occipital pain. Days with pain per month decreased by 80%, chronic background pain intensity decreased by 81%, and pain intensity during crisis decreased by 76%. Accordingly, drug use dropped by approximately 70%. Only minor complications were reported in four patients.

**Conclusions:** The described technique could contribute to and further support surgical decompression as the first option among the invasive approaches to treat occipital neuralgia. Results corroborate previous findings, adding a less-invasive, nerve- and muscle-sparing approach. (*Plast. Reconstr. Surg.* 151: 169, 2023.)

**CLINICAL QUESTION/LEVEL OF EVIDENCE:** Therapeutic, IV.

According to the latest version of the *International Classification of Headache Disorders*, published in 2018, occipital neuralgia is a neuropathy of the occipital nerves. The diagnostic criteria include unilateral or bilateral stabbing, intense, paroxysmal pain in the distribution of the greater, lesser, and/or third occipital

nerves. Criteria include that the pain can be eased temporarily by local anesthesia blocks of the affected nerves.<sup>1</sup>

Occipital neuralgia can coexist with a wide variety of headache syndromes, and it is considered rather rare (3.2 per 100,000) as an idiopathic, isolated condition.<sup>2</sup> Occipital neuralgia is frequently seen in association with other types of chronic migraines, and it can develop after whiplash injuries and previous operations in the occipital region.<sup>2</sup>

Although occipital neuralgia is well characterized and widely accepted as a disabling neuropathy, no consensus exists on the treatment

From the <sup>1</sup>Division of Aesthetic and Migraine Surgery, Global Medical Institute; and <sup>2</sup>Department of Neurosciences, Division of Plastic Surgery, University of Padua.

Received for publication January 18, 2021; accepted January 13, 2022.

Copyright © 2022 The Authors. Published by Wolters Kluwer Health, Inc. on behalf of the American Society of Plastic Surgeons. All rights reserved. This is an open-access article distributed under the terms of the *Creative Commons Attribution-Non Commercial-No Derivatives License 4.0 (CCBY-NC-ND)*, where it is permissible to download and share the work provided it is properly cited. The work cannot be changed in any way or used commercially without permission from the journal.

DOI: 10.1097/PRS.0000000000009777

**Disclosure:** The authors have no financial interest to declare in relation to the content of this article.

Related digital media are available in the full-text version of the article on [www.PRSJournal.com](http://www.PRSJournal.com).

algorithm among specialists. Therapy is usually started with over-the-counter medications and may require escalation to prescription analgesics, narcotics, and more invasive approaches.<sup>2</sup>

From the review of the scientific literature about the results of invasive options available for occipital neuralgia, surgical decompression seems to be the most effective, with a greater than 80% long-term success rate, as indicated by at least 50% improvement in migraine days, intensity, and duration calculated by the Migraine Headache Index.<sup>3-5</sup>

The two largest case series to date about surgical decompression of the occipital nerves (Ducic et al., who followed 209 patients<sup>3</sup>; and Ascha et al., who followed 176 patients<sup>4</sup>) report 80.5% and 86.2%, respectively, having more than 50% improvement, with a significant 43.5% and 52%, respectively, among those with complete remission.

Several anatomical studies have been published on the occipital nerves, describing the critical compression points along their trajectory.<sup>6-14</sup> Kwon et al.,<sup>15</sup> using Sihler staining, show the anatomical complexity and imbrication between the greater, lesser, and third occipital nerves and the occipital artery. This study shows that main sensitive nerve branches converge in a region described by Janis et al. as points 5 and 6,<sup>6</sup> which is where the greater occipital nerve pierces the nuchal line and intersects the occipital artery. Nerves travel then in a superolateral direction, corresponding to the occipital-temporal trajectory of the pain experienced by most patients with occipital neuralgia.

This area, where nerves are compressed by tendinous and fascial structures, corresponds to one of the most tender points pointed out by patients with occipital neuralgia. Based on all these critical anatomical observations, and the previously described surgical approaches, we here describe the outcome of a modified technique that allows the preservation of nerves and muscle.

## PATIENTS AND METHODS

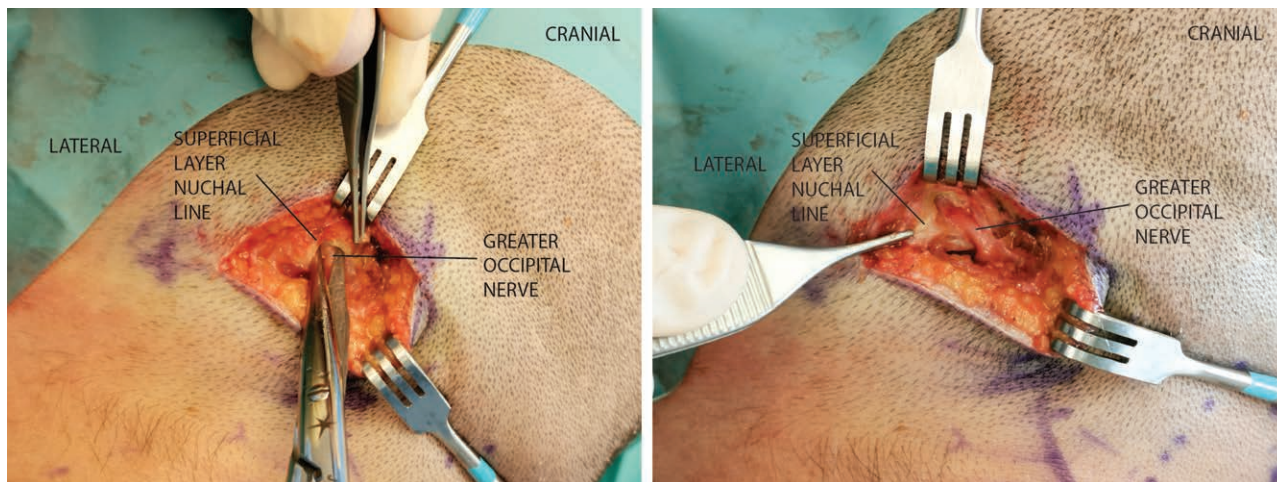
### Selection of the Candidates

Patients were either self-referred, or referred by a neurologist, pain specialist, or general practitioner after failing to respond in a satisfactory manner to abortive and disease-modifying medications for at least 1 year. Diagnosis was confirmed by a constellation of symptoms consistent with occipital neuralgia and selective blocks of the occipital nerves.<sup>16,17</sup> Positive response was considered when symptoms temporarily improved (at least >50% improvement). The block (2.5 cc of

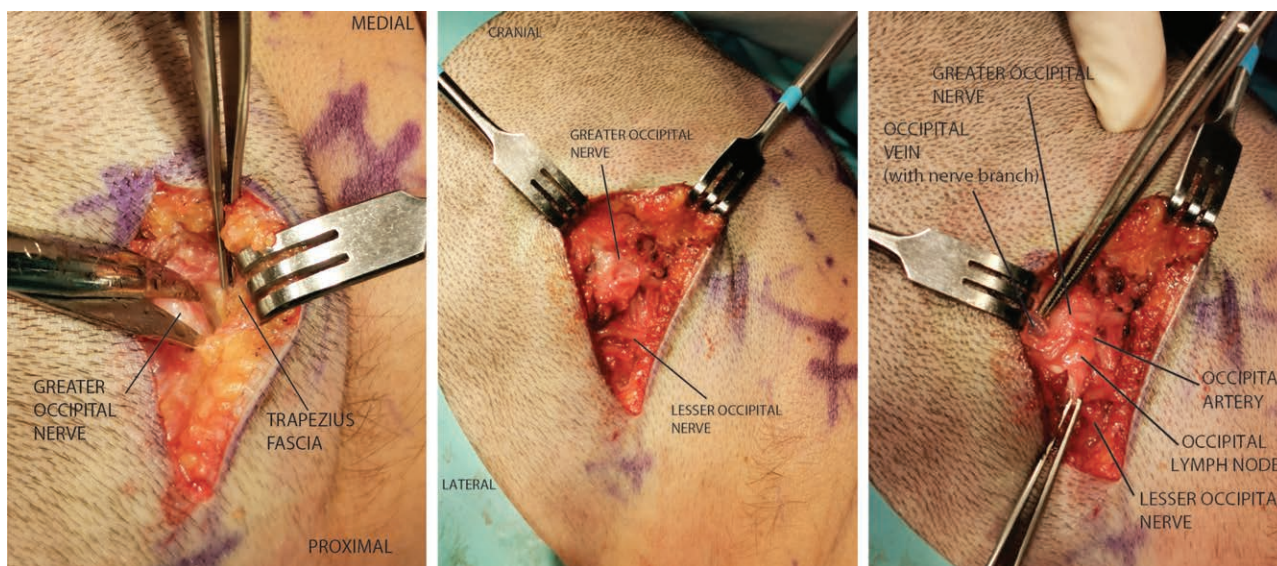
a mixture of 1% lidocaine and 10 mg of triamcinolone) was administered through a 30-gauge needle in the area between the lateral edge of the trapezius and the medial edge of the sternocleidomastoid muscle, just below the nuchal line.

### Surgical Technique

After marking the incision line across the most tender point with the patient sitting upright, the patient is placed in lateral (in case of one-sided occipital neuralgia) or prone (for bilateral occipital neuralgia) position. Local anesthesia is injected (5 cc of lidocaine with epinephrine) along the incision line. An oblique, beveled, 3.5-cm incision is made along the bisector between the nuchal line and the lateral edge of the trapezius a few millimeters caudal to the nuchal line at its most proximal and medial end. Through this access, the common tendinous insertion of the trapezius and sternocleidomastoid muscles at the nuchal line, which usually splits into two layers comprising the nerve fibers, is released (Fig. 1, left) [See Video 1 (online), which demonstrates the release of the nuchal line. The greater and lesser occipital nerves and the occipital artery are exposed. This case demonstrates the same anatomy shown in Fig. 2 and represents the surgical step between Fig. 2, left, and Fig. 2, center.] The occipital nerves often show signs of compression (change in color and caliber) at this level (Fig. 1, right). The more proximal compression points of the greater occipital nerve, such as the passage under the trapezius (trapezius tunnel) and through the semispinalis capitis muscle are visualized and addressed by means of fasciotomies along the course of the nerve fibers (Fig. 2, left). [See Video 2 (online), which demonstrates the proximal release of the greater occipital nerve from the semispinalis capitis fascia. This case demonstrates the same anatomy shown in Fig. 2 and it represents the surgical step between Fig. 2, left, and Fig. 2, center.] The proximal and distal compression points along the lesser occipital nerve are also addressed so that both occipital nerves are released (Fig. 2, center). The greater and lesser occipital nerves are decompressed proximally using a custom-made lighted retractor (Electro Surgical Instrument Company, Rochester, NY, designed by Dr. Robert Hagan, St. Louis). At the end of the procedure the greater and lesser occipital nerve fibers are free from any mechanical compression or tethering points along their course. No muscle fibers are transected, and only fasciotomies in the proximal trapezius (and



**Fig. 1.** (Left) Release of the nuchal line fibrous-tendinous tissues compressing the occipital nerves. (Right) The greater occipital nerve is completely released distally from the superficial layer of the nuchal line (retracted by forceps). Note the change in color and caliber of the nerve at the former compression point and the thickness of the superficial layer of the nuchal line.



**Fig. 2.** (Left) Proximal release of the trapezius fascia above the greater occipital nerve. (Center) The greater and lesser occipital nerves are decompressed. (Right) Decompression of the conflicts with the occipital artery, veins, and lymph nodes.

if needed, the semispinalis capitis) and sternocleidomastoid muscles are performed along the trajectory of the nerves. This access allows for visualization of the main branches of the greater occipital nerve, lesser occipital nerve, their communicating fibers, the occipital artery, and lymph nodes. When occipital artery and lymph nodes are found in contact with the nerves, these structures are gently pushed away (Fig. 2, right). The adventitial and periarterial tissues between the nerve, the lymph nodes, and the artery, rich in afferent and efferent autonomic nervous system fibers, is stripped in all cases.

When a not otherwise addressable conflict is found (such as a branch of the artery passing through the nerve fibers), this segment is divided as described previously.<sup>3</sup> Before closure, nerve blocks are performed using a mixture of 1% lidocaine with epinephrine and 0.5% Chirocaine (AbbVie, Chicago, IL) sprayed directly on the nerves. When the procedure has been chosen to be performed under local anesthesia, the patient is asked to move their head to make sure decompression is complete. The superficialis fascia is repaired with two subcutaneous tissue advancement flaps without tension

closed with 4-0 Monocryl (Ethicon, Inc., a Johnson & Johnson company, Bridgewater, NJ). The soft-tissue flap is raised above the nerve fibers by liberating in the cranial and caudal direction approximately 1 to 2 cm of subcutaneous tissues centered on the superficialis fascia. The flap does not cross any nerve fiber, as it is used as a protection layer from skin during healing. Skin is repaired with 5-0 Monocryl (Ethicon, Inc., Johnson & Johnson). Dressing is made with Opsite Spray (Smith & Nephew, Watford, United Kingdom) and compresses. The procedure takes less than 1 hour.

Twenty-two patients (25.3%) were treated under pure local anesthesia. Twelve patients (13.8%) were treated under local anesthesia and sedation. Most patients ( $n = 32$ ) treated under local anesthesia with or without sedation had monolateral occipital neuralgia. Two patients with bilateral occipital neuralgia were treated under local anesthesia in two separate operations. Patients were asked to manifest any discomfort, so that local anesthesia could be added when needed. No difficulties during dissection were found under local anesthesia and no procedure had to be aborted. General anesthesia was chosen in 53 patients (60.9%) with bilateral occipital neuralgia.

### Outcome Measures

We performed a retrospective review of the charts from 100 consecutive patients treated in our institution for occipital neuralgia. Eighty-seven patients were included. Average age was 45.5 years (range, 20 to 86 years), and the female-to-male ratio was 2.5:1. Thirty-two patients had unilateral occipital neuralgia, and 55 were affected bilaterally. Most of the patients included in this study had some type of previous trauma, such as a whiplash or direct contusion on the occipital region, with preservation of sensation. The trauma may or may not be correlated to the onset or worsening of the symptoms. Those ( $n = 13$ ) with direct nerve injuries, such as postsurgery, postneurectomy, postrhizotomy, and post-occipital neurostimulator implantation patients, with loss of sensation and end-stump neuroma formation, were excluded.

The minimum follow-up time was 12 months (average, 18.5 months). The days with pain per month and the use of drugs per month [divided into abortive or acute (ie, triptans and nonsteroidal anti-inflammatory drugs) and disease-modifying] were noted before and after surgery (at the

time of the last visit). Pain was assessed using a visual analogue scale from 0 to 10, with 0 being absence of pain and 10 being the worst pain imaginable. At follow-up, all patients had to bring their migraine journal, detailing the days, intensity of the crisis and background pain, duration of pain, and type and quantity of drugs used. Preoperative/postoperative levels were compared.

The Migraine Headache Index was measured [days/months with pain  $\times$  intensity (0 to 10)  $\times$  duration (fraction of 24 hours)] and this was compared with the baseline (preoperative) index value.<sup>3,18</sup> The overall improvement in the Migraine Headache Index was quantified from 0% to 100% and classified as follows: 0% to 50%, no significant improvement; 50% to 79%, significant, moderate improvement; 80% to 99%, significant, major improvement; and 100%, complete remission. The analysis of the results was approved by an internal review board. Electronic charts were analyzed by a biostatistician independent of the study.

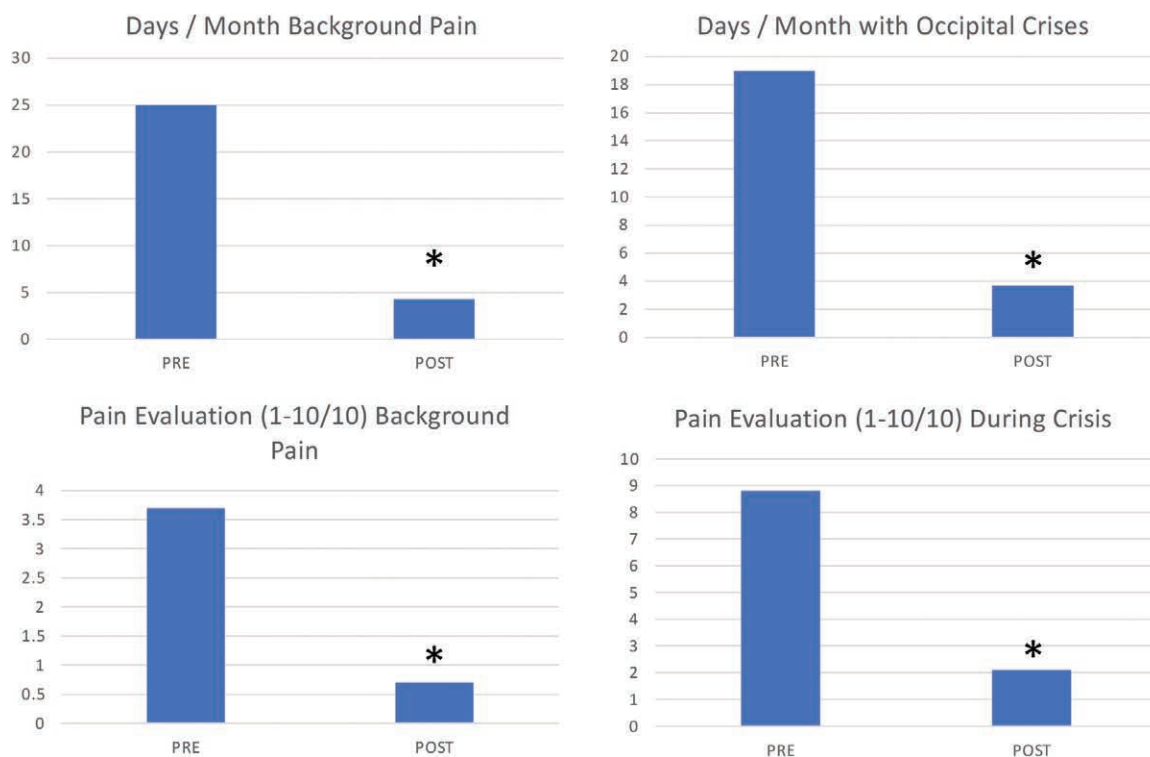
Two-tailed paired  $t$  tests were used to compare days with migraine, intensity of pain, and drug use measured before surgery (baseline) and at the last visit. A value of  $P < 0.05$  was considered significant. Surgical complications were reported.

## RESULTS

First, we quantified whether occipital decompression surgery as described above had an impact on headaches days. Patients with occipital neuralgia typically have chronic background pain and crisis of more intense pain and shorter duration. The chronic pain days decreased from an average of 25 to 4.3 ( $P < 0.01$ ), exhibiting a significant 80.5% reduction (5.8-fold) (Fig. 3, above, left). The pain crisis days per month passed from 19 to 3.7 ( $P < 0.01$ ), corresponding to an 82.8% reduction (5.1-fold) (Fig. 3, above, right).

Second, we evaluated pain intensity. Patients felt on average a background pain intensity of 3.7 of 10, whereas after surgery, the pain decreased to 0.7 of 10 ( $P < 0.01$ ), corresponding to a 76.1% reduction (5.2-fold) (Fig. 3, below, left). Pain intensity peaks during crises passed from 8.8 of 10 to 2.1 of 10 after surgery ( $P < 0.01$ ), corresponding to a significant reduction by 81.1% (4.2-fold) (Fig. 3, below, right).

The decrease in headache days and intensity mirrored the decreased drug use. The use of nonsteroidal anti-inflammatory drugs decreased from 25.3 to 7.7 pills per month (main drug used ibuprofen and equivalents, 69.7% reduction, 3.3-fold,  $P < 0.01$ , not shown). Patients with occipital



**Fig. 3.** (Above, left) After a minimum follow-up of 12 months, we observed a 5.8-fold decrease in days per month with background chronic pain, corresponding to an 80.5% improvement. (Above, right) the days with pain crisis per month decreased 5.1-fold, corresponding to an improvement of 82.8%. (Below, left) Average chronic, background pain intensity decreased after surgery 5.2-fold, corresponding to a 76.1% improvement. (Below, right) Pain intensity peaks during crises decreased 4.2-fold, corresponding to an 81.1% improvement (\* $P < 0.01$ ).

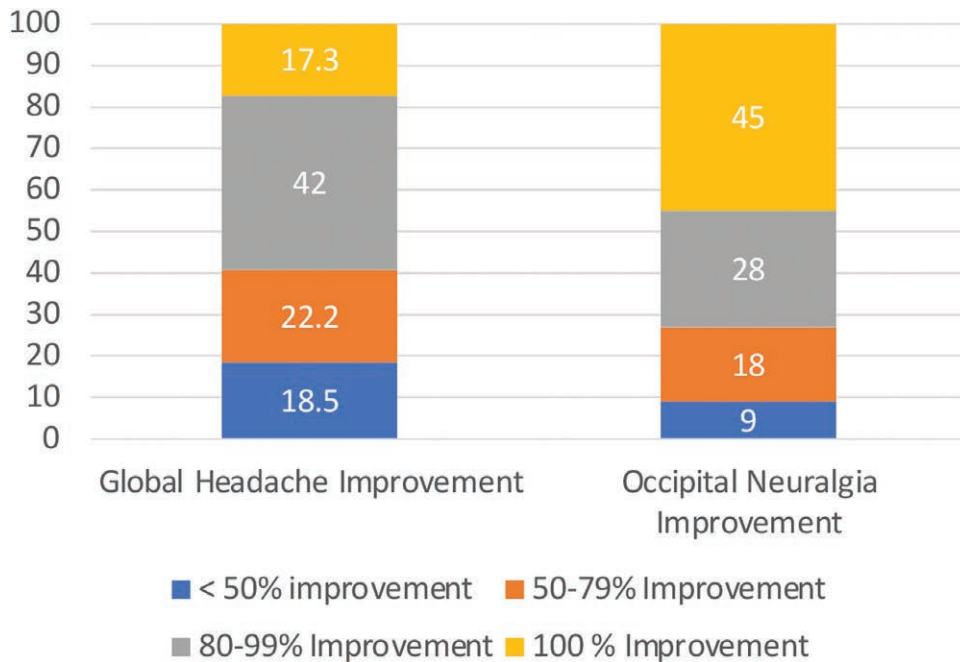
neuralgia may have other forms of headaches such as chronic migraines. These patients most often use triptans to improve their global pain. The use of triptans among our patient population decreased from 14 pills per month to 2.7 pills per month ( $P < 0.01$ ) (80.6% reduction, 5.2-fold, not shown). Patients are also often given disease-modifying drugs (including antiepileptics, antidepressants, beta-blockers, and anti-calcitonin gene-related peptide antibodies to decrease the general burden of the headaches). Fifteen of the 46 patients using disease-modifying drugs could stop 1 year after surgery, and among the other 31 patients, 15 could reduce the doses by more than 50% (not shown). Seven of 87 patients were on morphine derivatives before surgery, of which five could completely stop and two could reduce more than 50% the intake after surgery (not shown).

The overall improvement in Migraine Headache Index after surgery was divided into global and occipital. Global is the general evaluation of patients with other triggers or types of headaches in addition to occipital neuralgia. The analysis of the global improvement showed

81.5% of patients exhibiting more than 50% improvement, with 17.3% of patients exhibiting complete remission of all headaches, 42% of the patients showing 80% to 99% improvement, and 22.2% showing 50% to 79% improvement. 18.5% of patients did not show any significant global improvement. No patients reported a worsening of the symptoms (Fig. 4, left).

The impact on occipital pain relief was higher than the global improvement. The significant occipital pain improvement was 91%, with 45% of patients showing a complete remission of occipital symptoms; 28% showing significant, major improvement; and 18% showing significant, moderate improvement. Nine percent of the patients did not show any improvement. No patients reported a worsening of the symptoms (Fig. 4, right).

Only minor complications occurred. Four patients required postsurgery scar revision, all under local anesthesia. One patient had partial wound dehiscence, probably because of reaction to resorbable suture; and three patients developed pain around the surgical incision, probably because of excessive scarring.



**Fig. 4.** (Left) The Migraine Headache Index was used as a measure of occipital and global relief. The analysis of the global improvement (taking into consideration other forms of headaches in the same patients other than occipital neuralgia) showed 81.5% of patients exhibiting more than 50% improvement, with 17.3% of patients having complete remission of all headaches, and 42% of the patients showing 80% to 99% improvement; 18.5% of patients did not show any significant improvement. No patients reported a worsening of the symptoms. (Right) Ninety-one percent of patients had significant occipital pain relief, with 45% of patients showing a complete remission of occipital symptoms and 28% showing improvement between 80% and 99%. Nine percent of the patients did not show any occipital pain improvement. No patients reported a worsening of the symptoms.

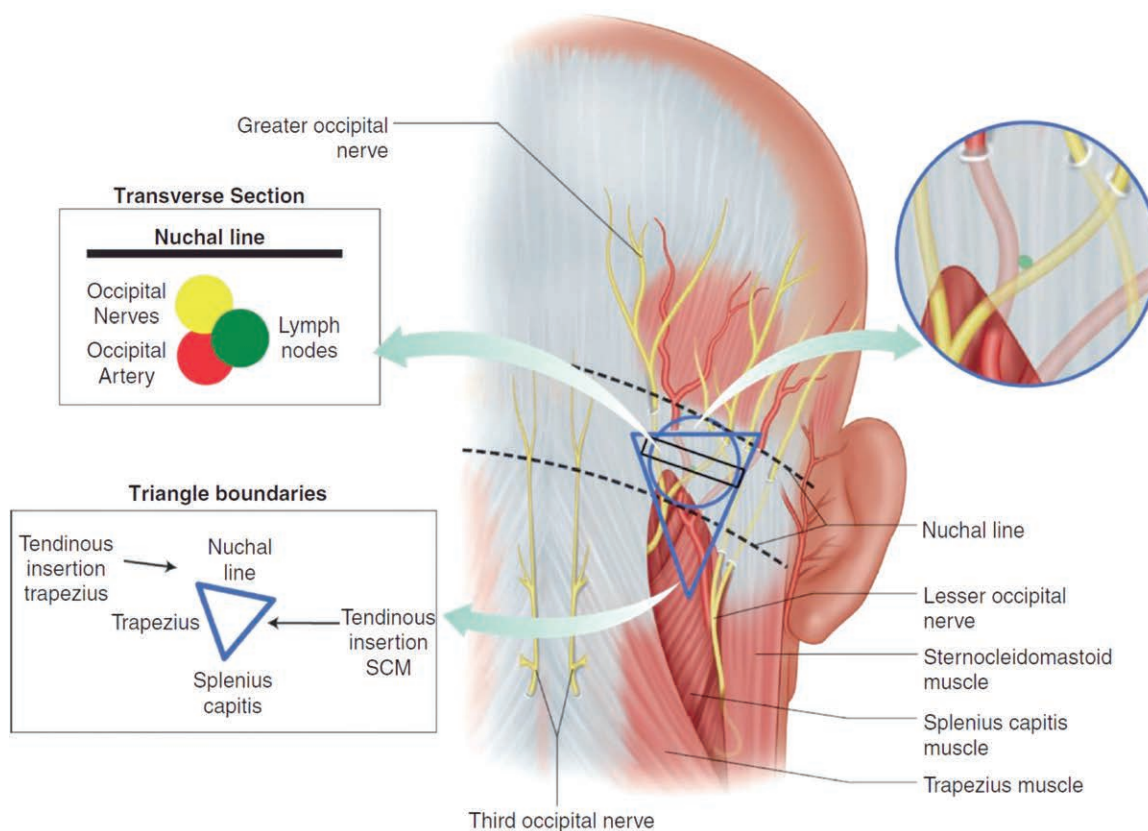
## DISCUSSION

We describe here a minimally invasive approach to decompress the greater and lesser occipital nerves to improve occipital neuralgia. Results from this nerve- and muscle-sparing approach show significant improvement in headache days, pain intensity, use of drugs, and overall occipital headache burden in more than 90% of the patients, with 45% presenting a complete remission, at a minimum follow-up of 12 months. Although results resemble previously reported ones, this technique does not require general anesthesia and offers the advantage of being muscle and nerve sparing and thus is less invasive compared with other approaches.

We observed that most patients with occipital neuralgia can point with one fingertip to the pit between the trapezius and the sternocleidomastoid muscles to indicate the origin of pain.<sup>19</sup> We define this zone as the occipital triangle, where the greater and lesser occipital nerve neurovascular bundle is compressed by fascial and tendinous structures and directly accessible.<sup>19</sup> The

triangle is located between the nuchal line superiorly; the proximal lateral border of the trapezius muscle medially; and laterally, the proximal medial border of the sternocleidomastoid muscle (Fig. 5).<sup>20</sup>

The described technique primarily addresses the conflicts between the tendinous insertion of the neck muscles and their fascia with the occipital nerves. Nerve and muscular structures are spared while releasing the mechanical component of the disease that is untreatable by physical or pharmacologic approaches (including botulinum toxin type A). A recent publication from Gfrerer et al. shows chronic inflammation and fibrotic and thickened trapezius fascia (approximately 3 mm thick) at this level in 94% of the cases, as opposed to normal semispinalis capitis muscle found in all operated patients with occipital neuralgia.<sup>21</sup> This observation and the results from the technique described here support the hypothesis that fascial structures play a significant role in the mechanical cause of this disease. The release of the nuchal



**Fig. 5.** The anatomy of the occipital triangle, the greater and lesser occipital nerves, occipital artery (and veins), and lymph nodes can be accessed in an area between the proximal edge of the trapezius medially, the nuchal line proximally, and the sternocleidomastoid muscle laterally. (Reproduced with permission from Pietramaggiore G, Thierrin L, Scherer S. Surgical anatomy and diagnosis of peripheral nerve compression and injury. In: Pietramaggiore G, Scherer S, eds. *Minimally Invasive Surgery for Chronic Pain Management: An Evidence-Based Approach*. Cham, Switzerland: Springer; 2020.)

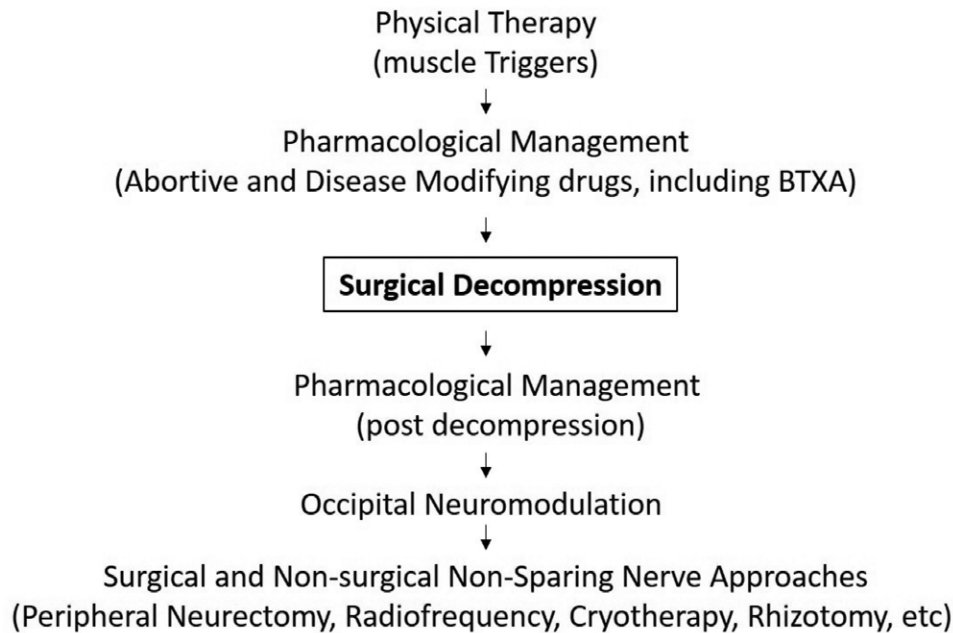
line represents an extension of compression point 5 described by Janis et al. as the point where the nerve pierces the trapezius fascia at its insertion into the nuchal line.<sup>6</sup> Sometimes, the course of the greater and lesser occipital nerves below the nuchal line is several millimeters long, requiring release beyond the trapezius tunnel. We define here for completeness as point 5a the release of the nuchal line along the greater and/or lesser occipital nerve fibers distal to the trapezius tunnel.

Compression and neuropathy of the greater and lesser occipital nerve are considered responsible for most of the occipital neuralgia symptoms. Two main surgical approaches have been described to decompress the occipital nerves: the midline approach as described by Guyuron et al.<sup>4,16</sup> and the transverse approach originally described by Ducic et al.<sup>3</sup> Although the vertical approach requires two additional incisions to address the lesser occipital nerve when indicated, the transverse approach allows for

decompression of both occipital nerves through one incision.

The described technique represents a further development of the transverse approach described by Ducic et al.<sup>3</sup> with the following differences: (1) the incision is oblique instead of transverse and more cranial (a few millimeters caudal to the nuchal line instead of 3 cm below) directly exposing compression points 5 and 6; (2) the oblique incision is shorter, 3.5 cm instead of 5 to 6 cm or several centimeters in the variant described by Afifi et al.,<sup>22</sup> maximally preserving lymphatic drainage and sensitive nerve endings; (3) both the greater and lesser occipital nerves are explored and decompressed, and no nerve or muscle fibers are transected; (4) only fasciotomies (of the trapezius and semispinalis muscles) along the trajectory of the nerve fibers are performed, and the semispinalis muscle is entirely preserved; and (5) no rectangular fat flaps and only advancement subcutaneous flaps are raised,

Confirmed Occipital Neuralgia diagnosis  
International Classification of Headache Disorders (ICHD 3, 2018)



**Fig. 6.** The proposed algorithm for treatment of occipital neuralgia. After failure of noninvasive physical and pharmacologic approaches, a nerve- and muscle-preserving decompression can be attempted. In case of nonsignificant (<50%) improvement after decompression surgery, pharmacologic approaches may become effective. In the absence of satisfactory response from medications, a neurostimulator may be tested. Only after failure of the neurostimulator should more invasive and nerve destructive methods eventually be used, with the added risk to generate neurogenic, neuroma-type pain, which may further complicate pain management.

with overall less secondary tissue injury and dead space creation.

Although nerve-preserving decompression is chosen by most authors to address greater occipital nerve neuralgia at least as the first option, the surgical approach for lesser occipital nerve neuralgia ranges from nerve-conserving decompression techniques<sup>14</sup> to resection of the lesser occipital nerve.<sup>3</sup> The third occipital nerve, of which the role in occipital neuralgia is still debated, is primarily treated by transection or avulsion.<sup>23</sup> In our practice, no nerves are transected unless proven to be already irreversibly injured, including the third occipital nerve.

Results from this study and others reported in the literature exhibit over 80% positive to excellent outcome<sup>3,18</sup> and only minor complications from surgical decompression of the occipital nerves. Because occipital decompression has shown superiority to other invasive approaches (eg, radiofrequency, phenolization, cryotherapy, implantation of an occipital neurostimulator, and

rhizotomy), it should be considered where available before less effective and more destructive methods, which also have higher rates of complications.<sup>5,24–26</sup> We hope that this study, focused on a minimally invasive, nerve- and muscle-preserving technique, will help support this algorithm across medical specialties taking care of patients with occipital neuralgia (Fig. 6).

## SUMMARY

This article describes a safe and cost-effective surgical technique to address occipital neuralgia. The technique spares the nerve and muscular structures with outcomes comparable to the previously, more invasive approaches. Through a single incision, both of the main occipital nerves (greater and lesser occipital nerves), the occipital artery, and the occipital lymph nodes can be visualized. The nerves can be decompressed proximally and distally, addressing all the previously described compression points under local



anesthesia, without partial muscle excisions or excessive subcutaneous flaps, decreasing the procedure time and costs and accelerating the recovery.

**Giorgio Pietramaggiore, MD, PhD**

Division of Aesthetic and Migraine Surgery  
Global Medical Institute  
Avenue Jomini 8  
1004 Lausanne, Switzerland  
dr.pietramaggiore@global.surgery

### REFERENCES

- Headache Classification Committee of the International Headache Society (IHS). The International Classification of Headache Disorders, 3rd edition. *Cephalalgia* 2018;38:1–211.
- Choi I, Jeon SR. Neuralgias of the head: occipital neuralgia. *J Korean Med Sci*. 2016;31:479–488.
- Ducic I, Hartmann EC, Larson EE. Indications and outcomes for surgical treatment of patients with chronic migraine headaches caused by occipital neuralgia. *Plast Reconstr Surg*. 2009;123:1453–1461.
- Ascha M, Kurlander DE, Sattar A, Gatherwright J, Guyuron B. In-depth review of symptoms, triggers, and treatment of occipital migraine headaches (site IV). *Plast Reconstr Surg*. 2017;139:1333e–1342e.
- Ducic I, Felder JM III, Fantus SA. A systematic review of peripheral nerve interventional treatments for chronic headaches. *Ann Plast Surg*. 2014;72:439–445.
- Janis JE, Hatf DA, Ducic I, et al. The anatomy of the greater occipital nerve: Part II. Compression point topography. *Plast Reconstr Surg*. 2010;126:1563–1572.
- Scherer SS, Schiraldi L, Sapino G, et al. The greater occipital nerve and obliquus capitis inferior muscle: anatomical interactions and implications for occipital pain syndromes. *Plast Reconstr Surg*. 2019;144:730–736.
- Mosser SW, Guyuron B, Janis JE, Rohrich RJ. The anatomy of the greater occipital nerve: implications for the etiology of migraine headaches. *Plast Reconstr Surg*. 2004;113:693–697; discussion 698–700.
- Janis JE, Hatf DA, Reece EM, McCluskey PD, Schaub TA, Guyuron B. Neurovascular compression of the greater occipital nerve: implications for migraine headaches. *Plast Reconstr Surg*. 2010;126:1996–2001.
- Ducic I, Moriarty M, Al-Attar A. Anatomical variations of the occipital nerves: implications for the treatment of chronic headaches. *Plast Reconstr Surg* 2009;123:859–863.
- Junewicz A, Katira K, Guyuron B. Intraoperative anatomical variations during greater occipital nerve decompression. *J Plast Reconstr Aesthet Surg*. 2013;66:1340–1345.
- Dash KS, Janis JE, Guyuron B. The lesser and third occipital nerves and migraine headaches. *Plast Reconstr Surg*. 2005;115:1752–1758; discussion 1759–1760.
- Lee M, Brown M, Chepla K, et al. An anatomical study of the lesser occipital nerve and its potential compression points: implications for surgical treatment of migraine headaches. *Plast Reconstr Surg*. 2013;132:1551–1556.
- Peled ZM, Pietramaggiore G, Scherer S. Anatomic and compression topography of the lesser occipital nerve. *Plast Reconstr Surg Glob Open* 2016;4:e639.
- Kwon HJ, Kim HS, O J, et al. Anatomical analysis of the distribution patterns of occipital cutaneous nerves and the clinical implications for pain management. *J Pain Res*. 2018;11:2023–2031.
- Guyuron B, Kriegler JS, Davis J, Amini SB. Comprehensive surgical treatment of migraine headaches. *Plast Reconstr Surg*. 2005;115:1–9.
- Guyuron B, Nahabet E, Khansa I, Reed D, Janis JE. The current means for detection of migraine headache trigger sites. *Plast Reconstr Surg*. 2015;136:860–867.
- Guyuron B, Kriegler JS, Davis J, Amini SB. Five-year outcome of surgical treatment of migraine headaches. *Plast Reconstr Surg*. 2011;127:603–608.
- Pietramaggiore G, Scherer S. *Minimally Invasive Surgery for Chronic Pain Management: An Evidence-Based Approach*. Cham, Switzerland: Springer; 2020.
- Pietramaggiore G, Thierrin L, Scherer S. Surgical anatomy and diagnosis of peripheral nerve compression and injury. In: Pietramaggiore G, Scherer S, eds. *Minimally Invasive Surgery for Chronic Pain Management: An Evidence-Based Approach*. Cham, Switzerland: Springer; 2020:1–14.
- Gfrerer L, Hansdorfer MA, Ortiz R, Chartier C, Nealon KP, Austen WG Jr. Muscle fascia changes in patients with occipital neuralgia, headache, or migraine. *Plast Reconstr Surg*. 2021;147:176–180.
- Afifi AM, Carbullido MK, Israel JS, Sanchez RJ, Albano NJ. Alternative approach for occipital headache surgery: the use of a transverse incision and “W” flaps. *Plast Reconstr Surg Glob Open* 2019;7:e2176.
- Lee M, Lineberry K, Reed D, Guyuron B. The role of the third occipital nerve in surgical treatment of occipital migraine headaches. *J Plast Reconstr Aesthet Surg*. 2013;66:1335–1339.
- Gande AV, Chivukula S, Moosy JJ, et al. Long-term outcomes of intradural cervical dorsal root rhizotomy for refractory occipital neuralgia. *J Neurosurg*. 2016;125:102–110.
- Martelletti P, Jensen RH, Antal A, et al; European Headache Federation. Neuromodulation of chronic headaches: position statement from the European Headache Federation. *J Headache Pain* 2013;14:86.
- Palmisani S, Al-Kaisy A, Arcioni R, et al. A six year retrospective review of occipital nerve stimulation practice: controversies and challenges of an emerging technique for treating refractory headache syndromes. *J Headache Pain* 2013;14:67.