

Transforaminal Ligaments of the Lumbar Spine: A Comprehensive Review

Randle Umeh¹, Christian Fisahn², Brittnei Burgess³, Joe Iwanaga³, Marc Moisi⁴, Rod J. Oskouian⁵, R. Shane Tubbs⁴

1. Department of Anatomical Sciences, St. George's University School of Medicine, Grenada, West Indies
2. Orthopedic Surgery, Swedish Neuroscience Institute 3. Seattle Science Foundation 4. Neurosurgery, Seattle Science Foundation 5. Neurosurgery, Complex Spine, Swedish Neuroscience Institute

✉ **Corresponding author:** Christian Fisahn, christian.fisahn@swedish.org
Disclosures can be found in Additional Information at the end of the article

Abstract

Once considered anomalous structures, transforaminal ligaments are not widely known and the criteria for identifying and classifying them are not universal. They are, however, of potential importance during neurological procedures, as their entrapment might lead to radicular pain.

Transforaminal ligaments are not present in all patients, but when they are, the incidence of all types of ligaments is significantly higher, with the most common type being the superior corporotransverse ligament. By diminishing the overall amount of space available for the spinal nerve to pass, many early studies concluded that transforaminal ligaments were the cause of nerve root entrapment, resulting in radicular pain. However, more recent studies conducted have claimed that the ligaments do not cause radicular pain but rather are more for the protection of nerves and vessels.

The contribution of transforaminal ligaments to radicular pain is still a topic of debate, but their role in the protection of nerves and vessels is certain. The clinician who performs interventional procedures directed toward the intervertebral foramen and the surgeon operating in this region should have a good working knowledge of the anatomy and proposed functions of the transforaminal ligaments.

Categories: Neurosurgery, Orthopedics

Keywords: review, transforaminal ligaments, spine, radicular pain

Introduction And Background

Once considered anomalous structures, transforaminal ligaments are not widely known and the criteria for identifying and classifying them are not universal. There are five major classifications of transforaminal ligaments: the superior and inferior corporotransverse ligaments, the superior and inferior transforaminal ligaments, and the mid-transforaminal ligament [1-3]. Each type is of importance during surgery near the intervertebral foramen, as inadvertent traction on these structures might lead to radicular pain. Having a comprehensive understanding of the transforaminal ligaments could help better localize a patient's source of radicular pain.

Review

The intervertebral foramina allow for the passage of numerous structures, including the root of

Received 08/31/2016
Review began 09/13/2016
Review ended 09/26/2016
Published 10/02/2016

© Copyright 2016

Umeh et al. This is an open access article distributed under the terms of the Creative Commons Attribution License CC-BY 3.0., which permits unrestricted use, distribution, and reproduction in any medium, provided the original author and source are credited.

How to cite this article

Umeh R, Fisahn C, Burgess B, et al. (October 02, 2016) Transforaminal Ligaments of the Lumbar Spine: A Comprehensive Review. Cureus 8(10): e811. DOI 10.7759/cureus.811

each spinal nerve, segmental spinal arteries and veins, lymphatics, and recurrent meningeal nerves [2, 4] (Figure 1).

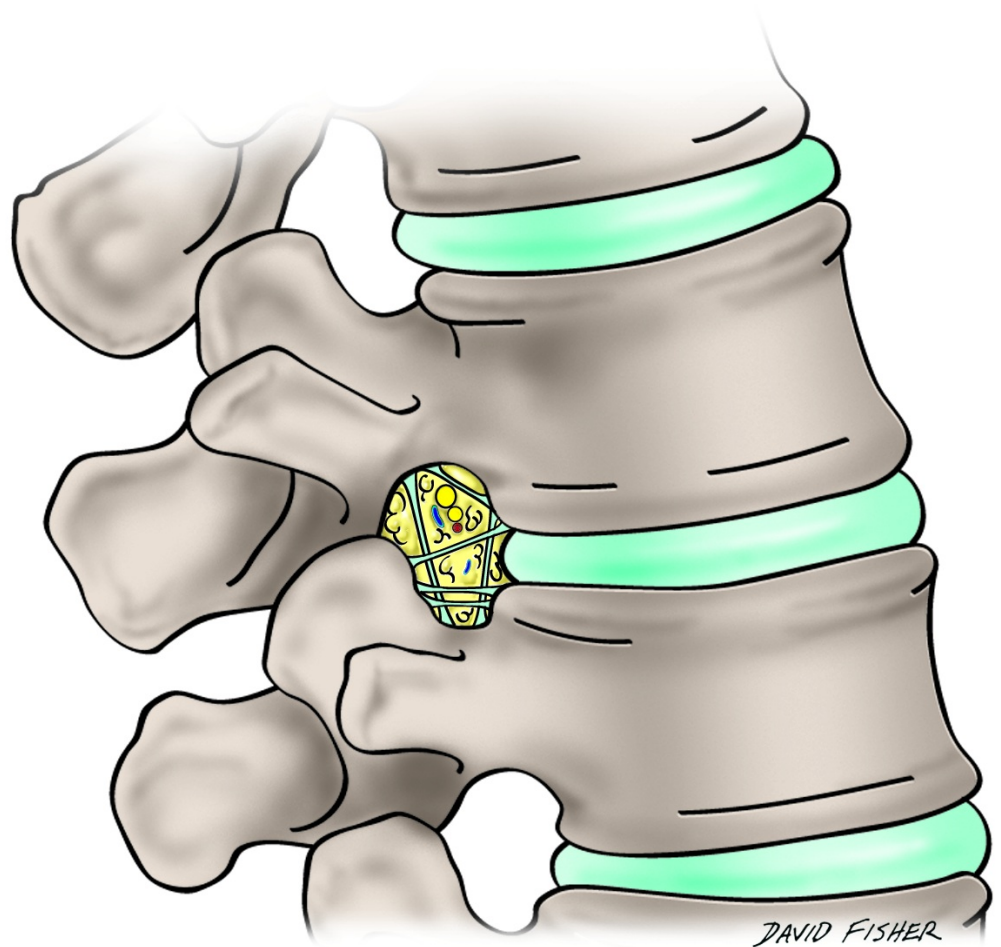


FIGURE 1: Schematic drawing of the varieties of transforaminal ligaments in the lumbar intervertebral foramen.

Two broad varieties of ligaments have been found in association with the intervertebral foramina: radiating and transforaminal ligaments [5]. The latter pass through the foramina and are of particular interest as they might contribute to neurovascular compression or exacerbate intervertebral foramen stenosis.

Within the boundary of each intervertebral foramen is a network of ligaments dividing the outlet into multiple subcompartments that contain their own specific anatomical structures [2]. In 1832, the French physician and anatomist, Jean-Baptiste Marc Bougery, illustrated these ligaments as traversing the intervertebral foramen [2]. These ligamentous bands were also noted in the works of Larmon and Magnuson as spanning the intervertebral foramen of the L5 segment [6-7]. However, it was Golub and Silverman [3] in 1969 who reported the presence of ligamentous bands traversing the foramina at all lumbar levels in 10 cadaveric lumbar spines (Figure 2).

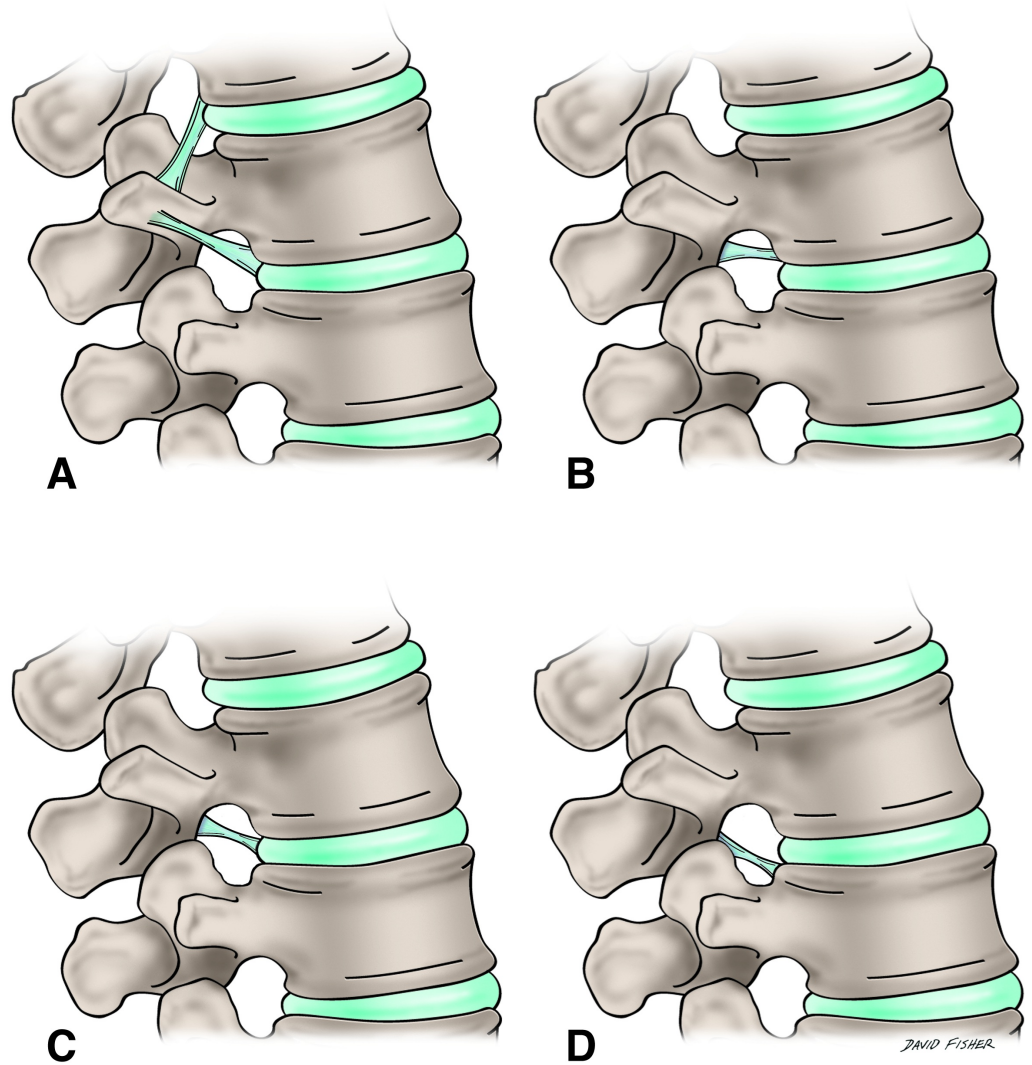


FIGURE 2: The various transforaminal ligaments as described by Golub and Silverman in 1969.

Upon examination of these 10 cadaveric lumbar spines, Golub and Silverman [3] reported that nine of them showed ligamentous bands crossing the intervertebral foramina but that these bands were not seen at all levels or on both sides of the spine. They concluded that the ligaments are not always present in the lumbar spine, but when they are present, they are commonly found at L1-L2 [1, 8-9]. Bachop and Hilgendorf [1] and others supported the findings of Golub and Silverman [3] but emphasized that the ligaments were more commonly found at the level of the fifth lumbar foramen [8].

The transforaminal (intervertebral foraminal) ligaments are not widely known and were once considered anomalous structures after they had been described in the anatomical study by Golub and Silverman [8-10]. However, further, more detailed studies indicated that they were normal anatomical, rather than pathological, structures [8-10]. Min et al. found transforaminal ligaments in approximately 70-90% of human lumbar foramina [5, 10-11], although the percentage reported in the literature ranges from 17.8 to 100% since the actual criteria for identifying and classifying the transforaminal ligaments differ among studies [12].

In their pioneering study on these ligaments in 1969, Golub and Silverman [3] described the transforaminal ligaments as condensations in the fascia that overlie the exits of the intervertebral foramina and that they have ligamentous features. Besides resembling condensations of fascia more than ligaments, these structures are also less ligament-like because, with one exception, they do not connect separate bones [1-2]. The five major types of transforaminal ligaments were identified in relation to their attachments and direction [2, 11]. The obliquely running bands were designated as the superior and inferior corporotransverse ligaments while those that ran transversely were named the transforaminal ligaments [9].

The two corporotransverse ligaments are mostly distributed in the L5-S1 intervertebral foramen: the superior corporotransverse ligament attaches from the posterolateral corner of the vertebral body to the accessory process of the transverse process of the same vertebra; the inferior corporotransverse ligament connects the same posterolateral corner of a vertebral body to the transverse process below [13]. The transforaminal ligaments are more superior in the L1-L4 intervertebral foramina [13], the superior transforaminal ligaments attaching to the inferior vertebral notches, and the inferior to the superior vertebral notches; the mid-transforaminal ligaments traverse from the posterolateral corner of an annulus fibrosus to the ligamentum flavum behind and the zygapophysial joint capsule.

It must be emphasized that transforaminal ligaments are not always present, but when they are, the overall incidence of all types of these ligaments is approximately 47% [2]. The most common type is the superior corporotransverse ligament at 27% and the only ligament type of connecting separate bones is the inferior corporotransverse ligament [2].

The anatomical location of the transforaminal ligaments led many early studies to conclude that these condensations of fascia were the cause of nerve root entrapment resulting in radicular pain since they diminished the space available for the spinal nerve to pass [2, 5, 8-10, 12]. It has been reported that the cross-sectional area of a foramen is decreased by as much as 30% by these bands of fascia [5, 10, 12]. However, Kuofi, et al. [8] mapped the ligaments topographically, establishing their consistent presence in the foramina, and concluded, in contradiction to earlier studies, that they did not cause nerve root entrapment leading to radicular pain. Rather, they were more protective of nerves and vessels [2, 13]. Clearly, further investigation into these structures is warranted.

Conclusions

This was a comprehensive literature review conducted on the transforaminal ligaments regarding their anatomy and function. Although there have been limited studies of their form and function, the transforaminal ligaments are believed by some to be protective of nerves and vessels traversing the intervertebral foramen while being the cause of radicular pain is still a matter of debate.

Additional Information

Disclosures

Conflicts of interest: In compliance with the ICMJE uniform disclosure form, all authors declare the following: **Payment/services info:** All authors have declared that no financial support was received from any organization for the submitted work. **Financial relationships:** All authors have declared that they have no financial relationships at present or within the previous three years with any organizations that might have an interest in the submitted work. **Other relationships:** All authors have declared that there are no other relationships or activities that could appear to have influenced the submitted work.

References

1. Bakkum BW, Mestan M: The effects of transforaminal ligaments on the sizes of T11 to L5 human intervertebral foramina. *J Manipulative Physiol Ther.* 1994, 17:517–22.
2. Gilchrist RV, Slipman CW, Bhagia SM: Anatomy of the intervertebral foramen. *Pain Physician.* 2002, 5:372–78.
3. Golub BS, Silverman B: Transforaminal ligaments of the lumbar spine. *J Bone Joint Surg Am.* 1969, 51:947–56.
4. Hadley LA: Constriction of the intervertebral foramen; a cause of nerve root pressure. *J Am Med Assoc.* 1949, 140:473–76. [10.1001/jama.1949.02900400027006](https://doi.org/10.1001/jama.1949.02900400027006)
5. Zhao Q, Zhong E, Shi B, Li Y, Sun C, Ding Z: The morphology and clinical significance of the intraforaminal ligaments at the L5-S1 levels. *Spine J.* 2016, 16:1001–1006.
6. Larmon WA: An anatomic study of the lumbosacral region in relation to low back pain and sciatica. *Ann Surg.* 1944, 119:892–96. [10.1097/0000658-194406000-00009](https://doi.org/10.1097/0000658-194406000-00009)
7. Magnuson PB: Differential diagnosis of causes of pain in the lower back accompanied by sciatic pain. *Ann Surg.* 1944, 119:878–91. [10.1097/0000658-194406000-00008](https://doi.org/10.1097/0000658-194406000-00008)
8. Amonoo-Kuofi HS, el-Badawi MG, Fatani JA: Ligaments associated with lumbar intervertebral foramina. 1. L1 to L4. *J Anat.* 1988, 156:177–83.
9. Amonoo-Kuofi HS, el-Badawi MG, Fatani JA, Butt MM: Ligaments associated with lumbar intervertebral foramina. 2. The fifth lumbar level. *J Anat.* 1988, 159:1–10.
10. Min JH, Kang SH, Lee JB, Cho TH, Suh JG: Anatomic analysis of the transforaminal ligament in the lumbar intervertebral foramen. *Neurosurgery.* 2005, 57:37–41. [10.1227/01.NEU.0000163481.58673.1A](https://doi.org/10.1227/01.NEU.0000163481.58673.1A)
11. Qian Y, Qin A, Zheng MH: Transforaminal ligament may play a role in lumbar nerve root compression of foraminal stenosis. *Med Hypotheses.* 2011, 77:1148–49. [10.1016/j.mehy.2011.09.025](https://doi.org/10.1016/j.mehy.2011.09.025)
12. Marić DL, Krstonošić B, Erić M, Marić DM, Stanković M, Milošević NT: An anatomical study of the lumbar external foraminal ligaments: appearance at MR imaging. *Surg Radiol Anat.* 2015, 37:87–91. [10.1007/s00276-014-1320-8](https://doi.org/10.1007/s00276-014-1320-8)
13. Yuan SG, Wen YL, Zhang P, Li YK: Ligament, nerve, and blood vessel anatomy of the lateral zone of the lumbar intervertebral foramina. *Int Orthop.* 2015, 39:2135–41. [10.1007/s00264-015-2831-6](https://doi.org/10.1007/s00264-015-2831-6)