



Since January 2020 Elsevier has created a COVID-19 resource centre with free information in English and Mandarin on the novel coronavirus COVID-19. The COVID-19 resource centre is hosted on Elsevier Connect, the company's public news and information website.

Elsevier hereby grants permission to make all its COVID-19-related research that is available on the COVID-19 resource centre - including this research content - immediately available in PubMed Central and other publicly funded repositories, such as the WHO COVID database with rights for unrestricted research re-use and analyses in any form or by any means with acknowledgement of the original source. These permissions are granted for free by Elsevier for as long as the COVID-19 resource centre remains active.



Contents lists available at ScienceDirect

Journal of Equine Veterinary Science

journal homepage: www.j-evs.com

Review Article

Donkey Internal Medicine—Part II: Cardiovascular, Respiratory, Neurologic, Urinary, Ophthalmic, Dermatology, and Musculoskeletal Disorders

Francisco J. Mendoza ^{a,*}, Ramiro E. Toribio ^b, Alejandro Perez-Ecija ^a^a Departamento de Medicina y Cirugía Animal, Universidad de Córdoba, Campus Rabanales, Córdoba, Spain^b Department of Veterinary Clinical Sciences, The Ohio State University, Columbus, OH

ARTICLE INFO

Article history:

Received 11 December 2017

Received in revised form

14 February 2018

Accepted 15 February 2018

Available online 27 February 2018

Keywords:

Asinine herpesvirus
 Atrioventricular block
 Interstitial pneumonia
 Laminitis
 Sarcoid
 Urolithiasis

ABSTRACT

Cardiovascular diseases are scarcely reported in donkeys, probably linked to their limited athletic attitude and low frequency of poor performance-related examinations. Reports on treatments for cardiovascular pathologies are anecdotal in donkeys. Respiratory tract anatomy shows important differences between horses and donkeys. Donkeys and mules can act as reservoirs spreading many viral, bacterial, and parasitic infectious respiratory diseases. Mosquito and tick-borne encephalitis have been reported in these species in the later years, and even donkeys are being used as sentinels in some areas to detect these emerging diseases. Management and treatment of lithiases can be transferable from horses; however, the same assumption must still be demonstrated for acute and chronic renal diseases. Ocular pathologies are similar to horses, with corneal ulcers frequently observed. Lameness is a common problem in donkeys, with laminitis as the most reported cause followed by pedal abscess.

© 2018 Elsevier Inc. All rights reserved.

1. Introduction

Nowadays, donkeys are of high interest, both for clinicians and owners due to their inner working abilities and also as companion animals. Therefore, an increased awareness for the well-being and care of these animals and a demand of specialized veterinary services have been observed in recent years. Numerous differences have been reported between donkeys and horses; therefore, extrapolate clinical data, treatment, and diagnostic protocols from horses to donkeys could lead to misdiagnosis and unnecessary or inadequate treatments [1–5].

In this review, we provide information on unique donkey characteristics that are relevant to several equine medical specialties, contrasting differences with other equids.

2. Cardiovascular System

Cardiovascular diseases can be observed in donkeys, presumably with a similar prevalence to horses. Because available information concerning these conditions is scarce in this species, clinicians tend to think that they are rare. Nonetheless, it is important to remember that a great proportion of cardiovascular diseases are found in horses during examinations due to poor performance. Considering that donkeys are not commonly used as riding animals and their limited athletic attitude, these diseases could easily be underdiagnosed [6].

Electrocardiographic parameters have been published for healthy donkeys [7–9]. Care must be taken when performing this test in donkeys because the wide range of sizes in different donkey breeds could result in broad variations in certain reference parameters. When compared with horses, donkeys' electrocardiogram usually shows a shorter P wave in lead II, most probably due to higher heart rates; more pronounced positive waves in QRS complexes and different QRS vectors, which could be related to a different cardiac size or heart location inside the thorax. Those findings have been described only for certain breeds and using a limited number of animals, which should always be considered by clinicians.

Animal welfare/ethical statement: It is not applicable for this review.

Conflict of interest statement: None of the authors has any financial or personal relationships that could inappropriately influence or bias the content of the article.

* Corresponding author at: Dr Francisco J. Mendoza, Department Animal Medicine and Surgery, University of Córdoba, Córdoba 14014, Spain.

E-mail address: fjmendoza@uco.es (F.J. Mendoza).

<https://doi.org/10.1016/j.jevs.2018.02.025>

0737-0806/© 2018 Elsevier Inc. All rights reserved.

Normal echocardiographic parameters have also been reported in healthy donkeys [10–12]. Amory et al [10] described normal values of echocardiographic dimensions and functional indexes, as well as quantitative reference values for Doppler flow in healthy donkeys. Again, those references must be taken with caution because marked variations can be seen depending on the breed, body size, age, growth rate, and training of the animal. In some studies, body size appears to be the key factor affecting the chamber dimension, with donkeys showing smaller chambers compared with horses but similar dimensions compared with ponies. When echocardiographic parameters are adjusted to body weight, donkeys display a lower left ventricular mass index, bigger left ventricular internal diameter index, and relative wall thickness compared with horses. Tricuspid and mitral peak flow velocities are also reported as lower in donkeys than horses. While some of these differences could be attributed to training disparities (left ventricular mass index), the rest of them are likely idiosyncratic to donkeys. This issue should be taken into account during the diagnosis and monitoring of cardiac patients. Finally, clinicians should know that standardized imaging techniques for guided M-mode and Doppler measurements previously described for horses can also be applied to donkeys.

Several cardiac acquired and congenital anomalies have been documented in donkeys, including ventricular septal defect, truncus arteriosus, Adams-Stokes syndrome, pseudotruncus arteriosus, third-degree atrioventricular (AV) block, myocardial disease, valvular sclerosis or thickening, and atrial fibrillation [6,13,14]. Third-degree AV block seems to be a common cardiac conduction disorder in donkeys, particularly in small breeds [15]. Signs of third-degree AV block include weakness, syncope episodes, and collapse [15]. Pacemakers have been successfully placed in donkeys with third-degree AV block [16,17].

It has been reported that 2% of donkeys have an audible murmur [6], considerably fewer than horses (50%–80%) [18]. This apparently lower prevalence could be related to a low sensitivity of cardiac auscultation in this species (due to wider subcutaneous fat, longer hair, and thicker skin) and also probably differences in sampled population. Of interest for clinicians, and considering that donkeys live longer than horses, aortic regurgitation can be frequently found in geriatric donkeys, even without an audible murmur.

Regarding antidysrhythmic drugs, verapamil (0.3 mg/kg/IV) has been studied in healthy nonpregnant jennies. Transient secondary effect such as sinus tachycardia (8 out of 10), wandering pacemaker (1/10), first-degree AV block (1/10), and second-degree AV block (1/10) were observed; therefore, caution should be taken when we use this drug (verapamil) as treatment for supraventricular arrhythmias in donkeys [8]. Tharwat and Al-Sobayil [19] studied the effects of intravenous digoxin (14 µg/kg) in healthy donkeys. No variations were observed in electrocardiogram; biochemistry; and acid-base, electrolytic, or cardiac troponin I plasmatic concentrations. Thus, digoxin appears to be a plausible treatment for arrhythmias and heart failure in donkeys, with a wider safety range compared with horses [20].

Glycoside toxicity due to *Oleander* spp. ingestion has been described in a 9-year-old gelding miniature donkey [21]. The animal showed depression, tachycardia, irregular rhythm, poor peripheral pulse quality, and congestive mucous membranes, as well as ventricular tachyarrhythmia (monitored by radiotelemetry), high plasmatic levels of CKmb, and acute renal failure. No murmurs or echocardiography changes were evidenced. Unsuccessful cardioversion was attempted with lidocaine (even at a 40 µg/kg/min dosage) and procainamide (1 mg/kg/min). Finally, a loading dose of phenytoin (10 mg/kg intravenously) followed by a maintenance dose (3 mg/kg/IV q 12 hours) allowed the return to sinus rhythm.

Caution should be kept in mind in areas where these plants can be found.

Cardiotoxicity of several antibiotics is widely known in donkeys. An example is tilmicosin, a macrolide commonly used in respiratory diseases in some species [22]. Doses used in horses (10 mg/kg) have been shown to induce transient and short-lasting changes in cardiac function and indexes measured by echocardiography in donkeys [23].

3. Respiratory Tract

Any described respiratory disease in horses could probably affect donkeys, although certain idiosyncrasies must be considered. For example, anatomically, nasolacrimal conduct nasal opening is located dorsolateral in donkeys, whereas it is in the lateral wall of the external nares in mules [24]. Nasal cavity is strikingly narrower in donkeys compared with horses. Clinicians should be aware of this particularity, which predisposes donkeys to epistaxis during nasogastric tubing or endoscopy. Moreover, guttural pouch opening is slightly more horizontally oriented (important during the endoscopic maneuver to gain access into the pouch), pharynx is narrower (predisposing to collapse during endoscopy), and epiglottis and aryepiglottic folds are commonly smaller in donkeys than horses [25–27]. The carotid arterial tree is also anatomically different between both species [28], which could be related with the low described incidence of guttural pouch mycosis in donkeys [29]. The specific anatomy of those arteries in donkeys should be carefully studied before arterial coil embolization. Other respiratory clinical differences between both species are caused by their dissimilar behavior and attitude, for example, their insensitive cough reflex compared with horses [27]. Because donkeys are markedly stoic and rarely intensely trained, clinical signs are noticed later, and early diagnosis due to poor performance is rare in donkeys. Considering all these factors, most donkeys with respiratory disturbances are attended with more chronic and severe diseases states than horses, which undoubtedly should be considered when a prognosis is provided in this species.

Congenital defects of the upper respiratory tract have been reported in donkeys, such as choanal atresia, laryngeal deformities [30], and cleft palate [27].

Normal cellular population in bronchoalveolar lavages (BALs) and transtracheal washes (TTWs) has also been described in donkeys, showing variations in the differential leukocyte counts compared with horses (which could be of marked importance in these fluids). Bronchoalveolar lavage description was similar to horses, but slightly higher macrophage percentages were observed [31]. On the other hand, TTW showed higher neutrophil and eosinophil counts in healthy donkeys compared with horses [25]. Perhaps these findings could be attributed to the breed and age of those animals used in this study.

Dynamic pulmonary tests have also been described in donkeys, showing higher total pulmonary resistance and respiratory rates, whereas pulmonary compliance was lower than in horses [25].

It is not the goal of this section to describe each respiratory pathology of donkeys in detail but to list the common ones and underline reported interspecific differences. In a population of 1,444 geriatric donkeys, pulmonary fibrosis was the most frequent disease (35.2%), followed by tracheal collapse (8.7%), guttural pouch disease (4.9%), lower pulmonary and pleural diseases—including recurrent airway obstruction and pneumonia (4%)—sinusitis (0.8%), and lung neoplasia (0.4%) (Fig. 1 and [Supplementary Material 1](#)) [14]. Exercise-induced pulmonary hemorrhage has not been described in donkeys to the authors' knowledge.

Pulmonary fibrosis, common in elderly donkeys, shows pathological findings similar to pleuroparenchymal fibroelastosis in

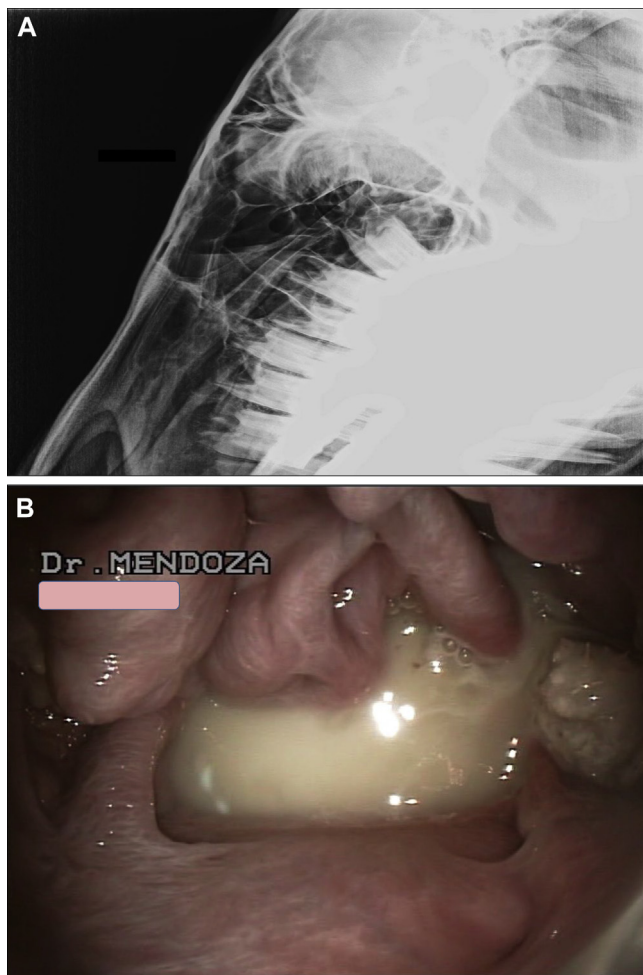


Fig. 1. A 10-year-old Andalusian jack with maxillary sinusitis secondary to oronasal fistula between 207 and 208 diastemata. (A) Lateral head radiography showing a fluid line in the rostral aspect of maxillary sinus. (B) Left maxillary sinuscopy; note molar roots and the accumulation of exudate into the sinus, caused by alimentary material penetrating through the oronasal fistula.

humans [32]. This fact could potentially make the donkey an interesting experimental model for this human disease. Asinine herpesvirus 4 (AHV-4) and AHV-5 have been isolated and proposed as potential causative agents for this condition [33]. One can speculate that this condition is equivalent to equine multinodular pulmonary fibrosis—linked to equine herpesvirus 5 (EHV-5)—in horses. Pulmonary fibrosis can be confused with severe donkey asthma because resting respiratory effort, tachypnea, and cough are features of both conditions. Absence of pulmonary sounds is frequent with pulmonary fibrosis (although pulmonary sounds can be challenging to hear in fat donkeys). The diagnosis is based on thoracic radiography, which usually shows a diffuse interstitial pattern. The value of BAL in the diagnosis of pulmonary fibrosis is unclear. Intracellular inclusion bodies identified in respiratory epithelial cells of horses with pulmonary fibrosis have not been demonstrated in donkeys. Thoracic ultrasonography is not diagnostic but can confirm the presence pulmonary parenchymal disease. Computed tomography (CT) and magnetic resonance imaging (MRI) are helpful in people but not feasible for donkeys. Pulmonary function tests and lung biopsy are useful ancillary diagnostic tools. Treatment for pulmonary fibrosis is similar to pulmonary interstitial diseases in horses and includes steroids, antifibrotic drugs (i.e., pentoxifylline), and bronchodilators. The pharmacology and

efficacy of antiviral drugs such as acyclovir or valacyclovir have not been evaluated in donkeys.

Tracheal collapse is a frequent finding in elderly donkeys [34]. Distal cervical trachea and thoracic inlet are the most common affected areas. Evidence is usually null, and diagnosis is elusive, being a necropsy finding in some animals. A link between tracheal collapse and pulmonary fibrosis has been proposed although not definitively proved, in a study. It is thought that a higher inspiratory effort and subsequent higher intrathoracic pressure could promote pulmonary fibrosis or viceversa, even in donkeys with moderate-severe asthma [27]. Clinical presentation depends on the collapse degree, from no signs to audible inspiratory and expiratory effort, tachypnea, chronic coughing, inspiratory honking noises, or even acute respiratory distress in severe forms. Final diagnosis is based on endoscopy and radiology. Stent placement has not been described in donkeys yet.

Similar to horses, primary pulmonary neoplasia is rare (0.4% incidence) and difficult to diagnose, being commonly confused with other respiratory diseases. Incidence is higher in elderly donkeys, and signs are variable, from chronic and progressive dyspnea to nasal discharge, cough, weight loss, or fever [27]. A complete examination is necessary, including biochemistry (anemia, monocytosis, and hyperglobulinemia are common features), endoscopy, thoracic radiography, cytological analysis of pleural effusions (if present), BAL, and pulmonary biopsy [35]. Both primary and secondary pulmonary neoplasia have a poor prognosis [36,37].

As previously mentioned, exercise-induced pulmonary hemorrhage has not been described in donkeys. Because intense training and exercise are not usual in this species, this finding could be expected. Nonetheless, readers should remind that apart from exercise, alveolar blood capillaries can also be damaged by other causes of excessive low intraalveolar pressure (laryngeal hemiplegia, tracheal collapse, intense respiratory effort due to pulmonary fibrosis, and so forth). Animals suffering from any of the aforementioned diseases could display hemoptysis to some degree.

Concerning infectious respiratory diseases, the role of donkeys and mules as reservoir should always be kept in mind. In show events, contact between horses with donkeys or mules is often not regulated or supervised and could be an avenue for cross infections [38]. Cohabitation between those species should also be strongly supervised and carefully registered. Moreover, strict deworming and vaccination programs should be implemented in farms with presence of various species.

Influenza is the most common infectious respiratory disease in donkeys [39], with cases reported worldwide, including the United States [40], Nigeria [41], Pakistan [42], Egypt [43], Spain [44], France [45], Morocco [46], and China [47]. Donkeys are apparently more susceptible than horses to this virus [48]. Avian influenza (H5N1) has been reported in three Egyptian donkeys [49]. Clinical signs and diagnosis are similar to horses. Influenza susceptibility in mules is unknown. Unfortunately, owners and veterinarians are not aware of donkeys' higher susceptibility to influenza, and vaccination programs are not common in this species. At this moment, horse vaccine could be administer to donkeys, until that a specific donkey vaccine is marketed.

Donkeys can be infected by EHV-1 and EHV-4 [50], as well as specific asinine herpesviruses (AHV-1, AHV-2, AHV-3, AHV-4, AHV-5, and AHV-6). Not every asinine variant causes respiratory disease in donkeys. Horses can also get infected with asinine viruses, leading to clinical disease or becoming asymptomatic carriers [51]. Mules can be infected but rarely show signs [52]. Clinical signs, diagnosis, and treatment are similar to horses [27]. AHV-3 diagnosis can be challenging because a negative polymerase chain reaction but positive cytopathogenic effect can be seen. Moreover,

complement fixation can yield false negative results due to the anticomplement activity of donkey and mule serum [53]. Till date, there are no available vaccines for asinine herpesviruses. Nonetheless, although no studies evaluating cross protection have been reported, equine vaccine protocols and products could be used in donkeys while specific ones are available.

Clinical disease from natural equine arteritis virus infection has not been reported in donkeys or mules; however, there are donkey-specific strains (KY-84; asinine-94) with limited transmission to horses [54]. Fever, mild depression, nasal and ocular discharges, and ventral edema were reported in donkeys infected experimentally [55]. The study supports species-specific resistance and the presence of subclinical infections [54]. Seropositivity has been documented in asymptomatic donkeys in South Africa [55], Morocco [55], Zimbabwe [55], Brazil [56], and Turkey [50].

Exotic respiratory infectious diseases affecting donkeys and mules include African horse sickness and glanders (*Burkholderia mallei*). Donkeys and mules appear to be more prone to glanders than horses [53,57], but African horse sickness is less severe and rarely fatal in donkeys [58], which may have epidemiological implications because donkeys and mules can act as carriers [59].

Mycotic pneumonia due to *Aspergillus* spp. was documented in five Albino Asinara donkey foals [60]; all animals died, and final diagnosis was reached via culture in postmortem specimens. No radiographic or echographic examinations were performed. The authors suggested that immunosuppression (e.g., herpesvirus pneumonia) could have facilitated fungal invasion. No evidence of gastrointestinal disease was found, contrary to systemic aspergillosis in horses [60]. Whether this condition is important for the general donkey population or merely a finding in those reported Asinara donkeys is still unclear.

Donkeys can host high numbers of adult lungworms (*Dictyocaulus arnfieldi*), showing minimal to no clinical signs compared with horses and acting as carriers. High prevalence (68%–87.5% for donkeys and 29% for mules) has been reported worldwide [61,62]. Therefore, horses and donkeys grazing together should be avoided, and pastures where donkeys have been grazing should be considered infested unless a strict routine deworming program has been implemented in those animals. Diagnosis is achieved via fecal examination (Baermann method). Bronchoalveolar lavage cytology may help, showing eosinophilic inflammation (keeping in mind differences in leukocyte percentages compared with horses) and rarer larval stages. Macrocyclic lactones (ivermectin and moxidectin) and benzimidazoles (fenbendazole, oxfendazole, and albendazole) are effective against this parasite. A pour on eprinomectin treatment has also been seen to be efficient in a couple studies [27,63]. Rhinoestrosis has been described in African and European donkeys [64]. This upper respiratory tract myiasis can cause respiratory (even neurological if larvae migrate to the brain) signs such as dyspnea, wheezing, snorting, respiratory stridor, face rubbing, or sinusitis. Parasitic charge determines the clinical presentation. Lower tract disease is rarely seen with these parasites. Diagnosis is commonly reached via endoscopy.

Donkeys' respiratory pharmacology is a poorly studied field, and clinicians are forced to use information available for horses. Nonetheless, antibiotics and antiinflammatory drugs must be adequately dosed in donkeys following their proper needs.

4. Neurology

Although neurological problems can be seen in donkeys, with similar causes to other equids, many physiological variables of importance for neurological diagnosis have not been established in donkeys yet. For example, a complete description of the normal X-

ray findings in the cervical area is lacking (of interest for the diagnosis of cervical stenotic myelopathy). Intravertebral and intervertebral ratios and measurements (useful for the diagnosis of this disease) are undescribed in this species as well. Normal cranial CT or MRI image descriptions are also lacking, and only one case report has described CT and MRI findings in a donkey with severe brain trauma [65]. On the other hand, although only for miniature donkeys [66], reference values for cerebrospinal fluid parameters have been established. Total (2–4 cells/ μ L) and differential cell count, specific gravity, glucose, urea, total protein, total calcium, phosphorus, magnesium, chloride, sodium, and potassium concentrations were measured. No gender differences were found, and only phosphorus was different between donkeys and horses (4 vs. 2.4 mg/dL, respectively). Nonetheless, care must be taken when interpreting these data in different donkey breeds. Finally, Nollet et al [67] described a transcranial magnetic stimulation technique for the diagnosis of nervous disorders in donkeys.

Infectious encephalitis can affect donkeys showing similar signs to those described in horses. Exotics (until recently) neurological vector-borne diseases are becoming common in template areas. This finding should probably be related to global warming because vector populations are now able to reproduce and maintain annual populations in nontypical areas. As an example, the first outbreak in Spain of West Nile virus (WNV) in equids and humans was confirmed in 2010 with 102 affected horses and 18 dead ones [68]; despite of seropositivity was seen earlier, in 2005 [69]. Although neither donkeys nor mules were affected in that outbreak, 7.3% of them have been reported as serologically positive in a previous study on 90 farms in Southern Spain. In other European WNV outbreaks, donkeys and mules were affected [70].

Japanese viral encephalitis has been described in donkeys in Asia, India, and Australia, with similar signs to WNV encephalitis [71,72]. This pathology is not reported in equids in Europe or America although wild migratory and resident birds have been proved to be carriers [73]. New emerging flaviviruses have been reported in horses all around the world, such as Usutu and Saint Louis virus encephalitis [74,75], but they have not been described in donkeys at this moment.

Other mosquito-borne viral encephalitides caused by alphaviruses (Eastern equine encephalitis, Western equine encephalitis, and Venezuelan equine encephalitis) are well documented both in donkeys and mules [76,77]. Donkeys are used to develop vaccines against these viruses [78]. Venezuelan equine encephalitis signs are usually mild in donkeys and mules [79], thus they could act as carriers and propagate the disease to horses and people. Vaccination strategies for horses also apply to donkeys.

There is a current controversy over equid alpha and gamma-herpesviruses (EHV and ASH), mostly concerning their nomenclature, pathogenicity, and similarity. ASH-3 is thought to be similar to EHV-1 according to their glycoprotein G nucleotide sequence [80]. Other studies have also detected EHV-1-like viruses in healthy donkeys, raising questions about their pathogenicity in this species [81]. A neurological condition similar to EHV-1 myeloencephalitis can be seen in donkeys [82], but its prevalence is lower than horses (even when affecting unvaccinated animals).

Borna disease has also been described both in donkeys and mules [83,84]. As an example, Borna positivity in Chinese donkeys (blood and brain samples) is 10% [85].

Rabies can still be seen in some African areas both in donkeys and mules [86,87]. Several cases have also been reported in the United States. In these examples, donkeys were tested due to bites to humans. Main rabies signs in this species are aggressiveness, paresis, chewing, and salivation [86]. Other examples of donkeys tested positive to rabies have been reported in Asia [88] and the Middle East [89].

Equine coronavirus infection has been shown to induce neurologic signs (head pressing, depression, ataxia, recumbency, and seizures) in donkeys, most probably due to intestinal hyperammonemia and secondary encephalopathy [90,91]. The presence of concurrent digestive signs could help in the diagnosis of these patients.

Equine emerging tick-borne neurological diseases has been reported in donkeys (because tick bites are highly prevalent in this species due to their common extensive management). Neosporosis has been described all over the world, from Europe [92] to South America [93,94]. Lyme disease (*Borrelia* spp.) has also been observed causing neurological disease in donkeys in Europe [95,96]. To the author's knowledge, equine protozoal myeloencephalitis (*Sarcocystis neurona*) has not been reported in donkeys, and this species is thought to be resistant [97]. Nonetheless, in a commonly neglected species as this one, the lack of reports should not be considered synonym of resistance to a disease.

Concerning other parasites, we could assume that verminous myelitis is probably more common in donkeys than other equids in some countries (due to their poor prophylactic anthelmintic control). Even so, only one case report of a 2-year-old male donkey showing weakness, ataxia, progressive paraparesis, and tetraplegia is reported [98].

Noninfectious neurological diseases have also been reported in donkeys and mules. Degenerative myeloencephalopathy could be expected to be common in donkeys due to the low vitamin E and poor-quality forage they are usually fed. Nonetheless, there are few reports in donkeys [99], and none in mules. Affected donkeys show similar clinical signs as horses (weakness, symmetric ataxia, a wide-based posture, and spasticity). Vitamin E deficiency has been also reported in donkey foals [100], but at this time, serum reference range and/or requirements for different age groups have not been published.

Compressive myelopathy occurs sporadically in donkeys and mules, but literature about this condition is lacking. Cervicovertebral malformation (stenotic myelopathy and Wobbler's syndrome), trauma, abscesses, neoplasia, and fractures can also be causes of compressive myelopathy in donkeys. These animals show a symmetric—more severe in hindlimbs—ataxia. Diagnosis is similar to horses, by means of lateral cervical radiography, CT or MRI, and cerebrospinal fluid collection. Clinicians should remember that species-specific X-ray descriptions of the cervical area and reference ranges for intravertebral and intervertebral ratios are not available in donkeys at this moment.

Leukoencephalomalacia due to fumonisin B1 intoxication was described in 100 donkeys in Mexico [101]. Donkeys showed ataxia, hyperesthesia, circling, head pressing, blindness, and hyperexcitability, similar signs to equine Venezuelan encephalitis. In fact, Venezuelan encephalitis should be a top differential for any neurological condition affecting multiple donkeys or equids in an area. Pyrrolizidine alkaloid toxicity can also cause neurological signs (due to the hepatic damage and associated encephalopathy) in this species [102].

5. Urinary System

Urinary tract diseases are not commonly reported in donkeys, which could be due to a truly low prevalence, unapparent clinical signs, lack of recognition by the veterinarian or owner, or infrequent evaluation of blood chemistry. Similar to disorders in other systems, diagnosis is often late (Fig. 2A).

In one postmortem survey of renal lesions in 100 donkeys, tubulointerstitial nephritis (50%), cystitis (19%), renal fibrosis, and cysts (13%) were the most common lesions found in the urinary

tract [103]. Hyperkalemia and hyponatremia were the most frequent biochemistry alterations in donkeys with renal disease [103]. Dysuria, stranguria, and pollakiuria were the most frequent clinical signs in these donkeys. *Streptococcus* spp. (43.3%), *Escherichia coli* (20%), and *Corynebacterium* spp. (10%) are the most common bacterial isolates in donkeys with urinary tract infections [104]. Congenital abnormalities of the urinary tract have also been reported in donkeys, such as one 3-week-old miniature donkey with incomplete urethra (hypospadias), which was successfully surgically resolved [105].

Studies on neither acute renal disease (ARD) nor chronic renal disease (CRD) in donkeys have been addressed, which markedly limit the scientific certainty of any treatment. Nonetheless, while a more profound understanding of those pathologies is achieved in this species, a similar medical management to horses could be advisable. In ARD, forced diuresis with fluid therapy and a furosemide continuous infusion could be helpful, followed by vasopressor drugs administration in severe cases (Fig. 2B). In patients with CRD, a low-calcium and low-protein diet should be implemented, along with high-quality grass and supplements such as soy oil, minerals, and vitamins.

Nephrolithiasis, ureterolithiasis, cystolithiasis, and ureterolithiasis have been reported in donkeys (Fig. 2C) [103,106,107]. Animals are usually referred due to hematuria and pollakiuria. Calculi removal can be achieved through lithotripsy, urethrostomy, laparoscopic cystotomy, and laparocystotomy (Fig. 2C), using similar technique as those previously described for horses [107].

Other causes of hematuria in donkeys include *Halicephalobus gingivalis* (formerly *Micronema deletrix*) infection [108,109] and idiopathic renal hematuria [110]. *Halicephalobus gingivalis* infection can be diagnosed by means of urinary analysis or renal ultrasound where an anechoic mass compatible with a parasitic granuloma can be occasionally observed. Idiopathic renal hematuria has only been described in an 18-year-old mule, with resolution after unilateral nephrectomy via a ventral midline celiotomy [109].

Klossiella equi infection has also been described in donkeys [111,112]. This is often a necropsy finding because clinical signs from this coccidian parasite are not apparent. Renal infection by *Leptospira* spp. has been documented in donkeys. In a study, 60% (9/15) of Moroccan donkeys were positive at least to one strain, but only three animals (20%) were positive against pathogenic ones [113].

Most drugs used in horses and ponies with renal disorders have not been investigated in donkeys; therefore, correct dosing and safety are unknown (many clinicians presume them to be similar to horses, which should not be a universal assumption). Moreover, nephrotoxicity due to several commonly used drugs has also been proved in donkeys. For example, renal congestion, interstitial nephritis, and gastric glandular ulcers were seen in a group of miniature donkeys treated with flunixin meglumine (1 mg/kg/IV/PO), ketoprofen (2.2 mg/kg/IV), and phenylbutazone (4.4 mg/kg/IV or PO) twice daily during 12 days. Animals treated with phenylbutazone also showed anorexia and mild diarrhea [114]. High doses of gentamicin can also induce acute kidney disease in donkeys, with elevation in the levels of interleukin-1 β , interleukin-6, and gamma interferon, as well as acute phase proteins. Interestingly, when this treatment was accompanied with vitamin C, inflammatory and acute disease markers significantly decreased [115]. In a similar way, other antioxidant products, such as selenium, have been proven to reduce azotemia in a donkey model with acute kidney disease induced by exercise [116].

6. Ophthalmology

There are significant differences in donkeys' ocular anatomy compared with horses. Their eyeball is usually slightly more

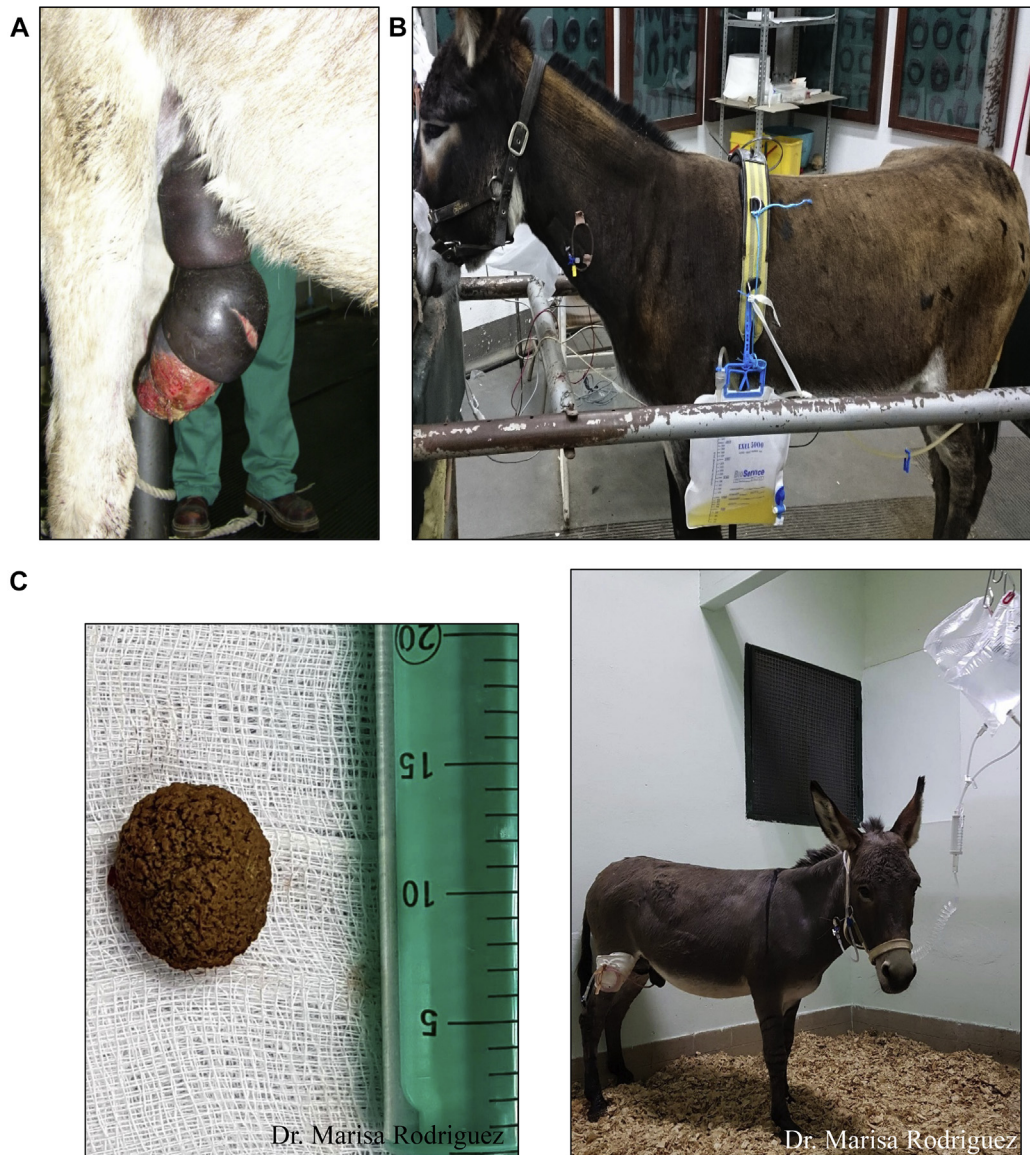


Fig. 2. (A) A 7-year-old Andalusian jack with balanoposthitis. Observe swollen penis with ulcerated skin. (B) A 6-year-old Catalonian jenny with acute renal failure secondary to prolonged severe hypovolemia. Note urine collection system and the urinary probe to measure urine production during a furosemide constant rate infusion. (C) A 13-year-old Catalonian jack with acute onset of colic signs, hematuria, and pollakiuria. Note the stone removed from the urethra (left image), and the urinary probe allocated through the artificial surgical urethral meatus. (Courtesy of Dr. Marisa Rodríguez, Hospital Veterinario San Vicente, Alicante, Spain).

sunken, and they commonly possess a thicker periocular hair (Fig. 3). These differences together with their stoical behavior and their common extensive or semi-wild management make one more difficult to detect initial and mild lesions in donkeys. Thus, clinicians are commonly faced with severe, recurring, and chronic pathologies, and a certain loss of sight is a usual finding in these animals during the examination.

Normal ocular ultrasonographic appearance has been described in donkeys, demonstrating marked idiosyncrasies in ocular biometry compared with horses. Donkeys possess a smaller eyeball (corrected for their body size). Finally, weight and age have been proven to affect lens size (elderly donkeys and those between 100 and 200 kg showing larger lens) [117].

Donkeys suffer similar ocular pathologies than horses. Incidence is usually high, and in some developing countries, such as Ethiopia, 86.4% donkeys present some ophthalmological condition [118] although this percentage should be understood to be

true only for working animals in that location. Most frequent ocular pathology in donkeys are corneal ulcers. Their bigger conjunctival sac -compared with horses- and the mentioned populous periocular hair provide an ideal environment for foreign bodies. Their corneal surface is slightly larger and more convex than horses, which also predisposes them to corneal ulcer. Due to their behavior, the typical florid signs shown in horses (blepharospasm, epiphora, photophobia, and so forth) are later seen in donkeys. Corneal ulcer's treatment is similar to that described in horses, relying on a medical approach and surgery in severe cases. Several surgical techniques have been reported in donkeys for corneal ulcers resolution, such as the use of a porcine urinary bladder extracellular matrix graft in a miniature donkey with severe unilateral keratomalacia [119]. When medically treating donkeys with corneal ulcers and, if atropine is administered, gut motility, fecal production, and heart rate should be closely monitored [120].

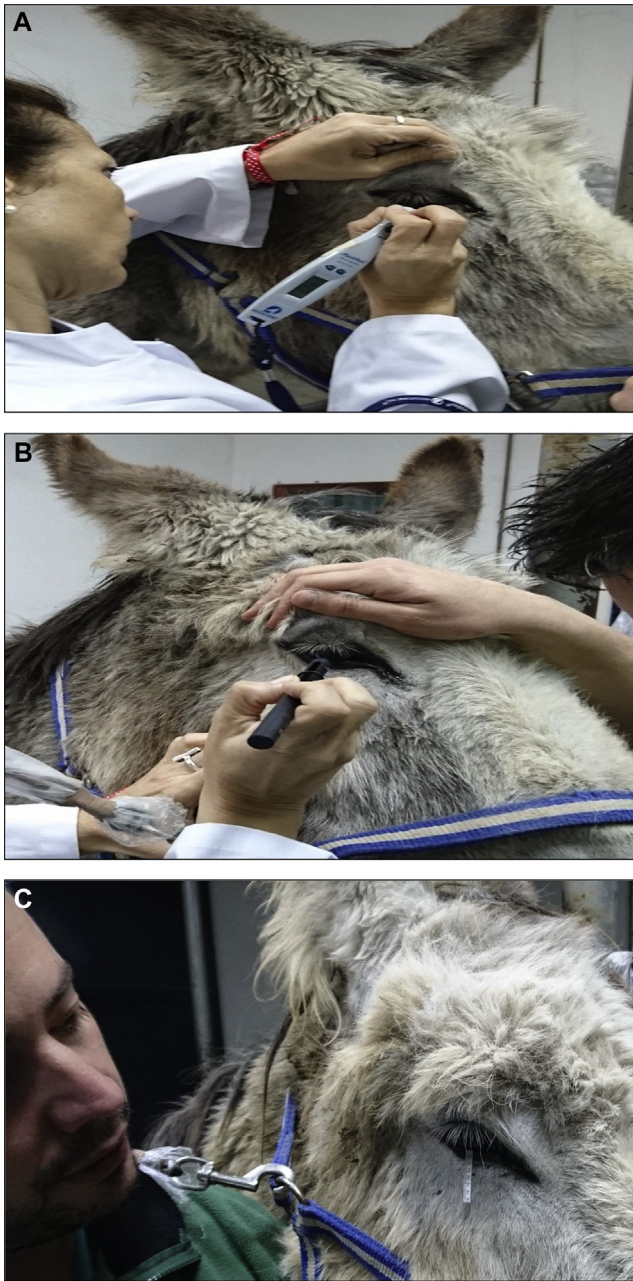


Fig. 3. A 5-year-old Andalusian jenny during an ophthalmological examination. (A) Ocular pressure measurement using a TonoPen device. (B) Measurement of corneal thickness. (C) Schirmer's test using regular trips.

Nonulcerative keratitis (e.g., eosinophilic keratitis) has been reported both in mules and donkeys. Blepharospasm, epiphora, and conjunctivitis were observed, and a final diagnosis of unilateral eosinophilic keratitis was made [121].

The distal opening of nasolacrimal duct (nasal caruncle) shows a different location in donkeys compared with horses and mules. Obstructions in this duct are not rare in asses, causing secondary conjunctivitis. An excessive dusty environment could be a risk factor for this condition. Dacryocystography is the technique of choice for the diagnosis of obstruction, atresia, or fistulation of this duct [122] and the aforementioned anatomical idiosyncrasy must be kept in mind. Maxillary sinusitis and neoplasia have also been seen sporadically to cause those obstructions. Only type 1 Schirmer's test has been described in donkeys. Because this species'

reflex tear production can be overwhelming, a 15 seconds evaluation is preferred, with an average 8.8 mm result [122]. If available, larger strips could be more appropriate for this test in donkeys. The effect of an iodine contrast medium has also been investigated in donkeys. Three milliliters of iohexol did not change tear production [123] and neither altered tear composition [124], contrary to oil-based mediums such as amidotrizoate. A dacryoadenitis extending to the duct due to *Histoplasma* spp. has also been reported in this species [125].

Both primary and secondary (due to corneal ulcers, nasolacrimal duct obstructions, trauma, and so forth) conjunctivitis can be observed in donkeys. Again, dusty environments and high fly population could be related to these pathologies. Treatment with a combined antibiotics ocular preparation can be curative. Most frequent bacteria isolated from healthy donkeys' conjunctiva are *Staphylococcus* spp. (65%) and *Enterobacteriaceae* (25%) [126]. Recently, the emerging human pathogen bacteria *Kocuria* spp. has been isolated in donkeys [127]. These results should be kept in mind when establishing treatment in chronic, recurrent, and nonresponsive conjunctivitis. Fungi can also be normally found in donkeys' conjunctiva. Nardoni et al [128] isolated at least one fungal microorganism in 79.4% healthy donkeys, with *Aspergillus* spp. (33%) being the most frequent genus, followed by *Penicillium* spp., *Cladosporium* spp., and *Acremonium* spp. This fungal flora should also be kept in mind when treating complicated ulcers. In addition, conjunctival flora depends on geographical distribution, and this issue must be considered for treatment [127].

Recurrent anterior uveitis seems to show a lower prevalence in donkeys compared with horses. This finding could be explained by the low frequency of ocular examinations in this species along with a certain degree of inattention by the owners and a semi-extensive management. Treatment and prognosis are similar to those described in horses because species-specific studies are lacking at this time.

Owing to their longevity, donkeys have been shown to be prone to lens pathologies such as cataracts and lens luxation. Both intracapsular and extracapsular surgical approaches have been reported for cataracts in this species, with similar complications than in horses [129].

Fundus pathologies, such as bilateral complete colobomas, can be observed in donkeys. Retinography and fluorangiography have been validated for donkeys [130]. Fundus differences (shape, color, and location of structures) are not prominent between donkeys and horses [131].

Ocular parasitism has also been described in donkeys, mostly by *Onchocerca* spp. [132] and *Setaria equina* [133]. Habronemiasis in the medial aspect of the conjunctiva is also a common finding in some regions [118].

Blindness can be challenging to detect in donkeys, mostly by owners. Donkeys usually remember and recognize their environment extremely well, and they are not frequently used in sport activities. Moreover, due to their gregarious behavior, it is not unusual to observe a paddock mate, guiding a blind animal. In addition to the aforementioned causes, blindness due to trauma with secondary phthisis bulbi has been reported in this species [118].

Periocular neoplasia, mostly sarcoids, can be observed in donkeys. Detailed information can be found in Section 7.

7. Dermatology

Although donkeys and horses share dermatoses, their clinical presentation and response to treatment may vary for a number of reasons, including thicker hair coat in donkeys, variable response to disease (e.g., pruritus threshold, and inflammatory response), and pharmacological properties of drugs used. Disorders tend to be

detected later due to the natural behavior of donkeys as well as management practices.

Congenital dermatoses have been rarely reported in donkeys, with dermoid cysts being the most commonly observed [134]. Excision is the treatment of choice.

Traumatic skin lesions are probably the most common problem in working donkeys around the world. Secondary bacterial or parasitic infection is common, as well as chronification due to continuous trauma.

Similar to horses, sarcoids are the most frequent cutaneous tumors in donkeys. In one study, the head and ears were the most prevalent location (51%), with male donkeys, showing predisposition to their development, although a convincing reason for this has not been reported yet [135]. Surgical excision can be effective if the lesion is completely removed. Cryosurgery, laser surgery, intralesional Bacillus Calmette-Guerin injections, radiotherapy (if available), and topical chemotherapy with drugs such as cisplatin and 5-fluorouracil can be used in a similar way to horses. Other skin tumors observed in donkeys are squamous cell carcinomas, fibromas, fibrosarcomas, melanomas, and epitheliotropic lymphomas [136].

Ringworm is the most reported cutaneous fungal disease in donkeys, usually caused by *Trichophyton verrucosum* or *T. mentagrophytes*. Clinical signs are those typically seen in equids, such as alopecia, scaling, centrifugally expanding circular (shape can vary) patches of alopecia, and lack of pruritus [137]. Although dermatophytosis can spontaneously resolve in some animals, clipping, topical washes with enilconazole and chlorhexidine, potassium iodide administration, and sunbathing can help [138].

Parasitic dermatoses are commonly observed in donkeys. Besnoitiosis (*Besnoitia benetti*) has been reported all around the world, independently of the climate, and affecting almost every donkey breed [139]. Typical clinical signs include presence of tissue cysts (approximately of 1 mm in diameter) in sclera, nasal and buccal mucosa, limbs, and perineum along with dermatitis. Treatment with trimethoprim-sulfamethoxazole [140] resolved the signs in one donkey [141]. Cutaneous habronemiasis has also been described in donkeys, mostly affecting the medial canthus, shoulder and pectoral regions, knee and fetlock joints, abdominal wall, and prepuce.

Insect hypersensitivity is seen in donkeys, mostly related to *Stomoxys calcitrans* and *Culicoides* spp. Signs of hypersensitivity to *Culicoides* spp. can vary between horses and donkeys [142]. In donkeys, intense pruritus, exudative dermatitis, lichenification, self-induced lesions, and crusts on the legs and head are more common than lesions on the withers, rump, and tail. Moreover, bilateral alopecia along the trunk midline (sweet itch syndrome) is rarely observed. Management and environmental actions (housing, blankets, insect repellents, and so forth) should be encouraged in these animals, same as in affected horses. Concerning bacterial dermatoses, folliculitis and furunculosis can appear in donkeys as secondary problems in pruritic conditions. *Dermatophilus congolensis* infection (rain scald or rain rot) has been reported in donkeys worldwide, with animals showing small scabs and raised tufts of hair in the back, shoulders, and neck [135]. Parenteral trimethoprim-sulfamethoxazole and topical iodide or chlorhexidine washings are usually used. Other less reported bacterial dermatoses are those caused by *Staphylococcus* spp. or *Corynebacterium pseudotuberculosis*. Deep abscesses have also been seen by the authors secondary to bites or traumatic wounds. Cultures and histopathology can aid in the diagnosis of bacterial skin diseases in asses. Independent of the primary agent, affected animals should be clipped out, maintained dry and clean, and an adequate treatment with antibiotic should be established based on antibiogram.

8. Musculoskeletal

Detailed studies about the epidemiology, types, and clinical signs of lameness in donkeys are only available for working animals. This population showed a strikingly high prevalence (90% in one study), mainly in the hindlimbs, which could be in part attributed to unique anatomical features, type of physical activity, and age [143,144]. In general, musculoskeletal diseases in donkeys are similar to those described in horses, but some anatomical idiosyncrasies must be considered. Foot lesions appear to be the main cause of lameness (65% of the cases), and this structure is the one where differences between both species are more marked [145]. The dorsal hoof wall is more vertical in donkeys than horses (5° – 10°), and their hoof-pastern axis is more upright [146]. The frog does not typically extend as far toward the toe as in horses (important when we apply a soft support in this area in cases of laminitis). In addition, the sole is more rounded in donkeys, with a U-shape (again important for corrective shoeing in laminitis and soft-tissue problems such as desmitis or tendinitis). For a more detailed description of donkeys' hoof idiosyncrasies, readers should consult the referenced bibliography [147]. The aforementioned anatomical differences are linked to radiographical specific findings in donkeys. For example, a negative phalangeal rotation angle can be seen in healthy donkeys [148]. The distance between the proximal limit of the hoof wall and the extensor process (founder distance) is greater in average-sized donkeys than that in horses (10–13 mm vs. 3–5 mm, respectively) [149,150]. Finally, the mean integument depth is 25% greater in donkeys than horses (16.2 mm vs. 11–13 mm, respectively) [149]. Knowledge of these hoof measurements can aid the clinician during the diagnosis and monitoring of hoof disturbances in donkeys.

Laminitis is a very common cause of lameness in donkeys (Fig. 4 and Supplementary Material 2). Because donkeys are not intensely trained, are usually in an extensive environment and less prone to express pain signs than horses, the diagnosis is typically later. Digital pulse, painful reactions to hoof testers and reluctance to move are the typical clinical signs. In chronic cases, rotation of the third phalanx, sinking, bone remodeling, and demineralization, as well as typical growth rings can be found. Most laminitis in donkeys are endocrine in their origin (metabolic syndrome and pituitary pars intermedia dysfunction). Therefore, along with X-ray images, endocrine tests should be performed in any donkey with laminitis. Treatment, for both acute and chronic cases, is similar to horses: soft support for the frog (bedding, soft pack, and soft shoes), nonsteroidal anti-inflammatory drugs, rest, and farrier. In cases with long evolution and without response to those measures, we could propose to the owner surgical techniques such as neurectomy and deep digital flexor tenotomy.

Pedal abscesses are also a common cause of lameness in donkeys, probably due to poor feet care and environmental conditions (high humidity, low hygienic paddocks, and so forth.) (Fig. 5). Clinical signs are similar to horses. The presence of solar or coronary band drainage supports the diagnosis. Radiology is valuable for the diagnosis and assessing the extent of the lesion. Treatment consists of drainage, local antiseptics, local antibiotics (metronidazol), soaking in various astringent solutions, bandaging, analgesics, and rest.

Long hooves are a frequent problem that may predispose donkeys to excessive coffin bone remodeling. Other pathologies such as white line disease, interphalangeal joint contracture and luxations, and keratomas have been also observed in this species but less frequently [147,151,152].

Hip fractures and coxofemoral luxations in small- to medium-sized donkeys (<250 kg) secondary to fall down appears to be

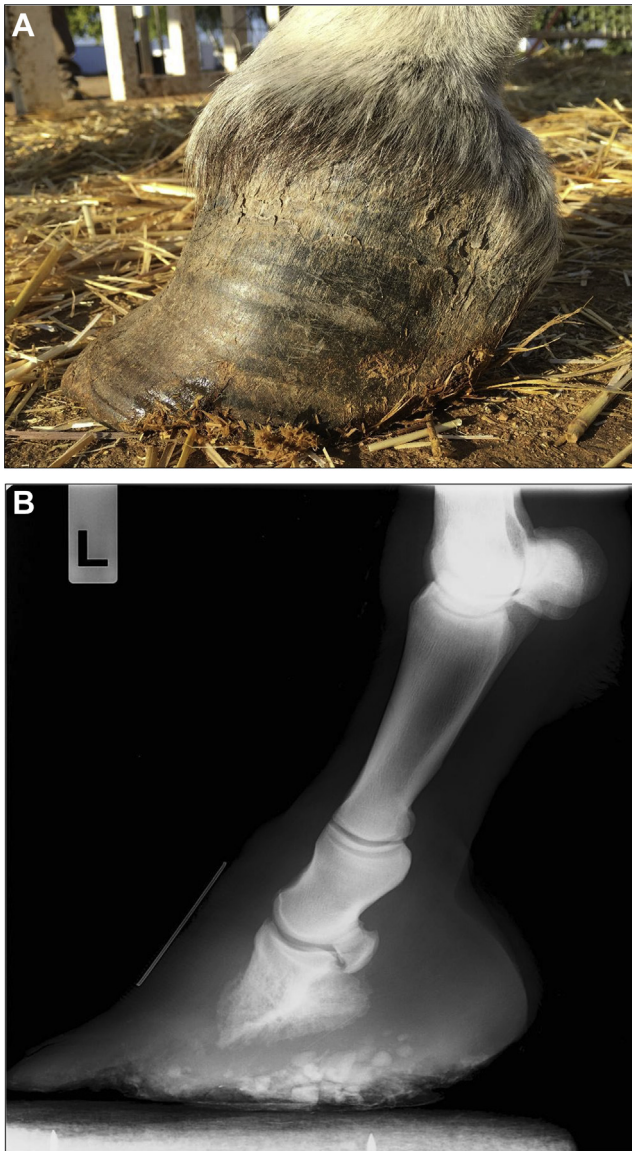


Fig. 4. A 10-year-old Andalusian jack with chronic bilateral forelimb laminitis. (A) Left forelimb showing long hoof and growth ring pattern typical of founder. (B) Lateral digital radiography showing third phalanx bone remodeling, rotation, and sinking.

frequent [153]. An oblique lateral projection in standing sedated donkeys can be diagnostic for those cases [154]. Moreover, femoral head osteotomy has been described for donkeys with such diseases [155]. Conformational abnormalities such as carpal valgus, cow hocks, and broken-forward hoof-pastern axis in hindlimbs are described in this species [145].

Deep and superficial digital flexor tendinitis (23%–47%), suspensory desmitis (16%–31%), and digital flexor tendon sheath swelling (62%–77%) are frequent problems associated with fore and hindlimb lameness in working donkeys [145]. A spinal origin of the lameness has been described in donkeys as well. Cervical and thoracolumbar reduced flexibility and pain has been linked to lameness of spinal origin [145]. Overwork and overloading in working animals or intervertebral disc protrusions could be the cause for this back pain [156].

Chronic myopathic changes (fiber size variation and internal nuclei) were the most frequent histological finding in donkeys and mules with muscular pathologies in a retrospective study

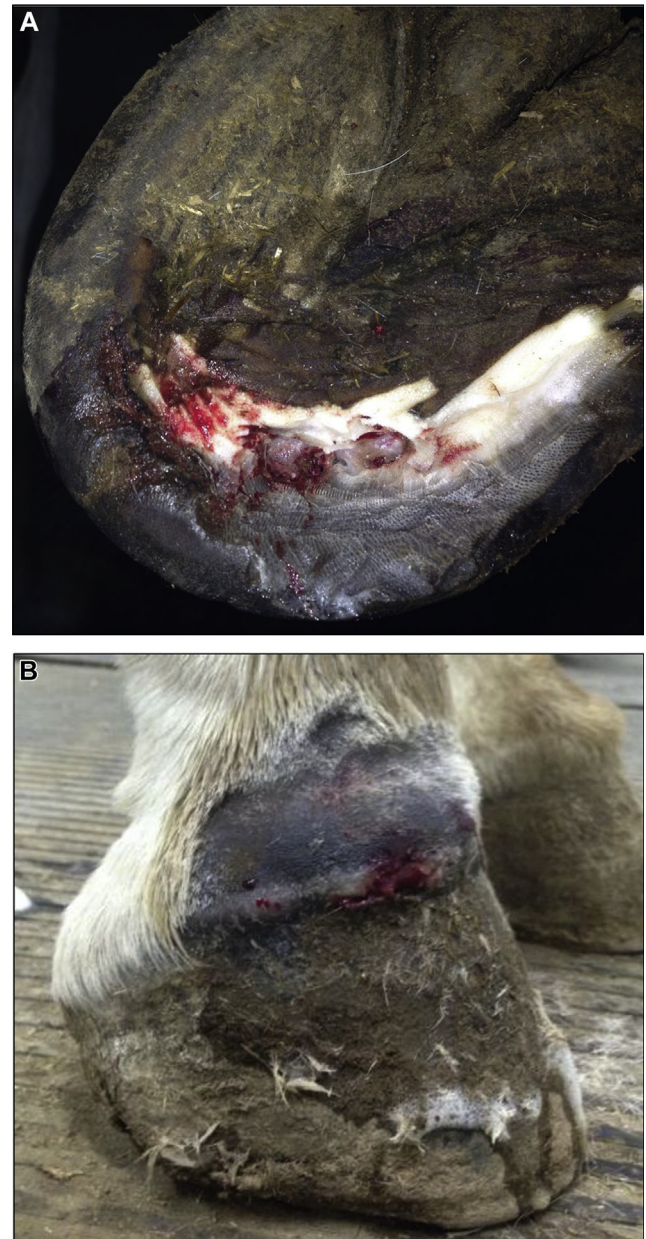


Fig. 5. A 6-year-old Andalusian jenny with right forelimb lameness (4/5°). (A) Hoof sole showing a ruptured pedal abscess. (B) Note the fistula in the inflamed coronary band due to a second point of rupture of the pedal abscess.

[157]. Muscle atrophy secondary to starvation or gastrointestinal disorders as well as degenerative muscular lesions and myonecrosis due to selenium deficiency were also seen in this study [157]. Biopsy sampling and histochemical techniques useful for myopathies are described in donkeys and mules [158]. Exertional rhabdomyolysis, polysaccharide storage myopathy, grass sickness, and atypical myopathy have been described in donkeys or mules [157,159–162].

Tetanus is uncommon in donkeys [160]. Anecdotal reports state that donkeys are resistant to botulism; however, authors clinical experience challenges this notion [163,164]. This disease has also been observed in mules [165].

Neoplasia -mainly osteosarcoma- have also been reported as causing lameness [166–168]. Hypertrophic osteopathy or Marie's disease was diagnosed in a 16-year-old gelding with

- [50] Yildirim Y, Kirmizigil AH, Tan MT, Gokce E, Irmak K. Seroprevalence of equine viral arteritis in donkeys in Kars District, Turkey. *J Anim Vet Adv* 2008;7:1110–2.
- [51] Rushton JO, Kolodziejek J, Nell B, Nowotny N. Prevalence of asinine herpesvirus type 5 (AsHV-5) infection in clinically normal Lipizzaner horses. *Vet J* 2014;200:200–3.
- [52] Bell SA, Pusterla N, Balasuriya UBR, Mapes SM, Nyberg NL, MacLachlan NJ. Isolation of a gammaherpesvirus similar to asinine herpesvirus-2 (AHV-2) from a mule and a survey of mules and donkeys for AHV-2 infection. *Vet Microbiol* 2008;130:176–83.
- [53] Naureen A, Saqib M, Muhammad G, Hussain MH, Asi MN. Comparative evaluation of rose bengal plate agglutination test, mallein test, and some conventional serological tests for diagnosis of equine glanders. *J Vet Diagn Invest* 2007;19:362–7.
- [54] McCollum WH, Timoney PJ, Tengelsen LA. Clinical, virological and serological responses of donkeys to intranasal inoculation with the KY-84 strain of equine arteritis virus. *J Comp Pathol* 1995;112:207–11.
- [55] Paweska JT, Binns MM, Woods PSA, Chirnside ED. A survey for antibodies to equine arteritis virus in donkeys, mules and zebra using virus neutralisation (VN) and enzyme linked immunosorbent assay (ELISA). *Equine Vet J* 1997;29:40–3.
- [56] Bello A, Cunha AP, Braz GF, Lara M, Reis JKP, Haddad JPH, et al. Frequency of equine viral arteritis in Minas Gerais state, Brazil. *Arq Bras Med Vet Zootec* 2007;59:1077–9.
- [57] Khan I, Ali S, Gwida M, Elschner MC, Ijaz M, Anjum AA, et al. Prevalence of *Burkholderia mallei* in equids of remount depot, Sargodha, Pakistan. *Pak J Zool* 2013;45:1751–6.
- [58] Williams R, Duplessis DH, Vanwyngaardt W. Group-reactive ELISAs for detecting antibodies to African horsesickness and equine encephalosis viruses in horse, donkey, and zebra sera. *J Vet Diagn Invest* 1993;5:3–7.
- [59] Hamblin C, Salt JS, Mellor PS, Graham SD, Smith PR, Wohlsein P. Donkeys as reservoirs of African horse sickness virus. *Arch Virol Suppl* 1998;14:37–47.
- [60] Stefanetti V, Marenzoni ML, Lepri E, Coletti M, Sebastianelli M, Agnetti F, et al. Five fatal cases of primary pulmonary aspergillosis in Albino Asinara donkey foals. *J Equine Vet Sci* 2015;35:76–9.
- [61] Andersen S, Fogh J. Prevalence of lungworm *D. arnfieldi* (Cobbold 1884) in donkeys in Denmark and in horses in herds together with donkeys. *Nord Vet Med* 1981;33:484–91.
- [62] Lyons ET, Tolliver SC, Drudge JH, Swerczek TW, Crowe MW. Lungworms (*Dictyocaulus arnfieldi*) – prevalence in live equids in Kentucky. *Am J Vet Res* 1985;46:921–3.
- [63] Veneziano V, Di Loria A, Masucci R, Di Palo R, Brianti E, Gokbulut C. Efficacy of eprinomectin pour-on against *Dictyocaulus arnfieldi* infection in donkeys (*Equus asinus*). *Vet J* 2011;190:414–5.
- [64] Otranto D, Colwell DD, Milillo P, Di Marco V, Paradies P, Napoli C, et al. Report in Europe of nasal myiasis by *Rhinoestrus* spp. in horses and donkeys: seasonal patterns and taxonomical considerations. *Vet Parasitol* 2004;122:79–88.
- [65] Junge HK, Mitchell KJ, Hoey S. Diagnosis of severe traumatic brain injury using multimodal imaging in a donkey. *Equine Vet Educ* 2017;29:539–43.
- [66] Mozaffari AA, Samadieh H. Analysis of serum and cerebrospinal fluid in clinically normal adult miniature donkeys. *N Z Vet J* 2013;61:297–9.
- [67] Nollet H, Vanschandevijl K, Van Ham L, Vanderstraeten G, Deprez P. Role of transcranial magnetic stimulation in differentiating motor nervous tract disorders from other causes of recumbency in four horses and one donkey. *Vet Rec* 2005;157:656–8.
- [68] Garcia-Bocanegra I, Jaen-Tellez JA, Napp S, Arenas-Montes A, Fernandez-Morente M, Fernandez-Molera V, et al. West Nile fever outbreak in horses and humans, Spain, 2010. *Emerg Infect Dis* 2011;17:2397–9.
- [69] Jimenez-Clavero MA, Llorente F, Sotelo E, Soriguer R, Gomez-Tejedor C, Figuerola J. West Nile virus serosurveillance in horses in Donana, Spain, 2005 to 2008. *Vet Rec* 2010;167:379–80.
- [70] Monaco F, Lelli R, Teodori L, Pinoni C, Di Gennaro A, Polci A, et al. Re-emergence of West Nile virus in Italy. *Zoonoses Public Health* 2010;57:476–86.
- [71] Erlanger TE, Weiss S, Keiser J, Utzinger J, Wiedenmayer K. Past, present, and future of Japanese encephalitis. *Emerg Infect Dis* 2009;15:1–7.
- [72] Gulati BR, Singha H, Singh BK, Virmani N, Khurana SK, Singh RK. Serosurveillance for Japanese encephalitis virus infection among equines in India. *J Vet Sci* 2011;12:341–5.
- [73] Garcia-Bocanegra I, Busquets N, Napp S, Alba A, Zorrilla I, Villalba R, et al. Serosurvey of West Nile virus and other flaviviruses of the Japanese encephalitis antigenic complex in birds from Andalusia, Southern Spain. *Vector Borne Zoonotic Dis* 2011;11:1107–13.
- [74] Barbic L, Vilbic-Cavlek T, Listes E, Stevanovic V, Gjenero-Margan I, Ljubin-Sternak S, et al. Demonstration of Usutu virus antibodies in horses, Croatia. *Vector Borne Zoonotic Dis* 2013;13:772–4.
- [75] Rosa R, Costa EA, Marques RE, Oliveira TS, Furtini R, Bomfim MR, et al. Isolation of saint louis encephalitis virus from a horse with neurological disease in Brazil. *PLoS Neglect Trop Dis* 2013;7:e2537.
- [76] Gonzalez-Salazar D, Estrada-Franco JG, Carrara AS, Aronson JF, Weaver SC. Equine amplification and virulence of subtype IE Venezuelan equine encephalitis viruses isolated during the 1993 and 1996 Mexican epizootics. *Emerg Infect Dis* 2003;9:161–8.
- [77] Gibbs EPJ, MT L. Equine alphaviruses. In: Sellon DC, Long MT, editors. *Equine infectious diseases*. Philadelphia, Pennsylvania: Saunders Elsevier; 2007. p. 191–7.
- [78] De Siger J, Pulgar E, Medina-Gutierrez G, Perez-Barrientos M, Matheus T, Colmenares M. Inactivated vaccine of eastern equine encephalitis virus south American strains. II. Evaluation in donkeys in captivity. *Rev Cient Fac Ciencias Vet* 2005;15:310–8.
- [79] Mackenzie RM, Desiger J, Parrav D. Venezuelan equine encephalitis virus comparison of infectivity and virulence of strains V-38 and P676 in donkeys. *Am J Trop Med Hyg* 1976;25:494–9.
- [80] Ficorilli N, Studdert MJ, Crabb BS. The nucleotide sequence of asinine herpesvirus 3 glycoprotein G indicates that the donkey virus is closely related to equine herpesvirus 1. *Arch Virol* 1995;140:1653–62.
- [81] Paweska JT, Gerdes T, Van Heerden J. Serological relationship between a donkey alphaherpesvirus (isolate M7/91) and equid herpesvirus type 1 and 4. *J S Afr Vet Assoc* 1994;65:64–6.
- [82] Vengust M, Wen X, Bienzle D. Herpesvirus-associated neurological disease in a donkey. *J Vet Diagn Invest* 2008;20:820–3.
- [83] Binz T, Lebel J, Niemann H, Hagenau K. Sequence analyses of the p24 gene of Borna disease virus in naturally infected horse, donkey and sheep. *Virus Res* 1994;34:281–9.
- [84] Grabner A, Herzog S, Lange-Herbst H, Frese K. Antemortem diagnosis of Borna disease (BD) in equids. *Pferdeheilkunde* 2002;18:579–86.
- [85] Zhang L, Wang X, Zhan QL, Wang ZH, Xu MM, Zhu D, et al. Evidence for natural Borna disease virus infection in healthy domestic animals in three areas of western China. *Arch Virol* 2014;159:1941–9.
- [86] Barnard BJ. Symptoms of rabies in pets and domestic animals in South Africa and South West Africa. *J S Afr Vet Assoc* 1979;50:109–11.
- [87] Kirui G, Mulei CM, Abuom TO. Rabies in donkeys: a review. 45th Annual Scientific Conference and 11th World Veterinary Day Celebrations. Kenya. 2011.
- [88] Xie TB, Yu H, Wu J, Ming PG, Huang SJ, Shen ZJ, et al. Molecular characterization of the complete genome of a street rabies virus WH11 isolated from donkey in China. *Virus Genes* 2012;45:452–62.
- [89] Faizee N, Hailat NQ, Ababneh MMK, Hananeh WM, Muhaidat A. Pathological, immunological and molecular diagnosis of rabies in clinically suspected animals of different species using four detection techniques in Jordan. *Transbound Emerg Dis* 2012;59:154–64.
- [90] Fielding CL, Higgins JK, Higgins JC, McIntosh S, Scott E, Giannitti F, et al. Disease associated with equine coronavirus infection and high case fatality rate. *J Vet Intern Med* 2015;29:307–10.
- [91] Giannitti F, Diab S, Mete A, Stanton JB, Fielding L, Crossley B, et al. Necrotizing enteritis and hyperammonemic encephalopathy associated with equine coronavirus infection in equids. *Vet Pathol* 2015;52:1148–56.
- [92] Machacova T, Bartova E, Di Loria A, Sedlak K, Guccione J, Fulgione D, et al. Seroprevalence and risk factors of *Neospora* spp. in donkeys from Southern Italy. *Vet Parasitol* 2013;198:201–4.
- [93] Blanco RD, Patarroyo JH, Vargas MI, Cardona JA, Araujo LS, Gomez VE. Occurrence of anti-*Neospora* spp. Antibodies in donkeys (*Equus asinus*) in the state of Sucre-Colombia. *Arq Bras Med Vet Zootec* 2014;66:450–4.
- [94] Gennari SM, Pena HFJ, Lindsay DS, Lopes MG, Soares HS, Cabral AD, et al. Prevalence of antibodies against *Neospora* spp. and *Sarcocystis* neurona in donkeys from northeastern Brazil. *Rev Bras Parasitol Vet* 2016;25:109–11.
- [95] Laus F, Veronesi F, Passamonti F, Paggi E, Cerquetella M, Hyatt D, et al. Prevalence of tick borne pathogens in horses from Italy. *J Vet Med Sci* 2013;75:715–20.
- [96] Veronesi F, Morganti G, Ravagnan S, Laus F, Spaterna A, Diaferia M, et al. Molecular and serological detection of tick-borne pathogens in donkeys (*Equus asinus*) in Italy. *Vet Microbiol* 2014;173:348–54.
- [97] Dubey JP, Lindsay DS, Saville WJA, Reed SM, Granstrom DE, Speer CA. A review of *Sarcocystis* neurona and equine protozoal myeloencephalitis (EPM). *Vet Parasitol* 2001;95:89–131.
- [98] Mayhew IG, Brewer BD, Reinhard MK, Greiner EC. Verminous (*Strongylus vulgaris*) myelitis in a donkey. *Cornell Veterinarian* 1984;74:30–7.
- [99] Miller MM, Collatos C. Equine degenerative myeloencephalopathy. *Vet Clin North Am Equine Pract* 1997;13:43–52.
- [100] Verdonck F, Merlevede I, Goddeeris BM, Deprez P, Cox E. Vitamin E deficiency and decreased serum immunoglobulin concentrations in a population of donkeys. *Vet Rec* 2007;160:232–3.
- [101] Rosiles MR, Bautista J, Fuentes VO, Ross F. An outbreak of equine leukoencephalomalacia at Oaxaca, Mexico, associated with fumonisin B1. *J Vet Med A Physiol Pathol Clin Med* 1998;45:299–302.
- [102] Nobre VMD, Riet-Correa F, Barbosa JM, Dantas AFM, Tabosa IM, Vasconcelos JS. Poisoning by *Crotalaria retusa* (Fabaceae) in Equidae in the semiarid region of Paraíba. *Pesqui Vet Bras* 2004;24:132–43.
- [103] Baker AM, Shaheed IB, RMS K. Survey on lesions of urinary system in donkeys. *Egypt J Comp Pathol Clin Path* 2008;21:147–66.
- [104] Mekibib B, Abraham E, Kassaye A, Tesfaye D, Amenu K. Clinicopathological findings associated with urinary tract problems in working donkeys, Southern Ethiopia: a case study. *Comp Clin Path* 2015;24:417–22.
- [105] Nelson BB, Ferris RA, McCue PM, Leise BS. Surgical management of atresia ani and perineal hypospadias in a miniature donkey foal. *Equine Vet Educ* 2015;27:525–9.
- [106] Van den Brand JM, Hendriks-Onstein WK, Kik MJ, Grone A, van Sloet OO. Renal cysts, nephrolithiasis, and ovarian cysts in a donkey suspected of having been sexually abused. *Tijdschr Diergeneesk* 2006;131:730–5.

- [107] Frei S, Kummer M, Furst A, Eser MW. Cystoliths in the horse – a retrospective study. *Pferdeheilkunde* 2016;32:124–31.
- [108] Schumacher J, Schumacher J, Schmitz D. Macroscopic haematuria of horses. *Equine Vet Educ* 2002;14:201–10.
- [109] Arnold CE, Taylor T, Chaffin MK, Schott HC, Caron JP. Nephrectomy via ventral median celiotomy in equids. *Vet Surg* 2013;42:275–9.
- [110] Schott HC. Red Urine: disorders you may have never considered. Proceedings of the 17th Congress of the Italian Association of Equine Veterinarians. Montesilvano, Italy. 2011.
- [111] Karanja DNR, Ngatia TA, Wandera JG. Donkey Klossiellosis in Kenya. *Vet Parasitol* 1995;59:1–5.
- [112] Rezaie A, Bahrami S, Ansari M. Klossiella equi in a donkey—a first case report from Iran. *Trop Biomed* 2013;30:543–6.
- [113] Benkirane A, Noury S, Hartskeerl RA, Goris MGA, Ahmed A, Nally JE. Preliminary investigations on the distribution of *Leptospira* serovars in domestic animals in North-west Morocco. *Transbound Emerg Dis* 2016;63: E178–84.
- [114] Mozaffari AA, Derakhshanfar A, Alinejad A, Morovati M. A comparative study on the adverse effects of flunixin, ketoprofen and phenylbutazone in miniature donkeys: haematological, biochemical and pathological findings. *N Z Vet J* 2010;58:224–8.
- [115] El-Ashker M, Abdelhamid F, Risha E, Salama M, El-Sebaei M. Vitamin C ameliorates gentamicin-induced acute kidney injury in equines: an experimental study. *J Equine Vet Sci* 2015;35:238–43.
- [116] Kojouri GA, Sharifi S. Preventing effects of nano-selenium particles on serum concentration of blood urea nitrogen, creatinine, and total protein during intense exercise in donkey. *J Equine Vet Sci* 2013;33:597–600.
- [117] Laus F, Paggi E, Marchegiani A, Cerquetella M, Spaziante D, Faillace V, Tesi B. Ultrasonographic biometry of the eyes of healthy adult donkeys. *Vet Rec* 2014;174:326.
- [118] Scantlebury CE, Aklilu N, Reed K, Knottenbelt DC, Gebreab F, Pinchbeck GL. Ocular disease in working horses in Ethiopia: a cross-sectional study. *Vet Rec* 2013;172:99.
- [119] Mancuso LA, Lassaline M, Scherrer NM. Porcine urinary bladder extracellular matrix grafts (ACell Vet (R) Corneal Discs) for keratomalacia in 17 equids (2012–2013). *Vet Ophthalmol* 2016;19:3–10.
- [120] Patipa LA, Sherlock CE, Witte SH, Pirie GD, Berghaus RD, Peroni JF. Risk factors for colic in equids hospitalized for ocular disease. *J Am Vet Med Assoc* 2012;240:1488–93.
- [121] Edwards S, Clode AB, Gilger BC. Equine eosinophilic keratitis in horses: 28 cases (2003–2013). *Clin Case Rep* 2015;3:1000–6.
- [122] Tabatabaei Naeini A, Daroukolaei NZ, daroukolaei OZ, MR T. Effect of amidotrizoate (Urographin 76%) on tear fluid total protein, lysozyme, sodium and potassium concentrations and tear electrophoresis after dacryocystography in donkeys Bulg. *J Vet Med* 2009;12:79–85.
- [123] Tabatabaei Naeini A, Daroukolaei NZ. Effect of iohexol on tear production and the fluctuations of Schirmer tear test values in clinically normal donkeys. *Comp Clin Path* 2008;18:59–61.
- [124] Tabatabaei Naeini A, Haghshenas MR, Ziaei Daroukolaei MR, Ouji N, Ziaei Daroukolaei N. Iohexol effects on tear biochemical profiles in normal large animal model. *J Mazandaran Uni Med Sci* 2008;18:46–54.
- [125] Soliman R, Ebeid M, Essa M, Elhamid MAA, Khamis Y, Said AH. Ocular histoplasmosis due to *Histoplasma farciminosum* in Egyptian donkeys. *Mycoses* 1991;34:261–6.
- [126] Foti M, Fischella V, Giacobello C. Detection of methicillin-resistant *Staphylococcus aureus* (MRSA) in the microbial flora from the conjunctiva of healthy donkeys from Sicily (Italy). *Vet Ophthalmol* 2013;16: 89–92.
- [127] Laus F, Faillace V, Attili AR, Spaterna A, Tesi B, Cuteri V. Conjunctival bacterial and fungal flora in healthy donkeys in Central Italy. *Large Anim Rev* 2016;22:137–42.
- [128] Nardoni S, Sgorbini M, Barsotti G, Corazza M, Mancianti F. Conjunctival fungal flora in healthy donkeys. *Vet Ophthalmol* 2007;10:207–10.
- [129] Misk NA, Makady FM, Sayed AM. Cataract extraction in the donkey – evaluation of 19 cases. *Assiut Vet Med J* 1992;27:209–21.
- [130] Martin-Suarez E, Galan A, Gallardo Galero JM, Mollada J. Bilateral typical complete colobomas in a donkey: Retinographic and fluorangiographic description. *Vet Ophthalmol* 2009;12:338–42.
- [131] Donisa A, Muste A, Beteg F, Krupaci A. Morphological characteristics of horse and donkey eye fundus. *Vet Med* 2009;55:149–54.
- [132] Hussein HS, Elsammani SE. *Onchocerca railieti* prevalence and pathology in sudanese donkeys. *J Comp Pathol* 1985;95:345–51.
- [133] Marzok MA, Desouky A-RY. Ocular infection of donkeys (*Equus asinus*) with *Setaria equina*. *Trop Anim Health Prod* 2009;41:859–63.
- [134] Abu-Seida AM, Ahmed KA. Dermoid cysts in donkeys. *Vet Med J* 2007;55:25.
- [135] White SD. Donkey dermatology. *Vet Clin North Am Equine Pract* 2013;29: 703–8.
- [136] Kaleibar MT, Eshghi D, Helan JA. A survey on the status of equine skin tumors and associated epidemiological factors in Iran. *Comp Clin Path* 2015;24: 1407–15.
- [137] Abdalla WG, Suliman EA, Abdo EL, Gabbar MA. A report on *Trichophyton verrucosum* in donkeys in the Sudan. *Sudan J Vet Res* 2005;20:83–5.
- [138] Knottenbelt DC. Skin disorders of donkeys. In: Matthews NS, Taylor TS, editors. *Veterinary care of donkeys*. IVIS; 2005.
- [139] Elsheikha HM, Mackenzie CD, Rosenthal BM, Marteniuk JV, Steficek B, Windsor S, et al. An outbreak of besnoitiosis in miniature donkeys. *J Parasitol* 2005;91:877–81.
- [140] Davis WP, Peters DF, Dunstan RW. Besnoitiosis in a miniature donkey. *Vet Dermatol* 1997;8:139–43.
- [141] Ness SL, Peters-Kennedy J, Schares G, Dubej JP, Mittel LD, Mohammed HO, et al. Investigation of an outbreak of besnoitiosis in donkeys in northeastern Pennsylvania. *J Am Vet Med Assoc* 2012;240:1329–37.
- [142] Yeruham I, Braverman Y, Orgad U. Field observations in Israel on hypersensitivity in cattle, sheep and donkeys caused by *Culicoides*. *Aust Vet J* 1993;70:348–52.
- [143] Pritchard JC, Lindberg AC, Main DCJ, Whay HR. Assessment of the welfare of working horses, mules and donkeys, using health and behaviour parameters. *Prev Vet Med* 2005;69:265–83.
- [144] Burn CC, Dennison TL, Whay HR. Environmental and demographic risk factors for poor welfare in working horses, donkeys and mules in developing countries. *Vet J* 2010;186:385–92.
- [145] Reix CE, Burn CC, Pritchard JC, Barr ARS, Whay HR. The range and prevalence of clinical signs and conformation associated with lameness in working draught donkeys in Pakistan. *Equine Vet J* 2014;46:771–7.
- [146] Fowler J. Trimming donkeys feet. *Equine Vet Educ* 1995;7:18–21.
- [147] Thiemann A, Rickards K. Donkey hoof disorders and their treatment. *Clin Practice* 2013;35:134–40.
- [148] Collins S, Dyson SJ, Murray RC, Newton JR, Burden F, Trawford AF. Development of a quantitative multivariable radiographic method to evaluate anatomic changes associated with laminitis in the forefeet of donkeys. *Am J Vet Res* 2012;73:1207–18.
- [149] Cripps PJ, Eustace RA. Radiological measurements from the feet of normal horses with relevance to laminitis. *Equine Vet J* 1999;31:427–32.
- [150] Collins SN, Dyson SJ, Murray RC, Burden F, Trawford A. Radiological anatomy of the donkey's foot: Objective characterisation of the normal and laminitic donkey foot. *Equine Vet J* 2011;43:478–86.
- [151] Walmsley JP. Flexural deformities of distal interphalangeal joints in a group of young donkeys. *Equine Vet Educ* 1995;7:4–6.
- [152] Brogniez L, Launois MT, Perrin RAR, Horn L, Clegg PD, Coomer R, et al. Treatment of a severe distal forelimb wound presenting with extensive laceration and distal interphalangeal joint luxation in a donkey. *Pferdeheilkunde* 2012;28:160.
- [153] Garcia-Lopez JM. Coxofemoral luxations in the horse: surgical options and challenges. *Equine Vet Educ* 2010;22:554–6.
- [154] Amitrano F, Gutierrez-Nibeyro S, Joslyn SK. Radiographic diagnosis of craniodorsal coxofemoral luxation in standing equids. *Equine Vet Educ* 2014;26:255–8.
- [155] Toth F, Adair HS, Holder TEC, Schumacher J. Femoral head ostectomy to treat a donkey for coxofemoral luxation. *Equine Vet Educ* 2007;19:478–81.
- [156] Drouard F, Feige K, Soldati G, Schwarzwald C, Fluckiger M. Thoracic intervertebral disc protrusion in a donkey. *Vet Rec* 2003;152:660–1.
- [157] Valentine BA. Pathologic findings in equine muscle (excluding polysaccharide storage): a necropsy study. *J Vet Diagn Invest* 2008;20:572–9.
- [158] D'Angelis FHF, Ferraz GC, Santos EB, Steque MFL, Feringer-Junior WH, Queiroz-Neto A. Standardization of metachromatic staining method of myofibrillar ATPase activity of myosin to skeletal striated muscle of mules and donkeys. *Pesqui Vet Bras* 2014;34:917–22.
- [159] Valentine BA, Habecker PL, Patterson JS, Njaa BL, Shapiro J, Holshuh HJ, et al. Incidence of polysaccharide storage myopathy in draft horse-related breeds: a necropsy study of 37 horses and a mule. *J Vet Diagn Invest* 2001;13:63–8.
- [160] Kay G, Knottenbelt DC. Tetanus in equids: a report of 56 cases. *Equine Vet Educ* 2007;19:107–12.
- [161] van Galen G, Pitel CM, Saegerman C, Patarin F, Amory H, Baily JD, et al. European outbreaks of atypical myopathy in grazing equids (2006–2009): Spatiotemporal distribution, history and clinical features. *Equine Vet J* 2012;44:614–20.
- [162] Mellor NE, Bladon B, Foote AK, O'Meara B. Successful treatment of chronic grass sickness in a donkey. *Equine Vet Educ* 2013;25:628–32.
- [163] Fourie J, Snyman P. Botulism in equines due to contaminated drinking water and hay. *J S Afr Vet Assoc* 1939;10:132–5.
- [164] Kopera D. Botulinum toxin historical aspects: from food poisoning to pharmaceutical. *Int J Dermatol* 2011;50:976–80.
- [165] Schoenbaum M, Hall S, Glock R, Grant K, Jenny AL, Schiefer TJ, et al. An outbreak of type C botulism in 12 horses and a mule. *J Am Vet Med Assoc* 2000;217:365–8.
- [166] Nelson AM, Baker D. Pedal osteosarcoma in a donkey. *Vet Pathol* 1998;35: 407–9.
- [167] Kilcoyne I, Wilson M, Terzo E, David F. Osteosarcoma of the proximal radius in a donkey. *Equine Vet Educ* 2010;22:125–9.
- [168] Mair TS, Dyson SJ, Fraser JA, Edwards GB, Hillyer MH, Love S. Hypertrophic osteopathy (Marie's disease) in Equidae: a review of twenty-four cases. *Equine Vet J* 1996;28:256–62.
- [169] Choubisa SL. Osteodental fluorosis in domestic horses and donkeys in Rajasthan, India. *Fluoride* 2010;43:5–12.