

# Negative correlation between X-linked inhibitors of apoptosis and second mitochondria-derived activator of caspase expression levels in cervical carcinoma and cervical intraepithelial neoplasia

XUE-JING JIN<sup>1</sup>, PING-SHENG CAI<sup>1</sup>, SHU-PIN ZHU<sup>1</sup>, LI-JIE WANG<sup>1</sup> and HUA ZHU<sup>2</sup>

<sup>1</sup>Departments of Obstetrics and Gynecology, Wenzhou Hospital of Integrated Traditional Chinese and Western Medicine, Wenzhou; <sup>2</sup>Departments of Obstetrics and Gynecology, The First Affiliated Hospital of Wenzhou Medical University, Wenzhou, Zhejiang 325000, P.R. China

Received October 27, 2015; Accepted April 13, 2017

DOI: 10.3892/ol.2017.6878

**Abstract.** X-linked inhibitors of apoptosis (XIAP) and second mitochondria-derived activator of caspase (Smac) have been widely reported to serve roles in the development of cervical carcinoma. The present study analyzed the associations between the expression levels of XIAP and Smac in normal cervical epithelium, cervical intraepithelial neoplasia (CIN) and cervical carcinoma. Immunohistochemistry staining of formalin-fixed, paraffin-embedded tissue sections was performed in order to analyze the expression levels of XIAP and Smac in 15 cases of normal cervical tissues, 69 cases of CIN and 76 cases of cervical carcinoma. All the tissue samples were confirmed by pathological diagnosis. The association of XIAP and Smac expression levels was analyzed using one-way analysis of variance,  $\chi^2$  tests and Spearman's  $\rho$  for the nonparametric bi-variant correlation analysis. Overall survival was determined using the log-rank test and Kaplan-Meier survival curves. The expression level of XIAP was increased in CIN and cervical carcinoma tissues compared with normal cervical tissues, whereas Smac demonstrated a converse expression pattern to XIAP in these tissues. The positive staining level of XIAP protein was increased in grade 3 CIN compared with that in grade 1-2 CIN, and was significantly higher in the less-differentiated tissue of cervical carcinoma compared with the well- or medium-differentiated tissues ( $P < 0.05$ ). The staining level was also significantly increased in cervical carcinoma with stage 2b-3 compared with tissues from stage 1-2a carcinoma ( $P < 0.05$ ). The expression levels of Smac were in opposition to these results. XIAP was associated

with pelvic lymph node metastasis, whereas no association was identified with Smac expression. The expression level of XIAP was significantly and negatively associated with cell survival time in cervical carcinoma, whereas the expression level of Smac was significantly and positively associated with cell survival time in cervical carcinoma. Therefore, XIAP and Smac may participate in the development of cervical cancer. The expression levels of XIAP and Smac were significantly and inversely associated. This may be useful in early diagnosis, evaluation of surgery and chemotherapy and the prognosis of cervical carcinoma.

## Introduction

Cervical carcinoma is the second most prevalent malignant tumor in females and has a high incidence rate in developing countries (1,2). There is a continuous development process from benign lesions to cervical intraepithelial neoplasia (CIN) and finally carcinoma (3). In total ~30% of CIN cases are resolved and only a small part of CIN cases develop into carcinoma (4). Previous studies have demonstrated that human papilloma virus (HPV) infection and the inhibition of apoptosis were involved in the occurrence and development of cervical cancer (5-9). CIN is a group of precancerous lesions that are closely associated with cervical carcinoma, including cervical dysplasia and primary cervical carcinoma. However, the pathogenesis of CIN and carcinoma remains to be elucidated. Ongoing research aims to elucidate the mechanism underlying the development of cervical cancer and to develop reliable biomarkers of cervical cancer for timely diagnosis and treatment.

Apoptosis, a cellular program that serves an important role in numerous pathological processes, including tumorigenesis, involves the sequential activation of a family of cysteine proteases known as caspases, whose proteolytic activity promotes cell death (10). The activity of these apoptotic proteins is downregulated by inhibitory proteins, termed the inhibitors of apoptosis proteins (IAPs). IAPs are highly conserved through evolution and have been reported to bind caspases and prevent caspase activation to control the induction of apoptosis (11). To date, numerous IAPs

---

*Correspondence to:* Professor Hua Zhu, Departments of Obstetrics and Gynecology, The First Affiliated Hospital of Wenzhou Medical University, 2 Fuxue Lane, Wenzhou, Zhejiang 325000, P.R. China  
E-mail: zhuhua06@sohu.com

**Key words:** cervical carcinoma, cervical intraepithelial neoplasia, X-linked inhibitors of apoptosis, second mitochondria-derived activator of caspase

have been identified, which include X-linked inhibitor of apoptosis (XIAP), cellular IAP-1 (c-IAP1), cellular IAP-2 (c-IAP2), testis specific IAP (Ts-IAP), survivin, livin and BRUCE/Apollon. Among these, XIAP, as the most potent suppressor of apoptosis, has been well characterized. Its baculoviral IAP repeat (BIR) domains were reported to target and inhibit numerous caspases (12). In addition, a previous study demonstrated that the RING domain of XIAP has E3 ubiquitin ligase activity, which destabilizes caspases following interaction with the proteasome (13).

Second mitochondria-derived activator of caspase (Smac), also termed as direct inhibitor of apoptosis-binding protein with low PI (DIABLO), was identified from mitochondria-released pro-apoptotic proteins (14). Smac is located in the intermembrane space in the mitochondria and is released into the cytosol in the presence of apoptotic stimuli. There, Smac interacts with IAPs and induces the activation of caspases. Previous studies have revealed that Smac interacts with mammalian IAPs, including XIAP, c-IAP1, c-IAP2, melanoma-IAP and survivin, and disrupts the caspase inhibition activity of IAPs (9,15-20). Furthermore, Smac promotes apoptosis by binding to c-IAP1 and c-IAP2 via rapid degradation by autoubiquitination (21). The aforementioned findings indicate the significance of the balance between IAPs and Smac.

Previous studies have identified an association between the expression levels of XIAP and Smac in cervical carcinoma suggesting there is a close association between XIAP and Smac in the generation and development of tumors (22,23). The increased expression level of XIAP was demonstrated to serve an important role in the carcinogenesis and the development of cervical carcinoma, which is associated with no or decreased Smac protein expression levels (24,25). However, the correlation analysis of these two protein factors in cervical intraepithelial neoplasia and cervical carcinoma prognosis remains to be elucidated.

The present study evaluated the expression levels of XIAP and Smac in normal cervical epithelium, tissues of cervical intraepithelial neoplasia and cervical carcinoma, and analyzed the association between their expression levels and carcinogenesis, development and prognosis of cervical carcinoma.

## Materials and methods

**Tumor samples.** A total of 160 cervical tissue samples were obtained from patients consecutively recruited at The First Affiliated Hospital of Wenzhou Medical University (Wenzhou, China) between January 2007 and March 2010. A total of 69 tissue samples were associated with CIN (11 with CIN1, 25 with CIN2 and 33 with CIN3) and 76 tissue samples were identified as cervical carcinoma (62 to squamous cell and 14 to adenocarcinoma). A total of 15 cases of normal cervical tissues were used as the control. The age of patients ranged from 18-79 years, with an average of 40.05. None of the patients received preoperative radiotherapy, chemotherapy or other adjuvant therapy, and there were no significant baseline differences between the 3 groups in age, body weight and the existence of other internal diseases (Table I). The stages of cervical carcinoma were categorized according to the International Gynecology and Obstetrics Federation

(FIGO) system (26) (<http://www.igo.org/>). The samples comprised 8 in stage 1A, 19 in 1B, 29 in 2A, 12 in 2B and 8 in stage 3, including 34 cases of exogenic type, 13 endogenous types, 18 ulcerative type and 11 cervical canal tissue samples. According to the histopathological grade, the tumors included 13 well-differentiated, 26 middle-differentiated and 37 low-differentiated cases. The present study was approved by the Ethics Committee of Wenzhou Hospital of Integrated Chinese and Western Medicine (Wenzhou, China). Written informed consent was obtained from all patients prior to enrollment in the present study.

**Histology.** Histopathology was graded according to the World Health Organization (27) classification system. The tissue samples were diagnosed by two senior pathologists from the First Affiliated Hospital of Wenzhou Medical University who were blinded to the method at the time of examination. If the two diagnoses did not match, then the two additional senior pathological experts from the same hospital were invited to discuss in order to make the final diagnosis.

**Immunohistochemistry.** Tissue sections <1 cm<sup>3</sup> were obtained from fresh cervical CIN and cervical cancer tissue samples, fixed in 10% neutral formalin at room temperature for 24 h, then dehydrated, embedded in paraffin, deparaffinized and rehydrated in graded ethanol (100, 95, 85 and 75%). Antigen retrieval was performed by heating the slides (10 min in a microwave oven, 122 mm) in citrate buffer at pH 6.0. Endogenous peroxidase activity was blocked with 0.3% H<sub>2</sub>O<sub>2</sub> for 10 min at room temperature. Sections were incubated with primary antibodies at 1:200 dilutions (anti-XIAP; A-7: sc-55550) and anti-Smac (V-17: sc-12683); Santa Cruz Biotechnology, Inc., Dallas, TX, USA) overnight at 4°C, washed with PBS and re-incubated with a secondary antibody horseradish peroxidase (32230; dilution, 1:500; Thermo Fisher Scientific, Inc., Waltham, MA, USA) for 30 min at 37°C. Diaminobenzidine staining was performed under close monitoring for 5 min at room temperature. Slides were finally counterstained with hematoxylin at room temperature for 2 min and dehydrated in graded ethanol (75, 85, 95 and 100%). Finally, the slides were imaged using an AperioScanScope GL (Aperio Technologies, Vista, CA, USA) at x400 magnification.

**Evaluation of XIAP/Smac expression levels.** XIAP/Smac immunoreactivity was evaluated by two pathologists come from the First Affiliated Hospital of Wenzhou Medical University blind to the procedure. To further validate the staining of XIAP/Smac in tumor cells, the expression intensity was graded according to the intensity of positive control and the percentage of positive tumor cells. A total of 6 fields of view were randomly selected and analyzed. The slides were first assessed for expression intensity (0, negative; 1, less intense compared with positive control; 2, equal intensity to control; 3, more intense compared with control). Subsequently, the slides were assessed for the rate of positive cells (0, <5%; 1, 5-25%; 2, 26-50%; 3, >50%; magnification, x400) using an AperioScanScope GL (Aperio Technologies). The multiplication product of two points was used as the final assessment [0, negative (-); 1-4, weakly positive (+); 5-8, moderate positive (++)]; 9-12, strong positive (+++)].

Table I. Study baseline data.

Variable	Cervical carcinoma	CIN	Normal cervical tissue
No. patients (n)	76	69	15
Average age $\pm$ standard deviation (years)	42.3 $\pm$ 3.5	39.5 $\pm$ 6.9	38.7 $\pm$ 4.3
No. patients with hypertension	15	18	3
No. patients with Diabetes Mellitus	10	7	2
No. patients that smoke	1	1	0
No. patients that drink alcohol	4	6	2
Average body weight $\pm$ standard deviation (kg)	52.3 $\pm$ 5.9	55.4 $\pm$ 3.7	54 $\pm$ 4.7

CIN, cervical intraepithelial neoplasia.

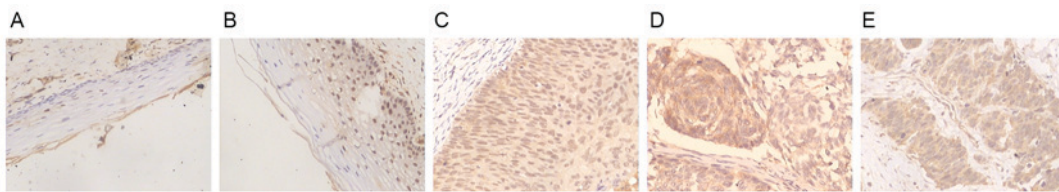


Figure 1. XIAP expression levels in cervical cancer samples. Tissue sections  $<1\text{ cm}^3$  were obtained from all fresh cervical tissue samples for immunohistochemistry analysis. (A) XIAP-negative staining in normal cervical tissue. (B) Weak XIAP-positive staining in CIN I-II cervical carcinoma tissue. (C) Moderate XIAP-positive expression level in CIN III cervical carcinoma tissue. (D) Strong XIAP-positive expression level in cervical squamous carcinoma tissue. (E) XIAP-positive expression level in cervical adenocarcinoma tissue. Magnification,  $\times 200$ . XIAP, X-linked inhibitors of apoptosis; CIN, cervical intraepithelial neoplasia.

**Statistical analysis.** In order to investigate the association between clinical characteristics and XIAP/Smac-positive immunostaining, the present study used one-way analysis of variance,  $\chi^2$  tests and Spearman's  $\rho$  methods for the nonparametric bivariate correlation analysis. The survival curve was drawn using the Kaplan-Meier method, and the survival was analyzed by log-rank test. The statistical package, SPSS version 17.0 (SPSS, Inc., Chicago, IL USA), was used for data analysis.  $P < 0.05$  was considered to indicate a statistically significant difference, or  $\alpha = 0.05$  for bilateral analysis.

## Results

**XIAP expression level and prediction of clinical outcome in cervical carcinoma.** The present study demonstrated that XIAP was typically localized in the cytoplasm, and its expression level gradually increased in normal cervical tissue to CIN and then with increasing cervical cancer stages, with the increasing development of pathogenesis. Compared with negative or weak staining in normal cervical tissue and CIN I-II cervical carcinoma, the immunostaining intensity of XIAP was moderate or strong in CIN III cervical carcinoma, squamous carcinoma and adenocarcinoma (Fig. 1A-E). Cervical intraepithelial neoplasia was also positively stained with XIAP (data not shown). The expression level of XIAP exhibited an increase from normal cervical squamous epithelium (20%, 3/15) to CIN stages (53.6%, 37/69) and again in cervical carcinoma (77.6%, 59/76; Table II). The expression level of XIAP among the 3 groups was significantly different ( $\chi^2 = 27.88$ ;  $P < 0.001$ ), and significant differences were identified between any two groups ( $P < 0.05$ ).

As XIAP demonstrated increasing levels of expression in CIN I-II and CIN III cervical carcinoma, the present study suggested that XIAP expression level was associated with the FIGO stage of the cancer. There were 36 CIN I-II and 33 CIN III types in the tissue samples, and 38.9% (14/36) of CIN I-II tissue samples were stained positively for XIAP, which was reduced compared with the number of CIN III tissue samples positively for XIAP (69.7%, 23/33; Table I). This indicated that the expression level of XIAP in CIN III was significantly increased compared with that in CIN I-II tissue samples ( $\chi^2 = 6.571$ ;  $P = 0.016$ ).

CIN was closely associated with precancerous lesions, including cervical atypical hyperplasia, which is further classified into poorly, moderately and well-differentiated grades (28). In the present study, the positive expression level of XIAP in well-differentiated cervical atypical hyperplasia (66.7%, 26/39) was significantly different compared with that in poorly differentiated hyperplasia (89.2%, 33/37;  $\chi^2 = 5.546$ ;  $P = 0.027$ ; Table II).

The expression level of XIAP was associated with the histological grade, the clinical stage and the presence of pelvic lymph node metastasis of the cervical carcinoma. A total of 67.8% (40/59) of cervical carcinoma with the clinical stage of I-IIa were stained positively for XIAP, whereas 95.0% (19/20) in stage I Ib-III were XIAP-positive (Table II) and this difference was statistically significant ( $\chi^2 = 4.715$ ;  $P = 0.032$ ). The positive expression level of XIAP in the lymph node metastasis group was 81.0% (17/21), which was significantly higher compared with tissue samples without lymph node metastasis in cervical cancer groups (37.9%, 11/29;  $\chi^2 = 9.149$ ;  $P = 0.004$ ; Table II).

Table II. XIAP and Smac expression levels in cervical cancer tissue samples.

Characteristics	No. patient samples n	No. XIAP-positive samples		No. Smac-positive samples	
		n (%)	P-value	n (%)	P-value
Normal cervical tissue	15	3 (20)	<0.01 <sup>a</sup>	15 (100)	<0.01 <sup>a</sup>
FIGO stage	69	37 (53.6)	<0.05 <sup>b</sup>	39 (56.5)	<0.05 <sup>b</sup>
CIN I	11	3 (27.3)		8 (72.7)	
CIN II	25	11 (44.0)		16 (64.0)	
CIN III	33	23 (69.7)		15 (45.5)	
Invasive cervical carcinoma	76	59 (77.6)		27 (35.5)	
Pathological type			>0.05		>0.05
Squamous carcinoma	62	48 (77.4)		21 (33.9)	
Adenocarcinoma	14	11 (78.6)		6 (42.9)	
Tumor grade			<0.05 <sup>b</sup>		<0.05 <sup>b</sup>
Well differentiated	13	6 (46.2)		6 (46.2)	
Moderately differentiated	26	20 (76.9)		9 (34.6)	
Poorly differentiated	37	33 (89.2)		12 (32.4)	
Clinical stage			<0.05 <sup>b</sup>		<0.05 <sup>b</sup>
Ia	8	5 (62.5)		4 (50.0)	
Ib	19	12 (63.2)		10 (52.6)	
IIa	29	23 (79.3)		10 (34.5)	
IIb	12	11 (91.7)		2 (25.0)	
III	8	8 (100.0)		1 (12.5)	
Tumor growth type			>0.05		>0.05
Exogenic type	34	26 (76.5)		13 (38.2)	
Endogenous type	13	11 (84.6)		4 (30.8)	
Ulcerative type	18	14 (77.8)		6 (33.3)	
Cervical canal	11	8 (72.7)		4 (36.4)	
Lymphatic metastasis			<0.01 <sup>c</sup>		>0.05
Negative	29	11 (37.9)		11 (37.9)	
Positive	21	17 (81.0)		9 (42.9)	

<sup>a</sup>P<0.01 among three groups; <sup>b</sup>P<0.05 between two groups; <sup>c</sup>P<0.01 between two groups. Smac, second mitochondria-derived activator of caspase; CIN, cervical intraepithelial neoplasia; FIGO, International Gynecology and Obstetrics Federation.

The present study further analyzed the association between XIAP expression levels and the pathology or tumor type of cervical carcinoma. The positive expression level of XIAP in squamous carcinoma and adenocarcinoma was 77.4% (48/62) and 78.6% (11/14), respectively (Table II;  $\chi^2=0.009$ ; P=1.000). The positive expression levels of XIAP in tumor types of cervical carcinoma, including exogenic, endogenous, ulcerative and cervical canal, were 76.5% (26/34), 84.6% (11/13), 77.8% (14/18) and 72.7% (8/11), respectively (Table II); however, this difference was not statistically significant ( $\chi^2=0.544$ ; P=0.909).

*Smac expression levels and the prediction of clinical outcome in cervical carcinoma.* Smac is primarily localized in the cytoplasm (14,29). The expression intensity of Smac was strong in normal cervical tissue, whereas it decreased with an increase in CIN stage and in cervical cancer, including in cervical squamous carcinoma and adenocarcinoma tissue

samples (Fig. 2A-E). The positive expression level of Smac in normal cervical tissue samples, CIN stage tissue samples and cervical cancer tissue samples was 100.00% (15/15), 56.5% (39/69) and 35.5% (27/76), respectively (Table II). The expression level of Smac among the three groups was significantly different ( $\chi^2=22.521$ ; P<0.001) and significant differences also existed between any two groups (P<0.01).

The results of the present study demonstrated that Smac had significantly increased expression in CINII tissues (66.7%, 24/36) compared with in CINIII cervical carcinoma tissues (45.5%, 15/33;  $\chi^2=5.115$ ; P=0.030; Table II). Smac positive expression levels in well-differentiated (48.7%, 19/39) and poorly differentiated cervical atypical hyperplasia (21.6%, 8/37) were significantly different ( $\chi^2=6.086$ ; P=0.017; Table II). The clinical data revealed that 42.9% (24/56) of tissues from clinical stage I-IIa exhibited positive staining of Smac and was significantly increased compared with that of clinical stage IIb-III (15.0%, 3/20;  $\chi^2=4.993$ ; P=0.031).

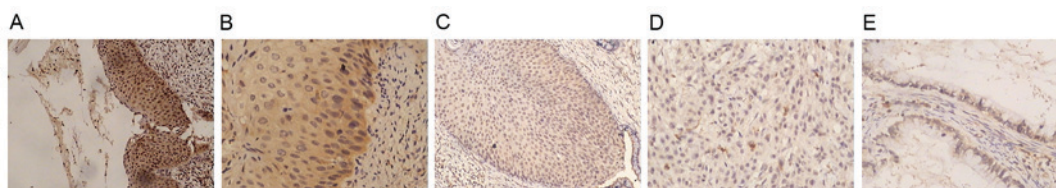


Figure 2. Smac expression levels in cervical cancer tissue samples. Tissue sections  $<1\text{ cm}^3$  were obtained from fresh cervical CIN and cervical cancer tissue samples and normal cervical tissues for immunohistochemistry analysis. (A) Strong Smac-positive expression level in normal cervical tissue. (B) Moderate Smac-positive expression level in CINII cervical carcinoma tissue. (C) Weak Smac-positive expression level in CINIII cervical carcinoma tissue. (D) Weak Smac-positive expression level in cervical squamous carcinoma tissue. (E) Weak Smac-positive expression level in cervical adenocarcinoma tissue. Magnification, x200. Smac, second mitochondria-derived activator of caspase; CIN, cervical intraepithelial neoplasia.

Smac expression level was further analyzed in squamous carcinoma (33.9%, 21/62) and adenocarcinoma (42.9%, 6/14) but did not demonstrating a significant difference ( $\chi^2=0.403$ ;  $P=0.549$ ; Table II). The present study also revealed that the positive expression level of Smac in the lymphatic metastasis group was 42.9% (9/21), similar to those without lymph node metastasis (37.9%, 11/29;  $\chi^2=0.123$ ;  $P=0.776$ ; Table II). There was no significant difference among the types of cervical carcinoma, which included exogenic (38.2%, 13/34), endogenous (30.8%, 4/13), ulcerative (33.3%, 6/18) and cervical canal types (36.4%, 4/11;  $\chi^2=2.259$ ;  $P=0.520$ ; Table II).

*Associations between the expression levels of XIAP and Smac and the prognosis of cervical cancer.* The survival time in the group with high XIAP expression levels was significantly reduced compared with that of the group with low XIAP expression levels (log rank=4.291;  $P=0.038$ ; Fig. 3). Conversely, the survival time in the group with high Smac expression levels was significantly lower compared with that in the group with low Smac expression levels (log rank=4.403;  $P=0.036$ ; Fig. 4).

*Associations between XIAP and Smac expression levels.* Among the 76 cervical carcinoma cases, 19 XIAP positively-stained tumors were negative for Smac, whereas 5 XIAP-negative tumors were identified to be positively-stained for Smac. The difference was statistically significant (Spearman coefficient of correlation,  $r=-0.291$ ;  $P=0.011$ ), which indicated that the expression levels of XIAP and Smac were negatively associated with each other in cervical carcinoma.

## Discussion

Proliferation enhancement and apoptosis inhibition are the two primary mechanisms underlying tumorigenesis (30). Apoptosis is a cell death pathway that cells are able activate. Compared with a cell proliferation disorder, the inhibition of apoptosis serves an important role in the occurrence, development and prognosis of tumors. The inhibition of apoptosis and cell proliferation disrupts the balance between cell growth and apoptosis to decrease the cell mortality rate. If the physiological balance is not restored, it may induce an increased number of cells with a growth advantage, which is an important part of tumor formation (31,32).

Previous studies have demonstrated that the IAP family has important roles in the gene regulation associated with cell apoptosis (33,34). The IAP family is a class of

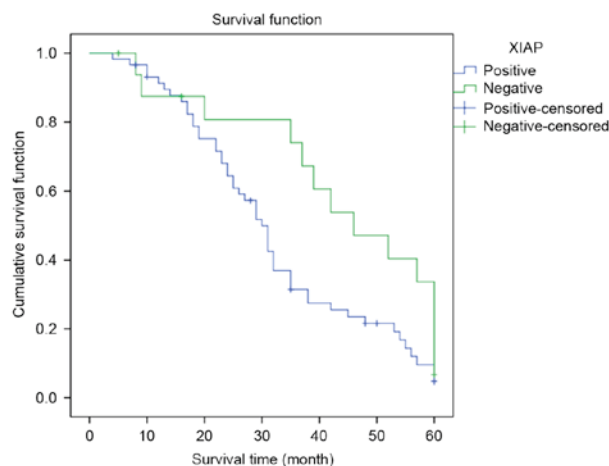


Figure 3. Expression levels of XIAP in cervical cancer and its association with patient survival time. The survival time in the group with positive XIAP expression level was significantly reduced compared with in the group with positive XIAP expression level (log rank=4.291;  $P=0.038$ ). XIAP, X-linked inhibitors of apoptosis.

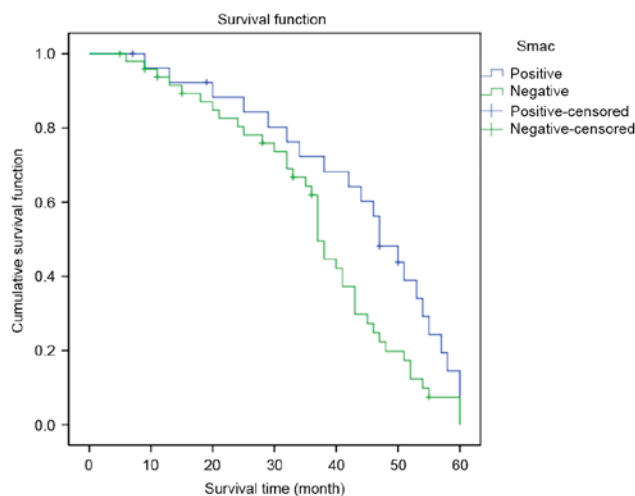


Figure 4. Expression levels of Smac in cervical cancer and its association with patient survival time. The survival time in the group with positive Smac expression level was significantly increased compared with in the group with negative Smac expression level (log rank=4.403;  $P=0.036$ ). Smac, second mitochondria-derived activator of caspase.

endogenous apoptosis inhibitory proteins, involved in tumor, neurodegenerative and other diseases. XIAP is an effective inhibitor in the IAP family. Its overexpression was established

to be associated with the occurrence and development of cervical cancer (35,36). The present study demonstrated that XIAP was primarily localized in the cytoplasm, and highly expressed in cervical intraepithelial neoplasia and cervical cancer compared with that in the normal cervical squamous epithelium. The present study identified that XIAP expression levels were positively associated with the malignancy of cervical cancer, indicating function for an increased expression level of XIAP in cervical squamous tumorigenesis. The present study also observed that XIAP expression level was closely associated with lymphatic metastasis, indicating its expression level was associated with the degree of malignancy and poor prognosis. The results of the present study demonstrated that CINIII stage may be pinnacle point in the malignant transformation of intraepithelial neoplasia lesions. The present study investigated the association between alterations of expression levels of XIAP and the occurrence and development of tumors, including lung cancer, gastrointestinal cancer and breast ductal carcinoma. The results provided evidence supporting the potential application of XIAP as a biomarker for the early diagnosis of malignant tumors.

Smac was first reported as a pro-apoptotic protein in July 2000 and is widely expressed in human normal tissues and primarily located in the cell mitochondria (29). Smac has been observed to act conversely to XIAP (37,38). Previous studies investigating Smac in numerous tumor tissues suggested that the low expression of Smac may inhibit the apoptosis of tumor cells (39-42). The present study demonstrated that Smac is expressed differently among tissues samples of normal epithelium, CIN and cervical squamous cell carcinoma. Its expression levels were negatively associated with the malignancy of cervical cancer, suggesting that the low expression levels of Smac may be associated with the occurrence of cervical squamous cell carcinoma, and the sustained low expression levels may contribute to malignant tumor development. However, the results of the present study also revealed that Smac may not serve significant role in the lymphatic metastasis and invasion of cervical squamous cell carcinoma.

Once cells were exposed to anticancer drugs, ultraviolet irradiation and another apoptosis signal stimulation, the active Smac/DIABLO protein is released from mitochondria into the cytoplasm and promotes apoptosis via its interaction with IAPs. The N-terminus of Smac is able to identify and interact with the BIR domain of IAPs. By binding to IAPs, Smac reduces the inhibitive activity of IAPs on caspase-9, caspase3 and caspase7, and thereby activates caspases and promotes apoptosis. However, certain studies revealed there may be other mechanisms underlying the apoptotic activity of Smac (43-45).

The survival curves in the present study suggested that a reduced expression level of XIAP or an increased expression level of Smac provides a significant survival advantage. Increased expression levels of XIAP or reduced expression levels of Smac were observed in patients with cervical cancer at advanced stages or patients with low differentiation or pelvic lymph node metastasis. Therefore, it was suggested that a high expression level of XIAP and a simultaneous low expression level of Smac in cervical cancer may be associated with the progression and prognosis of the disease.

The present study revealed negative associations between the expression levels of XIAP and Smac in cervical cancer,

suggesting a potential interaction between these proteins. The negative correlation between XIAP and Smac expression levels and the association with their increased or decreased expression level with cervical cancer, suggested the ratio of XIAP/Smac may be a potential prognostic indicator for cervical cancer. Further studies are required to verify this and investigate the mechanisms underlying the regulation and functions of XIAP/Smac in cervical cancer.

In conclusion, the present study demonstrated that XIAP expression levels were positively associated with the malignancy of cervical cancer, whereas Smac expression levels revealed a converse association. In addition, the expression levels of XIAP were negatively associated with that of Smac in cervical cancer. Further studies focusing on elucidating the interaction between XIAP and Smac in cervical cancer are required.

### Acknowledgements

The authors would like to thank Professor Jing Jin from Wenzhou Medical University (Wenzhou, China) for her support. The present study was supported by the Municipal Science and Technology Foundation of Wenzhou City, Wenzhou, China (grant no. Y20140110) and the Science Technology Department of Zhejiang Province, China (grant no. 2013C33098).

### References

- Husain RS and Ramakrishnan V: Global variation of human papillomavirus genotypes and selected genes involved in cervical malignancies. *Ann Glob Health* 81: 675-683, 2015.
- Ahmad F and Stewart DE: Predictors of clinical breast examination among South Asian immigrant women. *J Immigr Health* 6: 119-126, 2004.
- Gadducci A, Guerrieri ME and Greco C: Tissue biomarkers as prognostic variables of cervical cancer. *Crit Rev Oncol Hematol* 86: 104-129, 2013.
- Kyrgiou M, Mitra A, Arbyn M, Stasinou SM, Martin-Hirsch P, Bennett P and Paraskeva E: Fertility and early pregnancy outcomes after treatment for cervical intraepithelial neoplasia: Systematic review and meta-analysis. *BMJ* 349: g6192, 2014.
- Shoji Y, Saegusa M, Takano Y, Ohbu M and Okayasu I: Correlation of apoptosis with tumour cell differentiation, progression, and HPV infection in cervical carcinoma. *J Clin Pathol* 49: 134-138, 1996.
- Saslow D, Solomon D, Lawson HW, Killackey M, Kulasingam SL, Cain J, Garcia FA, Moriarty AT, Waxman AG, Wilbur DC, *et al.*: American cancer society, American society for colposcopy and cervical pathology, and American society for clinical pathology screening guidelines for the prevention and early detection of cervical cancer. *Am J Clin Pathol* 137: 516-542, 2012.
- Manzo-Merino J, Contreras-Paredes A, Vázquez-Ulloa E, Rocha-Zavaleta L, Fuentes-Gonzalez AM and Lizano M: The role of signaling pathways in cervical cancer and molecular therapeutic targets. *Arch Med Res* 45: 525-539, 2014.
- Massad LS, Einstein MH, Huh WK, Katki HA, Kinney WK, Schiffman M, Solomon D, Wentzensen N and Lawson HW: 2012 ASCCP Consensus Guidelines Conference: 2012 updated consensus guidelines for the management of abnormal cervical cancer screening tests and cancer precursors. *J Low Genit Tract Dis* 17 (5 Suppl 1): S1-S27, 2013.
- Jiang P and Yue Y: Human papillomavirus oncoproteins and apoptosis (Review). *Exp Ther Med* 7: 3-7, 2014.
- Liu SS, Tsang BK, Cheung AN, Xue WC, Cheng DK, Ng TY, Wong LC and Ngan HY: Anti-apoptotic proteins, apoptotic and proliferative parameters and their prognostic significance in cervical carcinoma. *Eur J Cancer* 37: 1104-1110, 2001.
- Yang YL and Li XM: The IAP family: Endogenous caspase inhibitors with multiple biological activities. *Cell Res* 10: 169-177, 2000.

12. Silke J and Meier P: Inhibitor of apoptosis (IAP) proteins-modulators of cell death and inflammation. *Cold Spring Harb Perspect Biol* 5: a008730, 2013.
13. Lukacs C, Belunis C, Crowther R, Danho W, Gao L, Goggin B, Janson CA, Li S, Remiszewski S, Schutt A, *et al*: The structure of XIAP BIR2: Understanding the selectivity of the BIR domains. *Acta Crystallogr D Biol Crystallogr* 69: 1717-1725, 2013.
14. Du C, Fang M, Li Y, Li L and Wang X: Smac, a mitochondrial protein that promotes cytochrome c-dependent caspase activation by eliminating IAP inhibition. *Cell* 102: 33-42, 2000.
15. Krepler C, Chunduru SK, Halloran MB, He X, Xiao M, Vultur A, Villanueva J, Mitsuuchi Y, Neiman EM, Benetatos C, *et al*: The novel SMAC mimetic birinapant exhibits potent activity against human melanoma cells. *Clin Cancer Res* 19: 1784-1794, 2013.
16. Lecis D, Drago C, Manzoni L, Seneci P, Scolastico C, Mastrangelo E, Bolognesi M, Anichini A, Kashkar H, Walczak H and Delia D: Novel SMAC-mimetics synergistically stimulate melanoma cell death in combination with TRAIL and Bortezomib. *Br J Cancer* 102: 1707-1716, 2010.
17. Finlay D, Vamos M, González-López M, Ardecky RJ, Ganji SR, Yuan H, Su Y, Cooley TR, Hauser CT, Welsh K, *et al*: Small-molecule IAP antagonists sensitize cancer cells to TRAIL-induced apoptosis: Roles of XIAP and cIAPs. *Mol Cancer Ther* 13: 5-15, 2014.
18. Shintani M, Sangawa A, Yamao N and Kamoshida S: Smac/DIABLO expression in human gastrointestinal carcinoma: Association with clinicopathological parameters and survivin expression. *Oncol Lett* 8: 2581-2586, 2014.
19. Fulda S: Smac mimetics as IAP antagonists. *Semin Cell Dev Bio* 39: 132-138, 2015.
20. Saelens X, Festjens N, Vande Walle L, van Gorp M, van Loo G and Vandenberghe P: Toxic proteins released from mitochondria in cell death. *Oncogene* 23: 2861-2874, 2004.
21. Yang QH and Du C: Smac/DIABLO selectively reduces the levels of c-IAP1 and c-IAP2 but not that of XIAP and livin in HeLa cells. *J Biol Chem* 279: 16963-16970, 2004.
22. Suzuki Y, Nakabayashi Y and Takahashi R: Ubiquitin-protein ligase activity of X-linked inhibitor of apoptosis protein promotes proteasomal degradation of caspase-3 and enhances its anti-apoptotic effect in Fas-induced cell death. *Proc Natl Acad Sci USA* 98: 8662-8667, 2001.
23. MacFarlane M, Morrison W, Bratton SB and Cohen GM: Proteasome-mediated degradation of Smac during apoptosis: XIAP promotes Smac ubiquitination in vitro. *J Biol Chem* 277: 36611-36616, 2002.
24. Baldus SE, Schwarz E, Lohrey C, Zapatka M, Landsberg S, Hahn SA, Schmidt D, Dienes HP, Schmiegel WH and Schwarte-Waldhoff I: Smad4 deficiency in cervical carcinoma cells. *Oncogene* 24: 810-819, 2005.
25. Phillipps HR and Hurst PR: XIAP: A potential determinant of ovarian follicular fate. *Reproduction* 144: 165-176, 2012.
26. Pecorelli S, Zigliani L and Odicino F: Revised FIGO staging for carcinoma of the cervix. *Int J Gynaecol Obstet* 105: 107-108, 2009.
27. Böcker W: WHO classification of breast tumors and tumors of the female genital organs: Pathology and genetics. *Verh Dtsch Ges Pathol* 86: 116-119, 2002 (In German).
28. Wright TC Jr, Cox JT, Massad LS, Carlson J, Twiggs LB and Wilkinson EJ; 2001 ASCCP-sponsored Consensus Workshop: 2001 Consensus guidelines for the management of women with cervical intraepithelial neoplasia. *J Low Genit Tract Dis* 7: 154-167, 2003.
29. Verhagen AM, Ekert PG, Pakusch M, Silke J, Connolly LM, Reid GE, Moritz RL, Simpson RJ and Vaux DL: Identification of DIA-BLO, a mammalian protein that promotes apoptosis by binding to and antagonizing IAP proteins. *Cell* 102: 43-55, 2000.
30. Malchenko S, Galat V, Seftor EA, Vanin EF, Costa FF, Seftor RE, Soares MB and Hendrix MJ: Cancer hallmarks in induced pluripotent cells: New insights. *J Cell Physiol* 225: 390-393, 2010.
31. Yang X, Hao Y, Ferenczy A, Tang SC and Pater A: Overexpression of anti-apoptotic gene BAG-1 in human cervical cancer. *Exp Cell Res* 247: 200-207, 1999.
32. Espinosa M, Cantú D, Herrera N, Lopez CM, De la Garza JG, Maldonado V and Melendez-Zajgla J: Inhibitors of apoptosis proteins in human cervical cancer. *BMC Cancer* 6: 45, 2006.
33. Silke J and Vucic D: IAP family of cell death and signaling regulators. *Methods Enzymol* 545: 35-65, 2014.
34. Wei Y, Fan T and Yu M: Inhibitor of apoptosis proteins and apoptosis. *Acta Biochim Biophys Sin (Shanghai)* 40: 278-288, 2008.
35. Estornes Y and Bertrand MJ: IAPs, regulators of innate immunity and inflammation. *Semin Cell Dev Biol* 39: 106-114, 2015.
36. Cavin LG, Wang F, Factor VM, Kaur S, Venkatraman M, Thorgeirsson SS and Arsur M: Transforming growth factor- $\alpha$  inhibits the intrinsic pathway of c-Myc-induced apoptosis through activation of nuclear factor- $\kappa$ B in murine hepatocellular carcinomas. *Mol Cancer Res* 3: 403-412, 2005.
37. Elsayy MA, Tikhonova IG, Martin L and Walker B: Smac-derived Aza-peptide as an aminopeptidase-resistant XIAP BIR3 antagonist. *Protein Pept Lett* 22: 836-843, 2015.
38. Hamacher-Brady A, Choe SC, Krijnse-Locker J and Brady NR: Intramitochondrial recruitment of endolysosomes mediates Smac degradation and constitutes a novel intrinsic apoptosis antagonizing function of XIAP E3 ligase. *Cell Death Differ* 21: 1862-1876, 2014.
39. Fulda S, Wick W, Weller M and Debatin KM: Smac agonists sensitize for Apo2L/TRAIL- or anticancer drug-induced apoptosis and induce regression of malignant glioma in vivo. *Nat Med* 8: 808-815, 2002.
40. Schliep S, Decker T, Schneller F, Wagner H and Häcker G: Functional evaluation of the role of inhibitor of apoptosis proteins in chronic lymphocytic leukemia. *Exp Hematol* 32: 556-562, 2004.
41. Kempkensteffen C, Hinz S, Christoph F, Krause H, Magheli A, Schrader M, Schostak M, Miller K and Weikert S: Expression levels of the mitochondrial IAP antagonists Smac/DIABLO and Omi/HtrA2 in clear-cell renal cell carcinomas and their prognostic value. *J Cancer Res Clin Oncol* 134: 543-550, 2008.
42. Bao ST, Gui SQ and Lin MS: Relationship between expression of Smac and Survivin and apoptosis of primary hepatocellular carcinoma. *Hepatobiliary Pancreat Dis Int* 5: 580-583, 2006.
43. Vucic D, Stennicke HR, Pisabarro MT, Salvesen GS and Dixit VM: ML-IAP, a novel inhibitor of apoptosis that is preferentially expressed in human melanomas. *Cur Biol* 10: 1359-1366, 2000.
44. LaCasse EC, Mahoney DJ, Cheung HH, Plenchette S, Baird S and Korneluk RG: IAP-targeted therapies for cancer. *Oncogene* 27: 6252-6275, 2008.
45. Vince JE, Wong WW, Khan N, Feltham R, Chau D, Ahmed AU, Benetatos CA, Chunduru SK, Condon SM, McKinlay M, *et al*: IAP antagonists target cIAP1 to induce TNF $\alpha$ -dependent apoptosis. *Cell* 13: 682-693, 2007.