

Fatal pancreatic pseudocyst co-infected by *Raoultella planticola*: an emerging pathogen

Fernando Peixoto Ferraz de Campos^a, Tiago Borges Guimarães^b,
Silvana Maria Lovisolo^c

Campos FPF, Guimarães TB, Lovisolo SM. Fatal pancreatic pseudocyst co-infected by *Raoultella planticola*: an emerging pathogen. *Autopsy Case Rep* [Internet]. 2016;6(2):27-31. <http://dx.doi.org/10.4322/acr.2016.034>

ABSTRACT

Raoultella planticola is an aerobic Gram-negative bacterium belonging to the Enterobacteriaceae family. Initially identified in the 1980s, its pathogenic potential was further recognized when the first case of bacteremia was reported. Since then, only a few infections caused by this pathogen have been described. Although considered an opportunistic agent, fatal outcomes are associated with the infection by this pathogen, since it is more prevalent among the patients with immunodeficiency. The authors report the case of a middle-aged man diagnosed with end-stage renal disease and alcoholic pancreatitis, who was admitted to the emergency department with septic shock. Physical examination disclosed peritoneal irritation and a laparotomy was undertaken. Purulent peritonitis was found as well as a retroperitoneal abscess, which was drained. The postoperative period was troublesome, and the patient died. The autopsy showed a ruptured, infected pancreatic cyst and purulent peritonitis, among other findings. The culture of the peritoneal fluid and two blood sample sets were positive for *R. planticola*. The authors call attention to the importance of this emerging pathogen associated with severe gastrointestinal infections.

Keywords

Enterobacteriaceae Infections; Pancreatic Diseases; Peritonitis; Autopsy

CASE REPORT

A 52-year-old man was brought to the emergency unit complaining of colicky upper abdominal pain over the previous 7 days, which had worsened in the last 2 days and was accompanied by nausea and vomiting. His past medical history included two episodes of pneumonia, one of which was complicated with thoracic empyema and chronic pancreatitis with acute exacerbation 2 years ago, hypertension, and stage IV chronic renal disease. The biliopancreatic

imaging referred the presence of pneumobilia. He was a tobacco smoker and a heavy drinker, but denied illicit drugs use. He was not taking any antibiotics, antiemetics, or painkillers before coming to the hospital. On admission, he looked critically ill, emaciated (body mass index was 18), dehydrated, tachypneic, tachycardic, and with poor peripheral perfusion. His blood pressure was 70/50 mmHg, room air oximetry was 88%, and Glasgow coma

^a Internal Medicine Division - Hospital Universitário - University of São Paulo, São Paulo/SP – Brazil.

^b Anatomic Pathology Department - Faculty of Medicine - University of São Paulo, São Paulo/SP – Brazil.

^c Anatomic Pathology Service - Hospital Universitário - University of São Paulo, São Paulo/SP – Brazil.



scale was 15. Cardiac and pulmonary examinations were unremarkable, but his abdomen was distended, diffusely painful with rebound tenderness and the presence of normal bowel sounds. The laboratory work-up revealed mild anemia and leukocytosis with marked left shift, acute renal failure with metabolic acidosis, increased hepatic enzymes and normal amylase, lipase, bilirubin, and clotting tests.

With the clinical diagnosis of peritonitis, the patient underwent an exploratory laparotomy, which disclosed an enormous amount of free purulent effusion within the abdominal cavity, edema of the intestinal loops and the great omentum, and an abscess in the retro-cavity of the epiploon (at the tail of the pancreas). The surgical procedure consisted of peritoneal lavage, abscess drainage, and closure of the abdominal wound with a Bogotá bag. The patient was referred to the intensive care unit in the early postoperative period, where, despite mechanical ventilatory support and vasoactive drugs, hemodynamic instability remained uncontrolled, and the patient died less than 24 hours after hospitalization.

The culture obtained from the abdominal cavity was positive for *Escherichia coli*, Group F β -hemolytic *Streptococcus*, and *Raoultella planticola*; the latter two agents were also isolated in two blood culture sets.

Bacterial identification was performed using VITEK-2 compact (version 07.01, BioMérieux, France).

AUTOPSY FINDINGS

The ectoscopic examination of the corpse showed a median xipho-pubic surgical incision and a Bogotá bag closure of the abdomen. At the opening of the cavities, pleural adhesion in the left hemithorax was present, and 400 mL of sero-hemorrhagic effusion covered the swollen viscera of the peritoneal cavity, which was thoroughly coated with a fibrinoid material.

The pancreas weighed 183 g (reference value: 60-100 g) and presented a distorted shape surrounded by increased fat tissue. At the cut surface, the usual lobulation was effaced; the color was mousy and intermingled by white areas of a hardened consistency. A purplish 3 cm pseudocyst was present with the rupture of the external wall (Figure 1).

The microscopy revealed that the pancreatic parenchyma was replaced by extensive fibrosis, acinar atrophy, intraductal eosinophilic protein plugs, and chronic inflammatory infiltration (Figure 2A and 2B). The surrounding pancreatic fat tissue, as well as the whole peritoneum, was thoroughly coated with fibrin, which, at histology, confirmed the presence

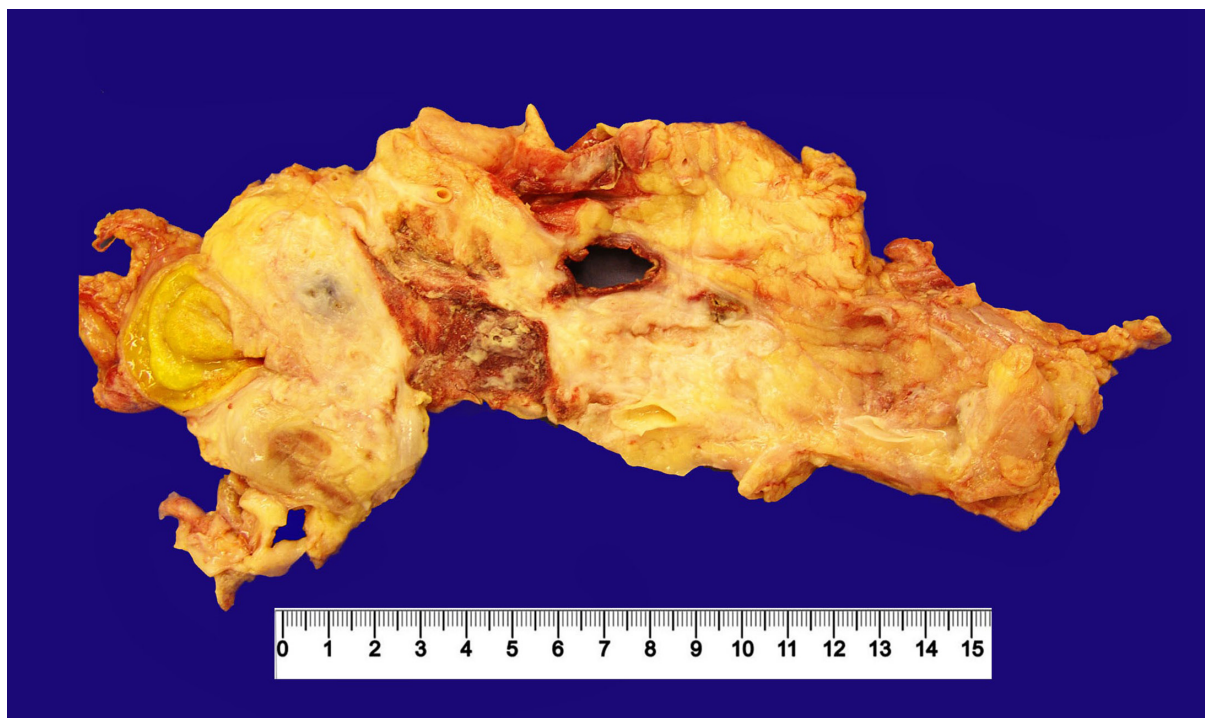

Figure 1. Gross appearance of the pancreas showing the replacement of the pancreatic parenchyma with fat tissue and, at the center, the perforation hole of the pseudocyst.

of peritonitis (Figure 2C). The internal surface of the pseudocyst presented acute inflammatory infiltration, venules thrombosis, and granulation tissue (Figure 2D).

Other findings consisted of small areas of lungs atelectasis, and alterations consistent with long-term tobacco abuse (respiratory bronchiolitis and tracheal squamous metaplasia); myocardial hypertrophy, bone marrow hypercellularity at the expense of myeloid hyperplasia; and changes consistent with shock, such as a loss of hepatocytes centrilobular trabeculation and vacuolation, acute tubular necrosis, and acute splenitis.

DISCUSSION

Initially labeled as *Klebsiella planticola*, in 1981,¹ *R. planticola* was subsequently identified, in 2001, by Drancourt et al.² based on 16S *rRNA* genes and *rpo B* sequence analyses. Therefore, *R. planticola* is a Gram-negative, aerobic, encapsulated nonmotile

bacillus, belonging to the *Enterobacteriaceae* family, which requires laboratory refinements for its precise identification. These challenges were responsible for previous misidentification to such an extent that some cases formerly classified as *K. pneumoniae* or *Klebsiella oxytoca* could, in fact, be *R. planticola*.³⁻⁶ Although *R. planticola* is an environmental bacterium found in the water, soil, and plants, it is also isolated from nearly all human tissues and fluids.⁷⁻⁸ After its identification, the clinical significance of *R. planticola* remained uncharacterized for almost a decade.⁸ However, since the description of the case of septicemia reported by Freney et al.⁹ in 1984 (identified as *Klebsiella trevisanii* at the time), many other cases of infections in humans have been reported; therefore the pathogenicity of *R. planticola* needs to be revised.

The actual incidence of *R. planticola* infection is difficult to estimate because of misidentification and underreported cases. To date, this infection is still rare.

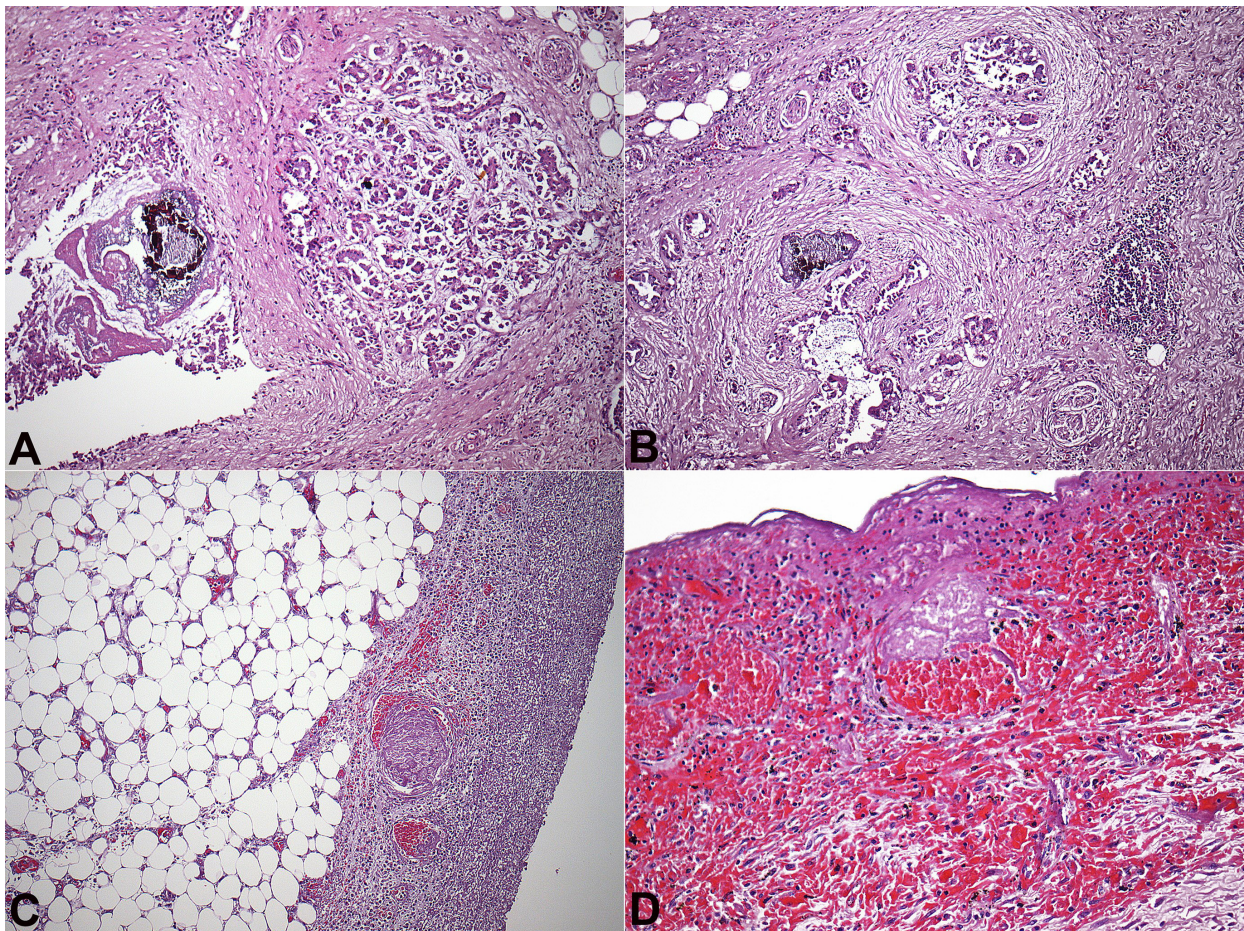


Figure 2. **A** and **B** - Photomicrography of the pancreas showing substantial replacement of the pancreatic parenchyma by fibrous tissue and chronic inflammatory infiltration wrapping the remaining pancreatic acini and the dilated pancreatic duct with a protein plug and calcification (H&E,4X); **C** - Photomicrography of the peripancreatic tissue showing the fat tissue and the marked peritonitis (H&E,10X); **D** - Photomicrography of the pseudocyst's inner lining showing the absence of epithelium (H&E, 20X).

The infection by this emerging pathogen is associated with either immunosuppression states, such as neoplasia, chronic renal disease, and diabetes mellitus, or invasive procedures and trauma.^{7,10} The infection sites reported so far that are caused by *R. planticola* are: (i) sepsis/bacteremia;^{9,11-17} (ii) pneumonia;¹⁴⁻¹⁸ (iii) abdominal infections;^{8,10-12,19-21} (iv) urinary tract;^{22,23} (v) skin and soft tissues;²⁴⁻²⁶ and (vi) conjunctivitis,²⁷ which account for a little more than 20 cases.

R. planticola was originally described as being sensitive to cephalosporins, aminoglycosides, fluoroquinolones, and carbapenems. However, recent studies^{18,28,29} have reported the emergence of carbapenem-resistant strains, which has changed what was an easily treatable infection into a therapeutic challenge. Polymicrobial infection of the peritoneal cavity concomitant with positive blood cultures, which included *R. planticola* among the other isolated agents, had also been reported.¹⁹

Considering the aforementioned concepts on *R. planticola*, our patient presented many characteristics found among the reported cases. The site of infection (i.e. the gastrointestinal tract in this case), has been reported as the second site of infection after bacteremia.^{10,11} Yokota et al.¹¹ support the hypothesis that *R. planticola* colonizes the gastrointestinal tract and becomes a potential source of infection. Our patient was a heavy drinker with the clinical diagnosis of chronic pancreatic disease, and had previous hospitalizations due to pneumonia and thoracic empyema, which confers some degree of malnutrition besides chronic renal disease. Both chronic organic failures associated with immunologic disturbance,^{10,11,18,19} facilitated the infection caused by *R. planticola*.

We deemed the presence of pneumobilia as an important risk factor for the development of the polymicrobial infection of our patient's pancreatic cyst since there must have had a contact between the intestinal flora and the biliopancreatic system. *R. planticola*, as the other bacteria of the Enterobacteriaceae family, is an opportunistic agent of the intestinal environment, and under immunosuppression it acts as an invasive agent. The fatal outcome of this patient is closely related to his poor clinical status and severe disease. We cannot blame the *R. planticola* for being entirely responsible for the drastic outcome; however it did play a role in the development of this severe infection.

The antibiogram of the *R. planticola* strain involved in our case showed sensitivity to cephalosporins,

fluoroquinolones, and carbapenems, but the severity of the infection and the early fatal outcome hampered the evaluation of the antimicrobial response.

In our literature search of *R. planticola* infections, we found only one case of pancreatic infection; therefore, we call attention to the rarity of this case.

REFERENCES

1. Bagley ST, Seidler RJ, Brenner DJ. *Klebsiella planticola* sp. nov.: a new species of Enterobacteriaceae found primarily in nonclinical environments. *Curr Microbiol.* 1981;6(2):105-9. <http://dx.doi.org/10.1007/BF01569013>.
2. Drancourt M, Bollet C, Carta A, Rousselier P. Phylogenetic analyses of *Klebsiella* species delineate *Klebsiella* and *Raoultella* gen. nov., with description of *Raoultella ornithinolytica* comb. nov., *Raoultella terrigena* comb. nov. and *Raoultella planticola* comb. nov. *Int J Syst Evol Microbiol.* 2001;51(Pt 3):925-32. <http://dx.doi.org/10.1099/00207713-51-3-925>. PMID:11411716.
3. Monnet D, Freney J, Brun Y, Boeufgras JM, Fleurette J. Difficulties in identifying *Klebsiella* strains of clinical origin. *Zentralbl Bakteriol.* 1991;274(4):456-64. [http://dx.doi.org/10.1016/S0934-8840\(11\)80081-2](http://dx.doi.org/10.1016/S0934-8840(11)80081-2). PMID:1863314.
4. Westbrook GL, O'Hara CM, Roman SB, Miller JM. Incidence and identification of *Klebsiella planticola* in clinical isolates with emphasis on newborns. *J Clin Microbiol.* 2000;38(4):1495-7. PMID:10747132.
5. Alves MS, Dias RC, de Castro AC, Riley LW, Moreira BM. Identification of clinical isolates of indole-positive and indolenegative *Klebsiella* spp. *J Clin Microbiol.* 2006;44(10):3640-6. <http://dx.doi.org/10.1128/JCM.00940-06>. PMID:16928968.
6. Monnet D, Freney J. Method for differentiating *Klebsiella planticola* and *Klebsiella terrigena* from other *Klebsiella* species. *J Clin Microbiol.* 1994;32(4):1121-2. PMID:8027329.
7. Kim SW, Kim JE, Hong YA, Ko GJ, Pyo HJ, Kwon YJ. *Raoultella planticola* peritonitis in a patient on continuous ambulatory peritoneal dialysis. *Infection.* 2015;43(6):771-5. <http://dx.doi.org/10.1007/s15010-015-0788-4>. PMID:25958102.
8. Alves MS, Riley LW, Moreira BM. A case of severe pancreatitis complicated by *Raoultella planticola* infection. *J Med Microbiol.* 2007;56(5):696-8. <http://dx.doi.org/10.1099/jmm.0.46889-0>. PMID:17446297.
9. Freney J, Fleurette J, Gruer LD, Desmonceaux M, Gavini F, Leclerc H. *Klebsiella trevisanii* colonisation and septicaemia. *Lancet.* 1984;1(8382):909. [http://dx.doi.org/10.1016/S0140-6736\(84\)91368-0](http://dx.doi.org/10.1016/S0140-6736(84)91368-0). PMID:6143213.
10. Ershadi A, Weiss E, Verduzco E, Chia D, Sadigh M. Emerging pathogen: a case and review of *Raoultella*

- planticola. *Infection*. 2014;42(6):1043-6. <http://dx.doi.org/10.1007/s15010-014-0638-9>. PMID:24902523.
11. Yokota K, Gomi H, Miura Y, Sugano K, Morisawa Y. Cholangitis with septic shock caused by *Raoultella planticola*. *J Med Microbiol*. 2012;61(Pt 3):446-9. <http://dx.doi.org/10.1099/jmm.0.032946-0>. PMID:22096135.
 12. Puerta-Fernandez S, Miralles-Linares F, Sanchez-Simonet MV, Bernal-Lopez MR, Gomez-Huelgas R. *Raoultella planticola* bacteraemia secondary to gastroenteritis. *Clin Microbiol Infect*. 2013;19(5):E236-7. <http://dx.doi.org/10.1111/1469-0691.12102>. PMID:23574552.
 13. Li J, Lan R, Xiong Y, et al. Sequential isolation in a patient of *Raoultella planticola* and *Escherichia coli* bearing a novel ISCR1 element carrying blaNDM-1. *PLoS One*. 2014;9(3):e89893. <http://dx.doi.org/10.1371/journal.pone.0089893>. PMID:24594606.
 14. Freney J, Gavini F, Alexandre H, et al. Nosocomial infection and colonization by *Klebsiella trevisanii*. *J Clin Microbiol*. 1986;23(5):948-50. PMID:3711281.
 15. Castanheira M, Deshpande LM, DiPersio JR, Kang J, Weinstein MP, Jones RN. First descriptions of blaKPC in *Raoultella* spp. (*R. planticola* and *R. ornithinolytica*): report from the SENTRY antimicrobial surveillance program. *J Clin Microbiol*. 2009;47(12):4129-30. <http://dx.doi.org/10.1128/JCM.01502-09>. PMID:19812278.
 16. Hu AY, Leslie KA, Baskette J, Elsayed S. *Raoultella planticola* bacteraemia. *J Med Microbiol*. 2012;61(Pt 10):1488-9. <http://dx.doi.org/10.1099/jmm.0.041129-0>. PMID:22820690.
 17. González-González L, Álvarez-Otero J, Ferreira JLL, Aguado JF. Cholangitis and bacteremia caused by *Raoultella planticola*. *Med Clin*. 2015;144(5):230-4. <http://dx.doi.org/10.1016/j.medcli.2014.04.010>. PMID:24994005.
 18. Xu M, Xie W, Fu Y, Zhou H, Zhou J. Nosocomial pneumonia caused by carbapenem-resistant *Raoultella planticola*: a case report and literature review. *Infection*. 2015;43(2):245-8. <http://dx.doi.org/10.1007/s15010-015-0722-9>. PMID:25595510.
 19. Salmaggi C, Ancona F, Olivetti J, Pagliula G, Ramirez GA. *Raoultella planticola*-associated cholangitis and sepsis: a case report and literature review. *QJM*. 2014;107(11):911-3. <http://dx.doi.org/10.1093/qjmed/hcu087>. PMID:24733944.
 20. Lee JH, Choi WS, Kang SH, et al. A case of severe cholangitis caused by *Raoultella planticola* in a patient with pancreatic cancer. *Infect Chemother*. 2012;44(3):210-2. <http://dx.doi.org/10.3947/ic.2012.44.3.210>.
 21. Teo I, Wild J, Ray S, Chadwick D. A rare case of cholecystitis caused by *Raoultella planticola*. *Case Rep Med*. 2012;2012:601641. PMID:22690225.
 22. Olson DS Jr, Asare K, Lyons M, Hofinger DM. A novel case of *Raoultella planticola* urinary tract infection. *Infection*. 2013;41(1):259-61. <http://dx.doi.org/10.1007/s15010-012-0294-x>. PMID:22802099.
 23. Koukoulaki M, Bakalis A, Kalatzis V, et al. Acute prostatitis caused by *Raoultella planticola* in a renal transplant recipient: a novel case. *Transpl Infect Dis*. 2014;16(3):461-4. <http://dx.doi.org/10.1111/tid.12213>. PMID:24750300.
 24. Wolcott R, Dowd S. Molecular diagnosis of *Raoultella planticola* infection of a surgical site. *J Wound Care*. 2010;19(8):329-32. <http://dx.doi.org/10.12968/jowc.2010.19.8.77710>. PMID:20852504.
 25. O'Connell K, Kelly J, Niriain U. A rare case of soft-tissue infection caused by *Raoultella planticola*. *Case Rep Med*. 2010;2010:134086. PMID:20811592.
 26. Kim SH, Roh KH, Yoon YK, et al. Necrotizing fasciitis involving the chest and abdominal wall caused by *Raoultella planticola*. *BMC Infect Dis*. 2012;12(1):59. <http://dx.doi.org/10.1186/1471-2334-12-59>. PMID:22423899.
 27. Zuberbuhler B, Abedin A, Roudsari A. A novel case of chronic conjunctivitis in a 58-year-old woman caused by *Raoultella*. *Infection*. 2014;42(5):927-9. <http://dx.doi.org/10.1007/s15010-014-0624-2>. PMID:24865691.
 28. Tseng SP, Wang JT, Liang CY, Lee PS, Chen YC, Lu PL. First report of blaMP-8 in *Raoultella planticola*. *Antimicrob Agents Chemother*. 2014;58(1):593-5. <http://dx.doi.org/10.1128/AAC.00231-13>. PMID:24145534.
 29. Tang H-X, Wu A-W, Song J-L, Yang L, Chen D-Q, Lin Y-P. Extensively drug-resistant *Raoultella planticola* carrying multiple resistance genes including blaNDM-1. *JMM Case Rep*. 2014;1(3). <http://dx.doi.org/10.1099/jmmcr0.000265>.

Conflict of interest: None

Submitted on: March 10th, 2016

Accepted on: April 14th, 2016

Correspondence

Fernando Peixoto Ferraz de Campos

Internal Medicine Division - Hospital Universitário - University of São Paulo (USP)

Av. Professor Lineu Prestes, 2565 – Butantã – São Paulo/SP – Brazil

CEP: 05508-000

Phone: +55 (11) 3091-9275

E-mail: fpfcampos@gmail.com