

Correlation of correct needle placement in caudal epidural space and anatomical structures of sacral canal in paediatric patients: An observational study

Address for correspondence:

Dr. Anuj Jain,
B-118, New Minal
Residency, Bhopal,
Madhya Pradesh - 462 023,
India.
E-mail: anuj.jain.mln@gmail.
com

Submitted: 23-Jan-2021
Revised: 15-Feb-2021
Accepted: 18-Mar-2021
Published: 10-May-2021

Anuj Jain, Swapnil K Barasker, Suruchi Jain¹, Vaishali Waindeskar

Departments of Anaesthesiology, and ¹Nuclear Medicine, All India Institute of Medical Sciences, Bhopal, Madhya Pradesh, India

ABSTRACT

Background and Aims: Caudal epidural block (CEB) is commonly performed using surface landmark-based technique in the paediatric patients, with a good success rate. Failure to perform CEB is usually attributable to anatomic variations. The aim of this study was to perform measurements of the anatomical landmarks that are generally used to perform CEB and find a relation between these measurements and successful needle placement. **Methods:** This was an observational study that included 114 patients, aged up to 15 years. Ultrasonography (USG) scan of the sacrococcygeal region with measurement of cornu height, skin to cornu distance, inter-cornu distance (ICD), vertical and oblique size of hiatus were done. Needle placement for CEB was done using the usual palpatory hiatal approach. Needle position was checked by using ultrasound. Spearman correlation coefficient and multi-variate logistic regression were used for measuring the correlation and predictors of correct needle placement, respectively. **Results:** Correct placement of needle was found in 84% patients. Statistically significant correlation was found between all the anatomical parameters. Regression analysis revealed that only ICD had a statistically significant contribution (OR 1.67, 95% CI 1.024–2.7; $P = 0.04$) in predicting an incorrect needle placement. If ICD was less than 12.5 mm, it predicted a difficult needle placement; all the children were less than 1.5 years in age; AUC was 77%, $P = 0.001$, sensitivity 83% and specificity 76.5%. **Conclusion:** ICD can be used as predictor of difficult needle placement for CEB. USG guidance may be of help while performing CEB in children less than 1.5 years.

Key words: Anaesthesia, caudal epidural, paediatric, sacro-coccygeal region, ultrasound

Access this article online

Website: www.ijaweb.org

DOI: 10.4103/ija.IJA_1599_20

Quick response code



INTRODUCTION

Caudal epidural block (CEB) in paediatric age group is a well-established technique for surgical anaesthesia and postoperative analgesia. CEB in children is usually performed with the help of anatomical guidance.^[1] In experienced hands, the success rate is high with a short learning curve.^[2]

The use of USG for CEB is mostly done to measure the distance between the skin and sacro-coccygeal ligament, identify spinal dysraphism such as tethered cord, low lying dural sac.^[3] Schuepfer *et al.*^[2] reported a pooled mean success rate of CEB of the staff anaesthesiologists to be 0.73 with a standard deviation of 0.45. Some investigators have reported a higher success rate of approximately 96%.^[4] Irrespective

of the high success rate, certain anatomical factors contribute to failure; ill-developed sacral cornu, thick subcutaneous fat in the sacral region, obliteration of hiatus due to fusion of lamina, ossified sacro-coccygeal ligament, dural sac puncture are some of the important factors contributing to procedure failure.^[4-6] Most of the available literature is focused on comparison

This is an open access journal, and articles are distributed under the terms of the Creative Commons Attribution-NonCommercial-ShareAlike 4.0 License, which allows others to remix, tweak, and build upon the work non-commercially, as long as appropriate credit is given and the new creations are licensed under the identical terms.

For reprints contact: WKHLRPMedknow_reprints@wolterskluwer.com

How to cite this article: Jain A, Barasker SK, Jain S, Waindeskar V. Correlation of correct needle placement in caudal epidural space and anatomical structures of sacral canal in paediatric patients: An observational study. *Indian J Anaesth* 2021;65:74-9.

of success in USG guided and landmark guided CEB.^[7] Although anatomical factors contributing to CEB failure have been studied in adults, such a study is lacking for the paediatric population.^[8,9]

The aim of the study was to find a correlation between correct needle placement and the sizes of relevant anatomical structures of the sacral canal.

METHODS

This study was approved by the institutional review board (ref: IHEC-LOP/2019/IM0203). Written informed consent was obtained from the guardians of paediatric patients aged up to 15 years before recruiting in the study, and the procedures was conducted in accordance with the Helsinki Declaration-2013. The patients were recruited between March 2019 and March 2020. After induction of general anaesthesia, the patients were positioned in the lateral decubitus in the knee-chest position. Under aseptic precautions, a high frequency, linear array (5-13 Hz) probe was used to scan the sacral region for sacro-coccygeal dysraphism or a low lying dural sac; measurement of the anatomical structures i.e., cornu height, inter-cornual distance (ICD), skin to cornu distance (SCD) and hiatus size was also done [Figure 1].

After the initial scan, needle was placed for CEB by a well-trained anaesthesiologist (more than 3 years

of experience in anaesthesia practice) using the equilateral triangle landmark technique (needle insertion site defined as the tip of the equilateral triangle formed between the sacral cornu and the sacral hiatus). After needle placement, confirmation of needle position was done by the ‘Swoosh’ test.^[10] In ‘Swoosh test’, saline (1 ml) was injected into the caudal space. During injection, a stethoscope was placed over the lower lumbar spine and the presence or absence of ‘swoosh’ was noted by an independent observer. Once the clinician had placed the needle satisfactorily, ultrasound probe was used to confirm correctness of the needle placement. A correctly positioned needle was defined as a needle passing between the two sacral cornu in the short axis view along with expansion and collapse of the epidural space with injection of the injectate (0.25% bupivacaine) in the long axis view [Figure 2].

For measurement of anatomical structures, the structures were defined in the following manner: for height of sacral cornu, in the short axis view, a frame was captured in which the cornu appeared most prominent. Height of the individual sacral cornu was measured from the tip to the base; base being the plane passing tangential to the posterior table of the sacrum. Inter-cornual distance (ICD) was defined as the distance between the tip of the sacral cornu; Skin to cornu distance (SCD) was defined as the distance from the most superficial part of the image to the tip of the cornu. Hiatus size measurement was done

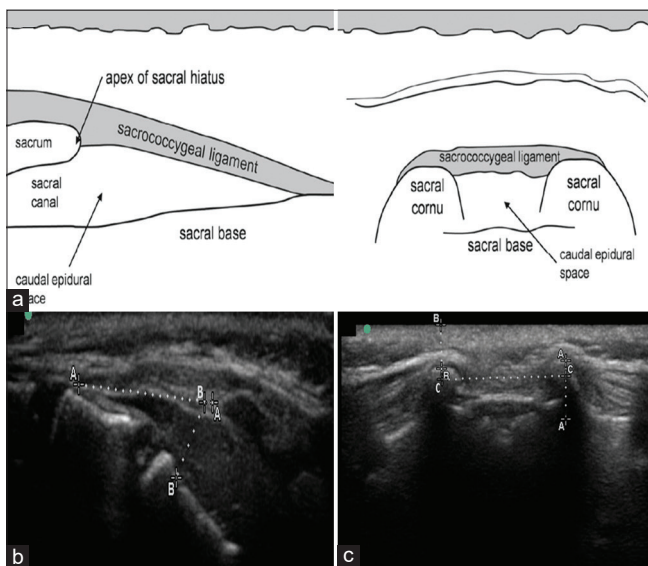


Figure 1: (a): Schematic diagram showing the structures of sacral hiatus in longitudinal and axial view. (b):USG image showing longitudinal view of the sacral hiatus; dotted line A-A represents oblique size of the hiatus; dotted line B-B represents the vertical size of the hiatus. (c): USG image showing axial view of sacral hiatus; dotted lines 'A-A','B-B','C-C' represent the height of cornu, Skin to cornu distance (SCD) and inter cornual distance (ICD) respectively

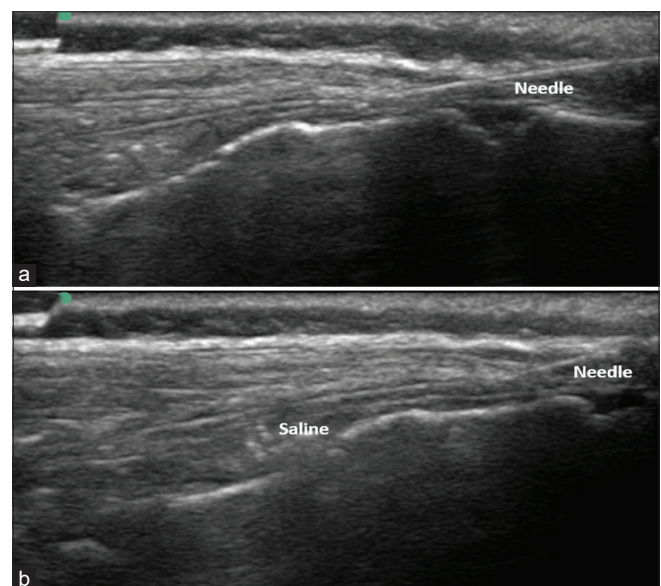


Figure 2: (a): USG image showing longitudinal view with needle in caudal epidural space. (b): USG image showing longitudinal view of caudal epidural space expansion with saline

with the USG probe in the long axis. Vertical hiatus size was defined as the vertical distance between the anterior and posterior elements of the sacral canal at the level of insertion of sacrococcygeal ligament. Length of sacrococcygeal ligament was defined as the oblique hiatus size.

We used the formula suggested by Green *et al.*^[11] to calculate the sample size for regression analysis ($N \geq 104 + x$; where 'N' is the sample size and 'x' is the number of independent variables). In this study, we had 8 independent variables namely age, weight, left cornu height, right cornu height, inter-cornual distance, skin to cornu distance, oblique and vertical size of the hiatus. As per this formula, a sample size of at least 112 was needed; we recruited 114 patients. The power of study was kept at 80%.

The data were analysed using the Statistical Package for Social Sciences (SPSS), version 16.0 (SPSS, Chicago, Illinois) software. For comparison of parametric data, Student's independent sample *t* test was used; for comparison of proportions, Chi-square test was used. Spearman correlation coefficient was used for measuring the correlation between independent variables and correctness of the needle placement. Multi-variate logistic regression was used to identify the predictors of correct needle placement.

RESULTS

In the current study, the age of 35 patients was less than 1.5 years; 48 patients were between 1.5 and 3.5 years; 11 were between 3.5 and 6 years; and 20 were more than 6 years old. The mean age of the study participant was 2.81 ± 3.16 years; mean weight was 15.22 ± 10.3 kg; 63 out of 114 were male. Overall success rate was 84% (96 out 114); the success rate in less than 1.5 years age group was 71%; in 1.5-3.5 years it was 92%; 3.5-6 years it was 100% while in more than 6 years age group it was 85%. Age, weight, hiatus size, ICD, SCD were significantly lesser in the patients with incorrect needle placement [Table 1].

Spearman correlation coefficient was calculated for various anatomical parameters under study. The study parameters had a statistically significant correlation with the correctness of needle placement. Although the correlation was weak, correlation between correct needle placement was strongest with ICD, oblique size of hiatus and height

Table 1: Comparison of various anatomical parameters among the patients with correct and incorrect needle placement

Risk factors	Correct placement (n=96)	Incorrect placement (n=18)	P
Age (in years)	3.19±3.16	1.38±2.5	0.02*
Weight (in kg)	16.6±10.0	9.2±9.8	0.006*
ICD (in mm)	13.29±1.43	11.0±3.06	0.00008*
SCD (in mm)	4.2±1.14	3.57±0.91	0.019*
Oblique hiatus size (in mm)	12.89±1.26	11.05±1.8	0.000018*
Vertical hiatus size (in mm)	2.76±0.65	2.25±0.688	0.00051*
Height of the right cornu (in mm)	3.2±1.28	1.86±1.02	0.00001*
Height of the left cornu (in mm)	3.18±1.19	1.73±0.95	0.00001*

The values are presented as mean±SD. ICD= Inter-cornual distance; SCD= Skin to cornu distance. *P<0.05 is significant

of the cornu size; R-value 0.36, 0.42, 0.4, and 0.37, respectively [Table 2].

Multi-logistic regression analysis of the data showed only ICD had a statistically significant contribution in predicting the correct placement of the needle; the association appears to be weak, OR 1.67 (95% CI, 1.0–2.7) and the clinical significance of it is rather contentious [Table 3]. Apart from ICD, all the other parameters had a non-significant contribution towards the correctness of needle placement [Table 3]. The regression model of the current study correctly predicted the outcome in 91.2% case [Table 4].

A ROC curve for ICD and correct needle placement was generated and based on this, it could be predicted that an ICD greater than 12.5 mm increases the chances of correct placement; AUC was 77%, P value = 0.001, sensitivity 83%, and specificity 76.5%. ICD less than 12.5 mm corresponded to an age less than 1.5 years; 29 patients had ICD less than 12.5 mm, while 85 had ICD more than 12.5 mm; out of the 29 patients with ICD less than 12.5 mm, needle was correctly placed in 55% patients; percentage of correct needle placement in more than 12.5 mm group was 94%.

None of the patients had a hyperechoic sacrococcygeal ligament or a closed sacral hiatus. Three patients out of 114 had a thecal sac filling the sacral hiatus and were not given CEB.

DISCUSSION

In this study, we found that in 84% patients, the needle was correctly placed with the help of landmark guidance. The patients with a correct needle placement were significantly bigger in age and weight and had

Table 2: Point biserial correlation coefficient for the anatomical parameters and correct placement of needle

Risk factors	Correlation coefficient (r)	P
Age	0.24	0.0078*
ICD	0.36	0.00008*
SCD	0.22	0.019*
Vertical Hiatus size	0.26	0.00519*
Oblique Hiatus size	0.42	0.0001*
Height of the right cornu	0.4	0.0001*
Height of the left cornu	0.37	0.00005*

*P<0.05 are significant

Table 3: Results of the multi-logistic regression analysis. OR is Odd's ratio and CI is Confidence interval

Risk factors	OR (95% CI)	P
Age	0.804 (0.4-1.61)	0.5
Height of Left cornu	2.556 (0.42-15.56)	0.3
Height of right cornu	9.42 (0.558-159.18)	0.1
Inter-cornual distance	1.67 (1.024-2.7)	0.04*
Skin to cornu distance	0.24 (0.039-1.48)	0.1
Oblique size of the hiatus	1.59 (0.502-5.072)	0.4
Vertical size of the hiatus	1.043 (0.24-4.51)	0.9
Weight	0.89 (0.733-1.09)	0.3

*P<0.05 are significant

Table 4: Comparison of the observed results and results predicted based on the regression analysis

	Predicted		Overall Percentage
	Correct	Incorrect	
Observed			
Correct	94	2	
Incorrect	8	9	
Percentage correct	97.9	52.9	91.2

a bigger hiatus size, ICD, SCD. ICD was the only anatomic variable that predicted the correctness of needle placement. ICD greater than 12.5 mm increases the chances of correct needle placement. 55% patients with a ICD less than 12.5 mm had a correct needle placement while the incidence of correctness in those with ICD more than 12.5 mm was 94%.

Anatomical variations at the sacral hiatus are frequently responsible for CEB failures. These anatomical variations can be in the form of small cornu, asymmetrical cornu, small size of sacral hiatus, calcified hiatus or uncanalised hiatus, thecal sac extending into sacral canal etc.^[8,9,12] Ultrasound is an effective screening tool for detecting anatomical variations and in turn improving the success of CEB.^[9,13,14] Although ultrasound-guided CEB is gaining popularity, a majority of anaesthesiologists perform the procedure based on palpable landmarks.

In the current study, we measured the anatomical landmarks and confirmed the correctness of needle

position with ultrasound. This success rate is lower than that in the available literature.^[15] The main reason of low success rate is that we had included patients of less than 1.5 years in our study; in the other group (ICD more than 12.5 mm), the success rate was at par with the available literature (94%).^[2,4]

Kim *et al.*^[16] performed a similar study in adult population and reported a CEB failure in approximately 11% patients. They reported the depth of sacral canal at the apex (comparable to vertical size of the hiatus in our study) and the length of sacrococcygeal ligament (comparable to oblique size of the hiatus) as the most important anatomical predictor of a difficult CEB or a failed CEB (r-value -0.46 and -0.45 respectively); the effect of SCD and ICD, age, sex or BMI was found to be a statistically. They found that depth of sacral canal at the apex less than 3.7 mm and length of sacrococcygeal ligament less than 17.6 mm predicted a difficult CEB. Chen *et al.*,^[9] predicted the earlier value to be 1.5 mm.

This study highlights that the predictors of a difficult CEB in paediatric and adult age groups are likely to be different. Of the many anatomical variables, only ICD was found to be a statistically significant predictor of correct needle placement, although the association is weak (OR 1.67,95%CI: 1.0-2.7) and its clinical relevance can be questioned.

ICD seems to play a more important role in paediatric than in adult population. An ungloved healthy human finger can appreciate the discreteness of two contact points only if they are more than 3-5 mm apart.^[17] For obvious reasons this distance would be more if the fingers are gloved, and the contact points are covered by skin and subcutaneous tissue. Hence, palpation of inter-cornual space would be difficult if ICD is less, thereby resulting in incorrect needle placement. Mirjalili *et al.*,^[18] found that in approximately 15% infants, the cornu are not adequately palpable and concluded that the equilateral landmark technique is unreliable in infants.

A closed caudal canal is reported in approximately 2%–3% of adults.^[12,19] The chances of finding a closed canal in children should be lesser than this. In the current study we did not find a closed canal in any patient.

In 8% children, the dural sac extends up to S2-3 level.^[20] In the current study, we identified dural sac extending up to the sacral hiatus in 3 patients (all

were less than 1.5 years in age; incidence 8.5% within the age group). The incidence of thecal sac extending into the sacral canal varies with the extent of spine flexion,^[21] and may be as high as 18% in the neutral position. Koo *et al.*^[21] suggested that screening of sacral hiatus be routinely done in children who are younger than 2 years and especially if they have a urological abnormality. Our study also reiterates these findings.

The impact of ultrasound screening and guidance seems rather trivial in bigger children. Apart from correct placement of needle, ultrasound guidance may help by improve the chances of success in a single prick, decreasing the chance of blood vessel and thecal sac puncture and subcutaneous injection.^[15]

This study has certain important limitations; only children of Indian origin were studied; hence the results may not be applicable to all the races. Although in studies on adult patients, there have been racial variations in the coccygeal region,^[22,23] their association with difficult CEBs is limited. Besides, we did not assess the block effect clinically and consider it to be major limitation of the study; variable duration of surgery and difficulty in assessment of block effect in paediatric population was the reason behind this decision. We did not verify the absence of inadvertent intravascular injection with fluoroscopy and consider it to be a limitation of the study. The study subjects belonged to a wide range of age, a more uniform sample may help bring out the results that may be more relevant clinically.

CONCLUSION

In paediatric population, inter-cornual distance (ICD) is the most important predictor of correct placement of needle while performing CEB. If the ICD is less than 12.5 mm, then the chances of incorrect needle placement are likely to increase.

Declaration of patient consent

The authors certify that they have obtained all appropriate patient consent forms. In the form the patient(s) has/have given his/her/their consent for his/her/their images and other clinical information to be reported in the journal. The patients understand that their names and initials will not be published and due efforts will be made to conceal their identity, but anonymity cannot be guaranteed.

Financial support and sponsorship

Nil.

Conflicts of interest

There are no conflicts of interest.

REFERENCES

1. Ponde V. Recent developments in paediatric neuraxial blocks. *Indian J Anaesth* 2012;56:470-8.
2. Schuepfer G, Konrad C, Schmeck J, Poortmans G, Staffelbach B, Jöhr M. Generating a learning curve for pediatric caudal epidural blocks: An empirical evaluation of technical skills in novice and experienced anesthetists. *Reg Anesth Pain Med* 2000;25:385-8.
3. Kil HK, Cho JE, Kim WO, Koo BN, Han SW, Kim JY. Prepuncture ultrasound-measured distance: An accurate reflection of epidural depth in infants and small children. *Reg Anesth Pain Med* 2007;32:102-6.
4. Dalens B, Hasnaoui A. Caudal anesthesia in pediatric surgery: Success rate and adverse effects in 750 consecutive patients. *Anesth Analg* 1989;68:83-9.
5. Bogduk N, Endres SM. *Clinical Anatomy of the Lumbar Spine and Sacrum*. Elsevier/Churchill Livingstone; 2005.
6. Dalens BJ, Mazoit JX. Adverse effects of regional anaesthesia in children. *Drug Saf* 1998;19:251-68.
7. Gupta S, Sharma R. Comparison of analgesic efficacy of caudal dexmedetomidine versus caudal tramadol with ropivacaine in paediatric infraumbilical surgeries: A prospective, randomised, double-blinded clinical study. *Indian J Anaesth* 2017;61:499-504.
8. Aggarwal A, Aggarwal A, Harjeet, Sahni D. Morphometry of sacral hiatus and its clinical relevance in caudal epidural block. *Surg Radiol Anat* 2009;31:793-800.
9. Chen CP, Wong AM, Hsu CC, Tsai WC, Chang CN, Lin SC, *et al.* Ultrasound as a screening tool for proceeding with caudal epidural injections. *Arch Phys Med Rehabil* 2010;91:358-63.
10. Orme RM, Berg SJ. The 'swoosh' test-an evaluation of a modified 'whoosh' test in children. *Br J Anaesth* 2003;90:62-5.
11. Green SB. How many subjects does it take to do a regression analysis. *Multivariate Behavioral Research* 1991;26:499-510.
12. Sekiguchi M, Yabuki S, Satoh K, Kikuchi S. An anatomic study of the sacral hiatus: A basis for successful caudal epidural block. *Clin J Pain* 2004;20:51-4.
13. Chen CP, Tang SF, Hsu TC, Tsai WC, Liu HP, Chen MJ, *et al.* Ultrasound guidance in caudal epidural needle placement. *Anesthesiology* 2004;101:181-4.
14. Klocke R, Jenkinson T, Glew D. Sonographically guided caudal epidural steroid injections. *J Ultrasound Med* 2003;22:1229-32.
15. Wang LZ, Hu XX, Zhang YF, Chang XY. A randomized comparison of caudal block by sacral hiatus injection under ultrasound guidance with traditional sacral canal injection in children. *Paediatr Anaesth* 2013;23:395-400.
16. Kim YH, Park HJ, Cho S, Moon DE. Assessment of factors affecting the difficulty of caudal epidural injections in adults using ultrasound. *Pain Res Manag* 2014;19:275-9.
17. Mendoza JE. Two-point discrimination. In: Kreutzer JS, DeLuca J, Caplan B, editors. *Encyclopedia of Clinical Neuropsychology*. New York: Springer; 2011. p. 2568-9.
18. Mirjalili SA, Taghavi K, Frawley G, Craw S. Should we abandon landmark-based technique for caudal anesthesia in neonates and infants? *Paediatr Anaesth* 2015;25:511-6.
19. Senoglu N, Senoglu M, Oksuz H, Gumusalan Y, Yuksel KZ, Zencirci B, *et al.* Landmarks of the sacral hiatus for caudal epidural block: An anatomical study. *Br J Anaesth* 2005;95:692-5.
20. Shin Seo K, Hong Jeong Y, Kim Won O, Koo Bon N,

- Kim Jee E, Kil Hae K. Ultrasound evaluation of the sacral area and comparison of sacral interspinous and hiatal approach for caudal block in children. *Anesthesiology* 2009;111:1135-40.
21. Koo BN, Hong JY, Kim JE, Kil HK. The effect of flexion on the level of termination of the dural sac in paediatric patients. *Anaesthesia* 2009;64:1072-6.
22. Norenberg A, Johanson DC, Gravenstein JS. Racial differences in sacral structure important in caudal anesthesia. *Anesthesiology* 1979;50:549-51.
23. Woon JT, Stringer MD. Clinical anatomy of the coccyx: A systematic review. *Clin Anat (New York, NY)* 2012;25:158-67.