

Isolated atrioventricular block of unknown origin in the adult and autoimmunity: diagnostic and therapeutic considerations exemplified by 3 anti-Ro/SSA-associated cases



Pietro Enea Lazzerini, MD,^{*} Antonio Brucato, MD,[†] Pier Leopoldo Capecchi, MD,^{*} Lucia Baldi, MD,[‡] Maria Romana Bacarelli, Tech,^{*} Claudia Nucci, MD,[‡] Valentina Moscadelli, MD,^{*} Gabriella Morozzi, BiOId,^{*} Mohamed Boutjdir, PhD,^{§**††} Franco Laghi-Pasini, MD^{*}

From the ^{*}Department of Medical Sciences, Surgery and Neurosciences, University of Siena, Siena, Italy, [†]Department of Internal Medicine, “Papa Giovanni XXIII” Hospital, Bergamo, Italy, [‡]Department of Heart, Thorax and Vessels, University Hospital of Siena, Siena, Italy, [§]Research Department, VA New York Harbor Healthcare System, New York, New York, ^{**}Departments of Medicine, Cell Biology and Pharmacology, State University of New York at Downstate Medical Center, New York, New York, and ^{††}Department of Medicine, New York University School of Medicine, New York, New York.

Introduction

A large body of evidence links the presence of circulating anti-Ro/SSA antibodies (anti-Ro/SSAs) in a mother with the risk of her newborn developing neonatal lupus, a paradigmatic model of transplacental passively acquired autoimmunity whose main cardiac manifestation is congenital complete atrioventricular block (congenital-III°AVB).¹ Although the precise underlying mechanisms of the block have not been fully elucidated, many experimental studies have demonstrated the ability of anti-Ro/SSA to biochemically cross-react with L-type and T-type calcium channels and thus significantly inhibit the related currents, both of which play a key role in the slow action potential of the conduction system cardiomyocytes.^{2,3} This interaction, at least in the initial acute phase, is electrophysiologically reversible (spontaneously or after appropriate immunosuppressive treatment of the mother), and in some cases may progress to an inflammatory-driven irreversible structural damage of the conduction system (ie, the findings characterizing the congenital-III°AVB).^{2,4}

Anti-Ro/SSAs, including the anti-Ro/SSA-52kD and anti-Ro/SSA-60kD subtypes, are frequently found in patients

with connective tissue diseases (CTDs), particularly in those with Sjögren syndrome (30–95%) and systemic lupus erythematosus (30–50%), but also in 0.5–2.7% of the healthy population.⁴ Although it is believed that adult heart does not represent an immunologic target for anti-Ro/SSA, increasing data indicate that these autoantibodies may also affect the adult conduction system, although to a lesser extent than the fetal heart.⁵

Accordingly, we have recently proposed the existence of 2 possible forms of anti-Ro/SSA-associated atrioventricular block (AVB) in adults: (1) a first type resulting from an immunomediated conduction-system interference secondary to anti-Ro/SSA developed during adulthood (*acquired form*) and (2) a second type representing the late progression of a subclinical anti-Ro/SSA-induced congenital damage of the conduction system (*late-progressive congenital form*).⁶

In the acquired form, characterized by the presence of anti-Ro/SSAs in the affected subject, the conduction defect seems to be related to a direct autoantibody-mediated inhibition of calcium channels in cardiomyocytes, and their effect is potentially reversible. Intrinsic age-related differences (lower calcium channel reserve and underdeveloped sarcoplasmic reticulum in the fetal heart)⁴ may explain why anti-Ro/SSAs induce only an electrophysiological effect in adults, without evolving to an inflammatory-driven heart injury as in newborns.⁶ However, a prenatally established structural (and irreversible) damage of immune origin appears to be the pathologic basis of the late-progressive congenital form, with a subsequent autoantibody-independent worsening with age. Accordingly, in late progressive congenital form patients anti-Ro/SSAs are not detectable, despite the seropositivity of their mothers. Thus, a recovery potential of the immunosuppressive therapy is expected in the acquired form only. Preliminary data indicate a rapid recovery of the conduction defects in patients with acquired anti-Ro/SSA-associated AVB after administration of immunosuppressive

KEYWORDS Isolated heart block in adults; Anti-Ro/SSA antibodies; Autoimmunity; Immunosuppressive therapy; Calcium channels

ABBREVIATIONS ANA = Antinuclear antibodies; **anti-Ro/SSA** = Anti-Ro/SSA antibody; **AV** = Atrioventricular; **AVB** = Atrioventricular block; **CTD** = Connective tissue disease; **ECG** = Electrocardiogram; **ELISA** = Enzyme-linked immunosorbent assay; **FEIA** = Fluoroenzyme immunoassay; **I°AVB** = First-degree atrioventricular block; **II°AVB** = Second-degree atrioventricular block; **III°AVB** = Third-degree atrioventricular block (Heart Rhythm Case Reports 2015;1:293–299)

Address reprint requests and correspondence: Dr Pietro Enea Lazzerini, Department of Medical Sciences, Surgery and Neurosciences, University of Siena, Policlinico “Le Scotte”, Viale Bracci, Siena, Italy. E-mail address: lazzerini7@unisi.it.

KEY TEACHING POINTS

- Congenital atrioventricular block (AVB) is the most recognized consequence of the transplacental passage of anti-Ro/SSA antibodies from the mother to the fetus. Although traditionally considered invulnerable, the adult conduction system also may represent a target for these antibodies.
- Recent data suggest 2 possible forms of anti-Ro/SSA-associated AVB in adults: (1) an *acquired form*, resulting from a direct and reversible autoantibody-mediated electrophysiological inhibition of cardiomyocyte calcium channels, and (2) a *late-progressive congenital form* related to a subclinical, prenatally established structural damage induced by maternally acquired anti-Ro/SSAs, with a subsequent autoantibody-independent worsening with age until a diagnosis in the patient's adulthood. Nevertheless, in some patients both the pathogenic mechanisms are concomitantly involved (*mixed form*).
- Whereas in the acquired form the patient shows circulating anti-Ro/SSAs, only the patient's mother is seropositive in the late-progressive congenital form. Thus, a recovery potential of immunosuppressive therapy is expected in the acquired form only.
- In adults with unexplained AVB, even in the absence of signs of connective tissue disease, a specific anti-Ro/SSA testing (enzyme-linked immunosorbent assay + Western blot) in the patient and patient's mother may be of diagnostic value. If anti-Ro/SSAs are detected in the patient, immunomodulating therapy may induce a rapid AVB recovery, thus avoiding or delaying pacemaker implantation.

drugs.⁶ An extensive review of the putative mechanisms underlying these 2 forms is reported elsewhere.⁶

The epidemiologic impact of anti-Ro/SSA-associated AVB in adults is higher than expected, probably because these patients (and their mothers) are frequently asymptomatic for CTDs and are therefore difficult to identify. In fact, available retrospective population studies indicate that the 2 forms, globally considered, may represent at least 20% of all cases of isolated III°AVB of unknown origin in adults (approximately 10% of cases attributed to each form).^{7,8} Thus, the importance of considering the possibility of anti-Ro/SSA-associated AVB and specifically testing for anti-Ro/SSAs in patients with "idiopathic" AVB should be emphasized, particularly for the important benefits coming

from an early immunosuppressive treatment of the acquired form.⁶

The clinical cases reported here provide further evidence in support of this view and demonstrate how in some patients both the pathogenic mechanisms characterizing the 2 forms of adult-onset anti-Ro/SSA-associated AVB may be concomitantly involved (*mixed form*).

Case reports

Case 1

A 29-year-old woman presented with chest pain, faintness, paleness, and sweating that had occurred acutely in the past few hours. An electrocardiogram (ECG) recorded at the emergency department demonstrated III°AVB and wide QRS ventricular escape rhythm with a rate of approximately 30–40 beats per minute (bpm), suggesting a conduction impairment distal to the bundle of His (Figure 1A). The clinical history of the patient was negative for relevant factors except for autoimmune thyroiditis, which was being treated with thyroxine, and subclinical positivity for anti-Ro/SSAs (no sign of CTDs) that had been incidentally detected 3 years before. As such, the patient had been carefully monitored for the risk of neonatal lupus during 2 previous pregnancies that delivered 2 healthy babies. Table 1

The patient was admitted to the intensive cardiac care unit. Laboratory investigation did not show abnormalities in thyroid hormone or thyrotropin levels. As expected, anti-nuclear antibody (ANA) testing results were positive (1:1280, speckled pattern), with very high circulating levels of anti-Ro/SSAs, including both anti-Ro/SSA-52kD and anti-Ro/SSA-60kD subspecificities, as assessed by an immunoenzymatic enzyme-linked immunosorbent assay (ELISA) method (>240 U/mL, reference values <7; fluoroenzyme immunoassay [FEIA] by a Phadia EliA system [Thermo Fisher Scientific, Waltham, MA]). The presence of the anti-Ro/SSA-52kD subspecificity was confirmed by Western blot analysis (MarDx Marblot HEp-2; Trinity Biotech, Carlsbad, CA).

Transthoracic and transoesophageal echocardiography were performed, and both excluded significant structural heart abnormalities. The patient was closely monitored for the following 12 hours, and then a permanent pacemaker was implanted (Figure 2B) to address the persistence of symptomatic III°AVB. The day after, and in consultation with the patient's immunologist (A.B.), immunosuppressive therapy with corticosteroids 1 mg/kg/d was started (intravenous methylprednisolone for the first day, and then oral prednisone). During the second day of treatment, III°AVB disappeared and a normal AV conduction was present. The patient was discharged, and a short-time follow-up ECG approximately 2 weeks later confirmed the persistence of a normal AV conduction (Figure 2C). However, in consideration of the fact that a pacemaker had already been implanted and the patient was totally asymptomatic for rheumatologic manifestations, corticosteroids were progressively tapered until complete termination to avoid unjustified side effects. A further

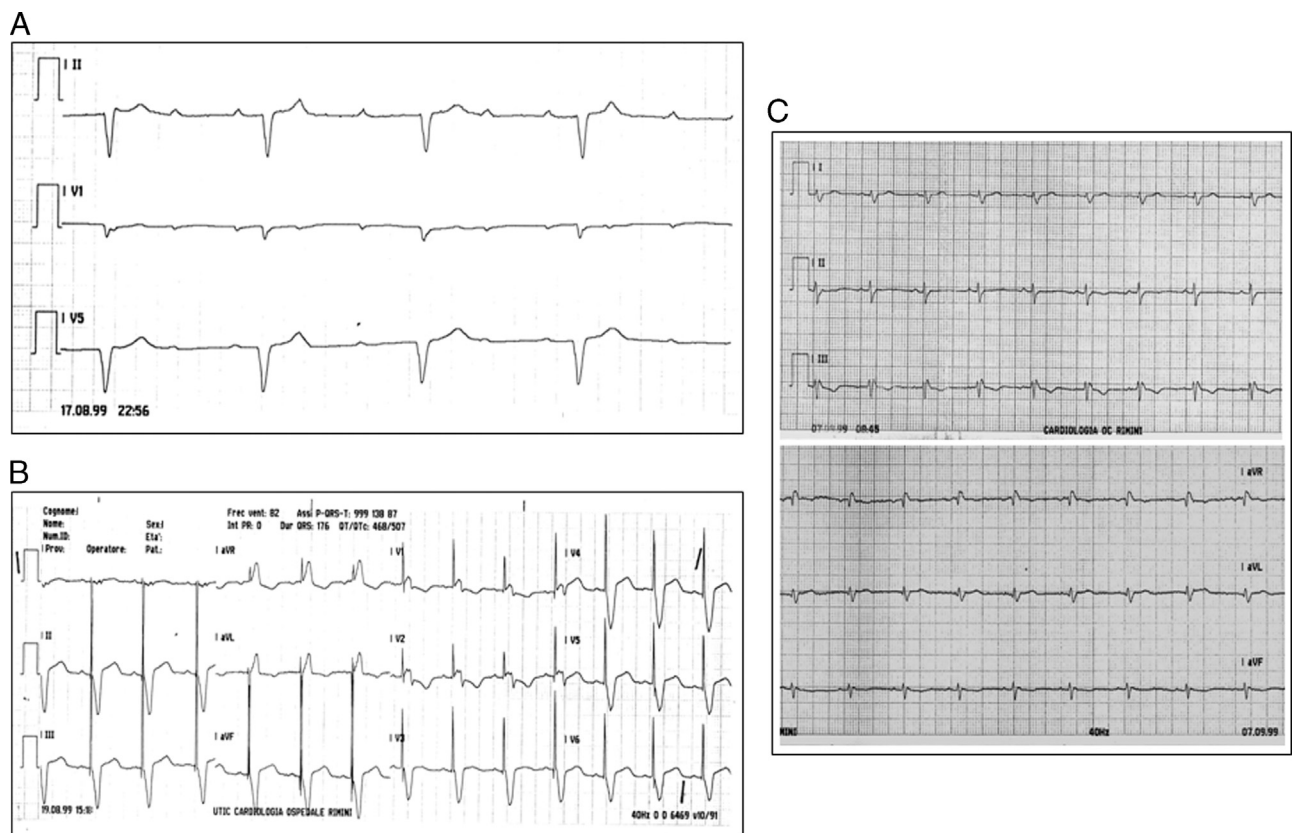


Figure 1 Resting electrocardiograms of case 1. **A:** At hospital admission, the recording shows third-degree atrioventricular block. **B:** After pacemaker implantation. **C:** 2 weeks after immunosuppressive therapy with prednisone, the recording showed normal atrioventricular conduction.

follow-up visit 6 months later showed the presence of a rhythm driven by pacemaker stimulation. Notably, clinical and instrumental monitoring in the following years did not show the appearance of possibly concealed sarcoidosis or other inflammatory/infiltrative cardiac diseases, despite persistent interruption of immunosuppressive therapy.

Case 2

An I°AVB (PR interval 320 milliseconds) was demonstrated in an asymptomatic 23-year-old woman who underwent a routine screening ECG in the course of a preemployment visit (Figure 2A). The following 24-hour ambulatory ECG showed intermittent II°AVB and episodes of high-grade

AVB with wide QRS escape beats (Figure 2B). The block appeared more likely to be at the AV nodal level, because of the narrow QRS complexes when conducted. The patient's clinical history was negative for any relevant disease. The retrospective analysis of a previous ECG performed at 9 years of age demonstrated that I°AVB was already present at that time. The patient was not taking any drugs, and there was no instrumental evidence of structural heart disease. Laboratory data, including thyroid hormone levels, were normal. The patient was specifically tested for ANA and anti-Ro/SSAs, and results of both tests were negative. However, the results of the same tests were positive in the patient's mother, a 51-year-old woman who was otherwise healthy except for a euthyroid multinodular goiter, under thyroid

Table 1 Patient characteristics by case

Case	Gender	Age, y	AV block degree	Connective tissue disease		Anti-Ro/SSA antibodies				Response to immunosuppressive therapy	Form
				Patient	Mother	Patient		Mother			
						FEIA	WB	FEIA	WB		
1	♀	29	third-degree	No	No	anti-52kD anti-60kD	anti-52kD	NA	NA	Yes	Acquired
2	♀	23	high-grade	No	No	—	—	anti-60kD	anti-52kD	Not evaluated	Late-progressive congenital
3	♀	21	high-grade	No	No	—	anti-52kD	—	anti-52kD	Yes	Mixed

AV = atrioventricular; FEIA = fluoroenzyme immunoassay; WB = Western blot; NA = not available; (-) = negative.

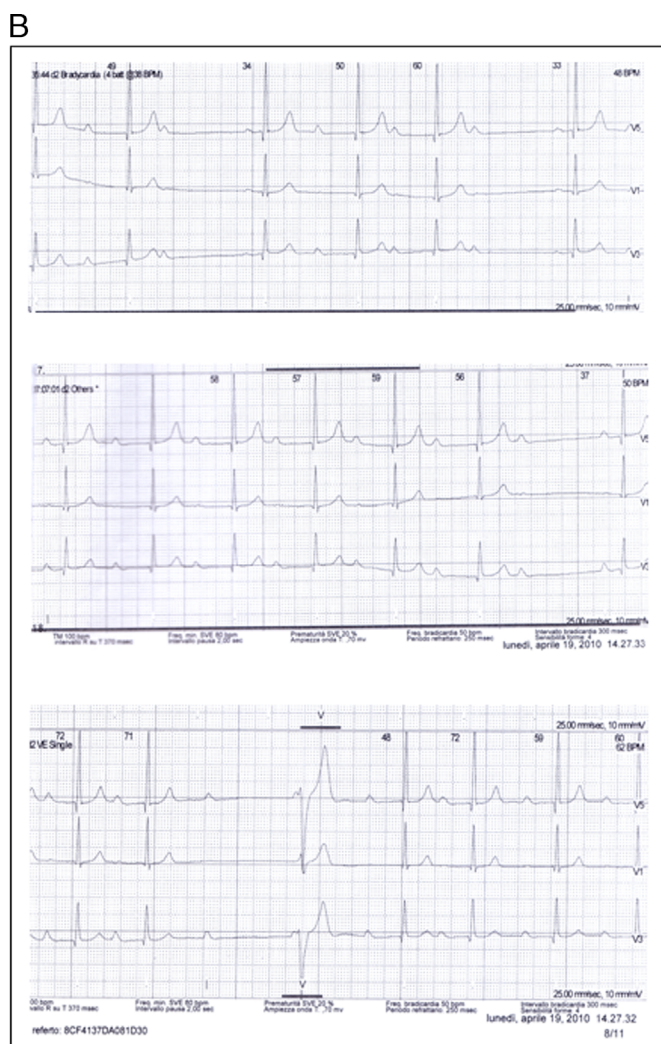
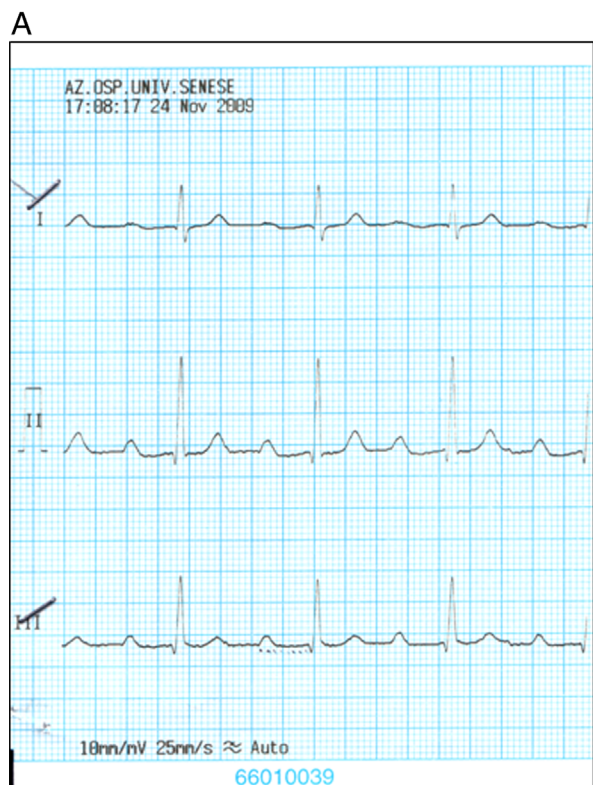


Figure 2 Electrocardiograms (ECGs) of case 2. **A:** Resting ECG showed first-degree atrioventricular block (PR interval, 320 milliseconds). **B:** A 24-hour ambulatory ECG showed intermittent second-degree atrioventricular block and episodes of high-grade atrioventricular block with wide QRS escape beats.

stimulating hormone-suppressive treatment with thyroxine. Indeed, FEIA displayed high levels of anti-Ro/SSAs (128 U/mL), with positivity for anti-Ro/SSA-60kD. Moreover, Western blot results revealed the presence of the subspecific anti-Ro/SSA-52kD.

The patient underwent close clinical and electrocardiographic follow-up in the next months, until episodes of dizziness led to the insertion of a backup permanent pacemaker.

Case 3

A 21-year-old woman presented with asymptomatic high-grade AVB, incidentally diagnosed during an endocrinology medical examination. ECG at rest showed III°AVB, narrow QRS, and a ventricular rate of approximately 45 bpm (Figure 3A). A 24-hour ambulatory ECG confirmed the presence of high-grade AVB for the most part of the day, with episodes of II°AVB (Mobitz type 1–2).

The patient had a history of autoimmune thyroiditis, which was being treated with thyroxine. A subclinical positivity for autoantibodies to gastric parietal cells was also

reported. Family history was negative for heart disease or autoimmune disorders. The patient had no history of cardiac surgery, ablation procedures, or drug use. There was no evidence of infiltrative heart diseases or myocardial ischemia. Transthoracic echocardiography and cardiac magnetic resonance imaging were unremarkable. No clinical manifestations of rheumatologic disease were present. Levels of thyrotropin were normal. Laboratory evaluation demonstrated a positive test for anti-Ro/SSA-52kD (Western blot), although FEIA testing was negative. Despite the patient’s negative history for conduction disturbances, a retrospective evaluation of available previous ECGs (recorded at ages 7 and 15) revealed the presence of a previously unrecognized I°AVB (PR interval 240 milliseconds) (Figure 4).

Laboratory testing of the mother, who was asymptomatic for CTDs, showed a positive result for ANA at a titer of 1:320, with a homogeneous pattern (ie, diffuse nuclear fluorescence), and anti-Ro/SSA-52kD (Western blot). Also in this case, FEIA results were negative.

Intravenous methylprednisolone was started for the patient at an immunosuppressive dose of 1 mg/kg/d, resulting in a

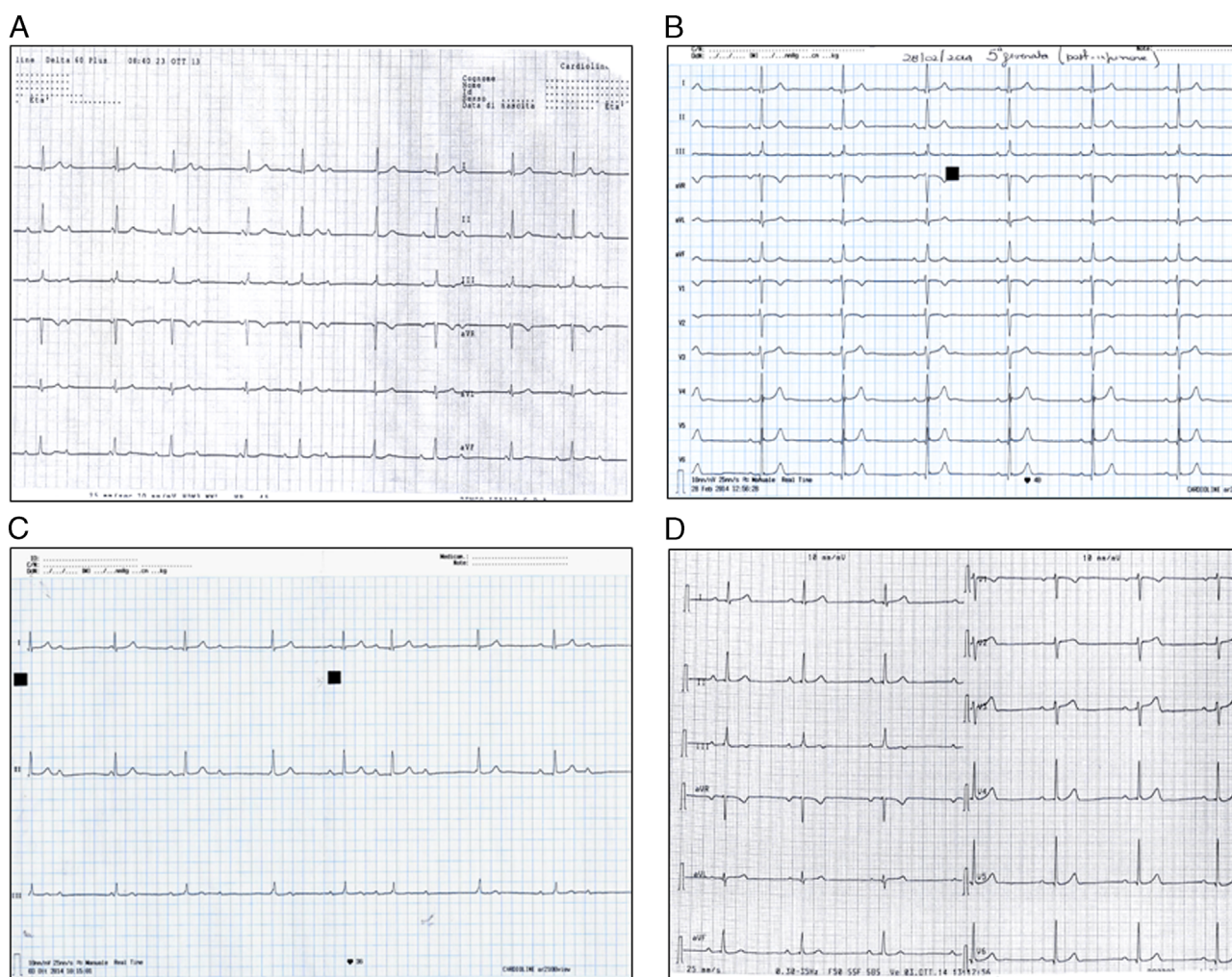


Figure 3 Resting electrocardiograms (ECGs) of case 3. **A:** At baseline, the ECG showed high-grade atrioventricular block. **B:** 5 days after the onset of the first course of intravenous methylprednisolone, the ECG showed first-degree atrioventricular block. **C:** 2 months after discontinuation of oral immunosuppressive therapy with azathioprine and prednisone, the ECG showed high-grade atrioventricular block; the patient was symptomatic. **D:** After the second course of intravenous methylprednisolone: first-degree atrioventricular block; the patient became asymptomatic.

rapid (within a few days) and significant improvement of ECG findings (disappearance of high-grade AVB; presence of I°AVB) (Figures 3B and Figure 4). Maintenance oral immunosuppressive therapy with azathioprine (100 mg daily) and prednisone (progressively reduced to 6.25 mg daily) was started. After 1, 3, and 6 months, new 24-hour ambulatory ECGs confirmed the absence of high-grade AVB, and the persistence of I°AVB (although with phases of II°AVB, Mobitz type 1–2) (Figure 4). At this time (3 months), Western blot results were negative for anti-Ro/SSA-52kD. However, since the patient was persistently asymptomatic and reluctant to long-term immunosuppressive therapy, the treatment was stopped. 2 months later, the patient presented persistent presyncopal symptoms, particularly in standing or sitting positions. Electrocardiogram demonstrated the reoccurrence of high-grade AVB with marked bradycardia (approximately 35 bpm) (Figure 3C). Administration of intravenous methylprednisolone again rapidly improved the conduction disturbances: soon the patient became completely asymptomatic and ECG tracings showed I°AVB with a mean heart rate

of 50–60 bpm (Figure 3D). A new immuno-Western blot performed at that time revealed the reappearance of anti-Ro/SSA-52kD positivity. The patient again underwent cardiac magnetic resonance imaging, and in this instance no signs of infiltrative or inflammatory diseases, particularly sarcoidosis, were detected. Currently, 1 month after restarting combined therapy with azathioprine and prednisone, the patient is stably asymptomatic and ECG shows I°AVB (with phases of II°AVB revealed by 24-hour ambulatory ECG) (Figure 4). The possibility of implanting a pacemaker is still under consideration.

Discussion

The cases reported in this paper illustrate the different forms of anti-Ro/SSA-associated AVB that can be observed in adults.

The first patient represents an acquired form, as indicated by circulating anti-Ro/SSAs. The pathogenic relevance of these autoantibodies in AVB development is strongly

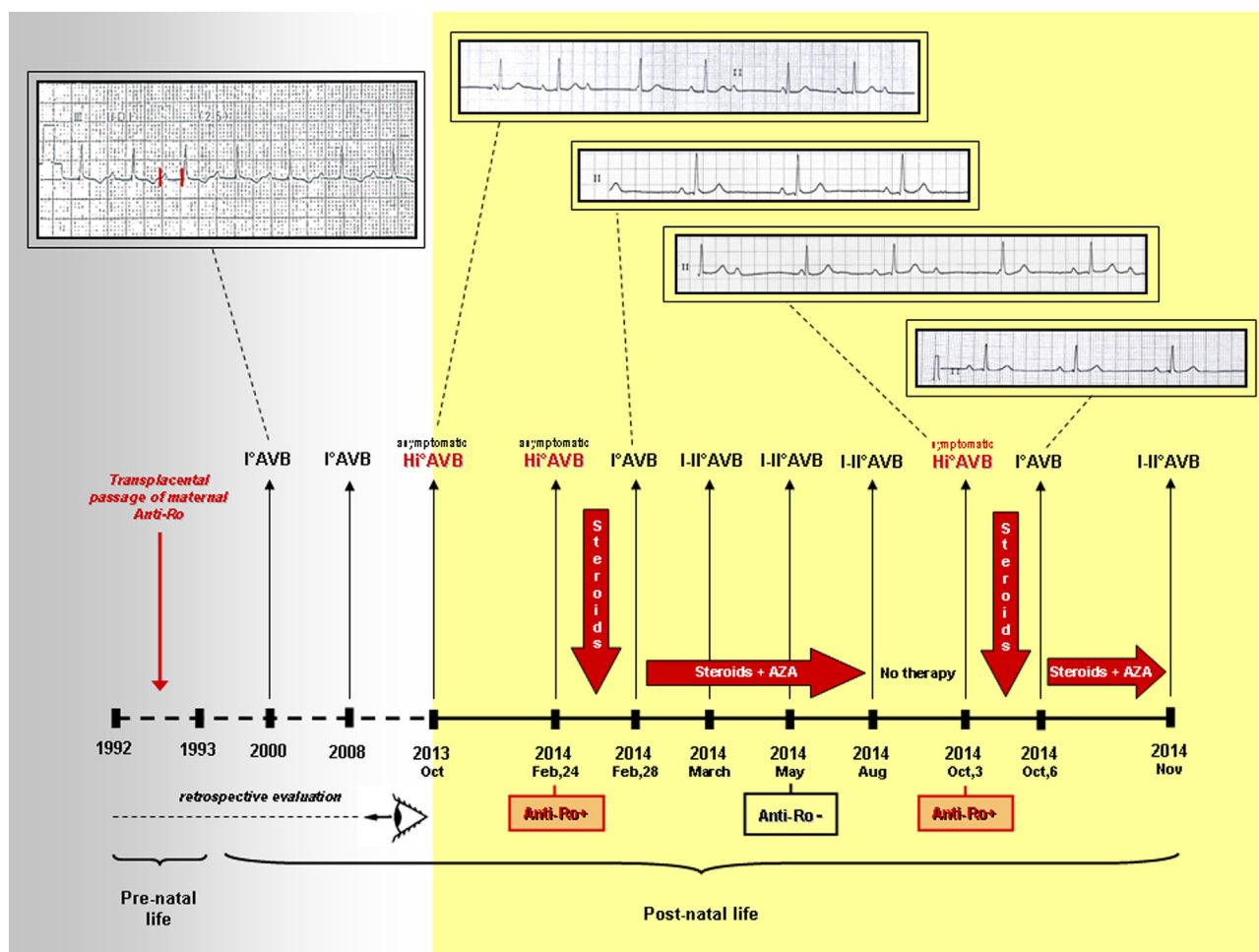


Figure 4 The time course of clinical, electrocardiographic, and laboratory changes, and immunosuppressive therapy in case 3. Gray: Data obtained from a retrospective evaluation of the patient and the patient’s mother. Yellow: Data obtained from the prospective evaluation of patient. Hi°AVB = high-grade atrioventricular block.

suggested by the complete recovery of the conduction disturbance soon after the onset of the steroid treatment. Conversely, the detection of anti-Ro/SSAs in the mother, but not in the patient, as well as the demonstration of signs of subclinical conduction system damage already present at the childhood stage (I°AVB at 9 years of age), identify the second case as a late-progressive congenital form.

Finally, in our opinion, the third case may represent a mixed form, in which both the mechanisms are involved. Indeed, the data suggest that, in this case, a peculiar “2-hits” autoimmune conduction system damage has developed. The first “hit” was the result of the transplacental passage of anti-Ro/SSAs that may have induced a subclinical congenital injury of the conduction system (incomplete AVB). The following development of a multiorgan autoimmune response, including anti-Ro/SSAs, during the postnatal life may have represented the second “hit” leading to the progression of the defect to high-grade AVB. Interestingly, another case of an anti-Ro/SSA-positive congenital-III°AVB (diagnosed as such at birth) followed by the development of anti-Ro/SSA in adult life has been already described,⁹ thus confirming the existence of this possibility as a probable result of the transmission of a “genetic

predisposition” to autoimmune response. The regression to incomplete AVB after immunosuppressive therapy in this patient further confirms that adult-onset anti-Ro/SSA-associated damage is reversible, whereas the fetal injury is permanent.

Noteworthy, in all the above-depicted cases, the presence of anti-Ro/SSA with pathogenic effects on the heart was not associated with clinical signs of autoimmune disease. In fact, patients 1 and 3 and the anti-Ro/SSA-positive mothers of patients 2 and 3 were totally asymptomatic. Although patients 1 and 3 had been previously diagnosed with autoimmune thyroiditis, they did not have clinical manifestations of CTD. This fact (in agreement with previous reports of anti-Ro/SSA-associated life-threatening rhythm disturbances in adult patients^{10,11}), with the evidence that anti-Ro/SSA-positive subjects in the general population are frequently asymptomatic for AD,¹² emphasizes the concept that in most cases only specific testing may reveal an anti-Ro/SSA-associated mechanism of disease in adult patients with isolated AVB of unknown origin.

The level of the block in these patients represents another intriguing issue. Indeed, whereas in children with congenital AVB it is generally localized at the AV node,¹³ our and

preliminary literature data¹⁰ suggest that in adult patients (particularly in the acquired form) the level of block may be more frequently distal to the bundle of His. It is currently unclear whether this feature is dependent on age-related differences in calcium channel density at the AV node vs the His-Purkinje system, and whether an electrophysiological study may provide useful diagnostic and prognostic information.

Finally, our report (particularly case 3) also suggests that an ELISA method alone is probably not able to detect all patients with anti-Ro/SSA-associated AVB, underscoring the crucial importance of completing anti-Ro/SSA testing using Western blot analysis in all patients whose ELISA results are negative. Further support of this view, also substantiated by previous data demonstrating a higher sensibility of Western blot in detecting anti-Ro/SSA-52kD with respect to immunoenzymatic methods,¹⁴ another case of anti-Ro/SSA-52kD-positive (blot only) III°AVB fully reversing after immunosuppressive therapy(acquired form) has been recently described.¹⁰

References

1. Brucato A, Cimaz R, Caporali R, Ramoni V, Buyon J. Pregnancy outcomes in patients with autoimmune diseases and anti-Ro/SSA antibodies. *Clin Rev Allergy Immunol* 2011;40:27–41.
2. Karnabi E, Boutjdir M. Role of calcium channels in congenital heart block. *Scand J Immunol* 2010;72:226–234.
3. Ambrosi A, Sonesson SE, Wahren-Herlenius M. Molecular mechanisms of congenital heart block. *Exp Cell Res* 2014;325:2–9.
4. Lazzerini PE, Capecchi PL, Laghi Pasini F. Anti-Ro/SSA antibodies and cardiac arrhythmias in the adult: facts and hypotheses. *Scand J Immunol* 2010;72: 213–222.
5. Lazzerini PE, Capecchi PL, Acampa M, Selvi E, Guideri F, Bisogno S, Rossi PC, Galeazzi M, Pasini FL. Arrhythmogenic effects of anti-Ro/SSA antibodies on the adult heart: more than expected? *Autoimmun Rev* 2009;9:40–44.
6. Lazzerini PE, Capecchi PL, Laghi-Pasini F. Isolated heart block of unknown origin in adults and anti-Ro/SSA antibodies: clinical evidence, putative mechanisms and therapeutic implications. *Heart Rhythm* 2015;12:449–454.
7. Villuendas R, Olivé A, Juncà G, Salvador I, Martínez-Morillo M, Santos-Pardo I, Pereferrer D, Zamora E, Bayes-Genis A. Autoimmunity and atrioventricular block of unknown etiology in adults: the role of anti-Ro/SSA antibodies. *J Am Coll Cardiol* 2014;63:1335–1336.
8. Bergman G, Skog A, Tingström J, Ottosson V, Hoxha A, Ambrosi A; Salomonsson S, Wahren-Herlenius M, Swedish Congenital Heart Block Study Group. Late development of complete atrioventricular block may be immune mediated and congenital in origin. *Acta Paediatr* 2014;103:275–281.
9. Reichlin M, Friday K, Harley JB. Complete congenital heart block followed by anti-Ro/SSA in adult life. Studies of an informative family. *Am J Med* 1988;84: 339–344.
10. Santos-Pardo I, Martínez-Morillo M, Villuendas R, Bayes-Genis A. Anti-Ro antibodies and reversible atrioventricular block. *N Engl J Med* 2013;368: 2335–2337.
11. Nakamura K, Katayama Y, Kusano KF, et al. Anti-KCNH2 antibody-induced long QT syndrome: novel acquired form of long QT syndrome. *J Am Coll Cardiol* 2007;50:1808–1809.
12. Hayashi N, Koshihara M, Nishimura K, Sugiyama D, Nakamura T, Morinobu S, Kawano S, Kumagai S. Prevalence of disease-specific antinuclear antibodies in general population: estimates from annual physical examinations of residents of a small town over a 5-year period. *Mod Rheumatol* 2008;18:153–160.
13. Ho SY, Esscher E, Anderson RH, Michaëlsson M. Anatomy of congenital complete heart block and relation to maternal anti-Ro antibodies. *Am J Cardiol* 1986;58:291–294.
14. Damoiseaux J, Boesten K, Giesen J, Austen J, Tervaert JW. Evaluation of a novel line-blot immunoassay for the detection of antibodies to extractable nuclear antigens. *Ann N Y Acad Sci* 2005;1050:340–347.