

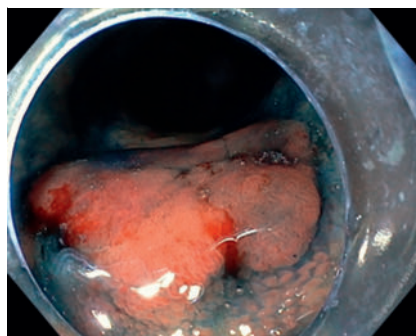
Endoscopic intermuscular dissection (EID) of a severely fibrotic benign rectal lesion in an area affected by radiation proctitis



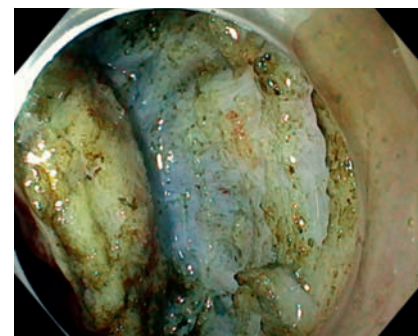
The rectum is the ideal part of the large bowel in which to perform deep excision for dysplastic lesions [1,2]. However, in cases of severe submucosal fibrosis and deep invasion of a carcinoma into the submucosa, performing endoscopic submucosal dissection can be very difficult. The intermuscular plane of dissection and myectomy of the inner muscular layer (endoscopic intermuscular dissection) previously have been described for treatment rectal neoplastic lesions, overcoming the compactness of the submucosa layer [3,4,5].

An 85-year-old man was referred to our department for a flat, 15-mm, dysplastic lesion (high-grade dysplasia [HGD]) close to the dentate line (► Fig. 1). Morphologically, the polyp was a Paris Classification 0-IIa, NICE Classification: 2 and LST-Classification: NG-Type/Flat elevated. The patient had completed radiotherapy for prostate cancer 14 months before our evaluation and was treated with mesalamine enemas. The surrounding rectal mucosa was scarred and compact with white stripes and telangiectasias as a secondary effect of radiation. We decided to perform a deeper excision into the intermuscular plane to avoid the severely fibrotic submucosal plane (► Fig. 2, ► Fig. 3, ► Fig. 4 and ► Video. 1). A single dose of broad-spectrum antibiotics was given interprocedurally to the patient. The defect remained open after the excision without any adverse events, such as bleeding, fever or pain, and the patient was discharged the next day (► Fig. 5). The pathology report revealed tubular adenoma with HGD radically resected. Follow-up endoscopy in 6 months later revealed almost complete healing of the defect (► Fig. 6).

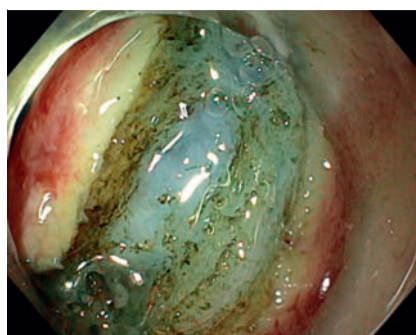
The dissection was performed between the inner circular and outer longitudinal muscles, instead of between the submucosal and muscle layers. The myectomy was achieved by using a Hook Knife (Olympus, Tokyo, Japan). Resecting be-



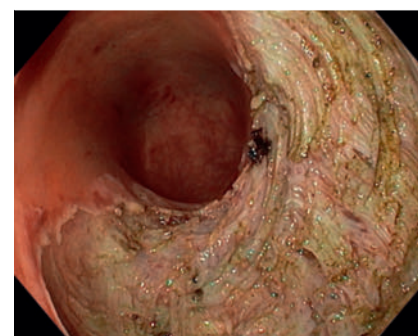
► Fig. 1 A 15-mm flat polyp in the area affected by radiation proctitis.



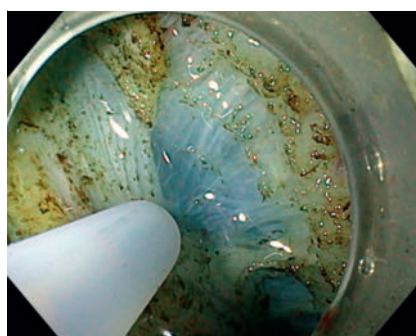
► Fig. 4 Dissection between the inner (circular) and outer (longitudinal) muscle layers.



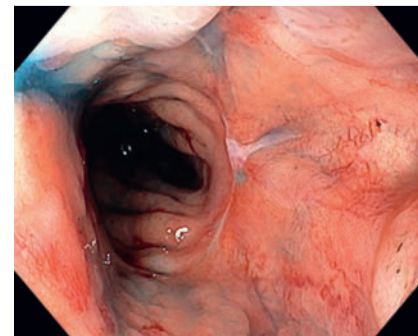
► Fig. 2 Inability to lift the compact and fibrotic submucosal space by fluid injection.



► Fig. 5 Open defect after removal of the dysplastic rectal lesion.

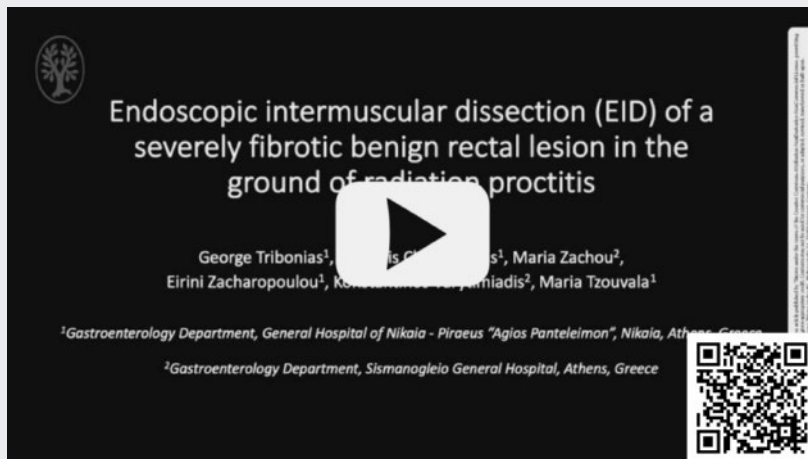

► Fig. 3 Fluid injection into the intermuscular space.



► Fig. 6 Healing of the dissection on follow-up endoscopy (6 months).

VIDEO



▶ **Video 1** Endoscopic intermuscular dissection (EID) of a dysplastic severely fibrotic benign rectal lesion.

nign severely fibrotic lesions in the rectum may constitute one of the advantages of EID, except in the case of resection of deeply infiltrative rectal carcinomas [5].

Video steps

HGD in the area affected by radiation proctitis
 Starting mucosal incision without adequate lifting due to fibrosis
 Compact and fibrotic submucosal space
 Changing knife for myotomy
 Entering intermuscular space
 Injection to expand the tiny intermuscular space
 Cautious intermuscular dissection
 After completing circumferential incision, continuing with dissection

Conflict of Interest

The authors declare that they have no conflict of interest.

The authors

George Tribonias¹, **Michail Christoulakis¹**,
Maria Zachou², **Eirini Zacharopoulou¹**,
Konstantinos Varytimiadis², **Maria Tzouvala¹**

- 1 Gastroenterology, General Hospital of Nikaia Peiraia Agios Panteleimon, Athens, Greece
- 2 Gastroenterology, Geniko Nosokomeio Attikes Sismanogleio Amalia Phlemink, Athens, Greece

Corresponding author

Dr. George Tribonias, PhD

General Hospital of Nikaia Peiraia Agios Panteleimon, Gastroenterology, D. Mantouvalou 3, 18454 Athens, Greece
 g.tribonias@gmail.com
 gtrimponias@gmail.com

References

- [1] Ohara Y, Toyonaga T, Tanaka S et al. Risk of stricture after endoscopic submucosal dissection for large rectal neoplasms. *Endoscopy* 2016; 48: 1–2 doi:10.1055/s-0034-139251426220284
- [2] Watanabe D, Toyonaga T, Ooi M et al. Clinical outcomes of deep invasive submucosal colorectal cancer after ESD. *Surg Endosc* 2018; 32: 2123–2130 doi:10.1007/s00464-017-5910-529098429
- [3] Rahni DO, Toyonaga T, Ohara Y et al. First reported case of per anal endoscopic myectomy (PAEM): A novel endoscopic technique for resection of lesions with severe fibrosis in the rectum. *Endosc Int Open* 2017; 5: E146–E150
- [4] Toyonaga T, Ohara Y, Baba S et al. Peranal endoscopic myectomy (PAEM) for rectal lesions with severe fibrosis and exhibiting the muscle-retracting sign. *Endoscopy* 2018; 50: 813–817
- [5] Moons LM, Bastiaansen B, Richir M et al. Endoscopic intermuscular dissection (EID) for deep submucosal invasive cancer in the rectum: a new endoscopic approach. *Endoscopy* 2022: doi:10.1055/a-1748-8573

Bibliography

Endosc Int Open 2023; 11: E733–E734
 DOI 10.1055/a-2109-8166
 ISSN 2364-3722

© 2023. The Author(s).

This is an open access article published by Thieme under the terms of the Creative Commons Attribution-NonDerivative-NonCommercial License, permitting copying and reproduction so long as the original work is given appropriate credit. Contents may not be used for commercial purposes, or adapted, remixed, transformed or built upon. (<https://creativecommons.org/licenses/by-nc-nd/4.0/>)

Georg Thieme Verlag KG, Rüdigerstraße 14, 70469 Stuttgart, Germany

