

Total hip arthroplasty after failed curved intertrochanteric varus osteotomy for avascular necrosis of the femoral head

Yasuhiko Takegami¹, MD; Daigo Komatsu¹, MD; Taisuke Seki¹, MD, PhD;
Naoki Ishiguro¹, MD, PhD; and Yukiharu Hasegawa², MD, PhD

¹Department of Orthopaedic Surgery, Nagoya University Graduate School of Medicine, Nagoya, Japan
²Department of Hip and Knee Reconstructive Surgery, Nagoya University Graduate School of Medicine, Nagoya, Japan

ABSTRACT

Curved intertrochanteric varus osteotomy (CVO) is one of the good surgical procedures for avascular necrosis of the femoral head (ANFH) patients. However, some patients with failed CVO are converted to total hip arthroplasty (THA) as a salvage operation. We compared the clinical and radiographic outcomes of 10 hips converted to THA after failed CVO (Group O) (mean age 43.0 years, 8 male and 2 female) with an age and gender matched control group of 20 hips that underwent primary THA for ANFH (Group C). Perioperative blood loss in Group O was significantly higher than that in Group C (535 g vs 282 g ($P = 0.002$)). Infection and dislocation occurred in 1 and 2 hips in Group O. There were no significant differences in both pre- and post-Harris Hip Score (HHS) between the groups. The stems in the AP radiograph were placed at 2.1° in a valgus position in Group O, whereas those in Group C were inserted at 1.0° in a varus position, a significant difference ($P = 0.01$). The stem alignment in the Lauenstein view in Group O was 1.2° in the extension position and in Group C was 0.4° in the flexion position, a significant difference ($P = 0.04$). THA after failed CVO provides with the stem inserted in a valgus and extension position. Operative bleeding was increased. THA after failed CVO is a technically demanding arthroplasty. We believe that careful preoperative planning and preparation are necessary for this arthroplasty.

Key Words: curved intertrochanteric osteotomy, total hip arthroplasty, osteonecrosis of the femoral head

INTRODUCTION

Avascular necrosis of the femoral head (ANFH) occurs predominantly in younger patients.¹ The weight-bearing area progresses to collapse and eventually to secondary osteoarthritis, restricting patients' daily activities and consequently leading to labor loss and decreased quality of life.^{2, 3} Total hip arthroplasty (THA) is a reasonable option at a later stage. However, long-term outcome of THA in young active patients is a considerable concern.⁴ It is preferable to try to preserve the patient's native joint if at all possible.⁵

Several surgical treatments aim to preserve native joints, including core depression,¹ intertrochanteric rotational osteotomy,⁶⁻¹⁰ pedicle-bone grafting,¹¹⁻¹³ intertrochanteric varus osteotomy,¹⁴ and curved intertrochanteric varus osteotomy (CVO).^{15, 16} The indications for CVO are the

Received: September 7, 2015; accepted: January 4, 2016

Corresponding author: Yasuhiko Takegami

Department of Orthopaedic Surgery, Nagoya University Graduate School of Medicine, 65 Tsurumai-cho, Showa-ku, Nagoya 466-8550, Japan

Tel: +81-52-741-211. Fax: +81-52-744-2260, Email: takegami@med.nagoya-u.ac.jp

potential to obtain cover of more than one-third of the intact articular surface on preoperative anteroposterior (AP) hip radiographs in maximum abduction and thus with an intact ratio of 30%.

Previous studies have reported success rates for CVO of 90–92%.^{15, 16)} Therefore, some patients with failed CVO are converted to THA as a salvage operation. However, the outcome of THA after failed CVO for ANFH is still unknown.

THA performed after intertrochanteric osteotomies for osteoarthritis are known to have higher perioperative and postoperative complication rates, from 17–25%, compared with patients without previous osteotomy.^{17, 18)} Although conversion to THA after failed transtrochanteric osteotomy for ANFH has provided a satisfactory clinical outcome, the operating time was increased and perioperative blood loss was increased compared with primary THA. Furthermore, the femoral stem was aligned in a varus or valgus malposition.^{19–21)}

The purpose of this study is to test whether, compared with primary THA, THA after CVO resulted in 1) a longer operating time and increased perioperative blood, 2) an inferior clinical outcome, and 3) stem malposition and higher complication rate (dislocation, infection, etc.).

MATERIALS AND METHODS

This study was approved by the institutional review board of our institute. The aim of the study was explained to, and written informed consent to participate was obtained from, each patient.

We compared the clinical and radiographic outcomes of 10 hips converted to THA after failed CVO (Group O) for ANFH with an age and gender matched control group of 20 hips that underwent primary THA for ANFH (Group C).

The diagnosis of ANFH was based on clinical presentation and imaging studies, including plain radiographs and magnetic resonance imaging findings and classified according to the Japanese Investigation Committee of Health and Welfare criteria.^{22, 23)}

The ANFH patients who had consistent pain with type B lesions were considered suitable for CVO. Furthermore, for patients with type C1 and type C2 lesions, we were able to obtain cover over more than one-third of the intact articular surface on preoperative AP hip radiographs in maximum abduction, thus with an intact ratio of 30%. An intact articulating circumference exceeding one-third of the entire articular circumference in the Lauenstein view was an indication for transtrochanteric rotational osteotomy (TRO).⁶⁾ Miyanishi *et al.* reported the minimum postoperative intact ratio necessary to prevent the progressive collapse of the femoral head during the initial ten years after a transtrochanteric rotational osteotomy was 34%.⁵⁾ Primary THA was indicated for the ANFH patients who were over 60 years of age, had a large collapsed area of the femoral head, or had osteoarthritic changes.

From 1990 to 2009, 112 hips were consecutively treated with CVO for ANFH at our university and affiliated hospitals. All operations were performed according to previous reports¹⁵⁾ or supervised by the senior surgeon (Y.H.). The osteotomy fragments had been stabilized by several screws or by a compression hip screw (Meira Co., Nagoya, Japan), and all metals were already removed.

From 1991 to 2009, 11 hips were converted to THA at our university hospital due to pain or loss of activity as a result of femoral head collapse or progression of secondary osteoarthritic changes. After 1 hip was excluded because the follow-up period was <1 year, we investigated 10 hip joints in 10 patients followed for at least 1 year. Eight patients were men, and 2 were women. The average age of the patients undergoing CVO was 38.1 years (range, 20–48), and for those undergoing conversion to THA, it was 43.0 years (range, 25–58). The average time

Table 1 Patient demographics

	Group O	Group C	P value
No. of hips	10	20	
Age, y	43.0 (25–58)	43.1 (21–59)	1
Sex (male/female)	8/2	16/4	1
BMI, kg/m ²	22.6 ± 3.2	23.0 ± 2.8	0.2
Etiology of AVFN, n			1
Steroid	6	10	
Alcohol	4	10	
Type, n			0.01
C1	6	2	
C2	4	18	
Stage, n			0.05
2	0	0	
3A	0	0	
3B	1	14	
4	9	6	
Follow-up, m	61 (20–126)	88 (12–168)	0.16

Results are shown as mean (range), n, or mean ± standard deviation.

Abbreviation: ANFH, avascular necrosis of the femoral head.

between CVO and conversion to THA was 58.4 months (range, 6–127) . The average follow-up after THA was 61 months (range, 20–126) (Group O).

During the same period, 20 age- and sex-matched patients (16 men and 4 women) undergoing primary THA, with no previous osteotomy, were selected as the control group (Group C). Their average age was 43.1 (range, 21–59) years.

In Group O, the ANFH was steroid-induced in 6 patients and alcohol-associated in 4 patients. In Group C, the ANFH was steroid-induced in 10 patients and alcohol-associated in 10 patients.

According to the classification of the Japanese Investigation Committee of Health and Welfare,^{22, 23)} in Group O, 6 hips were classified as type C1 and 4 hips as type C2. In Group C, before CVO, 2 hips were stage 2, 5 were stage 3A, 3 were stage 3B, and 1 was stage 4. At the time of conversion to THA, all 10 hips were type C1; 1 was stage 3B, and 9 were stage 4. In Group C, 2 were type C1 and 18 were type C2; 14 hips were stage 3B, and 6 hips were stage 4. (Table 1)

All THA surgeries were performed or supervised by 1 senior surgeon (Y.H.). All operations were carried out through the posterolateral approach. We tried to place the acetabular socket in 20° anteversion and 45° abduction with Urushitani's socket guide.²⁴⁾ We tried to position the stem in 20° anteversion using the lower leg as a reference. The femoral neck was distorted due to deformation from the previous osteotomy. Furthermore, new sclerotic bone was formed in the medial intertrochanteric lesion.¹⁵⁾ We used a power saw and/or burr to remove sclerotic bone in the medial intertrochanteric lesion.

We used Securefit (Stryker Orthopaedics, Mahwah, NJ), Trident (Howmedica Osteonics), and TriAD (Stryker Orthopaedics, Mahwah, NJ) sockets in 1, 5, and 4 hips in Group O and 2, 14,

and 4 hips in Group C, respectively.

We used a cementless and cement femoral stem. In Group O, Securfit (Stryker Orthopaedics) cementless stems were used in 8 hips; the Exeter (Stryker Howmedica Osteonics) stem in 2 hips. In Group C, SuperSecurfit cementless stems were used in 16 hips; and in 4 hips and the OmnifitEON (Stryker Orthopaedics) cement stem. We used an alumina head and an alumina liner in all hips in the Group O. An alumina head and an alumina liner were used in 13 hips; and a metal liner and a polyethylene liner in 7 hips in the Group C. The femoral head diameter was 28 mm in all hips.

Patients were followed clinically and radiographically each year after the operation. We compared the operation time, perioperative blood loss, cup position, and stem alignment between Groups O and C. We also compared postoperative complications, HHS,²⁵⁾ and radiologic results at the final follow-up.

Abduction and anteversion angles of the sockets and alignment of the femoral stems were measured at the final follow-up anteroposterior and Lauenstein radiographs on the electrical medical records (EGMAIN-NX; Fujitsu). The abduction and anteversion of the socket was calculated using the method of Lewinnek *et al.*²⁶⁾ Sockets with an abduction angle of $<30^\circ$ or $>50^\circ$ or with an anteversion angle of $<10^\circ$ or $>30^\circ$ were considered outliers.

Stem alignment was determined by measuring the angle formed between the longitudinal axis of the femoral stem and the longitudinal axis of the femoral canal.^{27, 28)}

The fixation of the femoral stem was classified by the method of Engh *et al.*²⁹⁾ and the fixation of the socket by the method of Latimer and Lachiewicz.³⁰⁾

Radiographs were evaluated by 2 independent observers (T.Y. and K.D.). For interobserver measurement, the interclass correlation coefficient (ICC) of stem alignment was 0.86 (95% confidence interval (CI), 0.51–0.97). The ICC of socket angle was 0.89 (95% confidence interval, 0.59–0.97).

We used the Fisher's exact test for categorical variables and the Mann-Whitney *U* test for numerical variables. All reported *P* values were 2-sided, and $P < 0.05$ was used to determine significance. For all statistical analysis, we used R software.³¹⁾

RESULTS

Clinical assessment

Perioperative blood loss in Group O (535 g; range, 288–915 g) was significantly higher than that in Group C (282 g; range, 60–765 g) ($P = 0.002$). The operating time of 116 (range, 79–165) minutes in Group O was not significantly longer than the 113 (range, 68–190) minutes in Group C ($P = 0.79$).

Infection and dislocation occurred in 1 and 2 hips, respectively, in Group O, but no perioperative complications were observed in Group C ($P = 0.06$). The infection occurred 8 years after conversion THA. The infection was deep. One-stage revision THA was performed. Dislocation occurred due to fall in all cases. The time of each dislocation is 10 months and 5 years after the THA. They were treated by closed reduction.

The average HHS before THA in Group O was 53.8 (range, 38–78) points, which improved to 89.7 (range, 76–98) points at the final follow-up. The average HHS before THA in Group C was 56.3 (range, 29–82) points, which improved to 88.6 (range, 55–98) points at the final follow-up. There were no significant differences in both pre- and post-HHS between the groups ($P = 0.62$ and 0.76 , respectively).

Radiological assessment

The abduction angle in the Group C was 47.0 degree, whereas that in the group O was 40.7 degree. The anteversion were 14 degree in Group C and 13.5 in Group O. There was significant difference in the socket abduction. ($P = 0.007$) In Group O, 5 of 10 sockets were within the Lewinnek safe zone, whereas 15 of 20 sockets in Group C were within this target region, with no significant difference between the groups ($P = 0.23$) (Figure 1).

The stems in the AP radiograph were placed at 2.1° in a valgus position (range, -2 to 6°) in Group O, whereas those in Group C were inserted at 1.0° in a varus position (range, -2 to 4°), a significant difference ($P = 0.01$). The stem alignment in the Lauenstein view in Group O was 1.2° in the extension position (range, -4 to 6°) and in Group C was 0.4° in the flexion position (range, 0 to 3°), a significantly difference ($P = 0.04$). (Figure 2)

A representative case is presented in Figure 3.

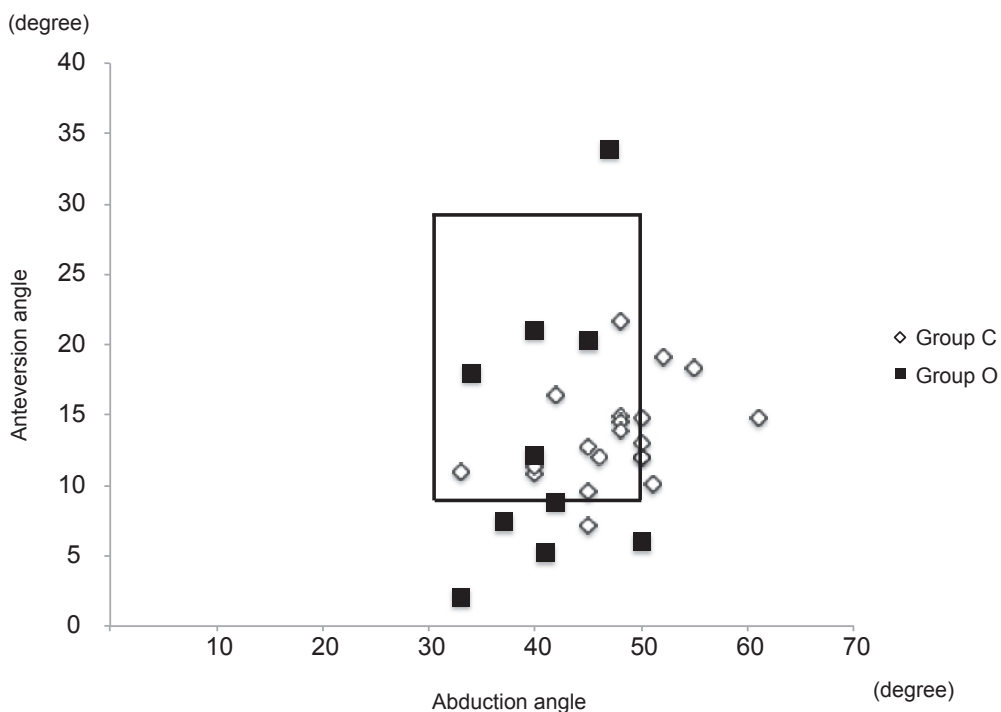


Fig. 1 Socket position.

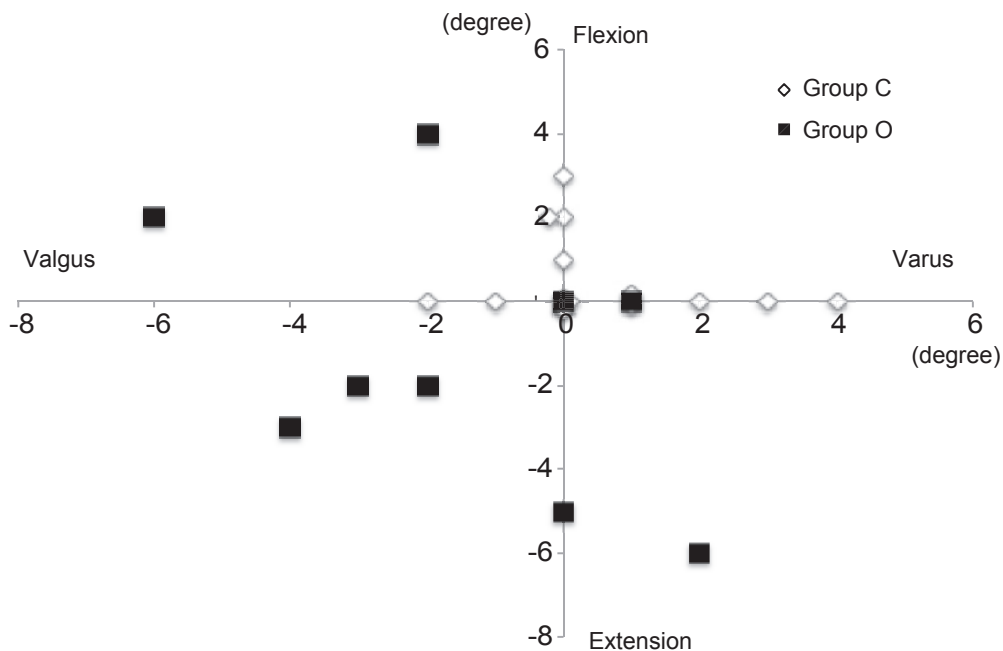


Fig. 2 Stem alignment. More stems in Group O were placed in the valgus position in comparison with those of Group C.

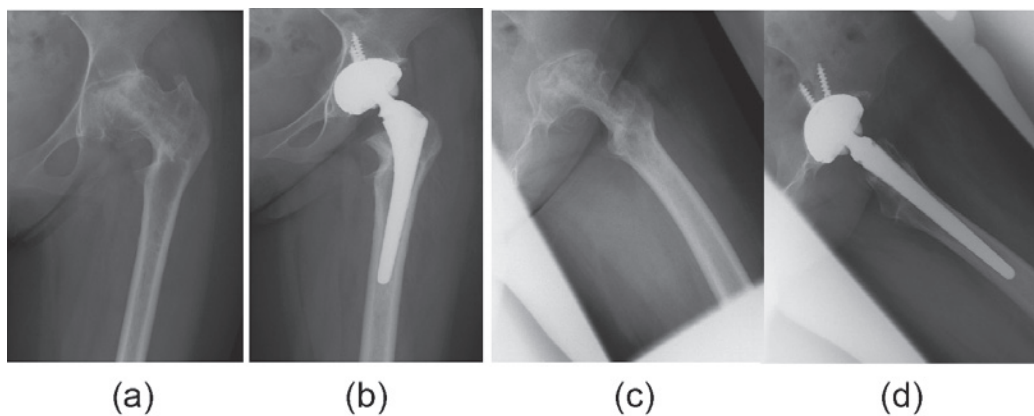


Fig. 3 Representative case of a 24-year-old woman with steroid-induced ANFH after CVO. (a) Preoperative AP view. (b) Stem alignment was 4 degrees valgus, and cup alignments were 45 degrees abduction and 12 degrees anteversion. (c) Preoperative Lauenstein view. (d) Stem alignment was 3.0 degrees in extension.

DISCUSSION

THA is a reliable treatment for reducing pain and regaining quality of life for end-stage ANFH patients. However, cup failure is relatively common even in non-ANFH THA.³²⁾ Because ANFH usually occurs in young adults, it is preferable to avoid or postpone THA. CVO is a

useful alternative treatment for young ANFH patients. Using CVO, Zhao *et al.*¹⁶⁾ reported a 91.8% success rate in 73 ANFH cases after 12 years of follow-up, and we also have a 90.1% success rate in 112 cases, indicating that some CVO patients will need to convert to THA if their femoral head collapse has progressed.

Previous reports about THA after varus or valgus osteotomy of the proximal femur for osteoarthritis of the hips have been reported.^{17, 18)} These reports discuss THA after femoral osteotomy as a technically demanding procedure. However, to our knowledge, there has been no report specifically regarding THA after CVO for hip disorders. We believe this is the first report of the conversion to THA after failed CVO.

Clinical outcomes

In our study, blood loss was significantly greater in THA after CVO than in primary THA, but the operation time did not significantly differ between groups. In several studies, the perioperative blood loss was greater and the operative time was longer significantly in the conversion group than in the primary THA group.^{19, 20, 33)} These results also suggest the technical difficulties in THA after femoral osteotomy, including CVO. Park *et al.*¹⁹⁾ reported a longer operation time due to the time taken for screw removal. While, our operative time in the THA after CVO group is not longer than in the primary THA group because we had removed all metal before the conversion to THA.

We observed postoperative complications only in the THA after failed CVO. Our postoperative complication observed in 3(30%) of 10. But there were not lasting clinical problems in these patients. Previous studies reported postoperative complications of THA after femoral osteotomy from 7 to 14%.^{18, 20, 33, 34)}

We reported that the clinical outcomes (HHS) were not significantly different. Several previous reports about THA after femoral osteotomy also showed similar results.^{19-21, 34)}

Radiographic assessment

About the socket position, there was no significant difference in the number of Lewinnek's safe zone outliers. However, the abduction of the socket decreased in the THA after CVO significantly.

Our study shows that the risk of stem valgus malposition in the AP view and extension insertion in the Lauenstein view were increased. ($P = 0.01$ and 0.03 , respectively). The stability of all prostheses in our study was bony ingrowth or stable fixation. After CVO, marked new bone formation was observed in the medial intertrochanteric region.¹⁵⁾ THA after a previous TRO also increased stem malposition because these rotational changes affected the anteversion of the stem and masked the landmark for stem insertion.³³⁾ CVO results in few changes of the greater trochanter, unlike TRO. Therefore, the medial intertrochanteric new bone formation exerts a greater influence than the greater trochanter abnormality. As a result, the stem was possibly inserted in the valgus position. Using a burr may be effective to remove sclerotic bone in the medial intertrochanteric lesion or choosing modular stem instead of straight stem. Preoperative templating and using image intensifiers in the operation room would help to confirm an accurate stem insertion.

There were several limitations to our study. First, the follow-up was short (maximum 8 years). Second, the sample size was small. However, THA after CVO has been relatively rare. Third, manual radiographic measurement of the socket and femoral stem component is less accurate than other methods, such as computer-assisted technologies. Thereby we were not able to measure the femoral stem anteversion and the actual socket position. However, the simplicity of radiographic measurement methods can have financial and clinical benefits for postoperative assessment. Fourth, the operations were not performed by 1 surgeon, and there was no objective

evaluation of surgical skill between residents. Fifth, the prosthesis was different. However, we have never seen mechanical failure in our series.

CONCLUSION

THA after failed CVO provides satisfactory clinical outcomes in comparison with primary THA. The stem inserted in a valgus and extension position and operative bleeding was increased. THA after failed CVO is a technically demanding arthroplasty. We believe that careful preoperative planning and preparation are necessary for this arthroplasty.

ACKNOWLEDGEMENT

My deepest appreciation goes to Kazuma Ikeuchi MD who provided helpful comments and suggestions. I also owe a very important debt to Takafumi Amano MD, Takehiro Kasai MD and Yoshitoshi Higuchi MD whose comments made enormous contribution to my work.

The authors have declared no conflicts of interest in this study.

REFERENCES

- 1) Mont MA, Hungerford DS. Non-traumatic avascular necrosis of the femoral head. *J Bone Joint Surg Am*, 1995; 77: 459–474.
- 2) Nakai T, Masuhara K, Matsui M, Ohzono K, Ochi T. Therapeutic effect of transtrochanteric rotational osteotomy and hip arthroplasty on quality of life of patients with osteonecrosis. *Arch Orthop Trauma Surg*, 2000; 120: 252–254.
- 3) Seki T, Hasegawa Y, Masui T, Yamaguchi J, Kanoh T, Ishiguro N, Kawabe K. Quality of life following femoral osteotomy and total hip arthroplasty for nontraumatic osteonecrosis of the femoral head. *J Orthop Sci*, 2008; 13: 116–121.
- 4) Kim Y-H, Kim J-S, Park J-W, Joo J-H. Contemporary total hip arthroplasty with and without cement in patients with osteonecrosis of the femoral head: a concise follow-up, at an average of seventeen years, of a previous report. *J Bone Joint Surg Am*, 2011; 93: 1806–1810.
- 5) Mont M a, Zywiell MG, Marker DR, McGrath MS, Delanois RE. The natural history of untreated asymptomatic osteonecrosis of the femoral head: a systematic literature review. *J Bone Joint Surg Am*, 2010; 92: 2165–2170.
- 6) Sugioka Y, Hotokebuchi T, Tsutsui H. Transtrochanteric anterior rotational osteotomy for idiopathic and steroid-induced necrosis of the femoral head. Indications and long-term results. *Clin Orthop Relat Res*, 1992; 277: 111–120.
- 7) Iwasada S, Hasegawa Y, Iwase T, Kitamura S, Iwata H. Transtrochanteric rotational osteotomy for osteonecrosis of the femoral head. 43 patients followed for at least 3 years. *Arch Orthop Trauma Surg*, 1997; 116: 447–53.
- 8) Sugioka Y. Transtrochanteric rotational osteotomy in the treatment of idiopathic and steroid-induced femoral head necrosis, Perthes' disease, slipped capital femoral epiphysis, and osteoarthritis of the hip. Indications and results. *Clin Orthop Relat Res*, 1984; 184: 12–23.
- 9) Rijnen WHC, Gardeniers JWM, Westrek BLM, Buma P, Schreurs BW. Sugioka's osteotomy for femoral-head necrosis in young Caucasians. *Int Orthop*, 2005; 29: 140–144.
- 10) Eyb R, Kotz R. The transtrochanteric anterior rotational osteotomy of Sugioka. Early and late results in idiopathic aseptic femoral head necrosis. *Arch Orthop Trauma Surg*, 1987; 106: 161–167.
- 11) Hasegawa Y, Sakano S, Iwase T, Iwasada S, Torii S, Iwata H. Pedicle bone grafting versus transtrochanteric rotational osteotomy for avascular necrosis of the femoral head. *J Bone Joint Surg B*, 2003; 85: 191–198.
- 12) Hasegawa Y, Torii S, Iwasada S, Kitamura S, Kubo T, Iwata H. Pedicle bone grafting versus transtrochanteric rotational osteotomy for idiopathic osteonecrosis of the femoral head--four patients with both procedures. *Nagoya J Med Sci*, 1999; 62: 47–55.

- 13) Iwata H, Torii S, Hasegawa Y, Itoh H, Mizuno M, Genda E, Kataoka Y. Indications and results of vascularized pedicle iliac bone graft in avascular necrosis of the femoral head. *Clin Orthop Relat Res*, 1993; 295: 281–288.
- 14) Nishio A, Sugioka Y. A New Technique of the Varus Osteotomy at the Upper End of the Femur. *Orthop Traumatol*, 1971(in Japanese); 20: 381–386.
- 15) Sakano S, Hasegawa Y, Torii Y, Kawasaki M, Ishiguro N. Curved intertrochanteric varus osteotomy for osteonecrosis of the femoral head. *J Bone Joint Surg Br*, 2004; 86: 359–365.
- 16) Zhao G, Yamamoto T, Ikemura S, Motomura G, Mawatari T, Nakashima Y, Iwamoto Y. Radiological outcome analysis of transtrochanteric curved varus osteotomy for osteonecrosis of the femoral head at a mean follow-up of 12.4 years. *J Bone Joint Surg Br*, 2010; 92: 781–786.
- 17) Benke GJ, Baker AS, Dounis E. Total hip replacement after upper femoral osteotomy. A clinical review. *J Bone Joint Surg Br*, 1982; 64: 570–571.
- 18) Ferguson GM, Cabanela ME, Ilstrup DM. Total hip arthroplasty after failed intertrochanteric osteotomy. *J Bone Joint Surg Br*, 1994; 76: 252–257.
- 19) Park K-S, Tumin M, Peni I, Yoon T-R. Conversion Total Hip Arthroplasty After Previous Transtrochanteric Rotational Osteotomy for Osteonecrosis of the Femoral Head. *J Arthroplasty*, 2014; 29: 813–816.
- 20) Kawasaki M, Hasegawa Y, Sakano S, Masui T, Ishiguro N. Total Hip Arthroplasty After Failed Transtrochanteric Rotational Osteotomy for Avascular Necrosis of the Femoral Head. *J Arthroplasty*, 2005; 20: 574–579.
- 21) Rijnen WHC, Lameijn N, Schreurs BW, Gardeniers JWM. Total hip arthroplasty after failed treatment for osteonecrosis of the femoral head. *Orthop Clin North Am*, 2009; 40: 291–298.
- 22) Ohzono K, Saito M, Takaoka K, Ono K, Saito S, Nishina T, Kadowaki T. Natural history of nontraumatic avascular necrosis of the femoral head. *J Bone Joint Surg Br*, 1991; 73: 68–72.
- 23) Sugano N, Kubo T, Takaoka K, Ohzono K, Hotokebuchi T, Matsumoto T, Igarashi H, Ninomiya S. Diagnostic criteria for non-traumatic osteonecrosis of the femoral head. A multicentre study. *J Bone Joint Surg Br*, 1999; 81: 590–595.
- 24) Kanoh T, Hasegawa Y, Masui T, Yamaguchi J, Kawabe K, Ishiguro N. Accurate acetabular component orientation after total hip arthroplasty using an acetabular alignment guide. *J Arthroplasty*, 2010; 25: 81–86.
- 25) Harris WH. Traumatic arthritis of the hip after dislocation and acetabular fractures: treatment by mold arthroplasty. An end-result study using a new method of result evaluation. *J Bone Joint Surg Am*, 1969; 51: 737–755.
- 26) Lewinnek GE, Lewis JL, Tarr R, Compere CL, Zimmerman JR. Dislocations after total hip-replacement arthroplasties. *J Bone Joint Surg Am*, 1978; 60: 217–220.
- 27) Khalily C, Lester DK. Results of a tapered cementless femoral stem implanted in varus. *J Arthroplasty*, 2002; 17: 463–466.
- 28) Martell JM, Pierson RH, Jacobs JJ, Rosenberg AG, Maley M, Galante JO. Primary total hip reconstruction with a titanium fiber-coated prosthesis inserted without cement. *J Bone Joint Surg Am*, 1993; 75: 554–571.
- 29) Engh CA, Glassman AH, Suthers KE. The case for porous-coated hip implants. The femoral side. *Clin Orthop Relat Res*, 1990; 261: 63–81.
- 30) Latimer HA, Lachiewicz PF. Porous-coated acetabular components with screw fixation. Five to ten-year results. *J Bone Joint Surg Am*, 1996; 78: 975–981.
- 31) Ross Ihaka and Robert Gentleman. R: Language for Data Analysis and Graphics. *J Comput Graph Stat*, 1996; 5: 299–314.
- 32) Issa K, Pivec R, Kapadia BH, Banerjee S, Mont MA. Osteonecrosis of the femoral head: the total hip replacement solution. *Bone Joint J*, 2013; 95-B(11 Suppl A): 46–50.
- 33) Lee Y-K, Ha Y-C, Kim K-C, Yoo JJ, Koo K-H. Total hip arthroplasty after previous transtrochanteric anterior rotational osteotomy for femoral head osteonecrosis. *J Arthroplasty*, 2009; 24: 1205–1209.
- 34) Boos N, Krushell R, Ganz R, Müller ME. Total hip arthroplasty after previous proximal femoral osteotomy. *J Bone Joint Surg Br*, 1997; 79: 247–253.