

Cerebral Venous Sinus Thrombosis as the First Manifestation of *JAK2*^{V617F}-positive Essential Thrombocythemia

Wei-Bi Chen, Xian-Ling Wang

Department of Neurology, Xuanwu Hospital, Capital Medical University, Beijing 100053, China

To the Editor: Essential thrombocythemia (ET) complicated by cerebral venous sinus thrombosis (CVST) is exceptionally rare. Hitherto, few studies have mentioned the role of Janus kinase 2V617F (*JAK2*^{V617F}) mutation in ET patients who developed CVST; thus, the strategy and long-term outcomes are yet rarely reported. The present study documented four cases, wherein CVST was the first manifestation of *JAK2*^{V617F}-positive ET.

The first case of a 33-year-old woman presented with a 1-year history of headache. Further examination revealed papilledema. Considering the slight elevated intracranial pressure (ICP) together with normal cerebral spinal fluid (CSF) and brain magnetic resonance (MR) imaging [Figure 1a], she was initially misdiagnosed with benign intracranial hypertension. However, the MR venogram showed occlusion of superior sagittal sinus, straight sinus, and bilateral transverse sinus [Figure 1b and 1c]. After administering anticoagulation therapy (low-molecular-weight heparin [LMWH], followed by warfarin), headache was slowly relieved. Due to thrombocytosis ($457\text{--}593 \times 10^9/\text{L}$), bone marrow aspiration was performed, which revealed hyperplasia of mature megakaryocytes and *JAK2*^{V617F} mutation. Subsequently, hydroxyurea (HU) and aspirin were prescribed and platelet counts were controlled. However, the patient discontinued the above medication after 4 years. Two months later, attacks of dizziness and blurred vision occurred in the patient. Further physical examination did not reveal papilledema but mild hemiparesis. ICP and platelet counts were normal. MR imaging displayed multiple lacunar infarctions [Figure 1d]. Consequently, the patient was prescribed aspirin twice a day combined with close monitoring of the platelet counts for cytoreduction as necessary.

Another case of a 34-year-old woman presented with a 19-day history of headache and vomiting, which were considered as early pregnancy symptoms after a positive pregnancy test. However, she lapsed into unconsciousness after 6 days. Neurological examination showed lethargy with neck stiffness and papilledema. Babinski's sign was also observed. Cranial MR demonstrated thrombosis of the great cerebral vein, straight sinus, right transverse sinus, and sigmoid sinus together with infarction in the bilateral thalamus. Lumbar puncture showed a high ICP with acellular CSF. Furthermore, thrombocytosis ($330\text{--}593 \times 10^9/\text{L}$) was noted. *JAK2*^{V617F}-positive ET was confirmed after bone marrow biopsy and gene testing. The patient was subjected to abortion, followed

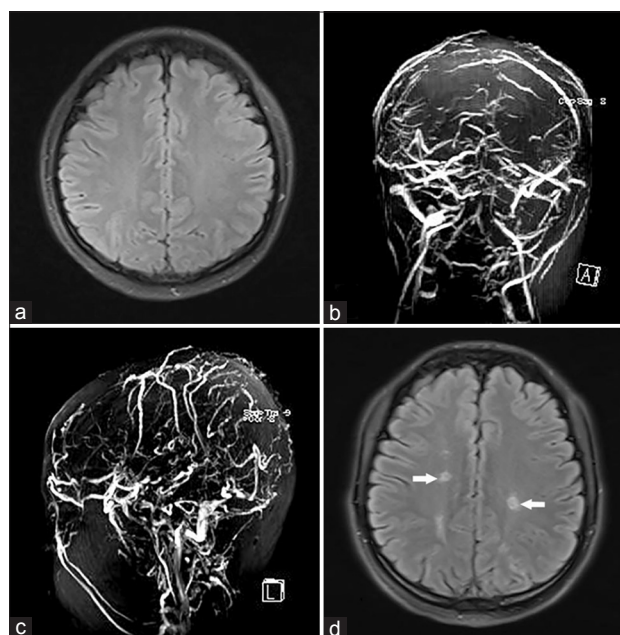


Figure 1: Cerebral venous sinus thrombosis as the first manifestation of *JAK2*^{V617F}-positive essential thrombocythemia (case 1). An axial T2-weighted MR scan of the brain was normal during the first hospital admission (a). MR angiography showed occlusion of superior sagittal sinus, straight sinus, and bilateral transverse sinus with enriched scalp and superficial vein during the first hospital admission (b and c). Multiple lacunar cerebral infarctions (white arrows) were found in axial T2-weighted MR scan during the second hospital admission (d). *JAK2*^{V617F}: Janus kinase 2V617F; MR: Magnetic resonance.

by treatment with antithrombotic therapy (LMWH, warfarin, and then aspirin). The platelet counts were well controlled after using

Address for correspondence: Prof. Xian-Ling Wang,

Department of Neurology, Xuanwu Hospital, Capital Medical University,
No. 45, Changchun Street, Xicheng District, Beijing 100053, China
E-Mail: xlwang6@yahoo.com

Access this article online

Quick Response Code:



Website:
www.cmj.org

DOI:
10.4103/0366-6999.226903

This is an open access article distributed under the terms of the Creative Commons Attribution-NonCommercial-ShareAlike 3.0 License, which allows others to remix, tweak, and build upon the work non-commercially, as long as the author is credited and the new creations are licensed under the identical terms.

© 2018 Chinese Medical Journal | Produced by Wolters Kluwer - Medknow

Received: 14-12-2017 **Edited by:** Peng Lyu

How to cite this article: Chen WB, Wang XL. Cerebral Venous Sinus Thrombosis as the First Manifestation of *JAK2*^{V617F}-positive Essential Thrombocythemia. Chin Med J 2018;131:748-50.

interferon- α (IFN- α). The patient was adequately healthy in the following 6 years.

The next patient was a 71-year-old man who had a history of mild headache for 1 year, which aggravated recently after diarrhea. Physical examination showed impaired memory and attention. MR imaging revealed venous infarction in the bilateral thalamus, para-ventricle, and corpus callosum as well as occlusion of superior sagittal sinus, straight sinus, and bilateral transverse sinus. Lumbar puncture showed a high ICP and an acellular CSF. Furthermore, thrombocytosis ($460\text{--}759 \times 10^9/\text{L}$) was evident. *JAK2^{V617F}*-positive ET was confirmed by bone marrow biopsy and gene testing. The patient was administered only antithrombotic therapy (LMWH, warfarin, and then aspirin) as he denied cytoreduction. The above symptoms improved slowly and no further thrombotic events were observed in the subsequent 6 years.

The last patient of a 43-year-old man presented headache and numbness in the left limbs for 3 months. These symptoms were misdiagnosed as cervical spondylosis previously until an episode of convulsion occurred 2 months ago. Thus, head MR imaging was performed, which demonstrated cerebral venous infarction

in the right hemisphere. Further physical examination exhibited bilateral papilledema together with left-sided hemiparesis and hypoesthesia. Digital subtraction angiography revealed occlusion of superior sagittal sinus, right transverse sinus, and sigmoid sinus. After selective thrombolysis and thrombectomy, superior sagittal sinus was recanalized. However, during the anticoagulation therapy, superior sagittal sinus was reoccluded and had to be recanalized by the second thrombectomy. During hospitalization, thrombocytosis ($352\text{--}506 \times 10^9/\text{L}$) was noted. Bone marrow examination revealed megakaryocytic hyperplasia and *JAK2^{V617F}* mutation. As a result, HU and antithrombotic (LMWH, warfarin, and then aspirin) were carried out. The patient did not experience any further attacks in the following 12 months.

Herein, we reported four cases with CVST, a rare manifestation, and *JAK2^{V617F}*-positive ET, which emphasized the thrombotic potential of this disease. The detailed characteristics were summarized in Table 1.

According to the World Health Organization (WHO) criteria,^[1] these patients were diagnosed as ET. ET is characterized by excessive production of platelets, which might present thrombotic

Table 1: Clinical characteristics of four patients with CVST associated with *JAK2^{V617F}*-positive ET

Patient	Age (years), sex	Symptom	Examination	Platelet ($\times 10^9/\text{L}$)	MR imaging	MR venogram or DSA	<i>JAK2^{V617F}</i> mutation	Bone marrow biopsy	Therapy
1 (1 st attack)	33, female	Headache	Papilledema	457–593	Normal	Occlusion of superior sagittal sinus, straight sinus, and bilateral transverse sinus	Positive (bone marrow)	Megakaryocytic hyperplasia	LMWH, warfarin, hydroxyurea, aspirin
1 (2 nd attack)		Dizziness and blurred vision	Mild hemiparesis	181	Multiple lacunar infarctions	Stenosis of superior sagittal sinus, straight sinus, and bilateral transverse sinus			Aspirin
2	34, female	Headache	Lethargy with neck stiffness and papilledema	330–593	Infarction in the bilateral thalamus	Thrombosis of the great cerebral vein, straight sinus, right transverse sinus, and sigmoid sinus	Positive (blood and bone marrow)	Megakaryocytic hyperplasia	LMWH, warfarin, interferon- α , aspirin
3	71, male	Headache	Impaired memory and attention	460–759	Venous infarction in the bilateral thalamus, para-ventricle, and corpus callosum	Occlusion of superior sagittal sinus, straight sinus, and bilateral transverse sinus	Positive (blood)	Megakaryocytic hyperplasia	LMWH, warfarin, aspirin
4 (1 st attack)	43, male	Headache, left limb numbness, and convulsion	Papilledema, left-sided hemiparesis, and hypoesthesia	456	Cerebral venous infarction in the right hemisphere	Occlusion of superior sagittal sinus, right transverse sinus, and sigmoid sinus	Positive (bone marrow)	Megakaryocytic hyperplasia	Selective thrombolysis, Endovascular thrombectomy, LMWH, warfarin
4 (2 nd attack)		Headache and partial status epilepticus	Papilledema, left-sided hemiparesis, and hypoesthesia	352–506	Cerebral venous infarction in the right hemisphere	Occlusion of superior sagittal sinus, right transverse sinus, and sigmoid sinus			Endovascular thrombectomy, LMWH, warfarin, hydroxyurea, aspirin

CVST: Cerebral venous sinus thrombosis; ET: Essential thrombocythemia; *JAK2^{V617F}*: Janus kinase 2V617F; MR: Magnetic resonance; LMWH: Low-molecular-weight heparin; DSA: Digital subtraction angiography.

diathesis. The *JAK2*^{V617F} mutation has been identified in 57% of the patients with ET,^[2] which might indicate a high risk of thrombosis. A meta-analysis of 2436 patients and a systematic review of 3150 patients confirmed that a *JAK2*^{V617F} mutation status was associated with a significantly increased risk of thrombosis as compared to wild type.^[3-4]

The first manifestation was CVST in the four latent ET patients. Usually, for acute CVST, anticoagulant therapy with heparin or LMWH is recommended.^[5] Moreover, the prevention of rethrombosis is also crucial. To determine the likelihood of rethrombosis, the International Prognostic Score of thrombosis^[6] was estimated in WHO-ET by assigning the risk scores. ET is subsequently devised in a three-tiered prognostic model: low risk, intermediate risk, and high risk. Considering the complication of CVST and *JAK2*^{V617F}-mutated state, these were classified into high-risk ET patients. In addition, cytoreductive therapy was recommended for high-risk ET patients.^[7] Except for case 3, who refused the procedure, the others were administered contemporary cytoreduction (HU or IFN- α) and antithrombotic therapy, which revealed favorable long-term outcomes.

In conclusion, occult ET should be kept in mind when dealing with CVST in patients with thrombocytosis, and the presence of *JAK2*^{V617F} mutation was strongly suggested to be identified. In *JAK2*^{V617F}-positive ET patients with CVST, contemporary antithrombotic and cytoreductive therapies might be a satisfactory treatment option for preventing rethrombosis.

Declaration of patient consent

The authors certify that they have obtained all appropriate patient consent forms. The patients' guardians have given their consent for reporting their images and other clinical information in the journal. The patients' guardians understand that their names and initials will not be published and due efforts will be made to conceal their identity.

Financial support and sponsorship

This work was supported by a grant from the Beijing Municipal Administration of Hospitals' Youth Program (No. QML20160801).

Conflicts of interest

There are no conflicts of interest.

REFERENCES

1. Arber DA, Orazi A, Hasserjian R, Thiele J, Borowitz MJ, Le Beau MM, *et al.* The 2016 revision to the World Health Organization classification of myeloid neoplasms and acute leukemia. *Blood* 2016;127:2391-405. doi: 10.1182/blood-2016-03-643544.
2. Saki N, Shirzad R, Rahim F, Saki Malehi A. Estimation of diagnosis and prognosis in ET by assessment of CALR and JAK2V617F mutations and laboratory findings: A meta-analysis. *Clin Transl Oncol* 2017;19:874-83. doi: 10.1007/s12094-017-1618-1.
3. Dahabreh IJ, Zoi K, Giannouli S, Zoi C, Loukopoulos D, Voulgarelis M. Is JAK2 V617F mutation more than a diagnostic index? A meta-analysis of clinical outcomes in essential thrombocythemia. *Leukemia research* 2009;33:67-73. doi: 10.1016/j.leukres.2008.06.006.
4. Lussana F, Caberlon S, Pagani C, Kamphuisen PW, Buller HR, Cattaneo M. Association of V617F Jak2 mutation with the risk of thrombosis among patients with essential thrombocythaemia or idiopathic myelofibrosis: a systematic review. *Thrombosis research* 2009;124:409-17. doi: 10.1016/j.thromres.2009.02.004.
5. Ferro JM, Boussier MG, Canhão P, Coutinho JM, Crassard I, Dentali F, *et al.* European stroke organization guideline for the diagnosis and treatment of cerebral venous thrombosis – Endorsed by the European Academy of Neurology. *Eur J Neurol* 2017;24:1203-13. doi: 10.1111/ene.13381.
6. Barbui T, Finazzi G, Carobbio A, Thiele J, Passamonti F, Rumi E, *et al.* Development and validation of an international prognostic score of thrombosis in World Health Organization-essential thrombocythemia (IPSET-thrombosis). *Blood* 2012;120:5128-33. doi: 10.1182/blood-2012-07-444067.
7. Tefferi A, Barbui T. Polycythemia vera and essential thrombocythemia: 2017 update on diagnosis, risk-stratification, and management. *Am J Hematol* 2017;92:94-108. doi: 10.1002/ajh.24607.