

Available online at www.sciencedirect.com

ScienceDirect

journal homepage: www.elsevier.com/locate/radcr

Case Report

Multiple large pancreaticoduodenal artery aneurysms due to celiac artery occlusion: Combination of the aorto-hepatic bypass and coil embolization with a dual approach through both the superior mesenteric artery and bypass [☆]

Kengo Ohta, MD^a, Masashi Shimohira, MD^{a,*}, Jumpei Shoji, MD^b, Shiro Yoshida, MD^c, Taku Takaishi, MD^d, Mamoru Morimoto, MD^e, Yoichi Matsuo, MD^e, Tatsuhito Ogawa, MD^f, Hisao Suda, MD^f, Yuta Shibamoto, MD^a

^a Department of Radiology, Nagoya City University Graduate School of Medical Sciences, Nagoya 467-8601, Japan

^b Department of Radiology, Japanese Red Cross Nagoya Daini Hospital, Nagoya 466-8650, Japan

^c Department of Radiology, Nishichita General Hospital, Tokai 477-8522, Japan

^d Department of Radiology, Konan Kosei Hospital, Konan 483-8704, Japan

^e Department of Gastroenterological Surgery, Nagoya City University Graduate School of Medical Science, Nagoya 467-8601, Japan

^f Department of Cardiovascular Surgery, Nagoya City University Graduate School of Medical Sciences, Nagoya 467-8601, Japan

ARTICLE INFO

Article history:

Received 8 October 2020

Revised 12 October 2020

Accepted 17 October 2020

Keywords:

Pancreaticoduodenal artery aneurysm

Celiac artery occlusion

Bypass

Embolization

ABSTRACT

Pancreaticoduodenal artery aneurysm can occur from occlusion or stenosis of the celiac artery due to arteriosclerosis or median arcuate ligament compression. The risk of rupture of the aneurysm is independent of the aneurysmal diameter. A 78-year-old woman presented with multiple large aneurysms of the anterior superior pancreaticoduodenal artery. To preserve arterial flow to the liver, bypass grafting from the supra-celiac aorta to the common hepatic artery was performed at first. Coil embolization was successfully performed 10 days later with a dual approach through both the superior mesenteric artery and bypass. It was considered that the combination of the aorto-hepatic bypass and coil embolization was effective for the pancreaticoduodenal artery aneurysms due to celiac artery occlusion.

© 2020 The Authors. Published by Elsevier Inc. on behalf of University of Washington.

This is an open access article under the CC BY-NC-ND license

(<http://creativecommons.org/licenses/by-nc-nd/4.0/>)

[☆] Competing Interests: The authors have declared that no competing interests exist.

* Correspondence author.

E-mail address: mshimohira@gmail.com (M. Shimohira).

<https://doi.org/10.1016/j.radcr.2020.10.031>

1930-0433/© 2020 The Authors. Published by Elsevier Inc. on behalf of University of Washington. This is an open access article under the CC BY-NC-ND license (<http://creativecommons.org/licenses/by-nc-nd/4.0/>)

Introduction

Pancreaticoduodenal artery aneurysms account for 2% of all visceral artery aneurysms [1] and often develop following pancreatitis, trauma including surgery, and occlusion or stenosis of the celiac artery due to arteriosclerosis or the median arcuate ligament compression [2]. Unlike other visceral artery aneurysms, the risk of rupture is independent of the aneurysmal diameter [3]. Treatment for pancreaticoduodenal artery aneurysms is therefore considered appropriate, even in asymptomatic patients. Recently, endovascular management has been considered the first-line treatment because it is highly successful [4]. When embolization of an aneurysm of the pancreaticoduodenal arcade is intended, hepatic artery flow must be preserved [4].

We herein report a patient with multiple large pancreaticoduodenal artery aneurysms due to the celiac artery occlusion, who was successfully treated with combination of the aorto-hepatic bypass and coil embolization with a dual approach through both the superior mesenteric artery and the bypass.

Case report

A 78-year-old woman underwent computed tomography from the abdomen to the legs for screening of peripheral arterial occlusive disease, and multiple large aneurysms of the anterior superior pancreaticoduodenal artery (ASPDA) were found incidentally (Fig. 1A). Coil embolization of the aneurysms was considered, but the celiac artery was occluded (Fig. 1B) and the posterior superior pancreaticoduodenal artery was very thin (Fig. 1C). Therefore, to preserve the arterial flow to the liver, bypass grafting from the supra-celiac aorta to the common hepatic artery was performed using the saphenous vein graft (Fig. 2). Ten days after the bypass grafting, coil embolization was performed in the following manner. A 4.5-Fr guiding sheath (Parent; Medikit, Tokyo, Japan) was introduced from the right femoral artery and placed at the superior mesenteric artery (SMA), and then a 4-Fr. catheter (Cerulean; Medikit)

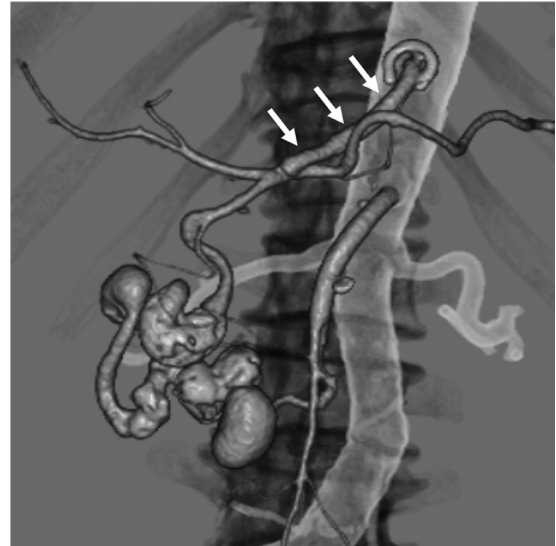


Fig. 2 – 3D-CTA revealed the bypass from the supra-coeliac aorta to the common hepatic artery (arrows).

was introduced. A 4-Fr sheath was introduced from the left femoral artery and a 4-Fr catheter (Shepherd Hook; Medikit) was advanced to the bypass. A 2.85-Fr microcatheter (Carry Leon High-flow, UTM, Toyohashi, Japan) was inserted through the 4-Fr catheter of SMA, and a small microcatheter (Carry Leon Selective, UTM) was advanced to the aneurysms. Meanwhile, another 2.85-Fr microcatheter (Carry Leon High-flow, UTM) was introduced through the 4-Fr catheter of the bypass, and a small microcatheter (Carry Leon Selective, UTM) was advanced to the aneurysms. To prevent migration of coils, embolization was started through both sides. To prevent retrograde flow to the aneurysms, we attempted to embolize the whole aneurysms. After the embolization, disappearance of the aneurysms was confirmed by angiography both from the SMA and bypass (Fig. 3A-E). The patient did well without any complication, and was discharged from hospital 5 days after the embolization.

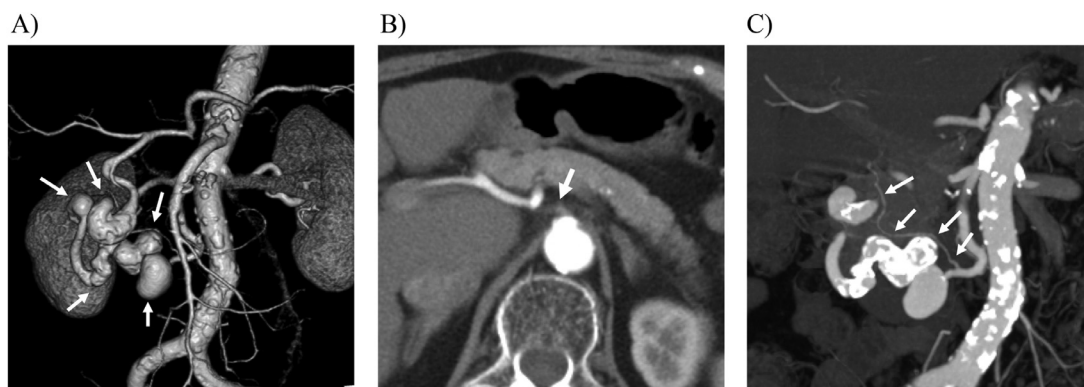


Fig. 1 – (A) 3D-CTA revealed multiple large aneurysms of the anterior superior pancreaticoduodenal artery (arrows). (B) An axial image showed occlusion of the celiac artery (arrow). (C) A coronal image showed the posterior superior pancreaticoduodenal artery was very thin (arrows).

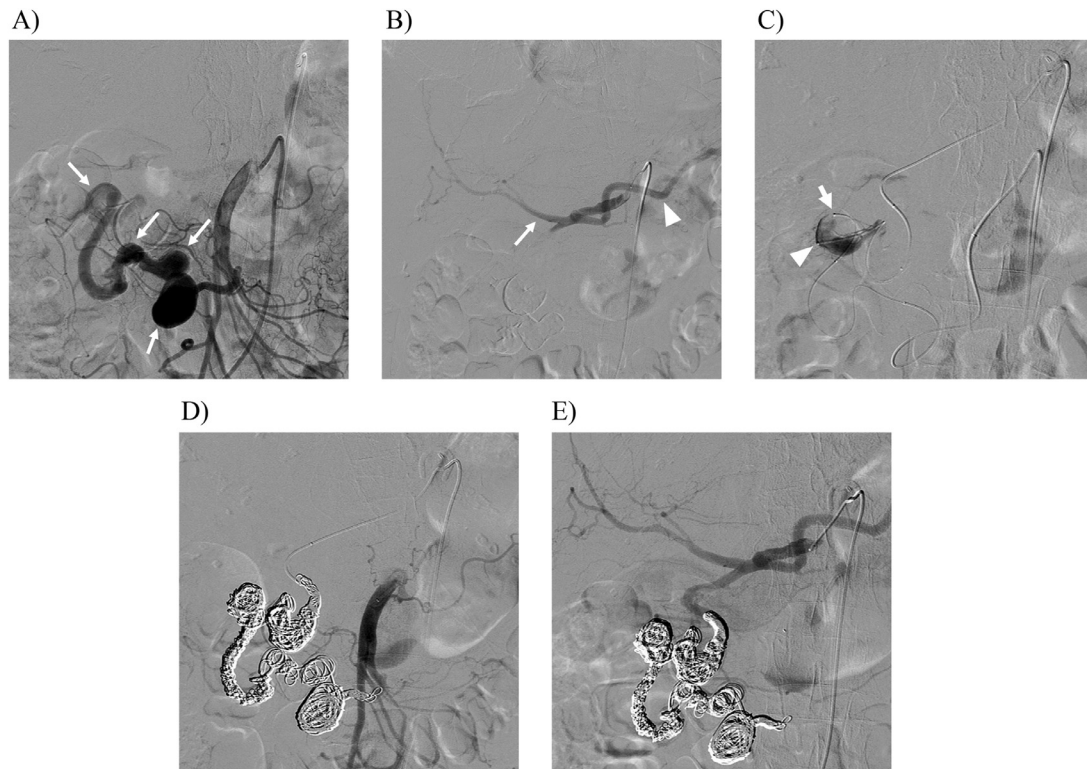


Fig. 3 – (A) Angiography from the superior mesenteric artery (SMA) showed multiple large aneurysms of the anterior superior pancreaticoduodenal artery (arrows). (B) Angiography from the bypass showed the proper hepatic artery (arrow) and the splenic artery (arrow head). (C) A microcatheter was introduced to the aneurysms from SMA side (arrow), and simultaneously another microcatheter was advanced to the aneurysms from bypass side (arrow head). Thereafter, coil embolization was performed from both sides. (D) Angiography from the SMA showed disappearance of multiple large aneurysms. (E) Angiography from the bypass also showed disappearance of multiple large aneurysms with preservation of blood flow for the hepatic and splenic arteries.

Discussion

Preservation of the hepatic arterial flow is an important issue in coil embolization for aneurysms of the pancreaticoduodenal arcade. However, revascularization of the celiac artery is not required usually, because arterial flow to the liver is maintained through a patent gastroduodenal artery (GDA) [4]. When it is necessary to embolize GDA in the presence of the celiac artery occlusion, revascularization of the celiac artery including aorto-hepatic artery bypass or celiac axis stenting should be considered [4].

In the present case, although the celiac artery was occluded, multiple aneurysms were only found in the ASPDA. However, the posterior superior pancreaticoduodenal artery was very thin, and we were concerned that it might not be enough to preserve hepatic arterial flow after embolization of aneurysms of the ASPDA, and thus we thought revascularization of the celiac artery was necessary. Although the celiac axis stenting was reported for celiac stenosis and pancreaticoduodenal artery aneurysms [5,6], the celiac artery of this case was occluded and it might have been technically difficult. So, we decided to perform the aorto-hepatic artery bypass.

Combination of the bypass surgery and embolization was reported with good results [7,8]. Multiple aneurysms of the ASPDA of the present case were located in the long and tortuous segment and it might be difficult to advance the microcatheter only from the SMA to treat the whole aneurysms. Thus, we approached from not only the SMA but also the bypass, and coil embolization was successfully accomplished. We believe this dual approach should be useful to treat such aneurysms located in such a long and tortuous segment. In addition, in this case, the bypass was connected to the common hepatic artery close to the orifice of the GDA, and thus it was so easy to advance the catheter to the GDA. Therefore, the position of connection of the bypass is important in this strategy.

The period between bypass and embolization is also an important issue. There may be a risk of thrombosis in the bypass, when an original collateral flow from the GDA is dominant. The period was reported as 1 day to 1 month in literature [7,8], and in this case, the period was 10 days. So, we think the embolization following the bypass should be performed at an early stage, at least within one month.

In conclusion, the combination of the aorto-hepatic bypass and coil embolization was effective for pancreaticoduodenal artery aneurysms due to celiac artery occlusion. The dual approach through both the SMA and bypass may be useful,

especially for multiple large aneurysms in the long and tortuous segment.

REFERENCES

- [1] Paty PS, Cordero JA Jr, Darling RC 3rd, Chang BB, Shah DM, Leather RP. Aneurysms of the pancreaticoduodenal artery. *J Vasc Surg* 1996;23(4):710–13.
- [2] Miyayama S, Terada T, Tamaki M. Ruptured pancreaticoduodenal artery aneurysm associated with median arcuate ligament compression and aortic dissection successfully treated with embolotherapy. *Ann Vasc Dis* 2015;8(1):40–2.
- [3] Suzuki K, Tachi Y, Ito S, Maruyama K, Mori Y, Komada T, et al. Endovascular management of ruptured pancreaticoduodenal artery aneurysms associated with celiac axis stenosis. *Cardiovasc Intervent Radiol* 2008;31(6):1082–7.
- [4] Corey MR, Ergul EA, Cambria RP, Patel VI, Lancaster RT, Kwolek CJ, et al. The presentation and management of aneurysms of the pancreaticoduodenal arcade. *J Vasc Surg* 2016;64(6):1734–40.
- [5] Takeuchi Y, Morikage N, Samura M, Harada T, Yamashita O, Suehiro K, et al. Treatment options for celiac stenosis and pancreaticoduodenal artery aneurysms. *Ann Vasc Surg* 2017;41:281.e21–281.e23.
- [6] Ikeda O, Nakasone Y, Yokoyama K, Inoue S, Tamura Y, Yamashita Y. Simultaneous coil embolization and angioplasty using a self-expanding nitinol stent to treat pancreaticoduodenal artery aneurysms associated with celiac artery stenosis. *Acta Radiol* 2013;54(8):949–53.
- [7] Aryal B, Komokata T, Ueno T, Yamamoto B, Senokuchi T, Yasuda H, et al. A 2-stage surgical and endovascular treatment of rare multiple aneurysms of pancreatic arteries. *Ann Vasc Surg* 2017;40:295.e9–295.e13.
- [8] Teng W, Sarfati MR, Mueller MT, Kraiss LW. A ruptured pancreaticoduodenal artery aneurysm repaired by combined endovascular and open techniques. *Ann Vasc Surg* 2006;20(6):792–5.