



Acetabular Morphology in Patients with Developmental Dysplasia of the Hip with High Dislocation

Kenji Tateda, MD, PhD, Satoshi Nagoya, MD, PhD, Daisuke Suzuki, PhD,
Ima Kosukegawa, MD, PhD, Toshihiko Yamashita, MD, PhD

Department of Orthopedic Surgery, Sapporo Medical University School of Medicine, Sapporo, Japan

Purpose: The current study aimed to investigate the morphology of the true acetabulum in developmental dysplasia of the hip (DDH) with high dislocation. A secondary was to evaluate the acetabular cup placement in patients with high dislocation who were treated with total hip arthroplasty (THA).

Materials and Methods: Using a retrospective design, 23 hips with DDH with high dislocation in patients who were treated with THA were included in this study. We measured the depth, width and thickness of the anterior and posterior walls of the original acetabulum using preoperative computed tomography images and investigated the cup size applied in these cases.

Results: The mean depth and width of the acetabulum was 18.4 and 16.2 mm proximal end, 18.4 and 24.3 mm in the middle, and 15.8 and 27.6 mm at the distal part. Mean thickness of the anterior and posterior walls was 10.9 and 23.9 mm at the proximal end, 10.3 and 22.2 mm in the middle, and 10.9 and 22.7 mm at the distal part. A 42-mm cup was using in one hip, a 46-mm cup in three hips, a 48-mm cup in 13 hips, and a 50-mm cup in six hips.

Conclusion: In patients with Crowe IV DDH, the morphology of the acetabulum comprises a triangle that broadens from proximal to distal points, with a relatively thick posterior wall. Reaming the acetabulum posteriorly and inferiorly may enable the placement of a relatively larger cup to achieve stable fixation.

Key Words: Acetabulum, Hip dislocation, Congenital, Arthroplasty, Replacement

Submitted: September 7, 2020 **1st revision:** October 16, 2020

Final acceptance: October 30, 2020

Address reprint request to

Kenji Tateda, MD, PhD

(<https://orcid.org/0000-0001-7611-5232>)

Department of Orthopedic Surgery, Sapporo Medical University School of Medicine, S-1 W-16, Chuo-ku, Sapporo, Hokkaido 060-8543, Japan

TEL: +81-11-6111-2111 **FAX:** +81-11-641-6026

E-mail: tateda@sapmed.ac.jp

This is an Open Access article distributed under the terms of the Creative Commons Attribution Non-Commercial License (<http://creativecommons.org/licenses/by-nc/4.0>) which permits unrestricted non-commercial use, distribution, and reproduction in any medium, provided the original work is properly cited.

INTRODUCTION

Total hip arthroplasty (THA) is challenging in patients with developmental dysplasia of the hip (DDH) with high dislocation. In Crowe IV DDH patients, the true acetabulum is small and the bone stock is often poor; therefore, the use of an extra-small acetabular component has been recommended¹⁻³. The use of extra-small components is complicated by findings that small acetabular components are disadvantageous in terms of the stability and long-term survival of the hip joint^{4,5}.

Some authors have described techniques for placing standard-sized cups in hips with total dislocated dysplasia.

Hartofilakidis et al.²⁾ recommended reaming of the acetabulum in a superior and posterior direction. Xu et al.⁶⁾ reported that maximum host bone coverage can be achieved by posterosuperior placement of the cup at the true acetabulum. In contrast, Paavilainen et al.³⁾ demonstrated the placement of an acetabular component below the anatomical acetabulum as the bone stock between the pubic and ischial rami was more substantial than in the hypoplastic iliac bone. It is controversial how a larger cup is safely placed in small acetabulum with dislocated hip. Therefore, detailed knowledge of the morphology of the true acetabulum in patients with Crowe IV DDH will be beneficial for the placement of a larger cup.

The commonly used procedure for THA by the authors includes placing a standard-sized acetabular component posteriorly and inferiorly at the true acetabulum in Crowe IV dysplasia patients according to the technique reported by Paavilainen et al.³⁾. The current study sought to determine the morphology of the true acetabulum in patients with high congenital dislocation of the hip to provide greater detail when following the typical procedure, as information regarding the depth and width of the acetabulum and the thickness of the anterior and posterior walls would aid in reaming for the placement of a larger cup. Additionally, the current study evaluated acetabular cup placement in Crowe IV dysplasia patients with dislocation who were treated with THA combined with subtrochanteric femoral shortening osteotomy⁷⁾.

MATERIALS AND METHODS

This retrospective study was approved by the Institutional Review Board of Sapporo Medical University (No. 292-41). The current study included 23 hips of 18 patients with Crowe IV developmental dysplasia who were treated with THA combined with femoral shortening osteotomy at our institution from 1998 to 2015. Seventeen patients were female, and mean age at surgery was 62.7 years (48-76 years). Two hips of two patients had previously been repaired by femoral valgus osteotomy. No other cases had undergone any surgical procedures related to the hip.

Preoperative computed tomography images of all patients were obtained and reconstructed 3-dimensional (3D) images were aligned with reference to the anatomical pelvic coordinate system by 3D computer-aided design software (3matic; Materialise, Leuven, Belgium). The anatomical pelvic coordinate system was constituted in the anatomical pelvic plane (APP) that included the left and right anterior

superior iliac spines^{8,9)}. Measurements were taken of the anteroposterior diameter (width), depth, thickness of the anterior and posterior walls and the anteversion of the original acetabulum using preoperative computed tomography images in the axial plane perpendicular to APP. In these cases, the edge of the anterior and posterior walls of the acetabulum displayed a dull shape that differed from the normal acetabulum¹⁰⁾, and the thickness of the anterior and posterior walls was nearly invariable in axial image slices. The width of the original acetabulum was defined as the distance from the posterolateral edge of the anterior wall to the anterolateral edge of the posterior wall and the depth of the original acetabulum as the distance from a line between the lateral edges of the anterior and posterior walls to the bottom of the acetabulum (Fig. 1). The superior and inferior ends of the original acetabulum were identified and the distance between them was measured to define the longitudinal diameter. The longitudinal diameter of the original acetabulum was divided into proximal, middle, and distal thirds. The width, depth and thickness of the acetabular walls were measured using three axial slices for each divided part (nine slices in total) and parameters for each part were compared (Fig. 2). Acetabular anteversion was measured at the level of the distal third of the acetabulum where the cup center was planned to be located.

Cup sizes and the number of screws for cup fixation used

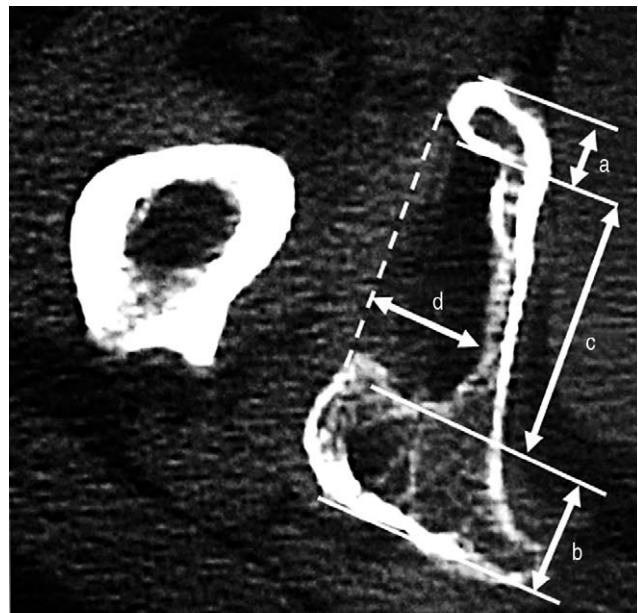


Fig. 1. Thickness of the anterior wall (a) and posterior wall (b), width (c), and depth (d) of the original acetabulum were measured using preoperative computed tomography images in axial view.

in these cases were investigated. The amounts of anterior and posterior wall reaming were calculated. Furthermore, the cup inclination and the cup center-edge angle (cup-CE angle)^{11,12} were measured using a postoperative plain X-ray and the vertical and horizontal offsets of the center of the cups were compared to the center of femoral heads of contralateral normal hips (n=8). Cup anteversion was measured using postoperative computed tomography images in axial plane (n=11).

1. Operative Procedure

For the patients with Crowe IV DDH, THA combined with femoral shortening osteotomy was performed to prevent excessive lengthening of the leg. A posterolateral approach was used with the patient in the lateral decubitus position. The femoral head was resected through the femoral neck 1 cm proximal to the lesser trochanter. Prior to exposing the acetabulum, a transverse osteotomy of the femoral shaft was performed 2 cm to 3 cm distal to the lesser trochanter so that the proximal femur was easily

retracted anteriorly. The redundant joint capsule was totally excised to provide a wide view of the acetabulum. The original acetabulum was exposed to visually recognize the thickness of the anterior and posterior wall. Reaming was started with a small size reamer to locate the center at the level of the distal third of the acetabulum. Reaming was performed from the thick posterior wall, gradually expanded anteriorly and finished when reaming reached the thin anterior wall and the superior end of the acetabulum. In 14 cases perforation of the medial wall about 1.5 cm occurred to deepen the reaming, though it did not affect the stability of the cups. With 1 mm under reaming, a cementless cup was placed so that the cup anteversion was 30 degrees. The cup inclination was aimed at 40 degrees, however, high inclination was allowed by up to approximately 50 degrees to bring the cup into enough contact with the superior acetabulum. In cases with insufficient cup contact with the superior acetabulum, the resected femoral head was grafted onto the external wall of the ilium.

2. Statistical Analysis

Data are expressed as means and standard deviations. Statistical analyses were performed using a one-way analysis of variance (ANOVA) with Tukey’s post hoc tests or a two-way ANOVA with Bonferroni’s post hoc tests. Results were considered statistically significant at *P*-values of <0.05.

RESULTS

The morphological parameters of the original acetabulum are shown in Table 1. Mean depth of the original acetabulum was 18.4±4.9 mm at the proximal part, 18.4±4.2 mm at the middle section, and 15.8±4.6 mm at the distal end. The depth at distal part was significantly shallower than that at proximal and middle part (Fig. 3). Mean width was 16.2±4.9 mm at the proximal part, 24.3±4.6 mm at the middle section, 27.6±5.6 mm at the distal part and was significantly wider at the distal part (Fig. 4). Mean thickness of the anterior wall was 10.9±4.0 mm at the proximal

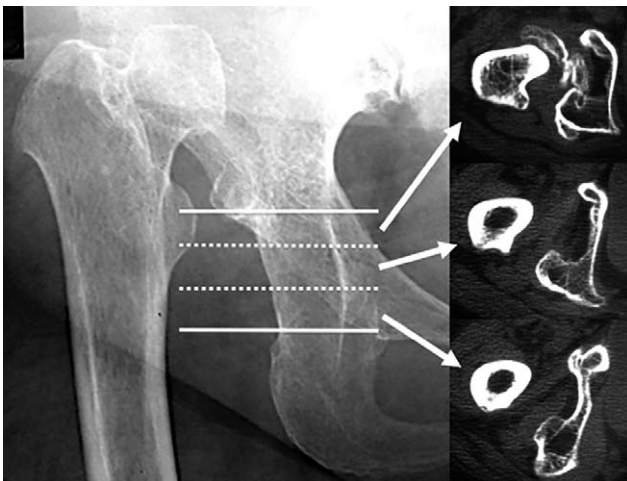


Fig. 2. Original acetabulum was divided into proximal, middle, and distal thirds. Thickness of the anterior and posterior walls, width, and depth of the acetabulum were compared among each part.

Table 1. Morphological Parameters of the Original Acetabulum

Variable	Proximal	Middle	Distal
Depth (mm)	18.4±4.9	18.4±4.2	15.8±4.6
Width (mm)	16.2±4.9	24.3±4.6	27.6±5.6
Thickness of anterior wall (mm)	10.9±4.0	10.3±3.5	10.9±2.8
Thickness of posterior wall (mm)	23.9±6.0	22.2±6.2	22.7±6.8

Values are presented as mean±standard deviation.

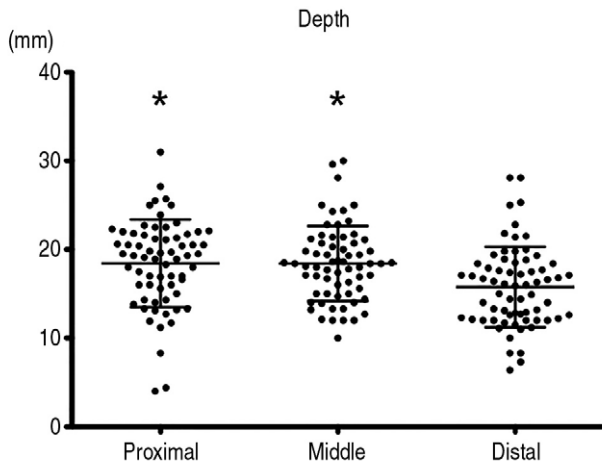


Fig. 3. Mean depth of original acetabulum was 18.4 ± 4.9 mm at the proximal, 18.4 ± 4.2 mm at the middle, and 15.8 ± 4.6 mm at the distal part, and the depth at distal part was significantly shallower than that at proximal and middle part. Values are presented as mean \pm standard deviation.

* $P < 0.05$, compared with distal part.

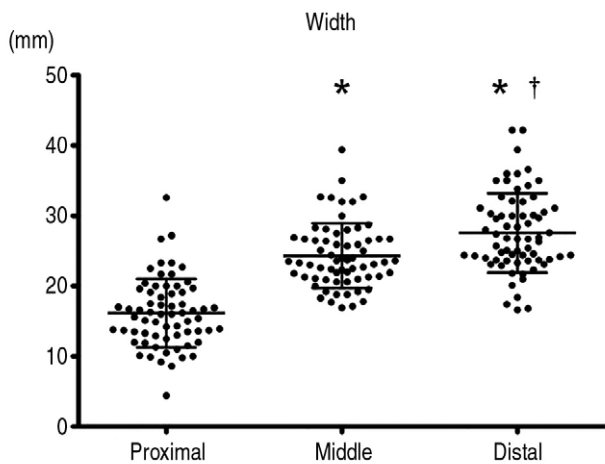


Fig. 4. Mean width was 16.2 ± 4.9 mm at the proximal, 24.3 ± 4.6 mm at the middle, and 27.6 ± 5.6 mm at the distal part, and was significantly widest at the distal part. Values are presented as mean \pm standard deviation.

* $P < 0.05$, compared with proximal part. † $P < 0.05$, compared with middle part.

part, 10.3 ± 3.5 mm at the middle section, and 10.9 ± 2.8 mm at the distal part (Fig. 5). Furthermore, mean thickness of the posterior wall was 23.9 ± 6.0 mm at the proximal part, 22.2 ± 6.2 mm at the middle section, and 22.7 ± 6.8 mm at the distal part. The posterior wall was significantly thicker than the anterior wall in all sections. Mean acetabular anteversion at the level of the distal third of the acetabulum was 30.2 ± 6.3 degrees. In summary, the acetabular morphology of dislocated hip dysplasia comprised a trian-

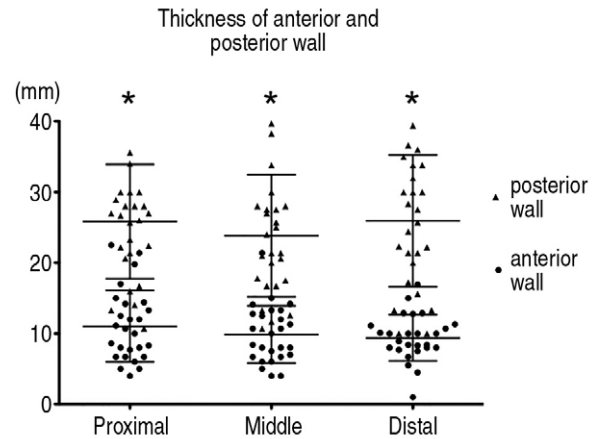


Fig. 5. Thickness of anterior wall was approximately 10 mm, and that of posterior wall was approximately 23 mm. The posterior wall was significantly thicker than the anterior wall in all parts. Values are presented as mean \pm standard deviation. * $P < 0.05$ for anterior wall vs. posterior wall.

gular shape that is broadened from the proximal to distal ends. The anterior wall was thin, and the posterior wall was relatively thick (Fig. 6).

A 42-mm cup was used in one dislocated hip, a 46-mm cup in three hips, a 48-mm cup in 13 hips, and a 50-mm cup in six hips (Fig. 7). A spiked cup was used in five hips and a cup with screw holes was used in another 18 hips with two to five screws (mean number was 3.5) used for cup fixation. The amounts of anterior and posterior wall reaming were calculated, indicating that the mean amount of reaming was 5.7 ± 3.1 mm for the anterior wall and 14.8 ± 4.1 mm for the posterior wall. The vertical and horizontal offsets of the cup center, cup inclination, and cup-CE angle were measured using a postoperative plain X-ray. Mean vertical and horizontal offsets of the center of the cups were 11.9 ± 5.4 mm inferior and 8.9 ± 5.8 mm medial to contralateral normal hip center, respectively. The mean cup inclination was 50.0 ± 6.6 degrees and the mean cup-CE angle was 21.0 ± 9.7 degrees. The femoral head graft onto the external wall of the ilium was applied in six hips, and the mean cup-CE angle in these cases was 12.6 ± 8.0 degrees. Bone grafts were not needed in another 17 hips, and the mean cup-CE angle of these hips was 24.0 ± 8.5 degrees. We measured cup anteversion using postoperative computed tomography images in the axial plane ($n=11$). Mean cup anteversion was 30.3 ± 8.3 degrees and was approximately the same as the original acetabular anteversion.

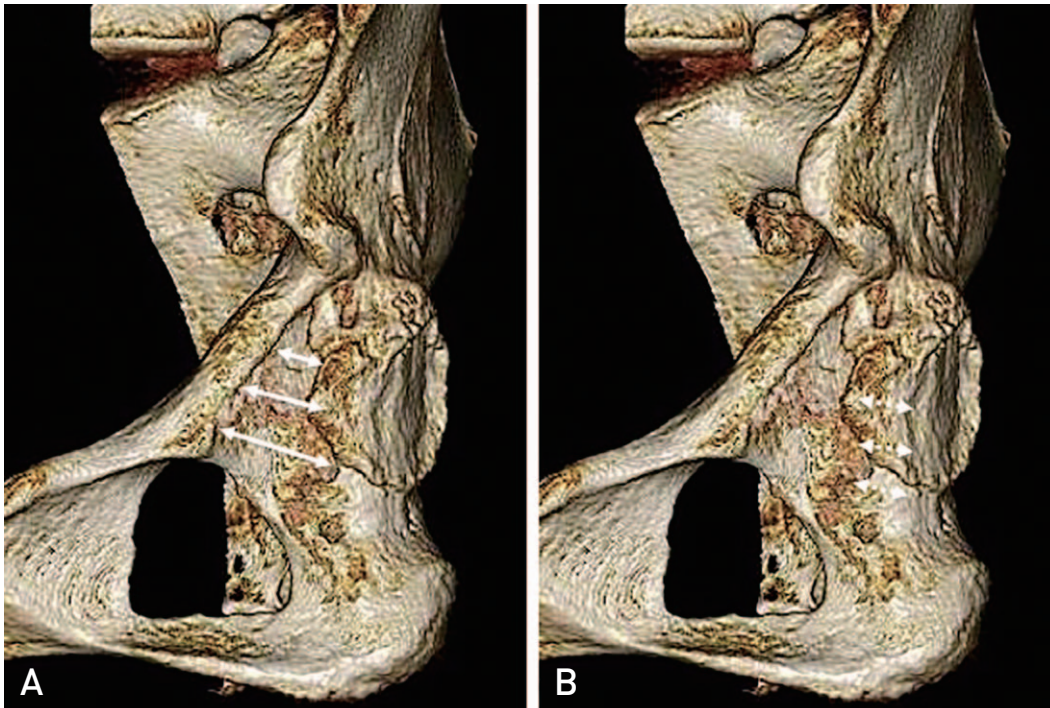


Fig. 6. Acetabular morphology of patients with Crowe IV hip dysplasia comprised a triangle with a proximal top (lined arrows) (A), and the posterior wall was relatively thick and the thickness was approximately constant from proximal part to distal part (dotted arrows) (B).

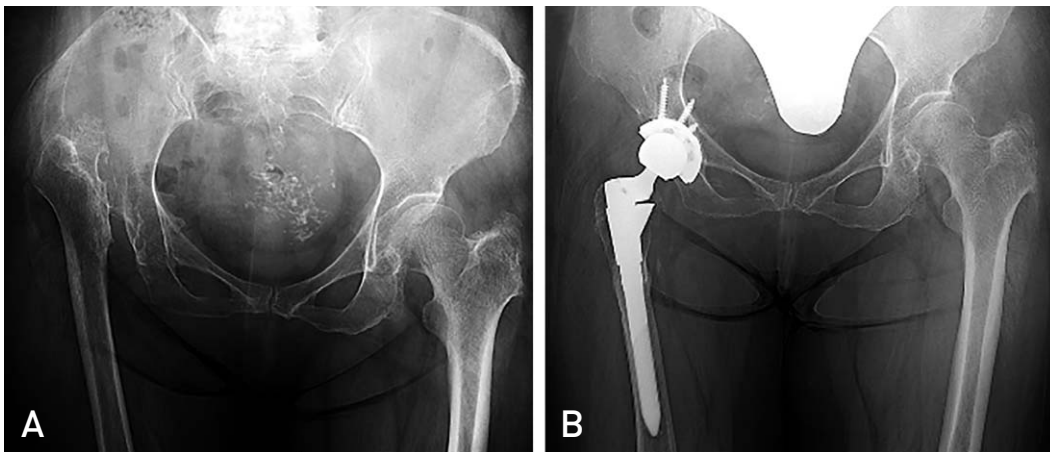


Fig. 7. Preoperative (A) and postoperative (B) radiographs of a 67-year-old female patient with Crowe IV developmental dysplasia of the hip. A 50-mm cup was placed below the anatomical acetabulum.

DISCUSSION

Primary THA remains challenging in patients with osteoarthritis secondary to DDH, especially in the case of Crowe IV DDH, due to the bone deficiency in the acetabulum, superolateral subluxation and dislocation, and leg length discrepancies^{13,14}. Crowe et al.¹⁵ noted that the acetabulum in patients with hip dysplasia with high dislocation

formed a small triangle and that the anterior and posterior margins limited the size of the acetabular component. Therefore, an extra-small acetabular component was required for adequate superior bone coverage. However, small acetabular components limit the thickness of the polyethylene liner and the femoral head size. Thin polyethylene liners have the disadvantage of liner wear, which causes osteolysis⁵, and a small femoral head has a risk of dislocation. Preserving

the anterior and posterior walls of the acetabulum is very important for cementless cup fixation¹⁶; however, placement of a larger size cup in a small acetabulum has a risk of acetabular wall destruction. Therefore, gaining detailed information on the morphology of the true acetabulum in patients with high dislocated hip is beneficial for the safe placement of a larger cup.

Some acetabular reconstruction techniques have been recommended for the placement of a standard-sized cup in high dislocated hips. Hartofilakidis et al.¹⁷ and Hartofilakidis and Karachalios¹⁸ proposed reaming the acetabulum in a superior and posterior direction, where bone stock is often adequate. Xu et al.⁶ reported that good host bone coverage can be achieved by posterosuperior placement of the cup at the true acetabulum. In both studies, researchers used 40 to 44-mm and 42 to 46-mm cups, respectively, in their techniques. Yang et al.¹⁹ reported a 3D implantation simulation study for hip dysplasia where the inferior edge of the virtual cup was placed at the level of the distal part of the cotyloid notch (the position of the transverse acetabular ligament), and the mean cup size was 38.4 ± 3.0 mm in Crowe IV hip. Paavilainen et al.³ reported a technique of acetab-

ular reconstruction in cases of total dislocation wherein the acetabular component was seated below the anatomical acetabulum as the proximal part of the ischial bone and the bony prominence close to the junction of pubic, and iliac bones offers good posterosuperior and anterosuperior support. The current study indicated that the acetabular morphology of Crowe IV DDH is triangular as the width of the acetabulum was widened from proximal to distal ends. Thickness of the anterior wall and posterior wall were approximately 10 and 23 mm, respectively, which was nearly constant throughout the proximal to distal parts. Therefore, a larger acetabular component was able to be fixed by placing the cup center posteriorly and inferiorly at the true acetabulum, where the width is broader and the posterior wall is thick. The cup center was planed to be located at the level of the distal third of the original acetabulum and the superior end of the cup was located at the top of the triangle of the acetabulum. The anterior wall was thin and the posterior wall was relatively thick, therefore the distance obtained by adding the anteroposterior diameter and the thickness of the posterior wall at the level of the distal third of the original acetabulum would be the diameter of the cup.

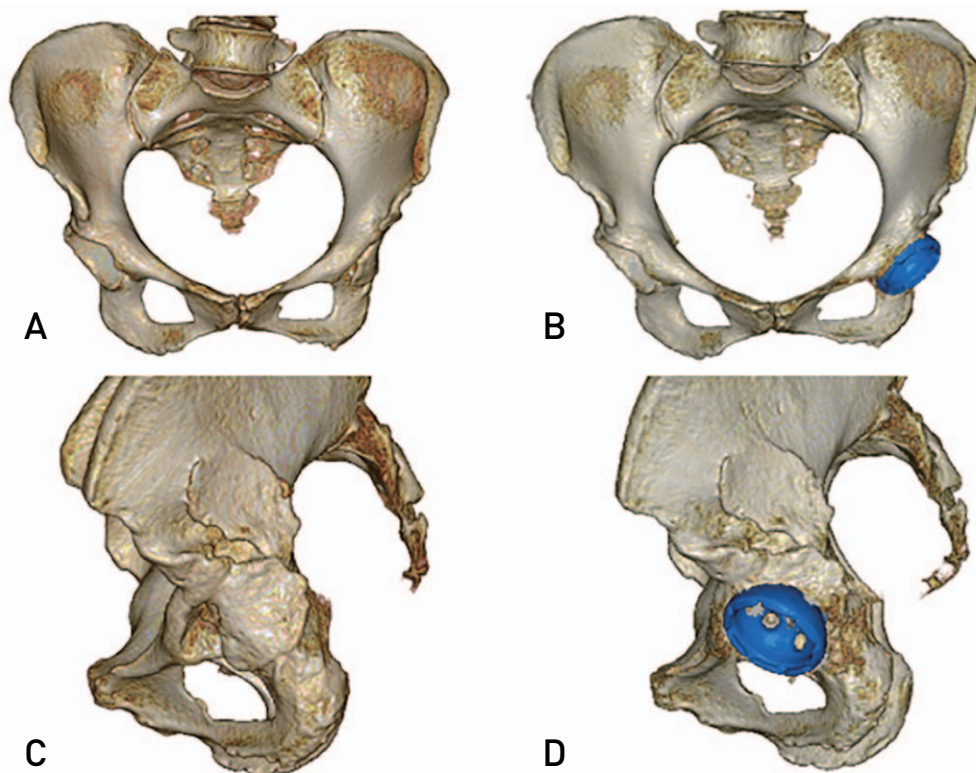


Fig. 8. Preoperative frontal view (A), lateral view (C), postoperative frontal view (B), and lateral view (D) of 3-dimensional computed tomography images of a 70-year-old female patient. A 48-mm cup was implanted 6.3 mm inferior to the level of contralateral hip center.

In patients with Crowe I-III acetabular dysplasia, the femoral head is subluxed from the acetabulum, and articular pressure is concentrated at the small area of the loaded surface. This is particularly true at the acetabular margin, which promotes superior bone defect of the acetabulum^{20,21}. In contrast, for Crowe IV acetabular dysplasia patients the femoral head is completely dislocated from the acetabulum and mechanical stress from the femoral head does not occur in the acetabulum. Therefore, superior bone defect as seen in Crowe I-III acetabular dysplasia is not observed in Crowe IV acetabular dysplasia. In the cases included in the current study, femoral head grafting was not needed in 17 hips, and metal augmentation for cup stability was not necessary in any of the cases. In 14 cases, intentional medial wall perforation occurred at approximately 1.5 cm to medialize the cup and to allow for enough contact with host bone. In the earliest case in this series, a 42-mm cup was used so that the cup center was located at approximately at the center of the original acetabular but not at the level of the distal third of the acetabulum (vertical offset of the cup center was only 4 mm inferior). In 22 cases, we successfully replaced three dislocated hips with a 46-mm cup, 13 hips with a 48-mm cup, and six hips with a 50-mm cup by reaming the true acetabulum posteriorly and inferiorly and placing cups approximately 12 mm inferior to the normal hip center (Fig. 8) with a mean cup-CE angle of 21.0 ± 9.7 degrees. Cup loosening was not observed in any of the cases at 3 to 20 years of follow-up.

There were limitations to the current study. One limitation was the small sample size, which may have been a result of the uncommon occurrence of Crowe IV dysplasia. An additional limitation was the use of two-dimensional computed tomography axial images to evaluate morphological parameters. The 3D evaluation of the morphology of the original acetabulum may prove more helpful for the planning of precise cup placement.

CONCLUSION

The morphology of the original acetabulum in hip dysplasia patients with high dislocation was comprised of a triangle that was broadened from proximal to distal sections, with a relatively thick posterior wall. Reaming of the acetabulum posteriorly and inferiorly enabled the placement of a relatively larger cup to achieve stable fixation.

CONFLICT OF INTEREST

The authors declare that there is no potential conflict of interest relevant to this article.

REFERENCES

- Dunn HK, Hess WE. *Total hip reconstruction in chronically dislocated hips*. *J Bone Joint Surg Am*. 1976;58:838-45.
- Hartofilakidis G, Stamos K, Ioannidis TT. *Low friction arthroplasty for old untreated congenital dislocation of the hip*. *J Bone Joint Surg Br*. 1988;70:182-6.
- Paavilainen T, Hoikka V, Solonen KA. *Cementless total replacement for severely dysplastic or dislocated hips*. *J Bone Joint Surg Br*. 1990;72:205-11.
- Jameson SS, Lees D, James P, et al. *Lower rates of dislocation with increased femoral head size after primary total hip replacement: a five-year analysis of NHS patients in England*. *J Bone Joint Surg Br*. 2011;93:876-80.
- Livermore J, Ilstrup D, Morrey B. *Effect of femoral head size on wear of the polyethylene acetabular component*. *J Bone Joint Surg Am*. 1990;72:518-28.
- Xu J, Xu C, Mao Y, Zhang J, Li H, Zhu Z. *Posterosuperior placement of a standard-sized cup at the true acetabulum in acetabular reconstruction of developmental dysplasia of the hip with high dislocation*. *J Arthroplasty*. 2016;31:1233-9.
- Nagoya S, Kaya M, Sasaki M, Tateda K, Kosukegawa I, Yamashita T. *Cementless total hip replacement with subtrochanteric femoral shortening for severe developmental dysplasia of the hip*. *J Bone Joint Surg Br*. 2009;91:1142-7.
- Suzuki D, Nagoya S, Takashima H, Tateda K, Yamashita T. *Three-dimensional orientation of the acetabulum*. *Clin Anat*. 2017;30:753-60.
- Augustine AS, Ewen AM, Wallace DT, Picard F. *Variations in pelvic dimensions: an anatomical and computed tomography study*. *Clin Anat*. 2018;31:981-7.
- Dunn PM. *The anatomy and pathology of congenital dislocation of the hip*. *Clin Orthop Relat Res*. 1976;(119):23-7.
- Sugano N, Nishii T, Nakata K, Masuhara K, Takaoka K. *Polyethylene sockets and alumina ceramic heads in cemented total hip arthroplasty. A ten-year study*. *J Bone Joint Surg Br*. 1995;77:548-56.
- Takao M, Nakamura N, Ohzono K, Sakai T, Nishii T, Sugano N. *The results of a press-fit-only technique for acetabular fixation in hip dysplasia*. *J Arthroplasty*. 2011;26:562-8.
- Rogers BA, Garbedian S, Kuchinad RA, Backstein D, Safir O, Gross AE. *Total hip arthroplasty for adult hip dysplasia*. *J Bone Joint Surg Am*. 2012;94:1809-21.
- Holzappel BM, Greimel F, Prodinger PM, et al. *Total hip replacement in developmental dysplasia using an oval-shaped cementless press-fit cup*. *Int Orthop*. 2012;36:1355-61.
- Crowe JF, Mani VJ, Ranawat CS. *Total hip replacement in congenital dislocation and dysplasia of the hip*. *J Bone Joint Surg Am*. 1979;61:15-23.
- Hayashi S, Hashimoto S, Takayama K, Matsumoto T, Nishida K, Kuroda R. *Multiple revision surgeries and acetabular bone defect size may predict daily activity after revision total hip arthroplasty*. *J Arthroplasty*. 2017;32:1606-11.

17. Hartofilakidis G, Stamos K, Karachalios T. *Treatment of high dislocation of the hip in adults with total hip arthroplasty. Operative technique and long-term clinical results. J Bone Joint Surg Am.* 1998;80:510-7.
18. Hartofilakidis G, Karachalios T. *Total hip arthroplasty for congenital hip disease. J Bone Joint Surg Am.* 2004;86:242-50.
19. Yang Y, Zuo J, Liu T, Xiao J, Liu S, Gao Z. *Morphological analysis of true acetabulum in hip dysplasia (Crowe Classes I-IV) Via 3-D implantation simulation. J Bone Joint Surg Am.* 2017;99:e92.
20. Pauwels F. *Biomechanics of the normal and diseased hip: theoretical foundation, technique and results of treatment: an atlas. Berlin: Springer-Verlag; 1976.*
21. Bombelli R. *Classification of osteoarthritis of the hip. In: Bombelli R, ed. Osteoarthritis of the hip: classification and pathogenesis the role of osteotomy as a consequent therapy. Berlin: Springer-Verlag; 1983. 89-108.*