CASE REPORT – OPEN ACCESS

International Journal of Surgery Case Reports 42 (2018) 227–232

Contents lists available at ScienceDirect

International Journal of Surgery Case Reports

journal homepage: www.casereports.com

Tension pneumoperitoneum after bystander cardiopulmonary resuscitation: A case report

Sherry Johnson*, Jessica McCracken, Fadi Baidoun

Henry Ford Wyandotte Hospital, 2333 Biddle Ave, Wyandotte, MI 48192, USA

ARTICLE INFO

Article history:
Received 30 September 2017
Received in revised form 5 December 2017
Accepted 6 December 2017
Available online 12 December 2017

Keywords:
Tension pneumoperitoneum
Gastric perforation
Veress needle
Complications of CPR

ABSTRACT

INTRODUCTION: Abdominal visceral injuries after cardiopulmonary resuscitation (CPR) are infrequent though can be significant complications of CPR requiring invasive interventions. We present a case of a gastric perforation as a result of bystander CPR. This resulted in tension pneumoperitoneum necessitating abdominal decompression prior to laparotomy and repair.

PRESENTATION OF CASE: 37-year-old female complained of abdominal pain and distension after return of spontaneous circulation from successful CPR following a drug overdose and cardiopulmonary arrest. Abdominal imaging showed significant amounts of free intraperitoneal air causing compression of the abdominal visceral organs. Patient underwent exploratory laparotomy. Prior to induction of general anesthesia with potential cardiovascular collapse from the tension pneumoperitoneum, the abdomen was decompressed with a spring-loaded insufflation (Veress) needle while the patient was awake. Upon exploration, there were two three-centimeter gastric perforations that were primarily repaired with omental patch. The patient had an uneventful recovery and discharged home on postoperative day four.

CONCLUSION: The Veress needle, usually used for insufflating the abdomen during laparoscopy, can also be an effective tool to decompress the abdomen when presented with tension pneumoperitoneum. Abdominal visceral injuries are rare following CPR but do occur and will likely require an invasive intervention. Surviving cardiac arrest as a young person and living without deficits outweighs the risk of a surgical correction for a visceral injury. While resuscitation measures are critical for survival, medical personnel need to be aware of potential complications from resuscitative efforts and potential management strategies.

1. Background

We present a case of a gastric perforation as a result of bystander cardiopulmonary resuscitation (CPR). Visceral injuries, specifically gastric as in this case, are infrequent though can be significant complications of CPR requiring invasive interventions [1]. While clearly documented in the literature, this has never been seen at our fairly busy community hospital.

2. Introduction

Gastric perforation during CPR is a relatively rare event though there have been multiple case reports describing pneumoperitoneum from gastric perforation after CPR [2]. CPR-related gastric perforations are reported to be caused by three main etiologies; bystander CPR (56% of the time), bag-mask ventilation (21%) and difficult airway management, i.e. intubation of the esophagus (21%) [2]. This can lead to massive accumulation of intraabdominal air under pressure or tension pneumoperitoneum and is potentially life threatening. It can lead to the development of acute abdominal compartment syndrome, compression of the inferior vena cava and other visceral veins resulting in reduced venous return and decreased cardiac output. Prompt intervention is required to prevent death.

3. Case description

37-year-old female found unresponsive and pulseless at home after taking oxycodone and alcohol. Her fiancé performed chest compressions and mouth-to-mouth resuscitation. Emergency medical services arrived on scene, continued CPR, gave naloxone and patient had successful return of vital signs and arrived to the emergency department (ED) awake, alert and oriented times three, where she was complaining of abdominal pain and shortness of breath. Past medical history: significant for seizure disorder.

* Corresponding author.
E-mail addresses: Sjohns30@hfhs.org (S. Johnson), Jmccrac3@hfhs.org (J. McCracken), Fbaidou1@hfhs.org (F. Baidoun).

https://doi.org/10.1016/j.ijscr.2017.12.014

Fig. 1. CT scan showing pneumopericardium, pneumomediastinum and extensive pneumoperitoneum.

Past surgical history: laparoscopic cholecystectomy, cesarean section. Past family history: patient denies. Prescribed medications: lacosamide. Social history: Never smoker, takes non-prescribed opiates, drinks alcohol weekly, applied for disability because flickering lights trigger her seizures. Vitals on arrival to ED: blood pressure 99/83, heart rate 138, respiratory rate 24. Physical exam showed diffuse abdominal tenderness and distension. No guarding. Chest radiograph showed pneumoperitoneum. Computed tomography (CT) chest/abdomen/pelvis showed pneumopericardium, pneumomediastinum and extensive pneumoperitoneum resulting in a mass effect upon the abdominal and pelvic organs (Figs. 1 and 2). Patient's blood pressure and heart rate was responsive to intravenous fluids (IVF). A contrast esophagram was ordered to evaluate for esophageal perforation which was highest on our

Fig. 2. CT scan showing extensive pneumoperitoneum causing compression of intraabdominal viscera.

differential at the time. Our thought was, that because she was able to maintain hemodynamic stability with IVF, we could spend the extra time doing the esophagram. The study was without active extravasation and esophageal perforation was much less on our differential of free intraperitoneal air etiology (Fig. 3). Patient was taken back to the operating room for exploratory laparotomy by the in house on-call acute care general surgeon who happened to be the chief of surgery at the time with ten years of operative experience. Due to the massive pneumoperitoneum compressing that patient's intraabdominal viscera and inferior vena cava, it was thought that induction of anesthesia might cause cardiovascular collapse due to decreased venous return. Before induction of anesthesia, local lidocaine was used to anesthetize the left upper quadrant and with the patient awake, a spring-loaded insufflation (Veress) needle was used to decompress the abdomen successfully in order to proceed with general anesthesia and exploratory surgery. Prior to induction after the decompression, we noticed an improvement in heart rate from 110 to high 90 s. The patient remained hemodynamically stable upon induction of general anesthesia. Upon exploration of the abdomen, patient was found to have two large (about three centimeter each) gastric perforations on the lesser curvature of the stomach near the gastroesophageal junction without other injuries (Fig. 4). These were debrided and primarily repaired with omental patch. Her operative time was 88 min and her estimated blood loss was 15 mL. Her post-operative course was uncomplicated and she was advanced slowly to regular diet on postoperative day four after an upper gastrointestinal contrast study was negative for extravasation of contrast and she was discharged home in good condition. The patient returned to clinic two weeks after discharge feeling well, eating normal and having regular bowel movements. She was grateful for her life being saved and was committed to getting help for her substance abuse.

4. Discussion

Most victims of cardiac arrest will die without immediate intervention with CPR. The American Heart Association encourages everyone, untrained bystanders and medical personnel, to begin CPR with chest compressions [3]. Bystander CPR is associated with improved survival [4]. Unfortunately, resuscitation attempts can cause harm to the patient. A review of autopsies showed that frequent findings include tracheal injuries and rib/sternal fractures [1,5]. Less common injuries happen to the pleura, pericardium, myocardium, head/neck, thorax and abdominal viscera [1,5]. Inadequately performed CPR is regarded as a main factor for resuscitation related visceral injuries [1]. In this case, bystander CPR may have resulted in the patient surviving but inappropriate technique led to a morbidity in this young patient. It has been described that gastric distension secondary to mouth-to-mouth or bag-mask ventilation happens when the upper airway is blocked (i.e. incorrect or absent chin lift during mouth-to-mouth ventilation) and air enters the stomach [6]. Also, incorrect placement of hands over the xiphoid process during CPR can increase the likelihood of visceral injuries [6]. The stomach gets distended with air and then outside mechanical pressure causes it to perforate.

Most cases with gastric perforation after CPR describe the perforation along the lesser curvature of the stomach where it is thought that the area has fewer mucosal folds, less elasticity and is fixed by the hepatogastric ligament [7]. In this case, in reviewing the upper esophagram retrospectively, there was no extravasation from the esophagus, but there was a questionable area of minimal extravasation around the lesser curvature of the stomach that was not identified on our initial reads. We hypothesize that the intraabdominal pressure from the pneumoperitoneum caused enough pressure to prevent the contrast from significantly extravasating from the

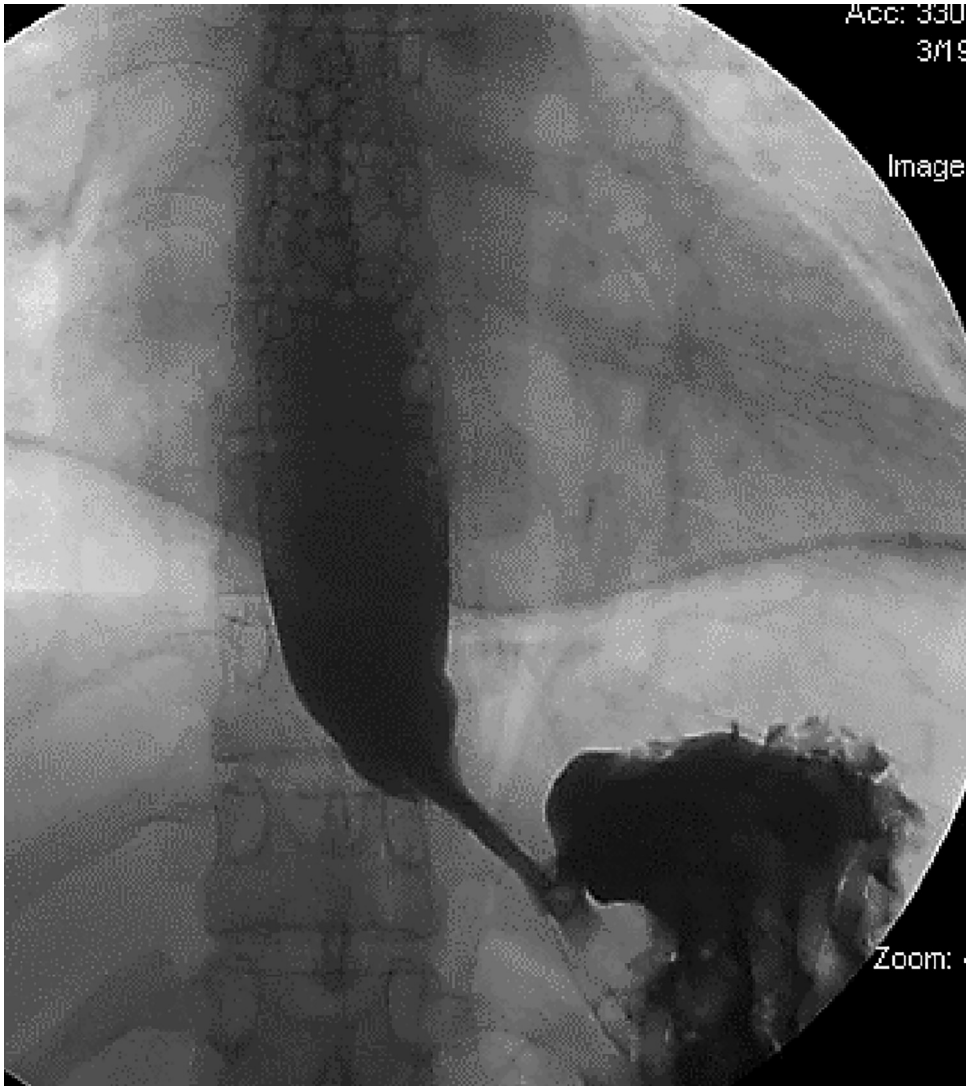

Fig. 3. Contrast esophagram without extravasation.

large stomach defects. We ordered this study because she maintained hemodynamic stability with IVF and esophageal perforation was first on our differential. We thought if we saw it on the contrast esophagram, that our surgical approach might be different, i.e. a thoracic approach as opposed to an abdominal approach.

5. Conclusion

Only 12% of people with out-of-hospital cardiac arrest survived to discharge in 2016 as reported by the latest American Heart Association statistics [8]. In those patients who do survive, it is essential to have a high index of suspicion for concomitant injuries which could lead to further morbidity and mortality. Abdominal visceral injuries are rare following CPR but do occur and will likely require an invasive intervention. In our case, where the injury presented with tension pneumoperitoneum, the Veress needle was an effective tool to decompress the abdomen prior to surgical intervention and to maintain hemodynamic status. Of note, this is the first case reported, to our knowledge, of using a Veress needle in the operating room to decompress the abdomen in this type of situation. If this presentation comes to our hospital again, gastric perforation as well as other potential visceral injuries will be much higher on our differential. Surviving cardiac arrest as a young person and living without deficits outweighs the risk of a surgical correction for a visceral injury. While resuscitation measures are critical for survival, medical personnel need to be aware of potential complications from resuscitative efforts and potential management strategies. This message needs to be disseminated widely amongst providers who are likely to deal with this patient population.

Our case has been reported in line with the SCARE criteria [9].

Conflicts of interest

None.

Funding

This research did not receive any specific grant from funding agencies in the public, commercial, or not-for-profit sectors.

All authors have approved the final article.

Ethical approval

Our institutional review board does not require approval for case reports but informed consent to publish has been received from the patient discussed in this case report.

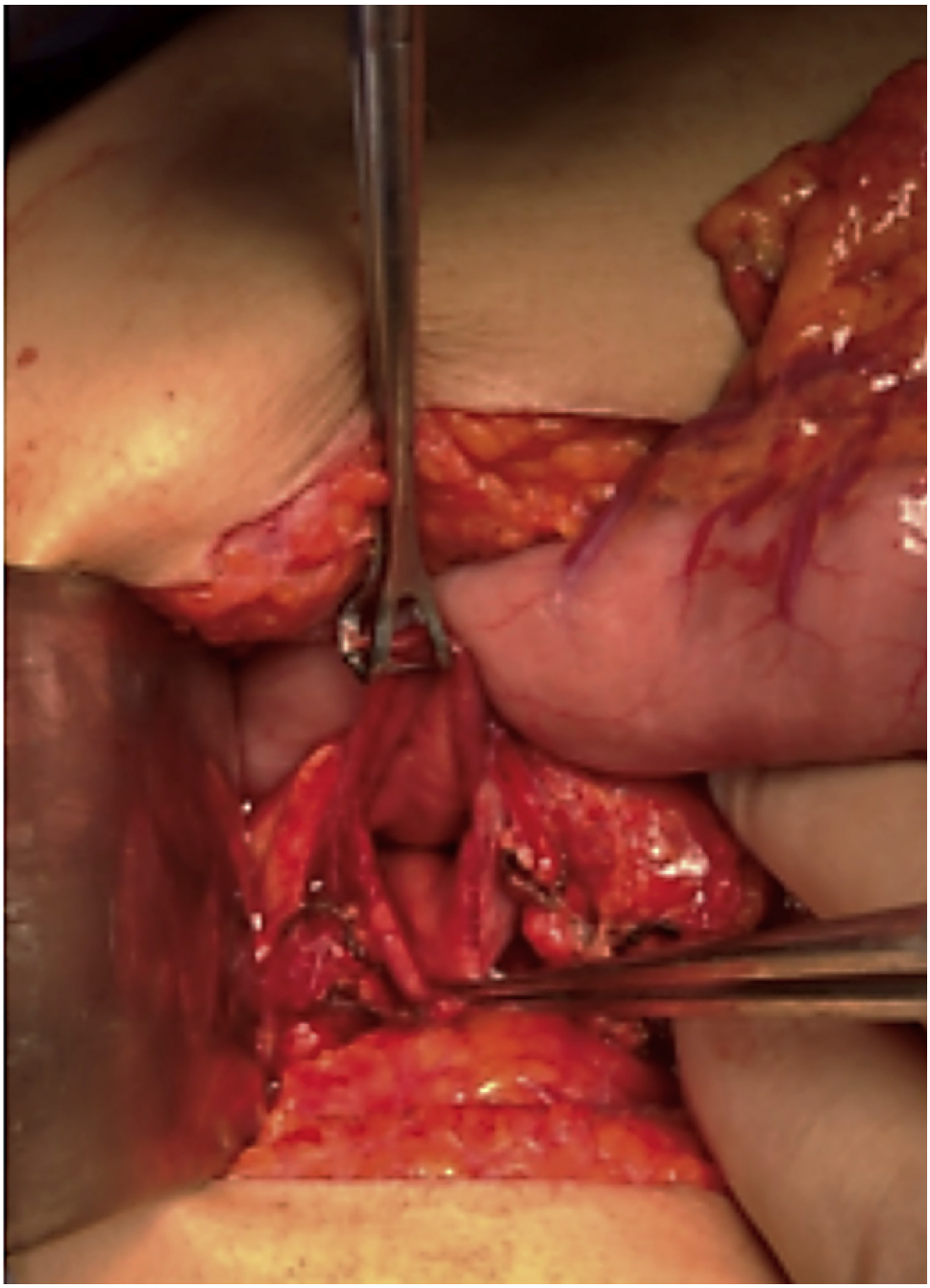

Fig. 4. One of the two gastric perforations (about three cm each) on the lesser curvature of the stomach near the GE junction.

Consent

Our institutional review board does not require approval for case reports but informed consent was obtained from the patient for publication of this case report and accompanying images. A copy of the consent is available for review by the Editor-in-Chief of this journal on request.

Authors contribution

Sherry Johnson, DO, Jessica McCracken DO and Fadi Baidoun MD have contributed in the study concept and writing.

Guarantors

Sherry Johnson, DO, Jessica McCracken DO and Fadi Baidoun MD.

References

[1] C.T. Buschmann, M. Tsokos, Frequent and rare complications of resuscitation attempts, Intensive Care Med. 35 (2009) 397.

[2] I. Spoormans, K. Hoorenbeeck, L. Balliu, P. Jorens, Gastric perforation after cardiopulmonary resuscitation: review of the literature, Resuscitation 81 (2010) 272–280.

[3] American Heart Association, 2015, American Heart Association Guidelines Update for Cardiopulmonary Resuscitation and Emergency Cardiovascular Care. Available at: https://eccguidelines.heart.org/wp-content/uploads/2015/10/2015-AHA-Guidelines-Highlights-English.pdf. Accessibility verified March 10, 2017.

[4] G. Nichol, F. Kim, Bystander interventions can improve outcomes from out-of-hospital cardiac arrest, JAMA 314 (3) (2015) 231–232.
[5] G. Meron, I. Kurkciyan, F. Sterz, M. Susani, H. Domanovits, K. Tobler, et al., Cardiopulmonary resuscitation-associated major liver injury, Resuscitation 75 (3) (2007) 445–453.
[6] S.M. Jalali, H. Emami-Razavi, A. Mansouri, Gastric perforation after cardiopulmonary resuscitation, Am. J. Emerg. Med. 30 (2012) 2091, e1–2091. e2.
[7] A. Sajith, B. O-Donohue, R.M. Roth, R.A. Khan, CT scan findings in oesophagogastric perforation after out of hospital cardiopulmonary resuscitation, Emerg. Med. J. 25 (2008) 2.
[8] American Heart Association, 2016, Out-of-Hospital and In-Hospital Cardiac Arrest Statistics. Available at: http://www.cpr.heart.org/AHAECC/CPRAndECC/General/UCM_477263_Cardiac-Arrest-Statistics.jsp. Accessibility verified November 25, 2017.
[9] R.A. Agha, A.J. Fowler, A. Saetta, I. Barai, S. Rajmohan, D.P. Orgill, SCARE Group, The SCARE statement: consensus-based surgical case report guidelines, Int. J. Surg. 34 (2016) 180–186.