



Case Report

Dilation of proximal internal carotid artery collapse due to severe distal stenosis after angioplasty for distal stenosis: A case report

Masanori Kinosada, Hiroyuki Ikeda¹, Takumi Morita¹, Makoto Wada, Minami Uezato, Yoshitaka Kurosaki, Masaki Chin

Department of Neurosurgery, Kurashiki Central Hospital, Kurashiki, Japan.

E-mail: *Masanori Kinosada - masanorik3@gmail.com; Hiroyuki Ikeda - rocky@kuhp.kyoto-u.ac.jp; Takumi Morita - kapipara10000@gmail.com; Makoto Wada - ysichi87h9@gmail.com; Minami Uezato - mysichi87h9@gmail.com; Yoshitaka Kurosaki - kurosaki0106@gmail.com; Masaki Chin - mc13552@kchnet.or.jp



*Corresponding author:

Masanori Kinosada,
Department of Neurosurgery,
Kurashiki Central Hospital,
Kurashiki, Japan.

masanorik3@gmail.com

Received : 09 January 2023

Accepted : 15 February 2023

Published : 24 February 2023

DOI

10.25259/SNI_27_2023

Quick Response Code:



ABSTRACT

Background: We report a case of proximal internal carotid artery (ICA) collapse due to severe distal stenosis that dilated after angioplasty for distal stenosis.

Case Description: A 69-year-old woman underwent thrombectomy for the left ICA occlusion due to stenosis of C3 portion and was discharged home with a modified Rankin Scale score of 0. One year later, she developed cerebral infarction due to progressive stenosis of the C3 portion of the left ICA with proximal ICA collapse and underwent emergency percutaneous transluminal angioplasty (PTA) for distal stenosis. Device guidance to the stenosis was difficult due to proximal ICA collapse. After PTA, blood flow in the left ICA increased, and proximal ICA collapse dilated over time. Due to severe residual stenosis, she underwent more aggressive PTA followed by Wingspan stenting. Device guidance to the residual stenosis was facilitated because proximal ICA collapse had already dilated. Six months later, proximal ICA collapse further dilated.

Conclusion: PTA for severe distal stenosis with proximal ICA collapse may result in dilation of proximal ICA collapse over time.

Keywords: Dilation, Distal stenosis, Percutaneous transluminal angioplasty, Proximal collapse, Wingspan

INTRODUCTION

Carotid artery near-occlusion is a condition, in which blood flow to the distal internal carotid artery (ICA) is reduced due to severe stenosis of the proximal ICA, resulting in collapse of the ICA distal to the stenosis, and narrowing of the vessel diameter.^[11] Carotid endarterectomy (CEA) or carotid artery stenting (CAS) for carotid near-occlusion often improves distal ICA collapse.^[5,10] However, there are no reports of improvement of proximal ICA collapse over time after percutaneous transluminal angioplasty (PTA) in patients with proximal ICA collapse due to severe distal stenosis, and the time required for improvement is unknown. Furthermore, proximal ICA collapse makes it difficult to guide devices to distal stenosis. This report presents a case of proximal ICA collapse due to severe distal stenosis that dilated after angioplasty for distal stenosis.

This is an open-access article distributed under the terms of the Creative Commons Attribution-Non Commercial-Share Alike 4.0 License, which allows others to remix, transform, and build upon the work non-commercially, as long as the author is credited and the new creations are licensed under the identical terms.

©2023 Published by Scientific Scholar on behalf of Surgical Neurology International

CASE REPORT

Patient

A 69-year-old woman.

Present illness

One year before, the patient presented with the right upper and lower extremity paralysis. The National Institutes of Health Stroke Scale (NIHSS) score was 10, and the Alberta stroke program early computed tomography (CT) score was also 10. Computed tomography-angiography (CTA) showed left ICA occlusion [Figure 1a]. After intravenous alteplase injection, thrombectomy was performed. A 9-Fr balloon-guided catheter was guided to the cervical portion of the left ICA. Angiography showed occlusion of the left ICA and collateral vessels in the C2 portion of the ICA from the external carotid artery and ophthalmic artery [Figures 1b and c]. A stent retriever was used to retrieve the thrombus in the C3 portion of the ICA, and thrombolysis in cerebral infarction 2b recanalization was achieved [Figures 1d and e]. Stenosis of Warfarin-Aspirin Symptomatic Intracranial Disease (WASID) 68% was observed at the C3 portion of the ICA [Figure 1e], but no additional treatment

was performed, because blood flow distal to the stenosis was excellent. Postoperatively, she made a full recovery, and magnetic resonance angiography (MRA) the day after thrombectomy showed the patency of the left ICA [Figure 1f]. Since no embolic source of cerebral infarction was found, she was considered to have an atherothrombotic cerebral infarction at the C3 portion of the left ICA. She was discharged home with a Modified Rankin Scale score of 0 after the management of medical risk factors and induction of aspirin 100 mg/day and was followed up as an outpatient. Two months before being treated for present illness, before the patient experienced transient right upper extremity weakness several times. Subsequently, persistent right upper extremity weakness, transient motor apraxia, and right facial paralysis appeared, and she presented to the emergency room. The Glasgow coma scale score was 15 (E4V5M6). Right upper extremity paralysis (manual muscle testing 4) and right hemisensory paresthesia were present. The NIHSS score was 2. Magnetic resonance imaging (MRI) showed scattered cerebral infarctions in the left cerebral hemisphere, and MRA showed reduced blood flow signals in the left ICA and left middle cerebral artery (MCA) [Figure 2a]. CT perfusion imaging showed decreased cerebral blood flow in the left MCA region. An urgent cerebral angiogram was

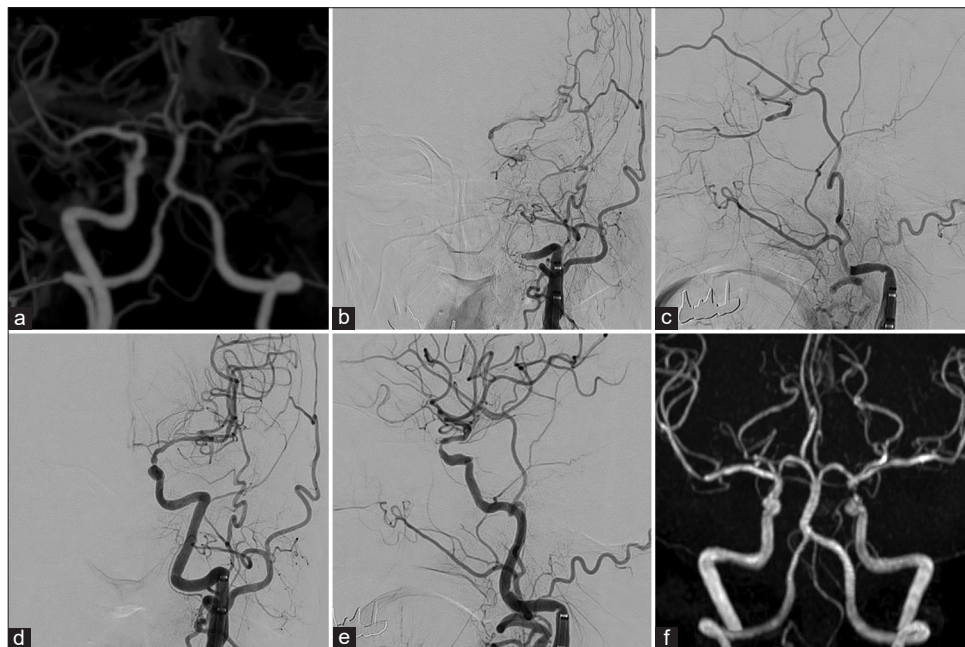


Figure 1: Perioperative images of thrombectomy performed 1-year ago. (a) Preoperative CTA showing left ICA occlusion. (b and c) Preoperative angiography showing occlusion of the left ICA and collateral vessels in the C2 portion of the ICA from the external carotid artery and ophthalmic artery to the distal ICA (b: frontal view, c: lateral view). (d and e) Postoperative angiography showing TICI 2b recanalization and WASID 68% stenosis in the C3 portion of the left ICA (d: frontal view, e: lateral view). (f) Magnetic resonance angiography the day after thrombectomy showing the patency of the left ICA. ICA: Internal carotid artery, TICI: Thrombolysis in cerebral infarction, WASID: Warfarin-aspirin symptomatic intracranial disease.

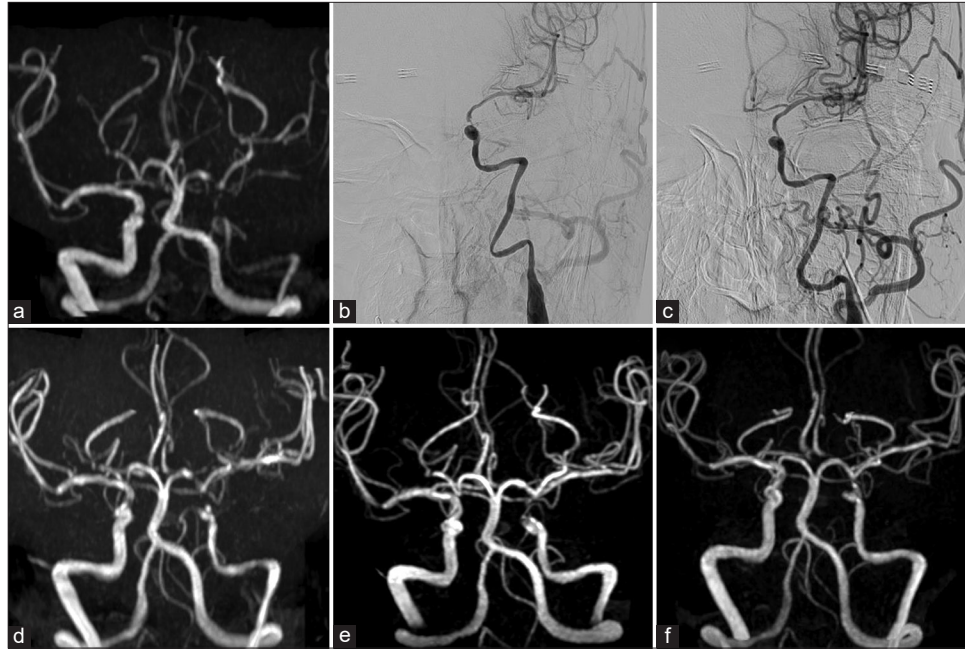

Figure 2: Perioperative images of initial percutaneous transluminal angioplasty. (a) Preoperative MRA showing reduced blood flow signals in the left ICA and left MCA. (b) Preoperative angiography showing severe stenosis of WASID 92% in the C3 portion of the left ICA with proximal ICA collapse and blood flow delay in the left MCA region. (c) Postoperative angiography showing dilatation of the stenosis (WASID 71%) and disappearance of blood flow delay in the left MCA region. (d) MRA the day after PTA showing increased blood flow signals in the left ICA and left MCA compared to preoperative ones, but the left-right asymmetry in ICA diameters remained. (e) MRA 5 days after PTA showing increased blood flow signals in the left ICA. (f) MRA 11 days after PTA showing maintenance of increased blood flow signals in the left ICA. MRA: Magnetic resonance angiography, ICA: Internal carotid artery, MCA: Middle cerebral artery, PTA: Percutaneous transluminal angioplasty, WASID: Warfarin-aspirin symptomatic intracranial disease.

performed for suspected progression of stenosis at the C3 portion of the left ICA. Although the left ICA maintained antegrade blood flow, severe stenosis of WASID 92% at the C3 portion of the ICA with proximal ICA collapse and blood flow delay in the left MCA region were observed [Figure 2b]. Since she was symptomatic with marked progression of stenosis, PTA was planned urgently and clopidogrel 300 mg was administered.

Initial PTA

An 8-Fr Optimo Epd balloon catheter (Tokai Medical Products, Kasugai, Japan) was guided to the cervical portion of the left ICA. It was deemed difficult to guide a distal access catheter to proximal ICA collapse, so an Excelsior SL-10 microcatheter (Stryker, Kalamazoo, MI, USA) and a Chikai 14 200 cm guidewire (Asahi Intecc, Seto, Japan) were guided from the Optimo Epd. The CHIKAI 14 passed through the stenosis and reached the MCA superior trunk. The Excelsior SL-10 was removed from the extended CHIKAI 14, and an Unryu xp 1.5 mm × 10 mm (Kaneka Medix, Osaka, Japan)

was guided along the CHIKAI 14, but collapse and tortuosity of the proximal ICA made it difficult to guide it to the stenosis. Staged dilatation of the C3 portion of the ICA was performed with an Unryu xp balloon 1.5 mm × 10 mm and an Unryu xp balloon 2.0 mm × 10 mm. Angiography confirmed dilatation of the stenosis (WASID 71%) and disappearance of blood flow delay in the left MCA region, and the operation was completed [Figure 2c]. Since it was difficult to guide the Unryu xp balloons from the Optimo Epd through proximal ICA collapse to the stenosis at the C3 portion of the ICA, it was also deemed difficult to guide a Wingspan stent system (Stryker) at this stage.

The day after PTA, she improved to no neurological deficit, and clopidogrel 75 mg/day was added to the medication; MRI showed no enlargement of the infarcted area, and MRA showed increased blood flow signals in the left ICA and left MCA compared to preoperatively, but the left-right asymmetry in the ICA diameters remained [Figure 2d]. MRA 5 days after PTA showed further increased blood flow signals in the left ICA and dilation of proximal ICA collapse [Figure 2e]; and MRA 11 days after PTA confirmed

maintenance of increased flow signals in the left ICA [Figure 2f].

Despite management of medical risk factors and administration of one antiplatelet drug, a second cerebral infarction due to stenosis at the C3 portion of the left ICA occurred, for which stenting was indicated. Since MRA and CTA confirmed dilation of proximal ICA collapse, Wingspan stenting was deemed feasible by placing a distal access catheter in the proximal ICA. A second PTA was scheduled 13 days after initial PTA.

Second PTA

Angiography showed dilation of proximal ICA collapse and improvement of vascular tortuosity [Figure 3a]. An 8-Fr Optimo Epd was placed in the cervical portion of the left ICA. A 6-Fr Cerulean guiding catheter (Medikit, Tokyo, Japan) was guided to the C5 portion of the ICA. A Chikai 14 315 cm was guided from the 6-Fr Cerulean to the M2 superior trunk, and predilatation of stenosis at the C3 portion of the ICA was performed with a Gateway balloon catheter 2.5 mm × 15 mm (Stryker), followed by deployment of a Wingspan 3.5 mm × 15 mm. Postdilatation was performed with a Gateway 3 mm × 9 mm. Angiography showed dilatation of stenosis (WASID 55%) [Figure 3b]. Because proximal ICA collapse and tortuosity had improved, any devices were easy to guide.

Postoperative course

Postoperative neurological findings were normal. MRA the day after stenting showed good blood flow in the left ICA [Figure 3c]. The postoperative course was uneventful, and she was discharged home 6 days after stenting. Six months later, MRA and angiography showed further dilated proximal ICA collapse [Figure 3d]; angiography showed no restenosis at the C3 portion of the left ICA. Since then, she undergoes

regular outpatient MRI and MRA, and no recurrent cerebral infarction has been detected.

DISCUSSION

The course of this case suggested that proximal ICA collapse occurs due to distal stenosis, that dilatation of distal stenosis improves proximal ICA collapse, and that this improvement is obtained at an early stage. Detailed reports documenting proximal ICA collapse due to distal stenosis have been scarce, whereas there are many reports on the treatment course of distal ICA collapse due to cervical ICA stenosis. In cases of symptomatic cervical ICA stenosis of 50% or more, the frequency of distal ICA collapse is relatively low, ranging from 5% to 12%.^[6,8] Furthermore, it has been reported that 3.8% of cases undergoing CAS for cervical ICA stenosis involved distal ICA collapse.^[13] Considering these reports, proximal ICA collapse associated with distal stenosis is a relatively rare condition.

Just as distal ICA collapse due to proximal stenosis may dilate after dilatation of proximal stenosis, proximal ICA collapse due to distal stenosis may dilate after dilatation of distal stenosis. Distal ICA collapse due to proximal stenosis occurs when severe proximal stenosis reduces blood flow to the distal ICA.^[3,9] A similar mechanism is expected for proximal ICA collapse; dilatation of distal stenosis increases blood flow and dilation of proximal ICA collapse. The increased blood flow also improved the tortuosity of the ICA by increasing pressure on the vessel wall and straightening the vessel. Matsuda *et al.* reported that 55.4% of cases of distal ICA collapse due to cervical ICA stenosis dilated immediately after CAS, and that 76.5% of those that did not dilate immediately after CAS dilated during a mean follow-up period of 6.75 months.^[10] In this case, PTA alone was performed without stenting for distal ICA stenosis. Although the improvement in proximal

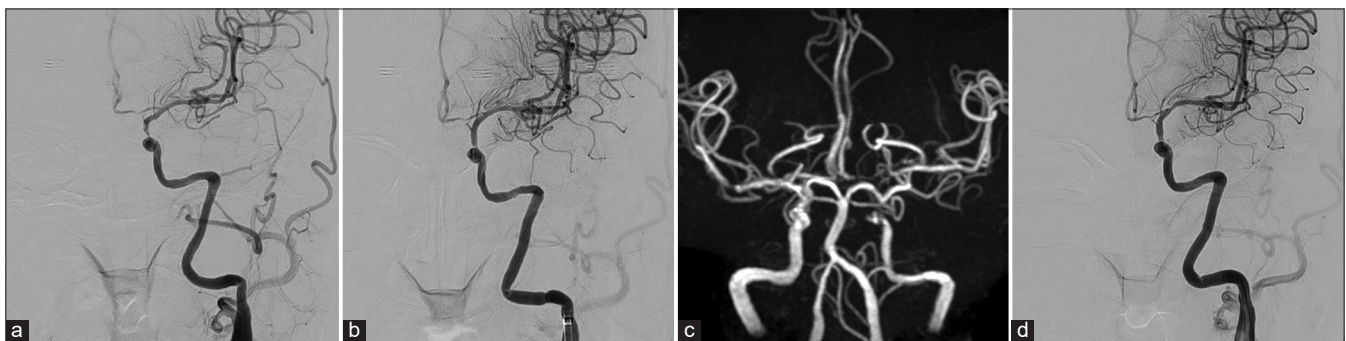


Figure 3: Perioperative images of second percutaneous transluminal angioplasty. (a) Preoperative angiography showing dilatation of proximal ICA collapse and improvement of vascular tortuosity. (b) Postoperative angiography showing dilatation of stenosis (WASID 55%). (c) Magnetic resonance angiography the day after stenting showing good blood flow in the left ICA. (d) Angiography 6 months after stenting showing further improvement of proximal ICA collapse. ICA: Internal carotid artery, WASID: Warfarin-aspirin symptomatic intracranial disease.

ICA collapse immediately after PTA was very mild, the increased blood flow in the ICA compared to before PTA may have improved proximal ICA collapse over time. Thus, the results of this study suggest that even balloon PTA alone may improve proximal ICA collapse over time as well as blood flow in the ICA.

Since proximal ICA collapse in this case began to dilate 5 days after PTA, dilation of proximal ICA collapse may be obtained early after dilatation of distal stenosis. Matsuda *et al.* classified cervical ICA stenosis into a single-channel group and a multiple-channel group and reported that the single-channel group achieved improvement in distal vessel diameter immediately after CAS.^[10] This may be because the single-channel group had not yet undergone organic changes after blood flow impairment.^[4,7] Therefore, the longer the disease duration, the poorer the dilatation after PTA of proximal ICA collapse due to distal stenosis. In the treatment of distal ICA collapse due to cervical ICA stenosis, Matsuda *et al.* used multiple stents in 43.5% of multiple-channel cases, and Omoto *et al.* used multiple stents in 77.8% of cases.^[10,13] Thus, there are relatively many cases, in which dilatation of cervical ICA stenosis alone is insufficient, and it is considered necessary to determine whether the lesion is a tandem stenotic lesion, which is difficult to determine by preoperative digital subtraction angiography findings.^[2] In this case, the intraoperative findings 1 year before PTA showed no proximal ICA collapse, suggesting that the time course of proximal ICA collapse was not long and did not cause organic changes. In addition, no tandem stenotic lesions were observed. Thus, the increased blood flow due to dilatation of distal stenosis may have begun to improve vessel diameter at an early stage.

In PTA for stenosis, device guidance to the stenosis and device maneuverability greatly affects the success or failure of the procedure. It has been reported that patients with distal ICA collapse associated with cervical ICA stenosis have difficulty in shunt insertion during CEA due to the narrow distal ICA.^[14] In addition, it has been reported that CAS failed due to difficulty in system delivery, causing dissection and spasm.^[1,10,12] Therefore, device induction into a collapsed ICA should be done with caution. Wingspan does not have good vessel tracking, and the condition of the vessels proximal to the stenosis makes it difficult to guide it to the stenosis. In emergency cases in which device guidance is difficult due to proximal ICA collapse, as in this case, blood flow should first be improved with modest PTA. After dilation of proximal ICA collapse is confirmed by imaging modalities, more aggressive PTA such as Wingspan stenting should be performed depending on the severity of residual stenosis. However, it is still unclear in what cases proximal ICA collapse dilates and when it dilates, and further case accumulation is needed.

CONCLUSION

PTA for distal stenosis with proximal ICA collapse may result in dilation of proximal ICA collapse over time.

Declaration of patient consent

The authors certify that they have obtained all appropriate patient consent.

Financial support and sponsorship

Nil.

Conflicts of interest

There are no conflict of interest.

REFERENCES

1. Cay F, Cil BE, Balci S, Arsava EM, Topçuoğlu MA, Arat A. Relevance of distal arterial collapse in stenting of atherosclerotic near-occlusion of the carotid artery. *AJNR Am J Neuroradiol* 2020;41:1054-60.
2. Chai S, Sheng Z, Xie W, Wang C, Liu S, Tang R, *et al.* Assessment of apparent internal carotid tandem occlusion on high-resolution vessel wall imaging: Comparison with digital subtraction angiography. *AJNR Am J Neuroradiol* 2020;41:693-9.
3. Clark OH, Moore WS, Hall AD. Radiographically occluded, anatomically patent carotid arteries. *Arch Surg* 1971;102:604-6.
4. Glagov S, Bassiouny HS, Sakaguchi Y, Goudet CA, Vito RP. Mechanical determinants of plaque modeling, remodeling and disruption. *Atherosclerosis* 1997;131:S13-4.
5. Greiner C, Wassmann H, Palkovic S, Gauss C. Revascularization procedures in internal carotid artery pseudo-occlusion. *Acta Neurochir (Wien)* 2004;146:237-43.
6. Gu T, Aviv RI, Fox AJ, Johansson E. Symptomatic carotid near-occlusion causes a high risk of recurrent ipsilateral ischemic stroke. *J Neurol* 2020;267:522-30.
7. Hirata Y, Sakata N, Tsuchimochi H, Tsugu H, Onishi H, Inoue T. Carotid endarterectomy for pseudo-occlusion of the cervical internal carotid artery. *Acta Neurochir Suppl* 2014;119:91-6.
8. Johansson E, Öhman K, Wester P. Symptomatic carotid near-occlusion with full collapse might cause a very high risk of stroke. *J Intern Med* 2015;277:615-23.
9. Lippman HH, Sundt TM Jr, Holman CB. The poststenotic carotid slim sign: Spurious internal carotid hypoplasia. *Mayo Clin Proc* 1970;45:762-7.
10. Matsuda Y, Terada T, Okada H, Masuo O, Ohshima K, Tsuura M, *et al.* Angiographic characteristics of pseudo-occlusion of the internal carotid artery before and after stenting. *Neurosurgery* 2016;79:832-8.
11. Morgenstern LB, Fox AJ, Sharpe BL, Eliasziw M, Barnett HJ, Grotta JC. The risks and benefits of carotid endarterectomy in patients with near occlusion of the carotid artery. *North*

- American Symptomatic Carotid Endarterectomy Trial (NASCET) Group. *Neurology* 1997;48:911-5.
12. Neves CR, Casella IB, da Silva ES, Puech-Leão P. Medical therapy for asymptomatic patients and stent placement for symptomatic patients presenting with carotid artery near-occlusion with full collapse. *J Vasc Interv Radiol* 2018;29:998-1005.
 13. Omoto K, Takayama K, Myouchin K, Wada T, Nakagawa I, Tanaka T, *et al.* Carotid artery stenting for near occlusion with full collapse. *World Neurosurg* 2022;163:e215-22.
 14. Zhang J, Chen J, Xu X, Sun M, Chen S, Liu P, *et al.* Carotid endarterectomy for the treatment of carotid near-occlusion with recurrent symptoms. *Front Neurol* 2022;13:765-95.

How to cite this article: Kinosada M, Ikeda K, Morita T, Wada M, Uezato M, Kurosaki Y, *et al.* Dilatation of proximal internal carotid artery collapse due to severe distal stenosis after angioplasty for distal stenosis: A case report. *Surg Neurol Int* 2023;14:75.

Disclaimer

The views and opinions expressed in this article are those of the authors and do not necessarily reflect the official policy or position of the Journal or its management. The information contained in this article should not be considered to be medical advice; patients should consult their own physicians for advice as to their specific medical needs.