



Case report

Case series: Delayed diagnoses of *Acanthamoeba* keratitis

Moon Jeong Lee, Divya Srikumaran, Sidra Zafar, Mahsa Salehi, Tiffany S. Liu, Fasika A. Woreta *

Wilmer Eye Institute, Johns Hopkins University School of Medicine, 600 N Wolfe St, Wilmer, Baltimore, MD, 21287, USA

ARTICLE INFO

Keywords:

Acanthamoeba keratitis
Contact lens
Atypical keratitis

ABSTRACT

Purpose: To describe two cases of *Acanthamoeba* keratitis in contact lens wearers misdiagnosed as *Herpes simplex* keratitis.

Observations: Case 1 is a 54-year-old male that was misdiagnosed with *Herpes simplex* keratitis who developed advanced *Acanthamoeba* keratitis. His treatment course was complex and involved both medical therapy and surgical intervention with poor resolution. Case 2 is an 18-year-old male who was also initially misdiagnosed and treated for *Herpes simplex* keratitis, but ultimately treated with polyhexamethylene biguanide and chlorhexidine with complete resolution.

Conclusions and importance: The clinical presentation of *Acanthamoeba* keratitis may closely resemble other causes of keratitis and continues to be misdiagnosed, leading to delayed diagnosis and treatment. However, given the significant morbidity and challenging treatment course for *Acanthamoeba* keratitis, it is important for clinicians to maintain a high suspicion for *Acanthamoeba* and to consider obtaining cultures in contact lens wearers with atypical keratitis prior to making a diagnosis of *Herpes simplex* keratitis.

1. Introduction

Acanthamoeba is an uncommon, chronic, mainly contact lens-related parasitic infection that can cause significant visual morbidity. It is a rare cause of infection that is commonly misdiagnosed, with a delay in diagnosis often leading to poor outcomes.^{1,2} It usually causes a progressive ulcerative keratitis that is unresponsive to common antimicrobial therapy. Depending on the stage of infection, *Acanthamoeba* keratitis may resemble an atypical keratitis such as those seen with *Herpes simplex* or fungi.³ Early diagnosis is thus important to prevent significant morbidity and vision loss from *Acanthamoeba* infection.⁴ Here, we report two cases of *Acanthamoeba* keratitis misdiagnosed as herpetic keratitis. These cases highlight the importance of obtaining *Acanthamoeba* cultures in contact lens wearers presenting with atypical keratitis prior to making a presumed diagnosis of *Herpes simplex* keratitis.

2. Case 1

A 54-year-old male was referred to the Wilmer Eye Institute, Johns Hopkins Hospital with a 2-week history of left eye pain associated with blurred vision, photophobia and excessive lacrimation. His past ocular and medical history were significant for daily soft contact lens wear.

Prior to his presentation at the Wilmer Eye Institute, the patient had been unsuccessfully treated for keratoconjunctivitis with oral valacyclovir, bacitracin, difluprednate, besifloxacin, and moxifloxacin at an outside facility.

Upon presentation to Wilmer, his visual acuity in the left eye was 20/60, which improved to 20/25 on pinhole. His intraocular pressure (IOP) was 18 mm Hg and slit lamp examination revealed 1+ injection of the conjunctiva/sclera, a sectoral heaped dendrite, diffuse punctate epithelial erosions, corneal edema, focal keratic precipitates, and trace flare in the anterior chamber. Herpetic endotheliitis was suspected and his oral valacyclovir, difluprednate and bacitracin were continued.

On follow-up 2 weeks later, the patient reported having improved vision. Photophobia and pain in his left eye, however, had increased. His outside ophthalmologist had tapered his difluprednate. Slit lamp examination revealed no significant changes. Suspecting an increase in inflammation resulting from the corticosteroid taper, the patient's difluprednate was subsequently increased.

During subsequent follow-up at Wilmer, the patient noted continually improving symptoms. His medication regimen of valacyclovir, difluprednate and bacitracin was thus continued. More than 1 month following his initial presentation to Wilmer, he reported worsening symptoms and decreased visual acuity. On examination, his left eye visual acuity was 20/40–1 and his IOP was 18 mm Hg. On slit lamp

* Corresponding author. Johns Hopkins Hospital, 600 N. Wolfe Street, Wilmer B20, Baltimore, MD, 21287, USA.

E-mail address: fworeta1@jhmi.edu (F.A. Woreta).

<https://doi.org/10.1016/j.ajoc.2020.100778>

Received 17 September 2018; Received in revised form 19 May 2020; Accepted 7 June 2020

Available online 10 June 2020

2451-9936/© 2020 Published by Elsevier Inc. This is an open access article under the CC BY-NC-ND license (<http://creativecommons.org/licenses/by-nc-nd/4.0/>).

examination (Fig. 1), he had worsening conjunctival/scleral injection (3+), corneal edema, and diffuse keratic precipitates. His exam was negative for herpetic lesions or significant follicular conjunctival reaction. Fluorescein staining showed an early circular dendritic appearing ulcer with excavated areas of fluorescein pooling (Fig. 2). At this time, corneal scrapings were taken for culture of fungi, bacteria and *Acanthamoeba*, and the patient was started on prednisolone acetate instead of difluprednate and polymyxin B.

After 48 hours, the non-nutrient agar with *E. coli* overlay was positive for *Acanthamoeba* and the patient was subsequently started on voriconazole and polyhexamethylene biguanide (PHMB) in addition to polymyxin B. Slit lamp and fluorescein staining photos were repeated after 2 weeks of therapy (Fig. 3). Slit lamp examination showed a large epithelial defect centrally with a ring infiltrate. His following treatment course was complex, and his medication regimen involved steroids, antibiotics, oral valacyclovir, oral and topical non-steroidal anti-inflammatory drugs, voriconazole, and PHMB. He also received multiple corneal bandage placements, amniotic extracellular matrix placement and bandage contact lens placement for persistent keratitis. A corneal biopsy was done to assess for the presence of any resisting infection along with a membrane graft and tarsorrhaphy for a persistent corneal ulcer. The biopsy showed persistent *Acanthamoeba* infection and thus corneal cross-linking (standard protocol of 3mW/cm² over an exposure period of 30 minutes) was performed. At his last follow-up visit approximately 1 year from presentation, his visual acuity in the left eye was hand motion secondary to a complete conjunctivalization and neovascularization of the cornea.

3. Case 2

An 18-year-old male presented to the emergency department (ED) at Johns Hopkins Hospital with a 7-week history of left eye pain and blurred vision associated with redness, swelling and eye discharge. His past history was significant for occasionally sleeping with his contact lenses over a period of 2 years. Prior to presentation at the ED, he had been diagnosed with a corneal ulcer by an outside ophthalmologist and was being treated with moxifloxacin and steroid drops. Upon examination, visual acuity in the left eye was 20/70–1, improving to 20/50 on pinhole with a pressure of 19 mm Hg. Slit lamp examination revealed conjunctival injection around the limbus, and peripheral small circular subepithelial defects with stromal haze. At this time, he was diagnosed with herpetic stromal keratitis and started on oral valacyclovir and cyclopentolate.

On follow-up 2 days later at Wilmer, the patient reported improvement in symptoms. His visual acuity was 20/60–1 improving to 20/50–1 on pinhole and IOP was 11 mm Hg. Slit lamp examination showed no changes and prednisolone acetate was added to his regimen. Four days later, the patient reported improved vision and decreased pain. His cyclopentolate was subsequently discontinued and his prednisolone

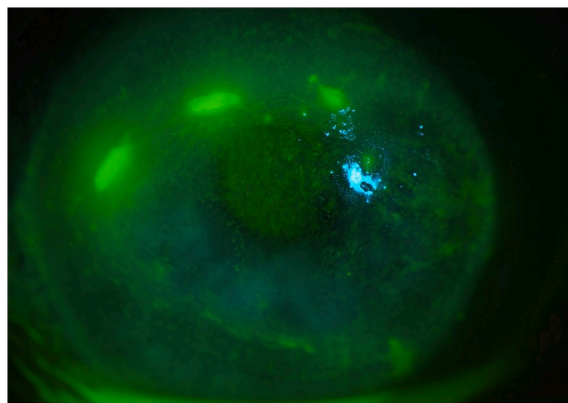


Fig. 2. Case 1 - Left eye fluorescein staining showing an early circular dendritic appearing ulcer with excavated areas of fluorescein pooling.

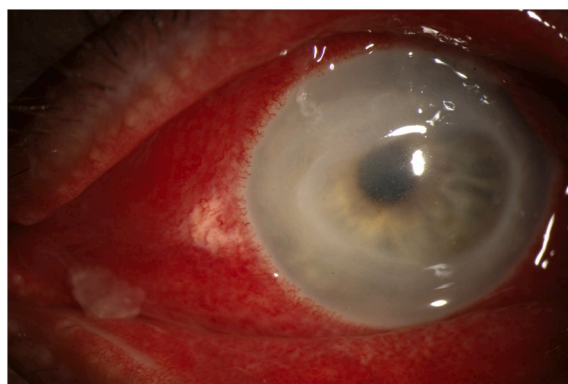


Fig. 3. Case 1 - Left eye slit lamp photograph.

acetate was tapered.

Approximately 1 month following his initial presentation to the ED, the patient returned with persistent blurred vision, and pain in his left eye. At this time, he was not on any oral or ocular medications. His visual acuity was 20/70 improving to 20/40 on pinhole and his IOP was 10 mm Hg. Slit lamp examination revealed reactive ptosis, conjunctival injection, reduced corneal sensitivity, diffuse punctate erosions, multifocal subepithelial haze and cells in the anterior chamber (Fig. 4). A detailed history revealed well water exposure and a habit of washing his contact lenses with tap water. Cultures were then collected on non-nutrient agar with *E. coli* overlay which came back positive for *Acanthamoeba*. The patient was consequently started on chlorhexidine and PHMB.

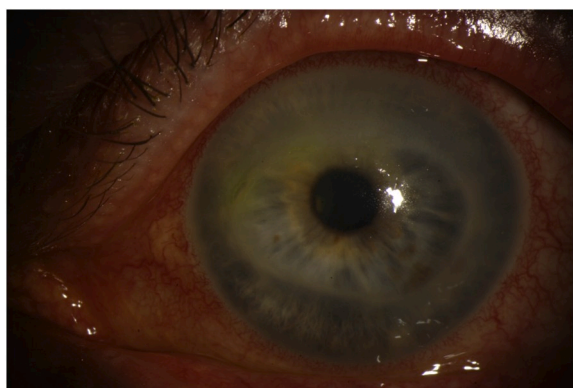


Fig. 1. Case 1 - Left eye slit lamp photograph.

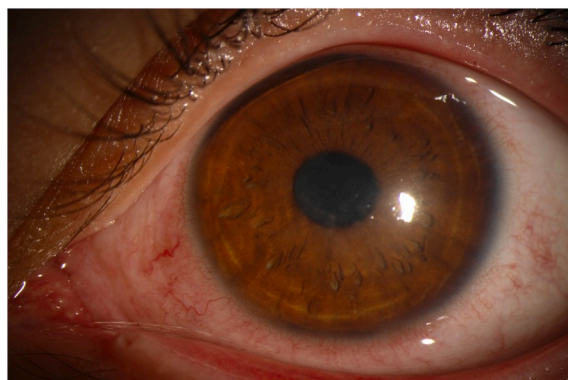

Fig. 4. Case 2 - Left eye slit lamp photograph showing corneal haze.

The patient was closely followed over the next several months. At his final follow-up visit 4 months following his initial presentation to the ED, the patient reported resolution of symptoms and return to baseline. His visual acuity at this visit was 20/30–2 improving to 20/25 + 2. He was tapered off the corticosteroid and instructed to discontinue PHMB and chlorhexidine after 1 month. The patient did not return for additional follow-up.

4. Discussion

Acanthamoeba sp. is a free-living cyst-forming protozoan found ubiquitously in the air, soil and water that is responsible for approximately 2% of all corneal infections.^{5,6} *Acanthamoeba* keratitis is a severe sight-threatening infection that can cause significant morbidity, resulting in vision loss in one third of patients and corneal transplantation in 25% of patients.^{4,6} An early diagnosis has been consistently cited as an important prognostic factor in visual outcomes,⁷ need for surgical intervention,² a higher cure rate, and lower morbidity.^{8,9} The primary risk factor for *Acanthamoeba* keratitis is contact lens wear, with approximately 85–88% of *Acanthamoeba* keratitis cases occurring in contact lens wearers, and an expected annual incidence of 1 in 30,000 in people who wear contact lenses.^{6,10}

The life cycle of *Acanthamoeba* consists of two stages: an active trophozoite stage and a dormant cyst stage, both which contribute to the clinical presentation and relative resistance to treatment. The trophozoite stage is responsible for active disease.^{11,12} Under optimal conditions, trophozoites divide mitotically and produce infection. However, exposure to harsher conditions causes transformation into the dormant cyst form, allowing *Acanthamoeba* to survive under harsh conditions and cause persistent disease.¹¹ In the cyst form, *Acanthamoeba* can endure the nutrient deficient environment, such as that seen in keratitis, and cause corneal and scleral inflammation.⁶ The encasement of *Acanthamoeba* in the cyst form requires that treatment include cysticidal drugs.⁶ The life cycle of *Acanthamoeba* is also related to the clinical presentation. The amoeba initially travels circumferentially through the epithelium, moving relatively quickly compared to other cells, resulting in an epitheliopathy. Initial signs of infection consist of a punctate keratopathy, pseudodendrites, and perineural infiltrates due to the amoeba's predilection for gathering around nerves.⁶ In later disease, the amoeba travels slowly through deeper layers of the cornea, resulting in ring infiltrates and deep corneal ulcers, as well as secondary anterior uveitis, and hypopyon. *Acanthamoeba* keratitis is a great masquerader and may present similarly to keratitis of fungal or herpetic etiology.³

Our first case had the number one risk factor of *Acanthamoeba* keratitis - contact lens use, along with several other risk factors identified to be associated with worse outcomes. These risk factors included older age, the presence of a stromal ring infiltrate, corticosteroid use and *Herpes simplex* keratitis treatment prior to anti-amoebic therapy.⁴ The clinical course of our patient, which involved aggressive medical therapy and surgical intervention, was made more complex due to the delayed diagnosis and prolonged use of corticosteroids aiding in the proliferation of trophozoites. This led to *Acanthamoeba* penetration into the corneal stroma, making successful therapy more difficult and resulting in chronic disease.^{3,4}

Our second patient who was also a contact lens wearer, was similarly misdiagnosed with *Herpes simplex* keratitis. A detailed history revealed exposure to well water and use of tap water to clean his lenses, which led to the work-up that confirmed *Acanthamoeba* keratitis. On initial presentation, he did not present with the classic findings of pain out of proportion to the physical exam or a ring infiltrate, often associated with *Acanthamoeba* keratitis.³ The variable presentation of *Acanthamoeba* keratitis highlights the need to culture for *Acanthamoeba* in any atypical keratitis in the setting of contact lens use. In both cases, the patients had delayed diagnoses, demonstrating that *Acanthamoeba* keratitis remains commonly misdiagnosed despite awareness of its severity and predilection for contact lens wearers.

Previous case studies on *Acanthamoeba* keratitis have discussed contact lens use and the value of early diagnosis on prognosis. Yet despite the abundant literature on *Acanthamoeba* keratitis, the diagnosis is often delayed. Our case series is an example of the potential for initial misdiagnosis leading to less than optimal management and in the first patient, a permanent loss of vision. The management of these cases provide valuable insight into important considerations for the diagnosis and management of *Acanthamoeba* keratitis. These include the need to culture for *Acanthamoeba* in any patient with a history of contact lens wear presenting with an atypical keratitis and before making a presumed diagnosis of *Herpes simplex* keratitis. A valuable diagnostic and management approach to patients presenting with a keratitis of unknown etiology would be to perform confocal microscopy, stop prior antimicrobials and topical steroids and culture to identify the organism. It also highlights the varied presentations of *Acanthamoeba* keratitis, which can present early on as a diffuse epitheliopathy. Finally, topical steroids should be used with caution before a diagnosis is made, as steroids can aid in the proliferation of trophozoites, possibly contributing to worsening and/or prolongation of disease.

5. Conclusions

This report highlights the importance of early diagnosis and high potential for misdiagnosis in cases of *Acanthamoeba* keratitis. The slow progression and clinical picture similar to that of other infectious agents may predispose patients to delayed presentation and treatment. This may further complicate the treatment of *Acanthamoeba* keratitis and put patients at risk of worse outcomes. Thus, clinicians should maintain a high index of suspicion for *Acanthamoeba* keratitis in contact lens wearers presenting with corneal infection and should consider culturing for *Acanthamoeba* before making a diagnosis of *Herpes simplex*.

Patient consent

Consent to publish the case report was not obtained. This report does not contain any personal information that could lead to the identification of the patient.

Funding

No funding or grant support.

Authorship

The authors attest that they meet the current ICMJE criteria for Authorship.

Declaration of competing interest

The authors have no financial disclosures.

Acknowledgements

None.

References

- Bacon AS, Frazer DG, Dart JKG, Matheson M, Ficker LA, Wright P. A review of 72 consecutive cases of *Acanthamoeba* keratitis, 1984–1992. *Eye*. 1993;7(6):719–725.
- Bouheraoua N, Gaujoux T, Goldschmidt P, Chaumeil C, Laroche L, Borderie VM. Prognostic factors associated with the need for surgical treatments in *Acanthamoeba* keratitis. *Cornea*. 2013;32(2):130–136.
- Lorenzo-Morales J, Khan NA, Walochnik J. An update on *Acanthamoeba* keratitis: diagnosis, pathogenesis and treatment. *Parasite*. 2015;22:10.
- Carnt N, Robaei D, Minassian DC, Dart JKG. *Acanthamoeba* keratitis in 194 patients: risk factors for bad outcomes and severe inflammatory complications. *Br J Ophthalmol*. 2018;102(10):1431–1435.

5. Roozbahani M, Hammersmith KM, Rapuano CJ, Nagra PK, Zhang Q, Siu SY. Acanthamoeba keratitis: are recent cases more severe? *Cornea*. 2018;37(11):1381–1387.
6. Dart JKG, Saw VPJ, Kilvington S. Acanthamoeba keratitis: diagnosis and treatment update 2009. *Am J Ophthalmol*. 2009;148(4):487–499.e2.
7. Claerhout I, Goegebuer A, Van Den Broecke C, Kestelyn P. Delay in diagnosis and outcome of Acanthamoeba keratitis. *Graefes Arch Clin Exp Ophthalmol*. 2004;242(8):648–653.
8. Bacon AS, Dart JKG, Ficker LA, Matheson MM, Wright P. Acanthamoeba keratitis: the value of early diagnosis. *Ophthalmology*. 1993;100(8):1238–1243.
9. Brown AC, Ross J, Jones DB, et al. Risk factors for Acanthamoeba keratitis—a multistate case-control study, 2008–2011. *Eye Contact Lens*. 2018;44(Suppl 1):S173–S178.
10. Seal DV. Acanthamoeba keratitis update—incidence, molecular epidemiology and new drugs for treatment. *Eye*. 2003;17(8):893–905.
11. Siddiqui R, Khan N. Biology and pathogenesis of Acanthamoeba. *Parasites Vectors*. 2012;5(1):6.
12. Weisman RA. Differentiation in Acanthamoeba castellanii. *Annu Rev Microbiol*. 1976;30(1):189–219.