

## Case Report

## Emergency stabilisation by single-stage posterior transpedicular approach for treatment of unstable lumbar spine fracture with neurological injury

Joaquin Alfaro-Micó<sup>a,\*</sup>, José Ramirez-Villaescusa<sup>a</sup>, Maria Dolores Martinez-Lozano<sup>b</sup>, Rosa Maria Sanchez-Honrubia<sup>c</sup>, David Ruiz-Picazo<sup>a</sup>

<sup>a</sup> Department of Orthopaedic, Spine Surgery Unit, Complejo Hospitalario Universitario de Albacete, Albacete, Spain

<sup>b</sup> Department of Neurology, Associated Teacher Neurology (UJI), Hospital General de Castellón, Castellón, Spain

<sup>c</sup> Department of Neurophysiology, Complejo Hospitalario Universitario de Albacete, Albacete, Spain

## ARTICLE INFO

## Keywords:

Lumbar spine fracture  
Neurological injury  
Emergency surgical treatment  
Transpedicular decompression

## ABSTRACT

Management of unstable thoracolumbar fractures remains controversial. Furthermore, when these are accompanied by related neurological injury, the choice of approach, decompression technique and timing of the intervention could have a neuroprotective effect. In terms of site, the lumbar spine represents only 1.2% of cases, yet fractures with severe instability and neurological injury call for attainment of the same goals, i.e., neurological stability and decompression.

After suffering high-energy trauma as a result of an accidental fall, a young male patient presenting with unstable injury of the lumbar spine and neurological impairment compatible with incomplete cauda equina syndrome was treated with emergency stabilisation and decompression through single-stage posterior transpedicular approach. At one year of the intervention, the patient is making good progress, with absence of lumbar pain, isolated deficit in left ankle dorsiflexion with no need of orthosis or cane, adequate sphincter control and return to his previous activity.

Patients who present with unstable injury of the lumbar spine and incomplete neurological involvement can benefit from emergency stabilisation and decompression treatment by posterior transpedicular approach, with improvement in neurological status and functional recovery.

## Introduction

Management of thoracolumbar vertebral fractures remains controversial. The morphological pattern, injury of the posterior ligamentous complex and neurological impairment will guide our treatment decision [1].

In cases where there is neurological injury, the choice of approach, decompression technique and timing of the intervention could have a neuroprotective effect in respect of secondary ischaemic spinal cord injury. Posterior, anterior or combined approaches and stabilisation techniques vary according to the morphological pattern and site of the injury [2]. Direct or indirect anterior decompression via posterior approach has been proposed as a neural element release technique. In the presence of a three-column injury, however, the posterior approach simultaneously allows for posterior stabilisation and decompression by the posterior transpedicular

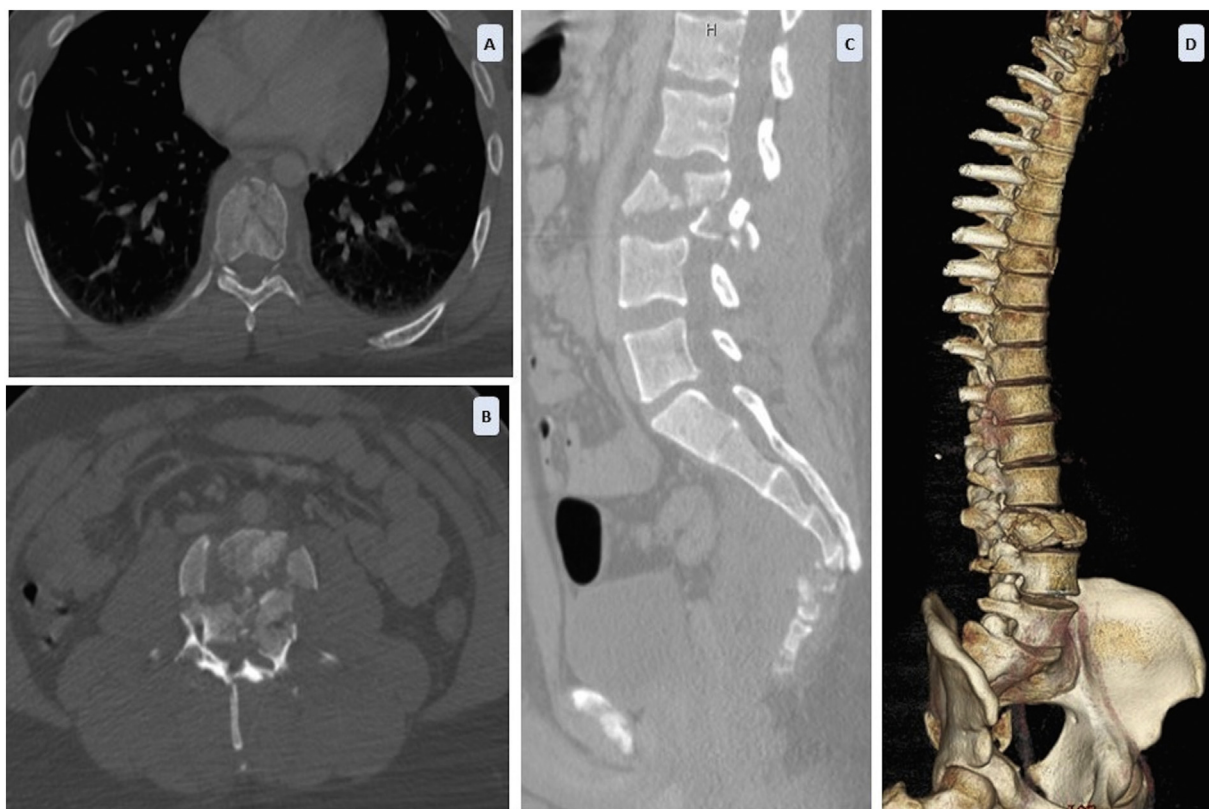
\* Corresponding author at: Complejo Hospitalario Universitario de Albacete, Servicio de Cirugía Ortopédica y Traumatología, Hermanos Falcó 37, 02006, Albacete, Spain.

E-mail address: [jamico@sescam.jccm.es](mailto:jamico@sescam.jccm.es) (J. Alfaro-Micó).

<https://doi.org/10.1016/j.tcr.2020.100300>

Accepted 6 April 2020

2352-6440/ © 2020 The Authors. Published by Elsevier Ltd. This is an open access article under the CC BY-NC-ND license (<http://creativecommons.org/licenses/by-nc-nd/4.0/>).



**Fig. 1.** Preoperative CT scans. (A) Axial view of stable compression fracture of T8. (B) Axial view of polyfragmentary fracture of L3 with > 70% canal occupation. (C) Sagittal view of lumbar spine with loss of height of L3, lumbar kyphosis, severe injury, osseous elements and posterior ligamentous complex. Fracture of S5 and kyphosis sacro-coccyx (D) Sagittal view of 3D reconstruction.

approach (TPA) [3], thus avoiding the morbidity of the double approach. Moreover, the timing of the intervention is controversial in cases where there is neurological injury.

Although lumbar spine fractures represent only 1.2% of all traumatic thoracolumbar injuries [4] and have a better prognosis of functional recovery, when there is severe mechanical instability and neurological impairment, the same principles of decompression and stabilisation should be applied. Emergency treatment with decompression and early stabilisation could improve long-term neurological status and functional outcome.

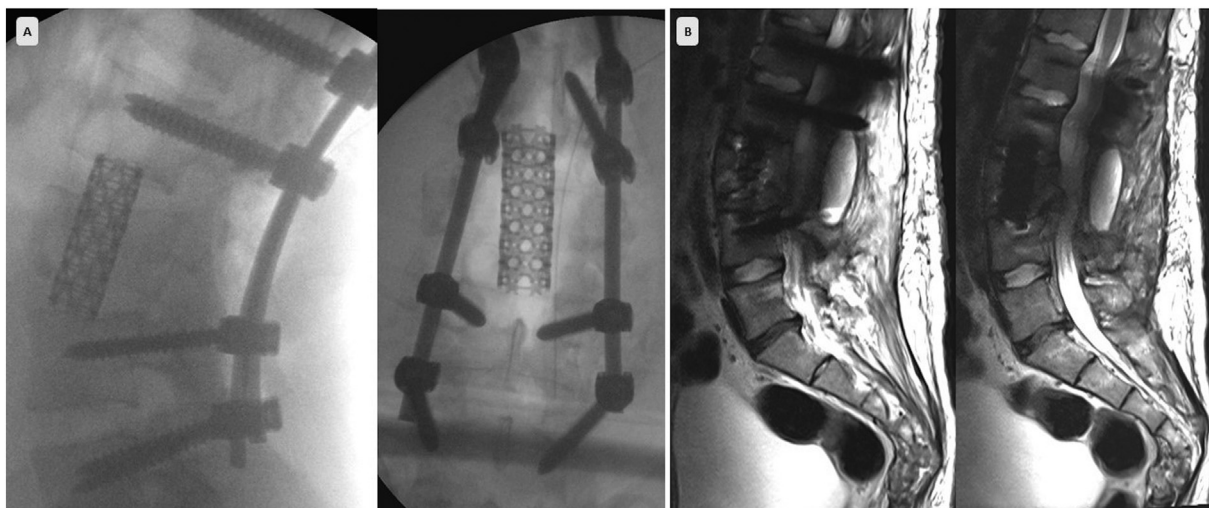
We report the case of a young patient presenting with unstable injury of the lumbar spine and neurological injury after suffering high-energy trauma, treated with emergency decompression and stabilisation via single-stage posterior TPA.

### Clinical case

A 23-year-old male, received by the emergency ward after experiencing an accidental fall from the fourth floor, was conscious on arrival, co-operative and somewhat confused (Glasgow14). On initial examination, he complained of lumbar pain and loss of strength in the lower limbs, with evidence of distal flaccid paralysis in lower limbs, thermoalgesic and proprioceptive hypoesthesia below level L2, and absence of anal and bulbocavernosus reflexes, with osteotendinous reflexes present and bilateral flexor cutaneous-plantar reflex.

The computed tomography (CT) scan showed multifragmentary fracture of the L3 body, middle column injury with occupation of 70% of the medullary canal, and injury of the complete ligamentous complex (Type C translation injury, according to the AOSpine Classification System). In addition, stable compression fracture of T8 and polyfragmentary fracture of S5 and coccyx were also in evidence (Fig. 1). The findings were compatible with incomplete cauda equina syndrome (CES).

At 4 h of the injury, an emergency surgical intervention was decided. Under general anaesthesia and antibiotic prophylaxis, with the patient in prone decubitus position and the lower limbs extended to maximise lumbar lordosis, a posterior approach of the lumbar spine was performed. We found which confirmed a complete tear of the L3-L4 and L4-L5 ligamentous complex, laceration of dura mater, and partial injury of lumbar spine nerve roots. Reconstruction of the posterior tension band, with bilateral pedicle screw fixation at L1-L2 and L4-L5 and posterolateral arthrodesis with autologous bone were performed. Direct decompression of the L3 body was achieved by means of left TPA and reconstruction of the anterior column, by placement of titanium mesh cage with autologous bone graft obtained from the surgical field (Fig. 2). Due to the severity of the injury of the dura mater, this was



**Fig. 2.** (A) Following screws were put two-levels up and below the L3, inferior L2/L3 and superior L3 facets were resected surrounding left L3 pedicle. The discs L2-L3 and L3-L4 were excised and through L3 left pedicle, the vertebral body L3 bone fragments were removed. Reconstruction was performed by insertion of titanium mesh filled with autologous bone from surgical field. First the mesh was introduced obliquely above the L3 root and then rotated in the intersomatic space. After the cage was placed and its positioned was confirmed by lateral and antero-posterior x-rays, compression was applied. Intraoperative views with appropriate position of implants and titanium cage in coronal and sagittal planes with recovery of lumbar lordosis. (B) Views in sagittal magnetic resonance (MR) projection of T1 and T2 sequences at three months post-operation with adequate decompression of neural elements. Picture compatible with encapsulated remnant cerebrospinal fluid due to initial dural tear.

reconstructed by suture and ovine patch graft. It was an urgent procedure, so intraoperative neuromonitoring wasn't available. The duration of the intervention was 5 h.

The patient made favourable progress after the intervention with progressive improvement in motor and sensory function, though he required intermittent bladder catheterisation for a few months. The postoperative MR scan showed evidence of adequate decompression of neural elements (Fig. 2).

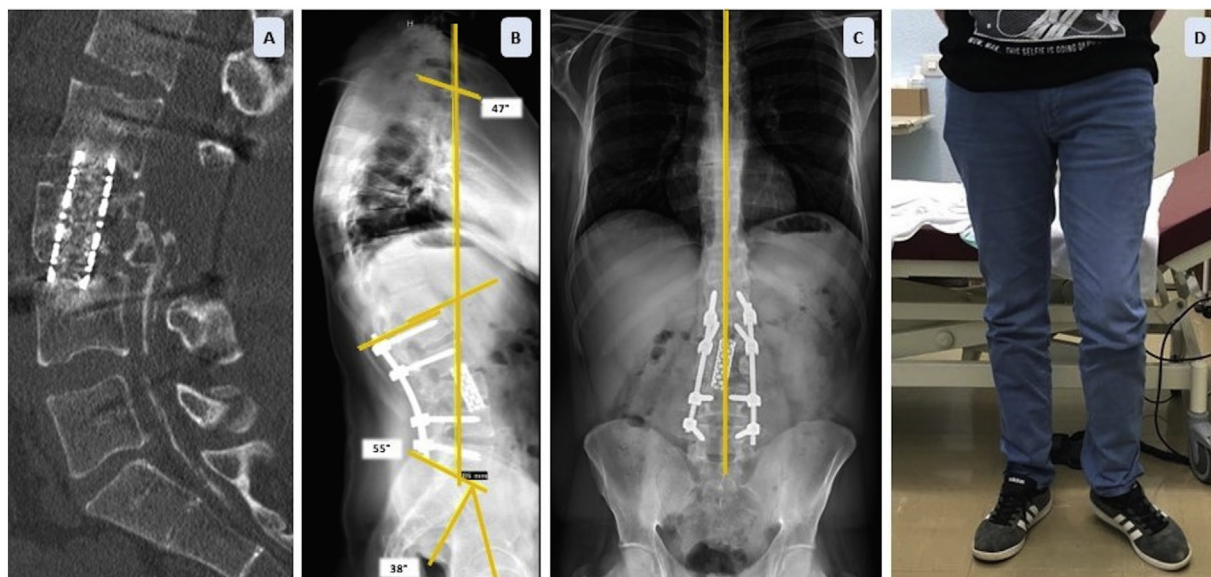
At 18 months of the intervention, the patient had recovered muscle strength at all levels, except for active dorsiflexion of the left ankle due to severe left L4 root damage, which was tolerated without need of a cane or ankle-foot orthosis for walking. He required no analgesia and had returned to his previous activity. Bladder and anal sphincter function were preserved, without need of catheterisation. The neurophysiological study showed chronic bilateral polyradiculopathy with moderate-severe bilateral involvement at L3-L4, right-sided involvement at L5 bilateral asymmetric involvement at S1-S2 and very severe left-sided involvement at L5. The radiological study performed at one year of the intervention showed maintenance of adequate sagittal and coronal axis, as well as lumbar lordosis proportional to pelvic incidence. CT study didn't show loosening of implants, and there were signs of bony bridging across the cage, which were compatible with solid osseous fusion (Fig. 3).

## Discussion

Most spinal fractures are located in the thoracolumbar region, due to the transition of rigid thoracic kyphosis to mobile lumbar lordosis, the change in facet orientation from coronal to sagittal, and the posterior load-bearing axis in the lumbar region versus the anterior load-bearing axis in the thoracolumbar spine. L3-L5 fractures of the lumbar spine are rare and account for 1.2% of vertebral fractures and 2.2% of thoracolumbar fractures [4]. Neurological injury is also more frequent in the thoracic and thoracolumbar spine versus the lumbar spine, due to the fact that the medullary cone ends at L2, the smaller diameter of the spinal canal, and precarious vascularisation. Moreover, functional prognosis was reported to be better in radicular than in spinal cord injuries [5].

One of the principles of surgical treatment is to stabilise the spine with the inclusion of the minimum number of segments, particularly in the case of lumbar mobile segments. In unstable burst, flexion-distraction and rotational injuries, short or long pedicle screw instrumentation has been described as standard treatment. If neurological injury is also present, decompression of neural elements can be performed indirectly by means of the posterior approach, directly by means of the anterior or posterior transpedicular approach, and combined by means of the double approach. However, any technique has shown itself to be superior to any other in terms of neurological recovery [6]. Although similar results have been described in lumbar fractures with surgical or conservative treatment [7], in patients with injury of the three columns, reconstruction of the posterior tension band and anterior spine is required.

In this case, a high degree of instability was observed due to the rupture of the posterior ligamentous complex into two contiguous segments, which required long-segment fixation with the inclusion of three segments to increase mechanical stability and prevent subsequent failure. Decompression of the anterior spine was carried out in the same surgical procedure via transpedicular, in order to prevent the morbidity of the anterior approach in a second procedure, though the need for preservation of lumbar spine nerve roots



**Fig. 3.** (A) Sagittal CT view at one year of the intervention. Appropriate position of the titanium cage and bony bridging across the cage were compatible with solid osseous fusion and preservation of lumbar lordosis. (B–C) The radiological study in upright position show adequate sagittal and coronal balance. The lumbar lordosis is proportional to pelvic incidence. (D) View of patient at one year in upright position. Extension deficit of left ankle persists but no cane or orthosis required for walking.

may render the technique difficult. Reconstruction of the anterior spine by placement of a titanium cage via posterior approach has been shown to be effective and useful for preventing complications such as late kyphosis or subsequent instrumentation failure with breakage of implants [8]. Furthermore, repair of the dural sac requires the use of suture or, where the rupture is irreparable, as in the case of our patient, the use of a dural graft to prevent postoperative complications such as infections or dural leaks.

Although intraoperative neuromonitoring modalities (somatosensory-evoked potentials and transcranial electric motor-evoked potentials) efficacy has been proved to prevent postoperative neurological deficit in tumour and deformity surgery, the daily use of spontaneous or triggered electromyography in lumbar spine surgery hasn't been well established to detect radicular injury or pedicular screw misplacement [9].

The advantages of surgical treatment with stabilisation and decompression are evident in injuries with a high degree of instability. Although the timing of the intervention remains controversial in terms of neurological recovery, emergency decompression could prevent secondary injury particularly in incomplete injuries [10,11].

## Conclusion

Patients who present with unstable injury of the lumbar spine and incomplete neurological involvement can benefit from emergency stabilisation and decompression treatment by posterior TPA, with improvement in neurological status and functional recovery.

## Founding resources

This research did not receive any specific grant from funding agencies in the public, commercial, or not-for-profit sectors.

## Declaration of competing interest

None.

## References

- [1] A.R. Vaccaro, C. Oner, C.K. Kepler, M. Dvorak, K. Schnake, C. Bellabarba, et al., AOSpine thoracolumbar spine injury classification system: fracture description, neurological status, and key modifiers, *Spine* 1 (38 (23)) (2013) 2028–2037, <https://doi.org/10.1097/BRS.0b013e3182a8a381>.
- [2] A.R. Vaccaro, M.R. Lim, R.J. Hurlbert, R.A. Lehman, J. Harrop, D.C. Fisher, et al., Surgical decision making for unstable thoracolumbar spine injuries: results of a consensus panel review by the Spine Trauma Study Group, *J. Spinal Disord. Tech.* 19 (1) (2006) 1–10, <https://doi.org/10.1097/01.bsd.0000180080.59559.45>.
- [3] R.H. Patterson, E. Arbit, A surgical approach through the pedicle to protruded thoracic discs, *J. Neurosurg.* 48 (1978) 768–772.
- [4] C.A. Finn, E.S. Stauffer, Burst fracture of the fifth lumbar vertebra, *J. Bone Joint Surg. Am.* 74 (3) (1992) 398–403.
- [5] J.S. Harrop, S. Naroji, M.G. Maltenfort, J.K. Ratliff, S.I. Tjoumakaris, B. Frank, et al., Neurologic improvement after thoracic, thoracolumbar, and lumbar spinal cord (conus medullaris) injuries, *Spine* 1 (36(1)) (2011) 21–25, <https://doi.org/10.1097/BRS.0b013e3181fd6b36>.

- [6] F.C. Oner, K.B. Wood, J.S. Smith, C.I. Shaffrey, Therapeutic decision making in thoracolumbar spine trauma, *Spine* 1; 35 (21 Suppl) (2010) S235–S244, <https://doi.org/10.1097/BRS.0b013e3181f32734>.
- [7] D.A. Andreychik, D.H. Alander, K.M. Senica, E.S. Stauffer, Burst fractures of the second through fifth lumbar vertebrae: clinical and radiographic results, *J. Bone Joint Surg. Am.* 78 (8) (1996) 1156–1166.
- [8] M. Sasani, A.F. Özer, Single-stage posterior corpectomy and expandable cage placement for treatment of thoracic or lumbar burst fractures, *Spine* 34 (1) (2009) E33–E40, <https://doi.org/10.1097/BRS.0b013e318189fcfd>.
- [9] R.M. Ajiboye, S.D. Zoller, A. D'Oro, Z.D. Burke, W. Sheppard, C. Wang, et al., Utility of intraoperative neuromonitoring for lumbar pedicle screw placement is questionable, *Spine* 42 (2017) 1006–1010, <https://doi.org/10.1097/BRS.0000000000001980>.
- [10] M.G. Fehlings, A. Vaccaro, J.R. Wilson, A. Singh, W. Cadotte, J.S. Harrop, et al., Early versus delayed decompression for traumatic cervical spinal cord injury: results of the surgical timing in acute spinal cord injury study (STASCIS), *PLoS One* 23; 7 (2) (2012) e32037, , <https://doi.org/10.1371/journal.pone.0032037>.
- [11] J. Ramírez-Villaescusa, J. López-Torres Hidalgo, D. Ruiz-Picazo, A. Martín-Benlloch, P. Torres-Lozano, E. Portero-Martinez, The impact of urgent intervention on the neurologic recovery in patients with thoracolumbar fractures, *J Spine Surg Hong Kong* 4 (2) (2018) 388–396, <https://doi.org/10.21037/jss.2018.06.07>.