



## Case Report

# Experience using a portable X-ray system at the scene transported by a physician-staffed helicopter

Kazuhiko Omori, Youichi Yanagawa,  Ken-ichi Muramatsu, Hiroki Nagasawa,   
Ikuto Takeuchi, Shunsuke Madokoro, Kei Jitsuiki, Shoichiro Yatsu, Hiromichi Ohsaka, and  
Kouhei Ishikawa 

Department of Acute Critical Care Medicine, Shizuoka Hospital, Juntendo University, Shizuoka, Japan

**Background:** Fujifilm (Tokyo, Japan) developed a portable X-ray system called the CALNEO Xair, which can be carried by a physician. The X-ray radiation machine weighs 3.5 kg. The dimensions are: height, 144 mm; length, 148 mm; width, 258 mm.

**Case Presentation:** When a 33-year-old woman driving a car made a right turn at a crossroad, her car hit another car, causing her vehicle to tip onto its side. Staff of the doctor helicopter checked her at the scene, and the findings of chest and pelvic X-ray were all negative. She received a diagnosis of cervical sprain and pelvic contusion and was transferred to a local hospital by ambulance.

**Conclusion:** This is the first report of a case evaluated by a portable X-ray system at the scene, under transportation by a doctor helicopter. This system could be useful for undertaking prehospital assessment and medical treatment.

**Key words:** Physician staffed helicopter, portable X-ray, prehospital

## INTRODUCTION

X-RAY IRRADIATION IS used daily in medical facilities to diagnose bone-related diseases, including fractures, lung disease, heart disease, perforation of bowel, ileus, stone, or foreign body in the human body.

Fujifilm (Tokyo, Japan) have developed a portable X-ray system called the CALNEO Xair.<sup>1</sup> The X-ray radiation machine weighs 3.5 kg. The dimensions are: height, 144 mm; length, 148 mm; width 258 mm, without the skin guard or hand strap. The X-ray dose for the chest is approximately 45  $\mu$ Gy. The system requires a special cassette and notebook-type personal computer to operate and display X-ray images (Fig. 1). The physician can check the image on the computer display at the scene, which is transmitted by electrical wave after the X-ray examination (Fig. 2). If

charged, the X-ray unit can obtain X-ray images without a generator. Accordingly, the battery of the X-ray unit needs to be charged with specific chargers before use in the prehospital setting. Special cars have already been equipped with X-ray instruments in order to undertake medical check-ups outside of medical facilities.<sup>2–5</sup> However, there have been no reports of X-ray studies using portable X-ray systems under transportation by a physician-staffed helicopter in a prehospital setting. Our hospital is a base of the physician-staffed helicopter (called a doctor helicopter [DH] in Japan) of eastern Shizuoka Prefecture.<sup>6</sup>

We herein report our experience using a portable X-ray system at the scene under transportation by the DH.

## CASE

WHEN A 33-YEAR-OLD woman driving a car made a right turn at a crossroad, her car hit another car, causing her vehicle to tip onto its side. She had no remarkable medical history. The fire department dispatched an ambulance and requested the DH be dispatched after receiving an emergency call. After the DH equipped with the portable X-ray system landed at the rendezvous zone, the staff were sent by fire truck to the accident scene. When the staff of the DH checked the patient at the scene, her vital signs were as follows: Glasgow Coma Scale, E4V5M6; systolic

**Corresponding:** Youichi Yanagawa, MD, PhD, Juntendo University, 1129 Nagaoka, Izunokuni City, Shizuoka, Japan 410-2295. E-mail: [yyanaga@juntendo.ac.jp](mailto:yyanaga@juntendo.ac.jp).


Received 28 Jan, 2019; accepted 25 Apr, 2019; online publication 23 May, 2019

### Funding information

This article received financial support from the Ministry of Education, Culture, Sports, Science and Technology (MEXT) – Supported Program for the Strategic Research Foundation at Private Universities, 2015–2019.



**Fig. 1.** CALNEO Xair portable X-ray system, developed by Fuji-film (Tokyo, Japan), being carried by a nurse. (1) X-ray radiating apparatus. (2) Special cassette. (3) Notebook-type personal computer.



**Fig. 2.** Photograph showing how to take an X-ray and check the image using the CALNEO Xair portable X-ray system (Fuji-film, Tokyo, Japan). The image captured by the X-ray radiation machine is transmitted to notebook-type personal computer by electrical wave. (1) X-ray radiating apparatus. (2) Special cassette. (3) Notebook-type personal computer.

blood pressure, 110/66 mmHg; pulse rate, 77 b.p.m.; percutaneous oxygen saturation, 100% under room air; respiratory rate, 20 breaths/min. She had mild posterior neck tenderness and pelvic tenderness with a seat belt mark. The findings of a focused assessment with sonography for trauma, chest X-ray, and pelvic X-ray in the ambulance, after the patient verbally confirmed that she was not pregnant, were all negative (Fig. 3). She received a diagnosis of cervical sprain and pelvic contusion and was transferred to a local hospital by

ambulance staffed only with emergency medical technicians.

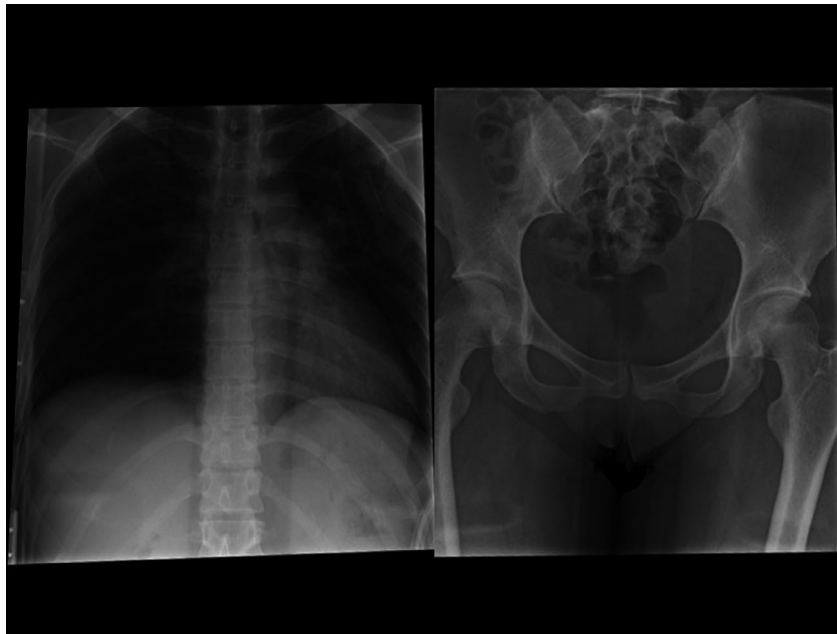
## DISCUSSION

**T**HIS IS THE first report of a case evaluated by a portable X-ray system at the scene, under transportation by a DH.

Japan's Ground Self Defense Force has access to an X-ray apparatus for use outside of a hospital environment.<sup>7</sup> Although this system has been successfully used in large-scale disaster settings, it is not used during times of peace. In addition, the X-ray apparatus used by the Ground Self Defense Force is extremely large and heavy, so much so that it cannot be transported by a single person or loaded into an ambulance or helicopter. In contrast, the portable X-ray system used in the present study can be used at any time and is easy to carry by a single medical staff member. In addition, the information obtained from the X-ray study is useful for making a diagnosis, deciding on the severity of trauma or disease, judging the accuracy of the positioning of medical instruments (e.g., tracheal intubation), and selecting the most appropriate medical facility to which to transport a patient from the scene. Furthermore, the prehospital information obtained from an X-ray study can facilitate the formulation of an appropriate treatment plan by the medical staff at the receiving hospital. This portable X-ray system could thus be useful for adapting prehospital medical treatment and developing new therapeutic strategies in the future.

The use of a portable X-ray unit weighing 90 kg, which required an electric generator, in the in-nursing home care field in Sweden has already been described in one report.<sup>8,9</sup> Mobile radiography services for the radiological assessment of patients in nursing homes have been shown to be technically feasible, with better image quality, and beneficial factors such as the security and comfort of patients, the fact that patients do not require transportation, and the fact that staff do not need to be absent from the nursing home to accompany patients. The X-ray unit in the present study has also been applied in home medical care. If patients are judged as severely ill, they require early medical intervention and transportation. Carrying the X-ray unit in the DH allows the patient to be diagnosed immediately, and facilitates the provision of first aid by the physician and nurse, and rapid transportation if necessary.

With regard to comparing the accuracy and effectiveness of the portable X-ray unit to a conventional X-ray system, this was the first time this Fujifilm X-ray unit had been used; thus, there were no comparative data. In a previous report to investigate the clinical effectiveness of portable X-ray imaging equipment in comparison to fixed X-ray equipment, a



**Fig. 3.** Chest and pelvic X-ray images, captured by doctor helicopter staff using the CALNEO Xair portable X-ray system (Fujifilm, Tokyo, Japan), in the case of a 33-year-old woman involved in a motor vehicle accident. The two X-rays do not show specific findings.

search of published works yielded no studies comparing their clinical effectiveness or cost effectiveness.<sup>8</sup> Furthermore, the search did not identify any guidelines on the use of portable X-ray systems.<sup>8</sup> In the trauma setting, portable ultrasound machines are a new effective and sensitive tool for evaluating chest trauma, such as cardiac tamponade, pneumothorax, hemothorax, or even rib fracture.<sup>10,11</sup> However, ultrasound is a point-of-care system and is not suitable for diagnosing abnormalities in the entire chest structure, such as the volume of pneumothorax, the number of rib fractures, mediastinal abnormality, or the position of foreign bodies, including iatrogenic foreign bodies. In pelvic fracture, palpation of the pelvis can detect pelvic fracture, but it cannot suggest whether the fracture is stable or unstable.<sup>12</sup> Furthermore, such manipulation could increase bleeding from the fracture site. Accordingly, the portable X-ray remains a valuable diagnostic tool.

Limitations associated with the portable X-ray system include the quality of the X-ray image when the system is operated by medical staff who are not radiologists, the lack of water resistance by the X-ray radiating apparatus, and the cassette potentially not working well at low temperatures. All of the X-ray pictures in the present study were obtained by physicians. Accordingly, in order to take X-rays effectively, it might be better to increase the number of DH staff members in order to shorten the time on site.

In addition, similar to a standard X-ray system, the manipulator needs to be protected from radiation, even though the portable X-ray unit involves less radiation. Alternatively, if the portable X-ray system can be set on a specific frame, the manipulator can leave the patient and trigger the system using a button connected to a cable; however, it takes time to set up the frame in the emergency setting. Furthermore, we failed to find any improvement of the patient's final outcomes using this system. Therefore, after the further development of this system, future studies will need to assess its utility.

## CONCLUSION

**T**HIS IS THE first report of a case evaluated using a portable X-ray system at the scene, under transportation by a DH. This system could be useful for undertaking prehospital assessment and medical treatment.

## ACKNOWLEDGEMENTS

**T**HIS ARTICLE RECEIVED financial support from the Ministry of Education, Culture, Sports, Science and Technology (MEXT)-Supported Program for the Strategic Research Foundation at Private Universities, 2015–2019 concerning [The constitution of total researching system for comprehensive disaster, medical management, corresponding to wide-scale disaster].

## DISCLOSURE

Approval of the research protocol: The protocol of this retrospective study was approved by the review board of Shizuoka Hospital, Juntendo University. No. 298.

Informed consent: N/A.

Registry and the registration no. of the study/trial: N/A.

Animal studies: N/A.

Conflict of interest: The all authors declare no conflicts of interest in association with this study.

## REFERENCES

- 1 FUJIFILM Inc. [homepage on the internet]. Tokyo: Fujifilm CALNEO Xair Portable X-ray Unit [updated Oct 2018; cited 24 Apr 2019]. Available from: <https://www.fujifilm.com/news/n181031.html>.
- 2 Hazell TJ, Vanstone CA, Rodd CJ, Rauch F, Weiler HA. Bone mineral density measured by a portable X-ray device agrees with dual-energy X-ray absorptiometry at forearm in preschool aged children. *J. Clin. Densitom.* 2013; 16: 302–7.
- 3 Moger TA, Bjørnelv GM, Aas E. Expected 10-year treatment cost of breast cancer detected within and outside a public screening program in Norway. *Eur. J. Health Econ.* 2016; 17: 745–54.
- 4 Ebinger M, Fiebach JB, Audebert HJ. Mobile computed tomography: prehospital diagnosis and treatment of stroke. *Curr. Opin. Neurol.* 2015; 28: 4–9.
- 5 Shuaib A, Khan K, Whittaker T, Amlani S, Crumley P. Introduction of portable computed tomography scanners, in the treatment of acute stroke patients via telemedicine in remote communities. *Int. J. Stroke* 2010; 5: 62–6.
- 6 Omori K, Ohsaka H, Ishikawa K *et al.* Introduction of a physician-staffed helicopter emergency medical service in eastern Shizuoka prefecture in Japan. *Air Med. J.* 2014; 33: 292–5.
- 7 Yanagawa Y, Muta S, Goto Y *et al.* Introduction of Self Defense Force Japan. Cooperation between fire department and Self Defense Force Japan in huge disaster. *J. Jpn Soc. Emerg. Med.* 2009; 12: 473–7 (In Japanese).
- 8 Portable versus fixed X-ray equipment: a review of the clinical effectiveness, cost-effectiveness, and guidelines [Internet]. Ottawa, ON: Canadian Agency for Drugs and Technologies in Health; [cited 22 Feb 2016]. Available from: <https://www.ncbi.nlm.nih.gov/books/NBK350588/>.
- 9 Eklund K, Klefsgard R, Ivarsson B, Geijer M. Positive experience of a mobile radiography service in nursing homes. *Gerontology* 2012; 58: 107–11.
- 10 Battle C, Hayward S, Eggert S, Evans PA. Comparison of the use of lung ultrasound and chest radiography in the diagnosis of rib fractures: a systematic review. *Emerg. Med. J.* 2019; 36: 185–90.
- 11 Kirkpatrick AW, Ng AK, Dulchavsky SA *et al.* Sonographic diagnosis of a pneumothorax inapparent on plain radiography: confirmation by computed tomography. *J. Trauma* 2001; 50: 750–2.
- 12 Nagasawa H, Omori K, Takeuchi I *et al.* Accuracy of the prehospital diagnosis of pelvic fractures diagnosed by traumatic PAN scans. *Sch. J. Appl. Med. Sci.* 2017; 5: 4252–6.