



Since January 2020 Elsevier has created a COVID-19 resource centre with free information in English and Mandarin on the novel coronavirus COVID-19. The COVID-19 resource centre is hosted on Elsevier Connect, the company's public news and information website.

Elsevier hereby grants permission to make all its COVID-19-related research that is available on the COVID-19 resource centre - including this research content - immediately available in PubMed Central and other publicly funded repositories, such as the WHO COVID database with rights for unrestricted research re-use and analyses in any form or by any means with acknowledgement of the original source. These permissions are granted for free by Elsevier for as long as the COVID-19 resource centre remains active.



Diagnostic utility of a direct immunofluorescence test to detect feline coronavirus antigen in macrophages in effusive feline infectious peritonitis



A.L. Litster^{a,*}, R. Pogranichniy^b, T.-L. Lin^b

^aPurdue University College of Veterinary Medicine, 625 Harrison Street, West Lafayette, IN 47907, USA

^bIndiana Animal Disease Diagnostic Laboratory, Department of Comparative Pathobiology, Purdue University, West Lafayette, IN 47907, USA

ARTICLE INFO

Article history:

Accepted 22 August 2013

Keywords:

Feline coronavirus
Feline infectious peritonitis
Direct immunofluorescence test
Macrophages

ABSTRACT

The antemortem diagnosis of feline infectious peritonitis (FIP) remains challenging in clinical practice, since current testing methods have suboptimal diagnostic accuracy. Immunohistochemical testing of biopsy specimens and postmortem examination are the standard diagnostic methods, although direct immunofluorescence (DIF) testing to detect feline coronavirus in macrophages in effusion specimens has been reported to have 100% specificity and has been recommended as an antemortem confirmatory test. The aim of this study was to compare the results of DIF testing in antemortem feline effusions with postmortem results using field samples. Effusion specimens were collected antemortem from 17 cats and tested by DIF, followed by postmortem examination. Histopathological examination of specimens collected at postmortem confirmed FIP in 10/17 cases and ruled out FIP out in 7/17 cases. Antemortem DIF testing was positive in all 10 cases confirmed as FIP at postmortem examination. In the seven cats where FIP was ruled out at postmortem examination, DIF was negative in five cases and positive in the remaining two cases. The calculated sensitivity of DIF testing was 100% and the specificity was 71.4%. Duplicate effusion specimens from eight cats that were initially DIF positive were stored refrigerated (4 °C) or at room temperature (22–25 °C) and subjected to serial DIF testing to determine the duration of positive results. DIF-positive specimens stored at both temperatures retained their positive status for at least 2 days.

© 2013 Elsevier Ltd. All rights reserved.

Introduction

Feline infectious peritonitis (FIP) is a common disease in cats caused by a virulent form of feline coronavirus (FCoV; Pedersen et al., 1981; Poland et al., 1996; Vennema et al., 1998). The ability of FCoV to replicate inside macrophages is an essential virulence factor for the development of FIP (Dewerchin et al., 2005; Rottier et al., 2005). The disease is characterised by widespread immune-mediated vasculitis and/or pyogranulomas, manifesting as an effusive form, with high protein effusions in body cavities, or a non-effusive form (Wolfe and Griesemer, 1966; Montali and Strandberg, 1972; Pedersen, 1976). The effusive form of FIP is more common than the non-effusive form, although the relative prevalence of non-effusive cases appears to be increasing (Pedersen, 2009). FIP is usually fatal (Hartmann and Ritz, 2008).

Making a definitive diagnosis of FIP antemortem is challenging and relies on building up tiers of evidence based on history, clinical signs, cytological and biochemical testing of effusions, hematology

and diagnostic tests aimed specifically at feline coronavirus (FCoV), such as those that detect viral antigens or antibodies against the virus (Addie et al., 2004). Clinical signs are often non-specific, hematological and biochemical abnormalities are not pathognomonic, and serological tests and PCR have relatively low diagnostic accuracy (Hartmann et al., 2003). The standard methods for diagnosis are histological examination (of biopsies, but more usually at postmortem examination) and immunohistochemical analysis of affected organs (Sparkes et al., 1991; Paltrinieri et al., 1999; Hartmann et al., 2003; Addie et al., 2004). Biopsies collected antemortem are usually not an option because of the risks of surgery in cats that are already in poor health (Addie et al., 2004). Collection of specimens using minimally invasive techniques, such as fine needle aspirates or needle core (Tru-cut) biopsies, can reduce the anesthetic risks, although these tests have poor sensitivity (Giordano et al., 2005).

Direct immunofluorescence (DIF) staining detects intracellular FCoV in macrophages in effusions from cats with FIP and results can be obtained on the same day as specimen submission. While this test is commonly used in Europe and Australia, it is not readily available commercially in the USA. Previously published studies

* Corresponding author. Tel.: +1 765 4183186.

E-mail address: catvet@purdue.edu (A.L. Litster).

investigating the diagnostic accuracy of the DIF test in clinical specimens have reported 100% specificity and sensitivities of 57–95% (Cammarata Parodi et al., 1993; Paltrinieri et al., 1999; Hartmann et al., 2003). A positive result enables the clinician to rapidly confirm the diagnosis of FIP and to provide an appropriate prognosis.

The widely held belief that the DIF test could be relied on as a confirmatory test in antemortem effusion specimens was recently called into question when Held et al. (2011) reported 96% specificity for DIF in a study examining the diagnostic accuracy of tests for FIP in feline effusions. The aim of the present study was to compare the results of a DIF test for the detection of FCoV in macrophages in antemortem feline effusions with postmortem results using field samples.

Materials and methods

Animals

Antemortem feline effusion specimens were obtained from 17 cats presented to Purdue University Veterinary Teaching Hospital ($n = 15$) or the University of California Davis School of Veterinary Medicine ($n = 2$) and subsequently euthanased for postmortem examination. Where possible, biochemistry and cytology was also performed on the effusion specimens. The study was approved by the Purdue Animal Care and Use Committee on 18 April 2012 (protocol number 1203000618).

Effusion biochemistry and cytology were performed at the Clinical Pathology Laboratory at Purdue University Veterinary Teaching Hospital. The protein concentration (g/dL) was measured using a refractometer. The white cell count (WCC) and differential counts were measured using an automated counter (Abbott Cell Dyn 3700).

Direct immunofluorescence test

Samples of effusion fluid arrived at the laboratory within 24 h of collection and 1 mL was transferred into a sterile vial. Hyaluronidase (1 mg/mL; Sigma) was added to the sample and mixed gently to reduce specimen viscosity. For samples with a low cell count on subjective assessment, some of the specimen was centrifuged in a microcentrifuge tube, then half of the supernatant was removed and the cells were resuspended in the remaining fluid. After cells were concentrated by centrifugation using a cytospin apparatus (CytoSpin 2, Shandon) at 750 g for 5 min, one drop of fluid was placed onto each of four labelled specimen slides. Slides were fixed in 80% acetone for 10 min, then dried for 20 min at 22–25 °C. The specimen dot was circled with a PAP pen (Sigma).

To label macrophages, two to three drops of monoclonal mouse anti-cat major histocompatibility complex (MHC) class II antibody (AbD Serotec, catalog number MCA2724), diluted 1:250 with phosphate buffered saline (PBS; Amresco) were placed on two specimen slides and incubated for 30 min at 22–25 °C. The slides were then washed with PBS and incubated with rhodamine-labelled polyclonal goat anti-mouse IgG (H + L) (KPL, catalog number 03-18-06), diluted 1:40 in PBS, for 30 min at 22–25 °C. To detect FCoV, two to three drops of anti-FCoV mouse monoclonal IgG2A conjugated to biotin (FIPV3-70, Custom Monoclonals International), diluted 1:100 with bovine serum albumin (BSA), were added to the positive control slide and two specimen slides, and incubated and washed as described above. The slide was then incubated with fluorescein isothiocyanate (FITC)-labelled streptavidin (KPL, catalog number 072-30-00), diluted 1:40 in PBS. A third specimen slide was stained with rhodamine-labelled polyclonal goat anti-mouse IgG (H + L) (KPL, catalog number 03-18-06) as the primary antibody, diluted 1:40 with PBS, to exclude non-specific staining.

Labelled slides were then placed in a moisture chamber for 30 min at 22–25 °C, dipped briefly in deionised water, then held for 10 min in PBS and which was slowly mixed using a magnetic stirrer. After 10 min, the slides were dipped briefly in deionised water, then air dried. All four slides (three specimen slides and one control slide) were mounted with buffered glycerin and observed under an inverted microscope (Nikon TE2000) using filters for concurrent visualisation of light emitted from rhodamine (excitation 545–565 nm, emission 582–622 nm) and FITC (excitation 475–494 nm, emission 503–533 nm). MHC II positive cells (macrophages) had red fluorescent cytoplasm and FCoV positive cells had bright green fluorescent cytoplasm. Specimens were considered to be positive if there was an average of at least one fluorescence positive cell per high power field.

Where possible for specimens that returned positive results on the initial DIF test, testing was repeated on stored effusion specimens ($n = 7$) at intervals for up to 13 days after specimen collection. For serial testing, split samples of effusion fluid were stored in the dark at room temperature (RT, 21–25 °C) or refrigerated at 4 °C.

Statistical analysis

Sensitivity and specificity were calculated using a statistical website.¹ Descriptive statistics and comparisons between groups (Mann Whitney *U* tests) were calculated using GraphPad Prism version 5.0d.

Results

Antemortem effusion specimens were collected from 17 cats (peritoneal fluid: $n = 13$; pleural fluid: $n = 4$), of which 10 were diagnosed with effusive FIP at postmortem examination and seven were negative for FIP at postmortem examination (Table 1). Effusion protein concentrations were higher in cats with FIP than in cats where FIP was ruled out at postmortem examination (FIP: $n = 6$, median 5.1 g/dL, range 3.0–6.0 g/dL; non-FIP: $n = 7$, median 2.6 g/dL, range 2.0–5.9 g/dL; $P = 0.027$). There was no significant difference between the two groups in effusion WCC (FIP: $n = 6$, range 402–47,000/ μ L; non-FIP: $n = 6$, range <100–54,100/ μ L; $P > 0.05$).

The 10 cats that were diagnosed with FIP on histopathological evaluation of specimens collected at postmortem examination had positive DIF results (Fig. 1). Of seven cats with postmortem results that ruled out FIP, five had negative DIF results and two had positive DIF results (cases 5 and 12). Case 5 had a diagnosis of hypertrophic cardiomyopathy; the DIF test was negative when repeated on a peritoneal effusion specimen and also when performed using the same method on a cryostat sample of spleen, both collected at postmortem examination. Case 12 had a diagnosis of cholangiocarcinoma; in this case, the DIF test was negative when repeated on a specimen of spleen collected at postmortem examination, while cryostat sections of the spleen, intestine, liver and kidney were DIF positive. Diagnostic statistics from this study and from cases reported in two previously published studies where there was postmortem confirmation of DIF test results are presented in Table 2 (Cammarata Parodi et al., 1993; Hartmann et al., 2003).

When serial testing was performed on effusion specimens that were DIF test positive on initial testing and on duplicate specimens that were stored at RT (21–25 °C; $n = 7$; case 8 not tested) or refrigerated (4 °C; $n = 7$; case 2 not tested), positive results persisted for at least 1–8 days for specimens stored at RT and for at least 2–13 days in refrigerated specimens (Table 3). DIF positive effusion specimens kept at RT and repeatedly tested until a negative result was obtained first became DIF negative after 2, 5 and 7 days. In three cases (cases 11, 13 and 14), specimens stored refrigerated still tested DIF positive when the same specimens stored at RT had begun to test negative (Table 3). At 21–25 °C, the latest recorded positive result was at 1 day ($n = 1$), 2 days ($n = 1$), 4 days ($n = 2$), 5 days ($n = 1$), 6 days ($n = 1$) and 8 days ($n = 1$), while the first recorded negative result was at 2 days ($n = 1$), 5 days ($n = 1$) and 7 days ($n = 1$); the time that results became negative was not recorded for five cases. At 4 °C, the latest recorded positive result was at 2 days ($n = 1$), 4 days ($n = 1$), 5 days ($n = 2$), 6 days ($n = 1$), 8 days ($n = 1$) and 13 days ($n = 1$), while the time of the latest recorded positive result was not recorded for one case; at 4 °C, the time of the first negative result was not recorded for any of the eight cases.

Discussion

In this study, false positive results were identified using DIF to test for FIP in feline effusion specimens collected antemortem. Accurate antemortem diagnosis is of superior importance in

¹ See: http://www.swogstat.org/stat/public/binomial_conf.htm (accessed 24 May 2013).

Table 1

Clinical details of cats included in the study, including effusion site, laboratory results and postmortem diagnosis.

Case	Age	Breed	Sex	Effusion site	Effusion protein (g/dL)	Effusion WCC (/μL)	Effusion RCC ($\times 10^3/\mu\text{L}$)	Postmortem diagnosis	Antemortem DIF result
1	12 y	DSH	MN	Pleural	2.8	2000	388	Hypertrophic cardiomyopathy	Negative
2	3 m	DSH	MN	Peritoneal	3.5	2000	<20	FIP	Positive
3	3 y	DSH	FS	Peritoneal	2.7	3200	<20	Congestive heart failure	Negative
4	12 y	DSH	MN	Pleural	5.9	54,100	567	Pulmonary adenocarcinoma	Negative
5	4 y	DSH	MN	Peritoneal	<2.0	<100	<30	Hypertrophic cardiomyopathy	Positive
6	13 y	DSH	MN	Peritoneal	<2.0	NA	NA	Abdominal lymphoma	Negative
7	10 y	DSH	FS	Pleural	2.6	547	<30	Pulmonary carcinoma	Negative
8	1 y	Burmese	MN	Peritoneal	NA	NA	NA	FIP	Positive
9	8 y	DSH	MN	Peritoneal	3.0	864	<30	FIP	Positive
10	3 y	Siamese	MN	Peritoneal	4.9	7300	<30	FIP	Positive
11	8 m	DSH	MN	Peritoneal	5.3	47,000	<1	FIP	Positive
12	3 y	DSH	MN	Peritoneal	2.4	2780	<30	Cholangiocarcinoma	Positive
13	1 y	DSH	MN	Pleural	5.7	402	<30	FIP	Positive
14	5 m	DSH	MN	Peritoneal	NA	NA	NA	FIP	Positive
15	4 y	Bombay mix	FS	Peritoneal	NA	NA	NA	FIP	Positive
16	1 y	Bengal	MI, C	Peritoneal	6.0	980	39	FIP	Positive
17	3 m	DSH	MI	Peritoneal	NA	NA	NA	FIP	Positive

WCC, white cell count; RCC, red cell count; DIF, direct immunofluorescence; y, years; m, months; DSH, domestic shorthair; MN, male neutered; FS, female spayed; MI, male intact; C, cryptorchid; NA, not available; FIP, feline infectious peritonitis.

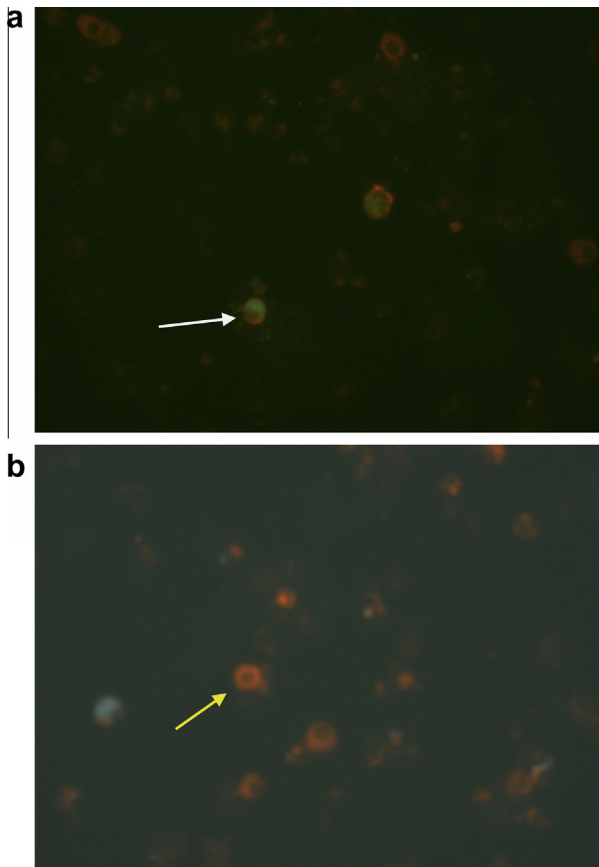


Fig. 1. Direct immunofluorescence test for feline coronavirus (FCoV) in smears of effusion samples. (a) Macrophage with positive staining for FCoV (white arrow). (b) Macrophage with negative staining for FCoV (yellow arrow).

clinical practice, since it directs the case management plan and enables veterinarians to give pet owners an appropriate prognosis while the cat is still alive. In the veterinary literature to date, there have been a limited number of feline effusion specimens where DIF test results have been compared to confirmation of FCoV infection status at postmortem examination (FIP negative and FIP positive cases) or survival for >12 months after testing (FIP negative cases)

(Cammarata Parodi et al., 1993, $n = 32$; Hartmann et al., 2003, $n = 171$; Table 2). The results reported by Paltrinieri et al. (1999) were not included in Table 2 because only 72/110 specimens analyzed in that study were collected antemortem and details of the numbers of true/false positive/negative results were not reported, so they did not match our study criteria.

Although the same diagnostic criteria were used across the studies cited in Table 2, it should be remembered that other animal and laboratory related factors might affect the results. If the specificity of DIF testing were <100%, according to the statistical rule of three, several hundred cases might be required for false positive results to emerge (Hanley and Lippmann-Hand, 1983). It is possible that false positive results were caused by antibodies binding to a target protein inside macrophages that was not FCoV. While it is technically possible that cross-reactivity could have been associated with the addition of hyaluronidase during the protocol, there is no evidence of an effect of hyaluronidase on other types of immunofluorescence tests used in human medicine.

It is possible that the false positive results identified in this study were caused by specimen contamination during the multiple staining steps for the DIF test. If specimen contamination was a contributing factor, the methodology used in our study could have been improved by the addition of a negative control slide. It is also possible that the test result was correct, but that FCoV infected cats were incubating FIP. The incubation period for naturally occurring FIP is unknown, but the clinical onset of disease can be preceded by long periods before overt disease is recognised.

In this study, all specimens were collected antemortem, whereas in previous comparable studies specimens were collected both antemortem and at postmortem examination (Cammarata Parodi et al., 1993; Hartmann et al., 2003). In the present study, the DIF test was negative when performed on an effusion specimen collected at postmortem examination from one of the false positive cases (case 5). In the other case (case 12), the effusion collected at postmortem examination was not subjected to DIF testing, but intestine and pooled liver and kidney collected at postmortem examination were positive on DIF testing. In practice, since the DIF test provides more rapid results than tests designed to detect FCoV antibodies or antigen, clinicians might be inclined to submit an effusion specimen for DIF testing as part of the exercise of 'building up tiers of evidence' for or against a diagnosis of FIP (Ad-die et al., 2004).

Table 2

Direct immunofluorescence antemortem effusion results from studies where the diagnostic criteria for feline coronavirus infection status were: (1) postmortem results (feline infectious peritonitis negative and positive cases); or (2) survival for >12 months after testing (feline infectious peritonitis negative cases).

	True positive	False positive	True negative	False negative	Total	Sensitivity (%) (95% CI)	Specificity (%) (95% CI)
Cammarata Parodi et al. (1993)	20	0	11	1	32	95.2 (76.2–99.9)	100 (71.5–100)
Hartmann et al. (2003)	109	0	16	46	171	70.3 (62.5–77.4)	100 (79.4–100)
Current study	10	2	5	0	17	100 (69.2–100)	71.4 (29.0–96.3)
Total	139	2	32	47	220	74.3 (67.9–80.8)	94.1 (80.3–99.3)

95% CI, 95% confidence interval.

Table 3

Results of serial direct immunofluorescence (DIF) testing for feline coronavirus in positive effusion specimens stored refrigerated (4 °C) or room temperature (RT; 22–25 °C).

Case	4 °C latest recorded positive result (days)	RT latest recorded positive result (days)	RT first recorded negative result (days)
2	NR	4	NR
8	4	NR	NR
10	5	5	NR
11	13	6	7
12	2	2	NR
13	6	1	2
14	5	4	5
17	8	8	NR

Days, days after laboratory submission; NR, not recorded.

The sensitivity of DIF testing in this study was 100%, which is higher than in previous studies (Cammarata Parodi et al., 1993; Hartmann et al., 2003; Table 2). It is possible that differences in the anti-FCoV antibody conjugate used in each of the three studies affected sensitivity. In the two previous studies, the antibody used was a commercial feline polyclonal FITC-conjugated antiserum which detects both feline infectious peritonitis biotypes 1 and 2, and cross reacts with transmissible gastroenteritis virus and canine coronavirus (catalogue number CJ-F-FIP, VMRD; Cammarata Parodi et al., 1993; Hartmann et al., 2003). In the study by Cammarata Parodi et al. (1993), specimen processing took place within 15 h of collection and a sensitivity of 95.2% was reported. Information on the time between specimen collection and processing was not provided for the study by Hartmann et al. (2003), which reported a DIF test sensitivity of 70.3%.

Initial DIF testing in the current study took place within 24 h of specimen collection and we also documented declining test sensitivity as the time between specimen collection and processing increased. This was especially the case if specimens were stored at RT rather than being refrigerated before processing (Table 3). This suggests that specimens should be kept close to 4 °C during transport to the laboratory, in which case FCoV can be detected for at least 2 days and possibly for more than 1 week. However, if stored at RT, FCoV detection might only be possible for 1 day after specimen collection in some cases.

Since FCoV (feline infectious peritonitis virus) has a strong tropism for macrophages (Dewerchin et al., 2005; Rottier et al., 2005), it was important to ensure that only macrophages were being 'read' during DIF testing. The test methodology used here included macrophage tagging so that only immunofluorescence in macrophages was viewed when the test slides were read. While further staining added rigour to our research methodology and avoided misclassification of positive cells, the differentiation of macrophages from other cells is usually relatively straightforward, so macrophage tagging is probably superfluous in routine practice.

A major limitation to this study is the relatively small sample size, especially when conclusions are being drawn regarding the diagnostic accuracy of the methodology used. By combining the

results of studies with similar entry criteria to calculate sensitivity and specificity for the DIF test from a larger sample set (Table 2), we aimed to alleviate this problem and estimate diagnostic accuracy more closely. However, since the studies were not identical, this might have introduced errors into our calculations. Additionally, it seems unrealistic to expect that any test could achieve 100% sensitivity or specificity under a variety of real-life conditions. Another limitation is the lack of negative control slides when performing DIF and this is a recommended component of future testing procedure.

Conclusions

A sensitivity of 100% and specificity of 71.4% were obtained when the DIF test was used to determine FIP status on feline effusion specimens collected antemortem and where infection status was confirmed at postmortem examination. Positive specimens stored at 4 °C remained positive in the DIF test for at least as long, and often longer, than duplicate specimens stored at RT.

Conflict of interest statement

None of the authors has any financial or personal relationships that could inappropriately influence or bias the content of the paper.

Acknowledgements

This study was supported, in part, by a grant from Maddie's Fund. The Purdue Maddie's Shelter Medicine Program is underwritten by a grant from Maddie's Fund. We would also like to thank the staff at the Indiana Animal Disease Diagnostic Laboratory (ADDL) for performing the DIF test, the veterinary pathologists and histopathology technicians at the ADDL, Dr Patty Pesavento, University of California Davis, for contributing case material, and Dr Hsin-Yi Weng, Purdue University, for statistical support.

References

- Addie, D.D., Paltrinieri, S., Pedersen, N.C., 2004. Recommendations from workshops of the Second International Feline Coronavirus/Feline Infectious Peritonitis Symposium. *Journal of Feline Medicine and Surgery* 6, 125–130.
- Cammarata Parodi, M.C., Camarata, G., Paltrinieri, S., Lavazza, A., Ape, F., 1993. Using direct immunofluorescence to detect coronaviruses in peritoneal and pleural effusions. *Journal of Small Animal Practice* 34, 609–613.
- Dewerchin, H.L., Cornelissen, E., Nauwynck, H.J., 2005. Replication of feline coronaviruses in peripheral blood monocytes. *Archives of Virology* 150, 2483e500.
- Giordano, A., Paltrinieri, S., Bertazzolo, W., Milesi, E., Parodi, M., 2005. Sensitivity of Tru-cut and fine needle aspiration biopsies of liver and kidney for diagnosis of feline infectious peritonitis. *Veterinary Clinical Pathology* 34, 368–374.
- Hanley, J.A., Lippmann-Hand, A., 1983. If nothing goes wrong, is everything all right? Interpreting zero numerators. *Journal of the American Medical Association* 249, 1743–1745.
- Hartmann, K., Binder, C., Hirschberger, J., Cole, D., Reinacher, M., Schroo, S., Frost, J., Egberink, H., Lutz, H., Hermans, W., 2003. Comparison of different tests to diagnose feline infectious peritonitis. *Journal of Veterinary Internal Medicine* 17, 781–790.
- Hartmann, K., Ritz, S., 2008. Treatment of cats with feline infectious peritonitis. *Veterinary Immunology and Immunopathology* 123, 172–175.

- Held, S., König, M., Hamann, H.P., Senge, R., Hullermeier, E., Neiger, R., 2011. Accuracy of diagnostic tests for feline infectious peritonitis (FIP) in cats with body cavity effusion. In: Proceedings of the European College of Veterinary Internal Medicine Congress, Seville, Spain, 8–10 September 2011, Abstract IM-O-17.
- Montali, R.J., Strandberg, J.D., 1972. Extraperitoneal lesions in feline infectious peritonitis. *Veterinary Pathology* 9, 109–121.
- Paltrinieri, S., Parodi, M.C., Cammarata, G., 1999. In vivo diagnosis of feline infectious peritonitis by comparison of protein content, cytology, and direct immunofluorescence test on peritoneal and pleural effusions. *Journal of Veterinary Diagnostic Investigation* 11, 358–361.
- Pedersen, N.C., 1976. Feline infectious peritonitis. Something old, something new. *Feline Practice* 6, 42–51.
- Pedersen, N.C., Boyle, J.F., Floyd, K., Fudge, A., Barker, J., 1981. An enteric coronavirus infection of cats and its relationship to feline infectious peritonitis. *American Journal of Veterinary Research* 42, 368–377.
- Pedersen, N.C., 2009. A review of feline infectious peritonitis virus infection: 1963–2008. *Journal of Feline Medicine and Surgery* 11, 225–258.
- Poland, A.M., Vennema, H., Foley, J.E., Pedersen, N.C., 1996. Two related strains of feline infectious peritonitis virus isolated from immunocompromised cats infected with a feline enteric coronavirus. *Journal of Clinical Microbiology* 34, 3180–3184.
- Rottier, P.J., Nakamura, K., Schellen, P., Volders, H., Haijema, B.J., 2005. Acquisition of macrophage tropism during the pathogenesis of feline infectious peritonitis is determined by mutations in the feline coronavirus spike protein. *Journal of Virology* 79, 14122–14130.
- Sparkes, A.H., Gruffydd-Jones, T.J., Harbour, D.A., 1991. Feline infectious peritonitis: A review of clinicopathological changes in 65 cases, and a critical assessment of their diagnostic value. *Veterinary Record* 129, 209–212.
- Vennema, H., Poland, A., Foley, J., Pedersen, N.C., 1998. Feline infectious peritonitis viruses arise by mutation from endemic feline enteric coronaviruses. *Virology* 243, 150–157.
- Wolfe, L.G., Griesemer, R.A., 1966. Feline infectious peritonitis. *Pathologia Veterinaria* 3, 255–270.