

In-office balloon dilation and drainage of frontal sinus mucocele

Jean Anderson Eloy, M.D., F.A.C.S.,^{1,2,3} Pratik A. Shukla, M.D.,¹ Osamah J. Choudhry, M.D.,² Jean Daniel Eloy, M.D.,⁴ and Paul D. Langer M.D., F.A.C.S.⁵

ABSTRACT

Treatment of frontal sinus disease represents one of the most challenging aspects of endoscopic sinus surgery. Frontal sinus mucocele drainage may be an exception to the rule because in many instances, the expansion of the mucocele widens the frontal sinus recess and renders surgical drainage technically undemanding. Recently, there has been an increased interest in in-office procedures in otolaryngology because of patient satisfaction and substantial savings of time and cost for both patients and physicians. Similarly, the past few years have witnessed an increased use of balloon dilation devices in sinus surgery. Previously, we have described the in-office use of this device in treating patients who failed prior conventional frontal sinusotomy in the operating room. In this report, we describe our step-by-step in-office experience using this tool for drainage of a large frontal sinus mucocele.

(Allergy Rhinol 4:e36–e40, 2013; doi: 10.2500/ar.2013.4.0041)

Frontal sinus disease management has been a difficult undertaking in endoscopic sinus surgery. The challenges faced during frontal sinusotomy can be attributed to the difficult and narrow anatomy of the frontal sinus recess and significant mucosal trauma sustained during frontal sinusotomy. Hence, numerous new techniques and instrumentation have been developed to address the variety of frontal sinus pathologies.^{1–6} Frontal sinus mucocele drainage may be an exception to the rule because the expansion of the mucocele significantly widens the frontal sinus recess and can render surgical drainage technically straightforward.

Recently, there has been an increased interest in in-office procedures in many subfields of otolaryngology.^{7,8} Analyses of in-office procedures in laryngology, otology, and rhinology revealed them to be safe and satisfying for patients, with substantial savings of time and money for both patients and physicians.⁸ In-office balloon dilation of the sinuses has recently gained significant popularity.⁹ Although still controversial be-

cause of a lack of definitive substantiating evidence and prospective randomized control trials to support its efficacy,^{10,11} proponents of this technology have reported favorable outcomes with its use.⁹ To our knowledge, this device has not been described for the in-office drainage of large frontal sinus mucoceles. Previously, we have described the in-office use of balloon dilation in treating patients who failed prior conventional frontal sinusotomy in the operating room.¹² Given the many advantages of in-office procedures for patients and physicians, our familiarity with the balloon dilation device, and the relative straightforwardness of accessing a widened frontal sinus recess from mucocele expansion, we have used and are describing our step-by-step in-office experience using this tool to drain a large frontal sinus mucocele.

ILLUSTRATIVE CASE

Subject

A 68-year-old woman presented with a 2-year history of asymptomatic progressive right eye proptosis and pressure. She denied changes in visual acuity; diplopia; or history of sinusitis, anosmia, nasal congestion, or previous trauma. Oculoplastic examination revealed 4 mm of right proptosis, and 20/20 visual acuity. Nasal endoscopic examination revealed a deviated nasal septum to the left side and a widened right middle meatus and frontal sinus recess. The patient had a medical history significant for systemic hypertension, 38 pack-years of tobacco usage, pulmonary hypertension, and severe chronic obstructive pulmonary disease.

From the Departments of ¹Otolaryngology–Head and Neck Surgery and ²Neurological Surgery, ³Center for Skull Base and Pituitary Surgery, Neurological Institute of New Jersey, and Departments of ⁴Anesthesiology and ⁵Ophthalmology and Visual Sciences, University of Medicine and Dentistry of New Jersey–New Jersey Medical School, Newark, New Jersey

Presented at the 58th annual meeting of the American Rhinologic Society, Washington, D.C., September 8, 2012

The authors have no conflicts of interest to declare pertaining to this article
Address correspondence and reprint requests to Jean Anderson Eloy, M.D., F.A.C.S., Department of Otolaryngology–Head and Neck Surgery, University of Medicine and Dentistry of New Jersey–New Jersey Medical School, 90 Bergen Street, Suite 8100, Newark, NJ 07103

E-mail address: jean.anderson.elay@gmail.com

Published online April 2, 2013

Copyright © 2013, OceanSide Publications, Inc., U.S.A.

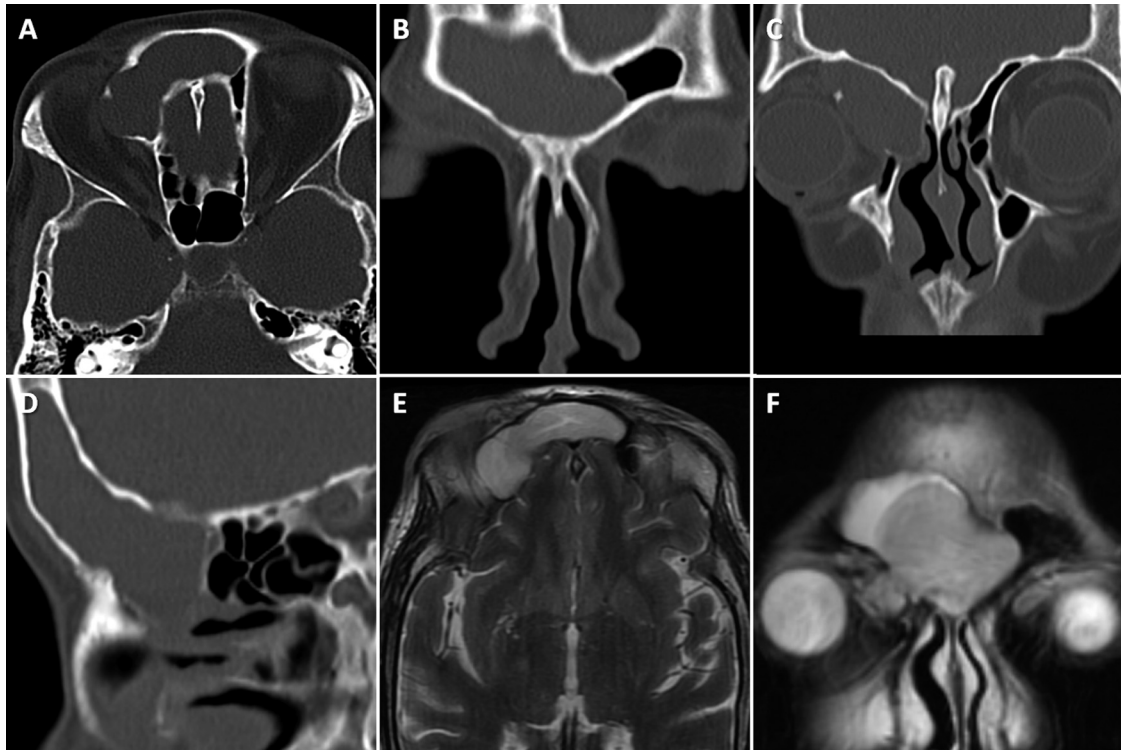


Figure 1. (A) Axial, (B and C) coronal, and (D) sagittal computed tomography scans of the orbits and paranasal sinuses show an expansile right frontal sinus mucocele with downward and lateral compression and displacement of the globe. (E) Axial and (F) coronal T2-weighted magnetic resonance imaging show a hyperintense right frontal sinus mass consistent with a mucocele.

Radiological Evaluation

Computed tomography scan of the orbits and paranasal sinuses showed a right frontal sinus expansile lesion with proptosis of the right eye with significant inferior and lateral displacement of the globe. There was erosion of the right lamina papyracea and the orbital roof (Fig. 1, A–D). Magnetic resonance imaging showed a large right frontal sinus mass with signal intensity consistent with a frontal sinus mucocele (Fig. 1, E and F).

Surgical Technique

Thirty minutes before the in-office rhinologic procedure, the patient was asked to take 2 tablets of oxycodone/acetaminophen (5/325 mg). The patient was then placed in the seated position and vital signs were assessed. The bilateral nasal cavities were decongested and anesthetized with a combination of oxymetazoline hydrochloride 0.05% and topical lidocaine hydrochloride 4%. After 5 minutes had elapsed, the right nasal cavity was packed with cottonoids soaked in topical lidocaine hydrochloride 4% and oxymetazoline hydrochloride 0.05% solution. Care was taken to lay the cottonoids in the middle meatus, anterosuperiorly in the region of the frontal sinus recess and against the nasal septum and anterolateral nasal wall to anesthetize the path of potential instrument contact. Ten min-

utes was subsequently allowed to elapse with the cottonoids in place against the nasal mucosa. Using a tuberculin syringe with a 25G needle, the areas surrounding the frontal sinus recess (upper uncinate process, upper middle turbinate, and anterior superior face of the bulla ethmoidalis) were injected with 1% lidocaine hydrochloride with 1:100,000 of epinephrine solution. After 5 minutes was allowed to elapse for an adequate anesthesia effect, the mucocele content was partially drained with a 21G needle. The frontal sinus recess area was subsequently cannulated using the transnasal balloon dilation probe (Entellus Medical, Inc., Maple Grove, MN) under direct endoscopic visualization with a 30 or 70° endoscope (Karl Storz and Co., Tuttlingen, Germany; Fig. 2). The content of the mucocele was collected for culture and pathological examination. The balloon was subsequently advanced, and the ostium was repeatedly dilated until an adequate diameter was achieved (≥ 5 mm).^{13,14}

Postoperative Care

Postoperatively, the patient was treated with 10 days of an oral corticosteroid, a β -lactamase resistant penicillin, oxycodone/acetaminophen (5/325 mg) as needed for pain, and a topical nasal corticosteroid was started at the first postoperative visit (~7–10 days).

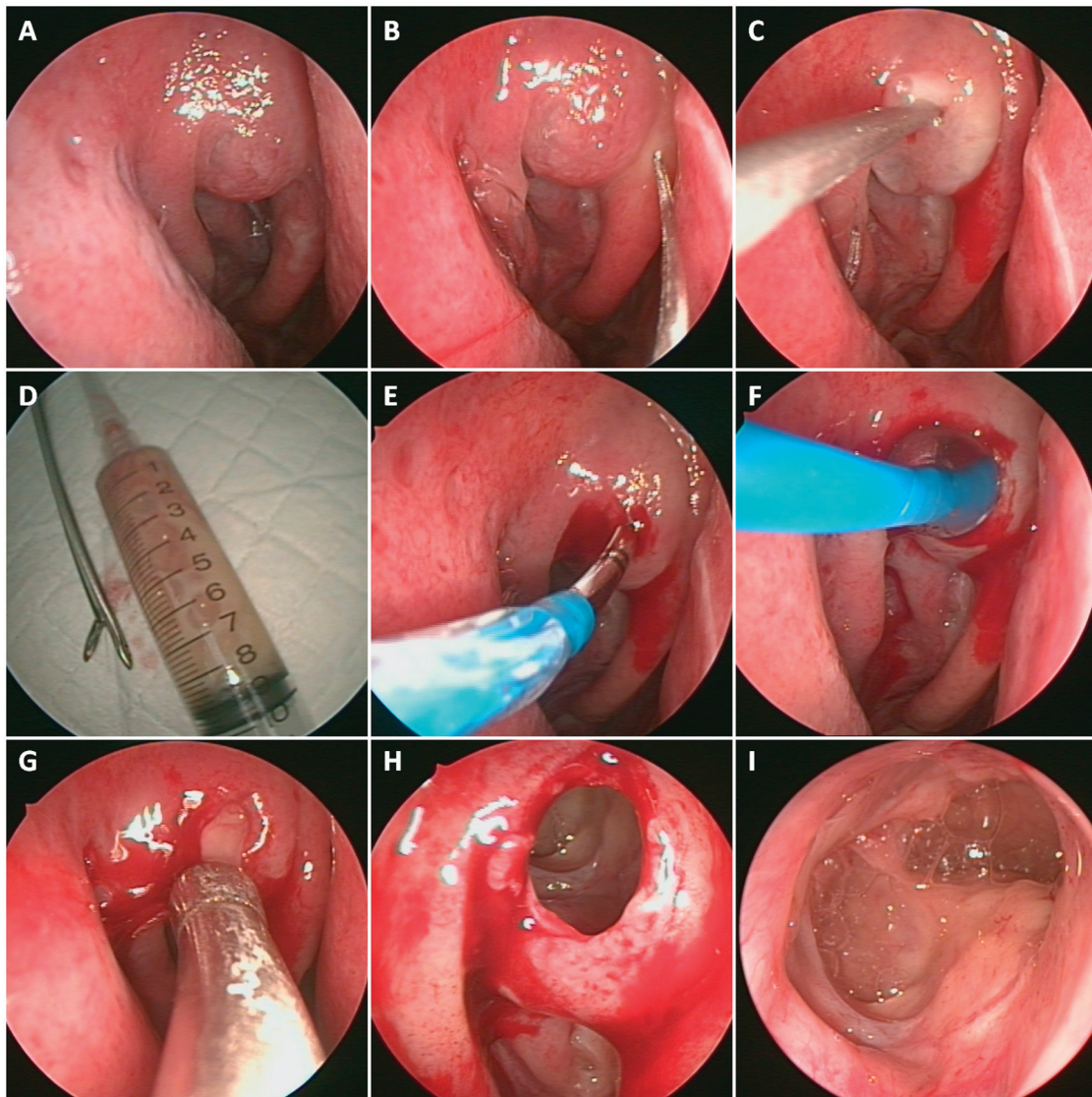


Figure 2. (A) In-office 30° endoscopic view shows expansion of the frontal sinus recess with bulging of the mucocoele in the middle meatus. (B) After the nasal cavity was decongested and anesthetized, it was injected with 1% lidocaine with 1:100,000 of epinephrine solution. (C and D) The mucocoele content was partially suctioned using a 10-mL syringe with a 21G needle. (E) The mucocoele was then cannulated (F) with the balloon dilation probe and dilated. (G) The contents of the mucocoele was subsequently evacuated, followed by repeated dilation using the balloon dilation device. Endoscopic (H) 30° and (I) 70° view of the opening and cavity after dilation.

Follow-Up

Postoperatively, the patient's proptosis was significantly decreased. She maintained full extraocular movements and normal visual acuity with resolution of eye pressure. Her postoperative CT scan showed a widely patent right frontal sinus cavity (Fig. 3). She had a patent drainage pathway at her 8-month follow-up without signs of contraction.

DISCUSSION

Frontal sinus disease is typically treated with medical management. Endoscopic sinus surgery is reserved for refractory cases and frontal sinus mucoceles or tumors. Postoperative recurrence secondary to scarring

of the frontal sinus recess is not uncommon and is usually the result of mucosal trauma sustained during surgery, caused by significant manipulation of a narrowed frontal sinus recess. Typically, frontal sinus mucoceles have been treated using external or endoscopic techniques under general anesthesia. However, in many cases (as was seen in this case), this pathological entity does not represent a significant surgical challenge because of the expansion of the frontal sinus recess, which renders this usually difficult anatomic area straightforward to access.

The last 5 years have witnessed a significant increase in the number of in-office procedures performed by otolaryngologists because of patient's satisfaction, in-

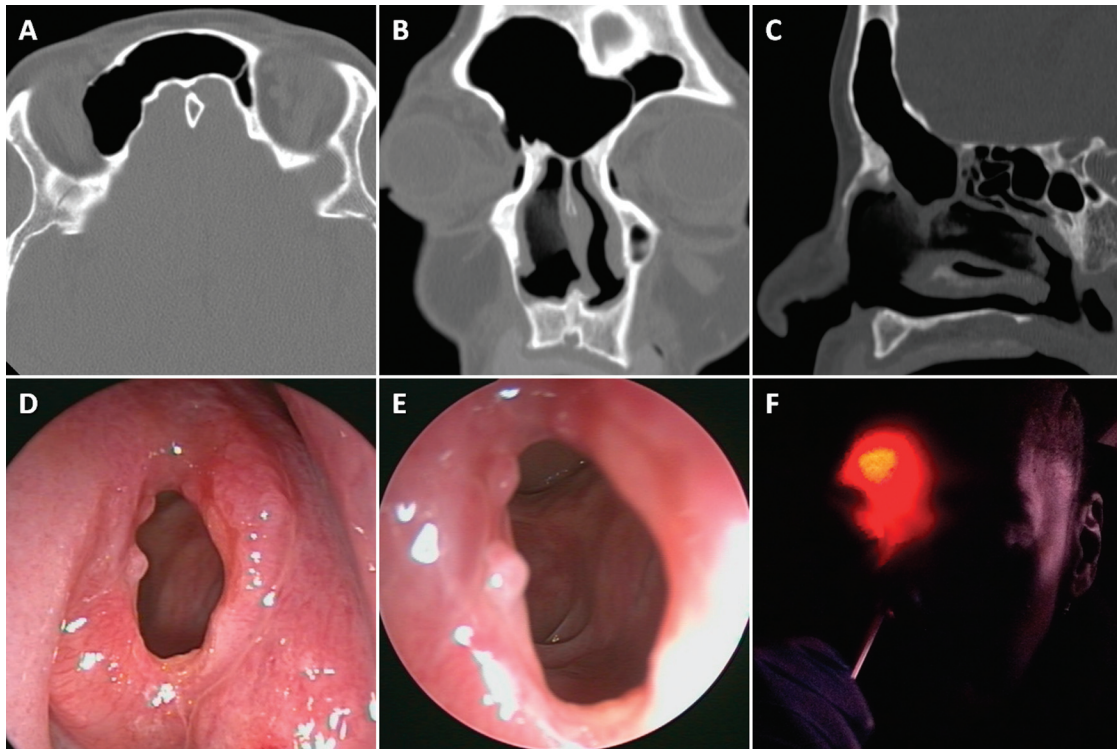


Figure 3. Postoperative (A) axial, (B) coronal, and (C) sagittal computed tomography scans of the orbits and paranasal sinuses show a patent right frontal sinus cavity. (D and E) Postoperative 70° nasal endoscopy shows a patent dilated opening. (F) Postoperative photograph of illuminated right frontal sinus cavity.

creasing physician expertise, and significant savings in time and cost.⁸ The subfield of rhinology, *e.g.*, has witnessed the emergence and escalating use of in-office balloon catheter devices as a means of dilating the diseased sinus ostia.¹² However, the use of balloon catheter devices has not been explicitly reported for drainage of large frontal sinus mucocele in the office. Potential advantages of the in-office use of this technology for drainage of frontal sinus mucoceles includes avoidance of the risks associated with general anesthesia, significantly shorter perioperative time for surgeons and patients alike, and overall decreased surgical cost.

To successfully use in-office balloon dilation for frontal sinus disease, appropriate patient selection is paramount. Although, ideally, one would prefer to operate on younger and healthier patients, this illustrative case shows a scenario where this technique was useful in an otherwise medically unhealthy patient. The expansion of this patient's frontal sinus recess from the mucocele definitely rendered surgical access feasible. This patient also had systemic and pulmonary hypertension, as well as chronic obstructive pulmonary disease, which significantly increased her risks of perioperative complications if she underwent general anesthesia.^{15–17}

Clear understanding of frontal recess anatomy, familiarity with balloon catheter devices, and adequate patient selection make in-office balloon dilation and

drainage of frontal sinus mucoceles an additional tool in the otolaryngologist's armamentarium for the management of frontal sinus mucoceles. This procedure should be considered a viable and reasonable option before subjecting patients to traditional endoscopic and open frontal sinus surgeries as well as the risks associated with general anesthesia. Nonetheless, it should be noted that this case could have been performed in the office setting using traditional endoscopic sinus surgery instruments. The balloon catheter device was chosen in this case because of the potential decrease in mucosal trauma associated with its use. Additionally, in cases of significant signal heterogeneity in a mucocele, multiple compartments within a mucocele, and significant and difficult bony architecture near the frontal sinus recess, this technique may not be the best approach. Traditional endoscopic sinus instruments may be superior in the aforementioned situations to completely address such mucoceles.

Given the loss of bone between the frontal sinus and orbital interface in the presented case, there are potential risks to introducing a balloon catheter into the frontal sinus mucocele without navigation. However, with adequate knowledge of the anatomy and appropriate surgical technique, this procedure can be achieved safely. Key steps to preventing complications in this setting include (a) meticulous and systematic analysis of preoperative imaging with special consid-

eration of areas of dehiscence at the skull base and lamina papyracea, (b) adequate patient selection (as for most in-office procedures, this case may not be appropriate for anxious patients), (c) adequate local anesthesia during the procedure, (d) suctioning of mucocele content to confirm the diagnosis before balloon dilation, (e) aiming of the balloon probe away from known dehiscent area, (f) ensuring correct positioning of the balloon catheter device within the mucocele through transillumination or fluoroscopy if available, and (g) care to only introduce a small portion of the probe and balloon into the mucocele.

Limitations of this study include all limitations inherent to a single case description. Although studies of this type are good in reporting novelty, a case study can not be used to make generalized recommendations. However, this novel technique should promote discussion and be the basis for future investigations in this area.

CONCLUSION

In-office frontal sinus mucocele drainage using balloon dilation appears to be a feasible technique and potential alternative to conventional endoscopic procedures in the operating room. In properly selected patients (similar to the case described), this technique can obviate the need for general anesthesia and the operating room and potentially reduce surgical cost.

REFERENCES

1. Friedel ME, Kuperan AB, Liu JK, and Eloy JA. Modified Draf IIB with frontal intersinus septectomy for contralateral frontal sinus disease: A cadaveric study. *Laryngoscope* 121:S229, 2011.
2. Eloy JA, Kuperan AB, Friedel ME, et al. Modified hemi-Lothrop procedure for supraorbital frontal sinus access: A case series. *Otolaryngol Head Neck Surg* 147:167–169, 2012.
3. Eloy JA, Friedel ME, Murray KP, and Liu JK. Modified hemi-Lothrop procedure for supraorbital frontal sinus access: A cadaveric feasibility study. *Otolaryngol Head Neck Surg* 145:489–493, 2011.
4. Eloy JA, Friedel ME, Kuperan AB, et al. Modified mini-Lothrop/extended Draf IIB procedure for contralateral frontal sinus disease: a case series. *Int Forum Allergy Rhinol* 2:321–324, 2012.
5. Eloy JA, Friedel ME, Kuperan AB, et al. Modified mini-Lothrop/extended Draf IIB procedure for contralateral frontal sinus disease: A cadaveric feasibility study. *Otolaryngol Head Neck Surg* 146:165–168, 2012.
6. Reh DD, Melvin TA, Bolger WE, and Lane AP. The frontal intersinus septum takedown procedure: Revisiting a technique for surgically refractory unilateral frontal sinus disease. *Laryngoscope* 121:1805–1809, 2011.
7. Albritton F, Casiano R, and Sillers M. Feasibility of in-office endoscopic sinus surgery with balloon sinus dilation. *Am J Rhinol Allergy* 26:243–248, 2012.
8. Prickett KK, Wise SK, and DelGaudio JM. Cost analysis of office-based and operating room procedures in rhinology. *Int Forum Allergy Rhinol* 2:207–211, 2012.
9. Vaughan WC. Review of balloon sinuplasty. *Curr Opin Otolaryngol Head Neck Surg* 16:2–9, 2008.
10. Burton MJ, Bhattacharyya N, and Rosenfeld RM. Extracts from the Cochrane Library: Functional endoscopic balloon dilation of sinus ostia for chronic rhinosinusitis. *Otolaryngol Head Neck Surg* 145:371–374, 2011.
11. Ahmed J, Pal S, Hopkins C, and Jayaraj S. Functional endoscopic balloon dilation of sinus ostia for chronic rhinosinusitis. *Cochrane Database Syst Rev* Jul 6:CD008515, 2011.
12. Eloy JA, Friedel ME, Eloy JD, et al. In-office balloon dilation of the failed frontal sinusotomy. *Otolaryngol Head Neck Surg* 146:320–322, 2012.
13. Hosemann W, K[umlaut]uhnel T, Held P, et al. Endonasal frontal sinusotomy in surgical management of chronic sinusitis: A critical evaluation. *Am J Rhinol* 11:1–9, 1997.
14. Naidoo Y, Wen D, Bassiouni A, et al. Long-term results after primary frontal sinus surgery. *Int Forum Allergy Rhinol* 2:185–190, 2012.
15. Fleisher LA, Beckman JA, Brown KA, et al. ACC/AHA 2007 guidelines on perioperative cardiovascular evaluation and care for noncardiac surgery: executive summary: A report of the American College of Cardiology/American Heart Association Task Force on Practice Guidelines (Writing Committee to Revise the 2002 Guidelines on Perioperative Cardiovascular Evaluation for Noncardiac Surgery). *Anesth Analg* 106:685–712, 2008.
16. Fleisher LA, Beckman JA, Brown KA, et al. ACC/AHA 2007 Guidelines on perioperative cardiovascular evaluation and care for noncardiac surgery: Executive summary: A report of the American College of Cardiology/American Heart Association Task Force on Practice Guidelines (Writing Committee to Revise the 2002 Guidelines on Perioperative Cardiovascular Evaluation for Noncardiac Surgery) developed in collaboration with the American Society of Echocardiography, American Society of Nuclear Cardiology, Heart Rhythm Society, Society of Cardiovascular Anesthesiologists, Society for Cardiovascular Angiography and Interventions, Society for Vascular Medicine and Biology, and Society for Vascular Surgery. *J Am Coll Cardiol* 50:1707–1732, 2007.
17. Arbous MS, Grobbee DE, van Kleef JW, et al. Mortality associated with anaesthesia: A qualitative analysis to identify risk factors. *Anaesthesia* 56:1141–1153, 2001. □