

Apatinib combined with docetaxel as a salvage treatment for metastatic esophageal squamous cancer: a case report

Li-Jun Liang^{1,2,*}

Yi-Xuan Wen^{1,2,*}

You-You Xia^{1,*}

Lei Wang¹

Jia-Yan Fei^{1,2}

Xiao-Dong Jiang^{1,2}

¹Department of Radiation Oncology, The Affiliated Lianyungang Hospital of Xuzhou Medical University, Lianyungang, People's Republic of China; ²Tumor Laboratory, The Affiliated Lianyungang Hospital of Xuzhou Medical University, Lianyungang, People's Republic of China

*These authors contributed equally to this work

Abstract: The first-line treatment for metastatic esophageal squamous cell cancer (ESCC) is a platinum- or fluorouracil-based agent, followed by later treatment with taxanes or irinotecan. However, there is still no standard third-line treatment for patients with metastatic ESCC. We present a 62-year-old man initially diagnosed with locally advanced ESCC. After esophagectomy, the patient was administrated with six cycles of docetaxel and cisplatin combined with radiotherapy. After 8.0 months, computed tomography showed the left cervical lymph node metastasis. However, the metastatic lymph node was not significantly shrunk after locally palliative radiotherapy and the patient was intolerant of irinotecan as second-line systemic therapy. Then, the patient was rechallenged with six cycles of docetaxel combined with apatinib (an oral tyrosine kinase inhibitor to vascular endothelial growth factor receptor 2 [VEGFR2]), followed by single dose of apatinib as maintenance therapy. According to the Response Evaluation Criteria in Solid Tumors (RECIST) 1.1 standard, partial response was achieved in this case after treating with docetaxel combined with apatinib. Now, the progression-free survival of this patient has been 7.5 months. After administrating with apatinib for 2 weeks, hypertension (grade III) was observed. Thus, the dose of apatinib was decreased from 850 to 500 mg and then the adverse effects were controllable and tolerable. In conclusion, apatinib with concurrent docetaxel provided potential efficacy as a salvage treatment for patients with metastatic ESCC. To our knowledge, this is the first case of ESCC who responded to apatinib combined with docetaxel.

Keywords: metastatic esophageal cancer, apatinib, docetaxel, vascular endothelial growth factor receptor-2, anti-angiogenesis

Introduction

Esophageal cancer is the world's eighth most common cancer and the sixth leading cause of cancer-related deaths.¹ Different from the situation in western countries, esophageal squamous cell carcinoma (ESCC) is still the dominant pathological type in China, which accounts for more than 95% of clinical cases.² The annual incidence of ESCC in China was about 260,000 and approximately half of the patients diagnosed with ESCC presented with metastatic diseases.² The first-line treatment for metastatic esophageal cancer is a platinum or fluorouracil-based agent,³⁻⁵ followed by later treatment with taxanes^{6,7} or irinotecan.^{8,9} No treatment strategy has been defined for patients who have been failed or intolerant to current standard therapies.

Angiogenesis is a critical process for cell growth, especially for the tumor growth.¹⁰ The vascular epidermal growth factor (VEGF) could bind to vascular epidermal growth factor receptor (VEGFR) and activate the downstream pathway to stimulate

Correspondence: Xiao-Dong Jiang
Department of Radiation Oncology,
Tumor Laboratory, The Affiliated
Lianyungang Hospital of Xuzhou Medical
University, NO 182 Tongguan North
Road, Lianyungang 222002, Jiangsu
Province, People's Republic of China
Tel +86 518 8560 5722
Fax +86 518 8545 6700
Email jxdysy1970@163.com

the proliferation of vessel endothelium, then leading to the growth of tumor.¹¹ Previous molecular pathology studies have revealed that VEGF overexpression could be detected in about 44.43% of esophageal cancer and the estimated mortality risk was 1.82-fold greater in patients with high VEGF expression,^{12,13} which indicated that antiangiogenic agents may have a therapeutic effect on esophageal cancer.

Apatinib, a novel small molecule tyrosine kinase inhibitor (TKI), exerts its anti-tumor effects by specifically acting on VEGFR-2.¹⁴ Phase II and III clinical trials suggested that apatinib could prolong overall survival (OS) of advanced gastric cancer patients who failed in the second-line treatment.^{15,16} In December 2014, China State Food and Drug Administration approved and launched apatinib as a treatment for patients with chemotherapy-refractory gastric cancer. Furthermore, many clinical studies have reported the satisfying efficacy of apatinib on various cancers including non-small-cell lung cancer,¹⁷ breast cancer,^{18,19} and pancreatic cancer.²⁰ However, there is rare report to evaluate its efficacy and safety in patient with esophageal cancer. We herein report a unique case of ESCC receiving concurrent apatinib and docetaxel following failure of the second-line therapy. The progression-free survival (PFS) of this patient at least 7.5 months has been achieved now, demonstrating the potential of apatinib combined with chemotherapy in the treatment of ESCC. To our knowledge, this is the first case of ESCC who responded to apatinib combined with docetaxel.

Case report

A 62-year-old man suffered from dysphagia for almost 1 month was admitted to our hospital. Endoscopy biopsy suggested ESCC 28–35 cm away from incisors (Figure 1A and B) and computed tomography (CT) indicated that there was a space-occupying lesion at the lower esophagus (Figure 2).

Physical examination did not show syndromes of hoarse voice and cough during drinking water, and no swelling superficial lymph node felt by touch. The patient had no history of hypertension, heart disease, diabetes, and kidney-related diseases.

The esophagectomy was performed on September 2, 2016; postoperative pathological examination indicated moderately differentiated ESCC. The full thickness of the esophageal wall was invaded, with dimensions of $5 \times 2 \times 1.3$ cm, and metastasis was observed in esophageal lymph nodes (3/7; Figure 1B) but not observed in the resection margin. According to the eighth edition Staging Guidelines of American Joint Committee on Cancer, the surgical-pathological staging was T3N2M0, stage IIIB. Since September 2016, the patient received six cycles of chemotherapy of docetaxel (75 mg/m^2 , day 1) and cisplatin (70 mg/m^2 , day 1) combined with radiation therapy (total dose=50 Gy/25 fractions). In the follow-up after therapy, the gastroscopy and imaging examination showed no tumor recurrence. Until May 1, 2017, a lump could be touched in the patient's left neck, shown as left cervical lymph node metastasis by CT (Figure 3A and B). Subsequently, locally radiotherapy (total dose=50 Gy/25 fractions) and three cycles of irinotecan (CPT-11, 250 mg/m^2 , 21 days as one cycle) monotherapy were performed; however, the patient suffered intolerable myelosuppression (grade IV) and severe gastrointestinal disturbances. Since CT revealed that the left cervical lymph node was not narrowed, the treatment was terminated (Figure 3C). After symptomatic treatment, the patient's leucocytes returned to normal level, and the gastrointestinal adverse reactions disappeared.

Since July 28, 2017, the patient received apatinib combined with six cycles of docetaxel (75 mg/m^2 , day 1, 21 days as one cycle) and then administrated apatinib as maintenance therapy.

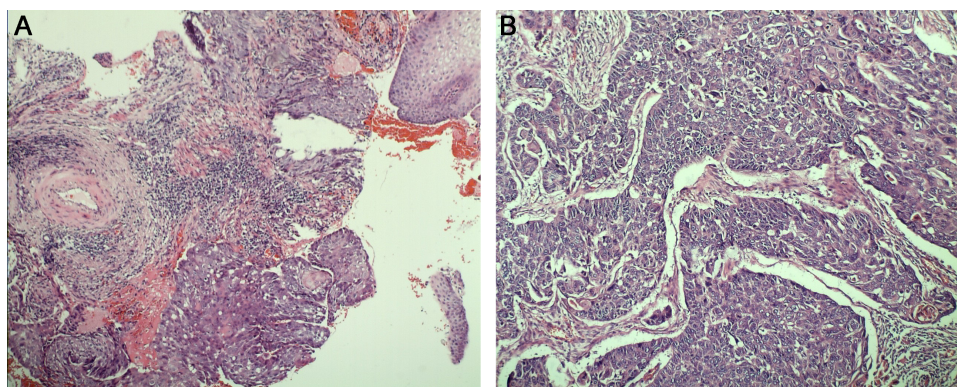


Figure 1 Endoscopy biopsy (A) suggested esophageal squamous cell carcinoma; postoperative pathology (B) demonstrated moderately differentiated esophageal squamous cell carcinoma invading the full thickness of the esophageal wall.

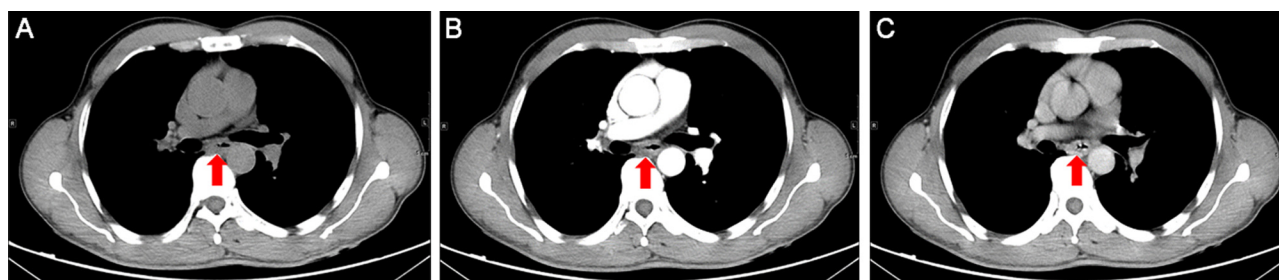


Figure 2 The initial thoracic CT indicated that the middle thickening esophageal wall was markedly enhanced. Plain scan (A); arterial phase (B); venous phase (C).

Note: Red arrows represent the lymph node.

Abbreviation: CT, Computed tomography.

After treatment with apatinib for 1.4 months, CT examination showed cervical lymph node was decreased, without tumor recurrence or metastasis in other sites (Figure 3D). These results suggested that the patient achieved partial response (PR) according to the Response Evaluation Criteria in Solid Tumors (RECIST) 1.1 standard. There was no sign of progression in the patient's conditions until we reported this case and now the PFS was 7.5 months (until March 10, 2018). The treatment schedule is given in Figure 4.

After apatinib was administrated for two weeks, hypertension (grade III) appeared, so the dose of apatinib was

adjusted from 850 to 500 mg. During the apatinib treatment cycles, the patient developed mild-to-moderate hypertension and hand-foot syndromes. After treating with appropriate agents, no other anti-angiogenesis-associated adverse event (AE) was reported. Toxicity was evaluated and graded according to the NCI-CTC for Adverse Events, version 4.0.

The study was approved by the Medical Ethics Committee of the Affiliated Lianyungang Hospital of Xuzhou Medical University and written informed consent was obtained from the patient. The patient also provided his written informed

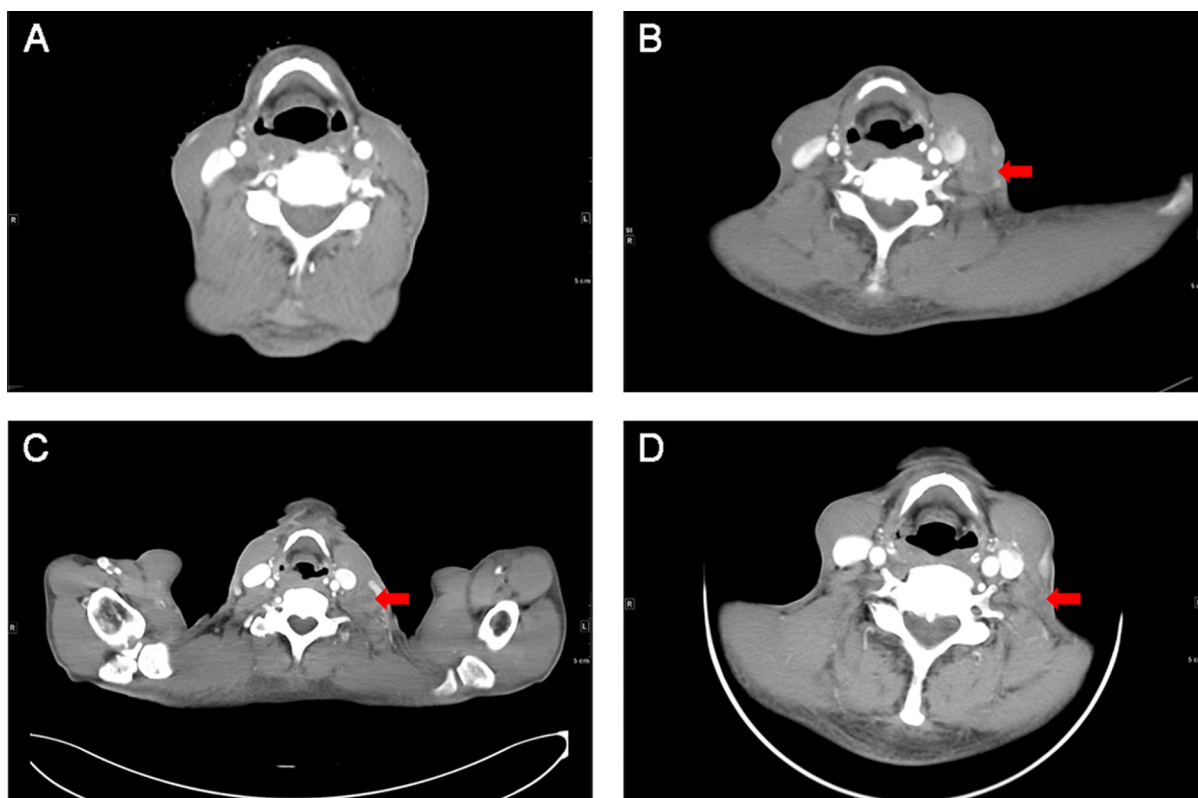


Figure 3 Cervical CT showed no lymphadenopathy before surgery (A); CT showed a significantly enlarged lymph node in the left neck which prompted PD after first-line chemotherapy (B); CT revealed the left cervical lymph node was not reduced after radiotherapy and irinotecan treatment (C); CT examination showed the swollen lymph nodes significantly narrowed and the border was not clear, suggesting that the patient achieved PR (D).

Note: Red arrows represent the lymph node.

Abbreviations: CT, Computed tomography; PD, disease progression; PR, partial response.

Schedule of treatment

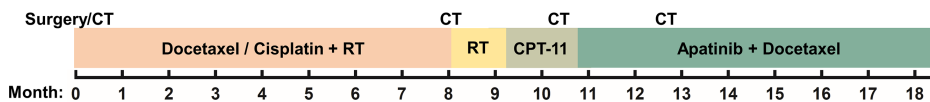


Figure 4 The treatment schedule of the patient.

Abbreviations: CT, computed tomography; RT, radiotherapy; CPT-11, irinotecan.

consent for the case details and accompanying images to be published in this case study.

Discussion

To date, there has been no effective therapy as standard third-line therapy for improving the survival of ESCC patients due to its aggressive nature. To the best of our knowledge, this is the first case report on apatinib combined with docetaxel for ESCC treatment achieving PFS of 7.5 months. In addition, the patient tolerated well to the treatment, and reported satisfactory quality of life.

As early as 1971, professor Folkman suggested that tumor growth relied on the formation of tumor blood vessels, thus “anti-tumor angiogenesis” would be a promising strategy for treating tumors.¹¹ Based on previous researches, multiple antiangiogenic agents have been developed and studied in clinical trials. In the RAINBOW clinical trial, ramucirumab (a monoclonal antibody of VEGFR-2) combined with paclitaxel significantly increased OS compared with placebo combined with paclitaxel in advanced gastric or gastro-esophageal junction adenocarcinoma.²¹ This agent was also advocated in treatment guidelines for esophageal adenocarcinoma.²² Some clinical trials have demonstrated the effectiveness of bevacizumab as neoadjuvant therapy in ESCC.^{23,24} However, there are very few studies on anti-angiogenesis agents for metastatic ESCC.

Apatinib is a novel orally taken small molecular TKI, exerting its anti-angiogenesis function through highly and selectively competing with intracellular VEGFR-2's adenosine triphosphate (ATP) binding sites. Thus, downstream signaling could be blocked to inhibit neovascularization in tumor tissue. The Phase II clinical trial of apatinib reported that median OS was increased to 4.83 months with apatinib 850 mg group, 4.27 months with apatinib 425 mg group, compared with 2.50 months with placebo group ($P < 0.001$ and $P = 0.0017$, respectively).¹⁵ Similar results were confirmed by the Phase III study (median OS was 6.5 months in the apatinib 850 mg vs 4.7 months in the placebo group, $P = 0.0149$; HR=0.709, 95% CI 0.537–0.937, $P = 0.0156$).¹⁶ The efficacy of apatinib on 62 advanced ESCC patients who

failed the standard therapy was retrospectively analyzed,²⁵ among which, 15 received PR, while 31 achieved stable disease, with a manageable safety profile. These results demonstrated the preliminary efficacy and safety of apatinib for advanced ESCC.

Although antiangiogenic therapies show remarkable antitumor activity, their efficacy is limited as monotherapy. Hence, these agents have been integrated with conventional chemotherapy or radiotherapy to enhance antitumor activity.^{26,27} In our case, the patient received the docetaxel plus cisplatin regimen as first-line treatment and a PFS of 8.0 months was achieved. After the failure of standard chemotherapy and local radiation therapy of metastatic lesion, the patient still showed performance status score of 1, with strong willingness to continue the treatment. Thus, the docetaxel plus apatinib was administrated as salvage treatment strategy. Beyond our expectation, for this patient, the PFS of third-line treatment can be favorably comparable with the first-line treatment, indicating a potentially synergistic effect between apatinib and docetaxel chemotherapy. Moreover, recent research showed that the cytotoxicity of paclitaxel could be significantly enhanced by apatinib in vitro and in vivo by reversing chemotherapy-resistance through blocking the function of multiple ATP-binding cassette transporters.²⁸ Furthermore, apatinib can markedly increase the intracellular accumulation of conventional chemotherapy agents in side population cells sorted from K562 cells,²⁹ and cisplatin-resistant non-small-cell lung carcinoma A549 cell could be resensitized through suppressing extracellular signal-regulated kinase signaling pathway.³⁰ Currently, there are also multiple ongoing clinical trials investigating on apatinib for molecular targeted therapy in ESCC (Table 1).

The common AEs of apatinib were hypertension and hand-foot syndrome.³¹ According to the instruction of apatinib, we first prescribed the patient with apatinib of 850 mg daily. Then, grade III hypertension was observed, leading to dosage adjustment to 500 mg. The AEs were controllable and tolerable. The bioavailability of apatinib in ESCC patients was noteworthy higher than those in patients with gastric cancer, which might be attributed to the fact

Table 1 Selected ongoing trials with apatinib in metastatic ESCC

Clinical trial identifier	Phase	Setting	Treatment regimen	Primary endpoint	Status
NCT03224221	II	Second line	Apatinib+chemotherapy	One-year survival rate	Recruiting
NCT02645864	I	Second line	Apatinib+irinotecan	DLT, MTD	Recruiting
NCT03251417	II	Second line	Apatinib+irinotecan	DCR	Recruiting
NCT03274011	II	Third line	Apatinib	PFS	Recruiting
NCT02683655	II	Second line	Apatinib	PFS	Ongoing but not recruiting
NCT02976896	II	Second line	Apatinib	DCR	Recruiting
NCT03193424	II	Second line	Apatinib+docetaxel	PFS	Recruiting
NCT03320629	II	First line	Apatinib+S-1+radiotherapy	PFS	Recruiting
NCT03170310	II	Second line	Apatinib	PFS	Recruiting

Abbreviations: DLT, dose-limiting toxicity; MTD, maximum tolerance dose; DCR, disease control rate; PFS, progression free survival.

that most gastric cancer patient had a subtotal gastrectomy surgery history.³²

In conclusion, apatinib with concurrent docetaxel had potential efficacy for metastatic ESCC patients as a salvage treatment and the prospective clinical trials are ongoing (Table 1).

Acknowledgments

We thank the patients and all investigators involved in this study. The first authors of this manuscript are Li-Jun Liang, Yi-Xuan Wen, and You-You Xia.

Disclosure

The authors report no conflicts of interest in this work.

References

- Torre LA, Bray F, Siegel RL, et al. *CA: a cancer journal for clinicians*. 2015;65(2):87–108.
- Chen W, Zheng R, Baade PD, et al. Cancer statistics in China, 2015. *CA Cancer J Clin*. 2016;66(2):115–132.
- Hayashi K, Ando N, Watanabe H, et al. Phase II evaluation of protracted infusion of cisplatin and 5-fluorouracil in advanced squamous cell carcinoma of the esophagus: a Japan Esophageal Oncology Group (JEOG) Trial (JCOG9407). *Jpn J Clin Oncol*. 2001;31(9):419–423.
- Bleiberg H, Conroy T, Paillot B, et al. Randomised phase II study of cisplatin and 5-fluorouracil (5-FU) versus cisplatin alone in advanced squamous cell oesophageal cancer. *Eur J Cancer*. 1997;33(8):1216–1220.
- Huang J, Zhou Y, Zhang H, et al. A phase II study of biweekly paclitaxel and cisplatin chemotherapy for recurrent or metastatic esophageal squamous cell carcinoma: ERCC1 expression predicts response to chemotherapy. *Med Oncol*. 2013;30(1):343.
- Kato K, Tahara M, Hironaka S, et al. A phase II study of paclitaxel by weekly 1-h infusion for advanced or recurrent esophageal cancer in patients who had previously received platinum-based chemotherapy. *Cancer Chemother Pharmacol*. 2011;67(6):1265–1272.
- Muro K, Hamaguchi T, Ohtsu A, et al. A phase II study of single-agent docetaxel in patients with metastatic esophageal cancer. *Ann Oncol*. 2004;15(6):955–959.
- Burkart C, Bokemeyer C, Klump B, Pereira P, Teichmann R, Hartmann JT. A phase II trial of weekly irinotecan in cisplatin-refractory esophageal cancer. *Anticancer Res*. 2007;27(4C):2845–2848.
- Mühr-Wilkenshoff F, Hinkelbein W, Ohnesorge I, et al. A pilot study of irinotecan (CPT-11) as single-agent therapy in patients with locally advanced or metastatic esophageal carcinoma. *Int J Colorectal Dis*. 2003;18(4):330–334.
- Hanahan D, Weinberg RA. Hallmarks of cancer: the next generation. *Cell*. 2011;144(5):646–674.
- Ferrara N, Adamis AP. Ten years of anti-vascular endothelial growth factor therapy. *Nat Rev Drug Discov*. 2016;15(6):385–403.
- Luz CCF, Noguti J, Araújo L, et al. Expression of VEGF and Cox-2 in Patients with Esophageal Squamous Cell Carcinoma. *Asian Pac J Cancer Prev*. 2018;19(1):171–177.
- Chen M, Cai E, Huang J, Yu P, Li K. Prognostic value of vascular endothelial growth factor expression in patients with esophageal cancer: a systematic review and meta-analysis. *Cancer Epidemiol Biomarkers Prev*. 2012;21(7):1126–1134.
- Tian S, Quan H, Xie C, et al. YN968D1 is a novel and selective inhibitor of vascular endothelial growth factor receptor-2 tyrosine kinase with potent activity in vitro and in vivo. *Cancer Sci*. 2011;102(7):1374–1380.
- Li J, Qin S, Xu J, et al. Apatinib for chemotherapy-refractory advanced metastatic gastric cancer: results from a randomized, placebo-controlled, parallel-arm, phase II trial. *J Clin Oncol*. 2013;31(26):3219–3225.
- Li J, Qin S, Xu J, et al. Randomized, Double-Blind, Placebo-Controlled Phase III Trial of Apatinib in Patients With Chemotherapy-Refractory Advanced or Metastatic Adenocarcinoma of the Stomach or Gastroesophageal Junction. *J Clin Oncol*. 2016;34(13):1448–1454.
- Zhang L, Shi M, Huang C, et al. A phase II, multicenter, placebo-controlled trial of apatinib in patients with advanced nonsquamous non-small cell lung cancer (NSCLC) after two previous treatment regimens. *Journal of Clinical Oncology*. 2012;30(15_suppl):7548.
- Hu X, Zhang J, Xu B, et al. Multicenter phase II study of apatinib, a novel VEGFR inhibitor in heavily pretreated patients with metastatic triple-negative breast cancer. *Int J Cancer*. 2014;135(8):1961–1969.
- Hu X, Cao J, Hu W, et al. Multicenter phase II study of apatinib in non-triple-negative metastatic breast cancer. *BMC Cancer*. 2014;14:820.
- Li CM, Liu ZC, Bao YT, Sun XD, Wang LL. Extraordinary response of metastatic pancreatic cancer to apatinib after failed chemotherapy: A case report and literature review. *World J Gastroenterol*. 2017;23(41):7478–7488.
- Wilke H, Muro K, et al; RAINBOW Study Group, et al. Ramucic-rumab plus paclitaxel versus placebo plus paclitaxel in patients with previously treated advanced gastric or gastro-oesophageal junction adenocarcinoma (RAINBOW): a double-blind, randomised phase 3 trial. *Lancet Oncol*. 2014;15(11):1224–1235.
- Ajani JA, D'Amico TA, et al. National comprehensive cancer network, et al. Esophageal and esophagogastric junction cancers, version 1. 2015. *J Natl Compr Canc Netw*. 2015;13(2):194–227.

23. Idelevich E, Kashtan H, Klein Y, et al. Prospective phase II study of neoadjuvant therapy with cisplatin, 5-fluorouracil, and bevacizumab for locally advanced resectable esophageal cancer. *Onkologie*. 2012; 35(7–8):427–431.
24. Bendell JC, Meluch A, Peyton J, et al. A phase II trial of preoperative concurrent chemotherapy/radiation therapy plus bevacizumab/erlotinib in the treatment of localized esophageal cancer. *Clin Adv Hematol Oncol*. 2012;10(7):430–437.
25. Li J, Wang L. Efficacy and safety of apatinib treatment for advanced esophageal squamous cell carcinoma. *Onco Targets Ther*. 2017;10: 3965–3969.
26. Cheng X, Xu Z, Chen J. Apatinib to enhance chemosensitivity of gastric cancer to paclitaxel and 5-fluorouracil. *J Clin Oncol*. 2017;35(15_suppl): e15545.
27. Zhou F, Feng S, Zhang J, Aa J, Wang G. Combined treatment of apatinib with docetaxel in non-small-cell lung cancer mice and its material basis of pharmacokinetics. *Journal of Clinical Oncology*. 2017;35(15_suppl): e14069.
28. Yj M, Liang YJ, Huang HB, et al. Apatinib (YN968D1) reverses multi-drug resistance by inhibiting the efflux function of multiple ATP-binding cassette transporters. *Cancer Res*. 2010;70(20):7981–7991.
29. Tong XZ, Wang F, Liang S, et al. Apatinib (YN968D1) enhances the efficacy of conventional chemotherapeutic drugs in side population cells and ABCB1-overexpressing leukemia cells. *Biochem Pharmacol*. 2012;83(5):586–597.
30. Liu ZL, Jin BJ, Cheng CG, et al. Apatinib resensitizes cisplatin-resistant non-small cell lung carcinoma A549 cell through reversing multidrug resistance and suppressing ERK signaling pathway. *Eur Rev Med Pharmacol Sci*. 2017;21(23):5370–5377.
31. Li J, Zhao X, Chen L, et al. Safety and pharmacokinetics of novel selective vascular endothelial growth factor receptor-2 inhibitor YN968D1 in patients with advanced malignancies. *BMC Cancer*. 2010;10:529.
32. Yu M, Gao Z, Dai X, et al. Population Pharmacokinetic and Covariate Analysis of Apatinib, an Oral Tyrosine Kinase Inhibitor, in Healthy Volunteers and Patients with Solid Tumors. *Clin Pharmacokinet*. 2017; 56(1):65–76.

OncoTargets and Therapy

Publish your work in this journal

OncoTargets and Therapy is an international, peer-reviewed, open access journal focusing on the pathological basis of all cancers, potential targets for therapy and treatment protocols employed to improve the management of cancer patients. The journal also focuses on the impact of management programs and new therapeutic agents and protocols on

Submit your manuscript here: <http://www.dovepress.com/oncotargets-and-therapy-journal>

patient perspectives such as quality of life, adherence and satisfaction. The manuscript management system is completely online and includes a very quick and fair peer-review system, which is all easy to use. Visit <http://www.dovepress.com/testimonials.php> to read real quotes from published authors.

Dovepress