

Emergomycosis in Africa: Time to Pay Attention to This Emerging Deadly Fungal Infection

Chibuikwe Ibe¹, Nicholas P Mnyambwa^{2,3}, Sayoki G Mfinanga²

¹Department of Microbiology, Faculty of Biological Sciences, Abia State University, Uturu, Nigeria; ²National Institute for Medical Research, Muhimbili Research Centre, Dar es Salaam, Tanzania; ³Alliance for Africa Health and Research (A4A), Dar es Salaam, Tanzania

Correspondence: Chibuikwe Ibe, Email c.ibe@abiastateuniversity.edu.ng

Abstract: Emergomycosis is an emerging deadly infectious disease caused primarily by a little-known airborne pathogen *Emergomycetes africanus*, which can cause clinical management challenge especially in patients with advanced HIV disease. This minireview describes *Es. africanus* as the main cause of emergomycosis in Africa as well as considers contributing factors to the difficulties encountered in managing this infection. Emergomycosis is common in HIV-positive persons with low CD4 lymphocyte count and has an estimated fatality of 50%. The infection exhibits airborne transmission with pulmonary and extrapulmonary manifestations leading to skin lesions. However, the pathogenesis of *Es. africanus* is still poorly understood. The management of the infection is complicated due to lack of defined diagnostic and therapeutic guidelines. Limited expertise, poor research funding, and lack of awareness and national surveillance are thought to impact the recognition and prioritisation of the infection. These factors may ultimately assign emergomycosis a ‘neglected infection status’ even as it is suspected to be prevalent in more African countries than previously recognised. Increased awareness and integrated and targeted strategies such as mobilising manpower in clinical mycology are of paramount importance in managing emergomycosis in Africa and beyond.

Keywords: emergomycosis, *Es. africanus*, epidemiology, pathogenesis, HIV

Introduction

Fungal pathogens are constantly evolving perhaps to develop new strategies to thrive in novel host niches and harsh environment leading to new species increasingly associated with human infections. Consequently, managing the resulting infections becomes a challenge. Emergomycosis is one of such observed infections caused by the recently described novel thermal dimorphic fungi genera, *Emergomycetes* which is closely related to *Histoplasma*, *Blastomyces*, and *Paracoccidioides*.¹ The genus *Emergomycetes* is made up of 5 unique species: *Emergomycetes pasteurianus*, *Emergomycetes africanus*, *Emergomycetes canadensis*, *Emergomycetes orientalis*, and *Emergomycetes europaeus*.^{1,2} Emergomycosis is common in immunocompromised persons and characterised with widespread skin lesion and pulmonary disease.³ Other clinical manifestations of the infection become apparent in HIV patients following the initiation of ART.⁴ Cases of emergomycosis reported are mainly due to *Es. africanus*⁵ which accounts for majority of the diagnosed cases in Africa.⁶

Emergomycosis is an airborne infection which can be diagnosed using histological findings, serology, and/or molecular identification; however, no well-streamlined guideline is available for emergomycosis diagnosis. Consequently, clinicians and dermatologists usually misdiagnose the lesions for other conditions ranging from varicella to scrofluoderma,³ which can significantly affect treatment outcome.

In Africa, *Es. africanus* causes systemic infection associated with skin lesions^{3,4} with an estimated case fatality rate of 50% especially among patients with advanced HIV disease (Table 1).³ In a recent study, 96% of patients with systemic emergomycosis infection had low CD4 lymphocyte counts (median CD4 lymphocyte count 16 cells/ μ L).³ The infection is now recognised as the most prevalent endemic fungal infection in South Africa with cases reported in 6 of the 9 provinces. Emergomycosis has also been reported in a Lesotho³ and a Ugandan patient (caused by *Es. pasteurianus*).⁷

Table 1 Description of Characteristics, Diagnosis, Treatment, and Outcome of Reported Cases of Emergomycosis Infection in Africa

^a Case	Patient Characteristic	CD4 Count (Cells/ μ L)	<i>Emergomyces</i> Species	^d Diagnostic Method	^b Treatment	Outcome for Emergomycosis	Author	Reference
Southern Africa – South Africa								
1	HIV + with progressive lesions on the nose which worsened following ART initiation	32	<i>Es. Africanus</i>	Culture and sequencing of ITS region	ART was initiated. Patients received intravenous amp B deoxy and prednisone, then oral itraconazole maintenance for a year	1/1	Crombie et al 2018	[8]
2	2 HIV - with disseminated emergomycosis. 1 was immunocompetent and the other was receiving immunosuppressive therapy due to renal transplant	-	<i>Emergomyces</i> species	Culture (misidentified <i>Blastomyces</i> species in 1) and PCR assay	Intravenous amp B deoxy and prednisone, then oral itraconazole maintenance	1/2	Heys et al 2014	[9]
3	3 HIV + with disseminated skin lesions. 1 had TB coinfection and non-TB mycobacteria while 1 had non-TB mycobacteria. 1 was ART naïve and 2 were defaulting ART	≤ 5	<i>Emergomyces</i> species	Culture (misidentified as <i>Trichosporon</i> species in 2 and as <i>Histoplasma capsulatum</i> in 1) and sequencing of ITS region	ART was either initiated or restarted. Patients received a combination of fluconazole, amp B deoxy and itraconazole.	2/3	Hougenhouck-Tulleken et al 2014	[10]
24	13 HIV + were diagnosed of emergomycosis and the rest were caused by other fungal species and only 2 had TB coinfection. The 13 had widespread skin lesions. Lesions worsened after ART initiation in 3	Median 16 (interquartile range, 10–44).	<i>Emergomyces</i> species were identified in the 13 while the others had <i>Histoplasma capsulatum</i> , <i>Sporothrix schenckii</i> , <i>Cryptococcosis</i> and <i>Candida</i> species.	Histology examination Culture and sequencing of ITS region	ART was either initiated, continued, or modified. Patients received intravenous amp B deoxy and then itraconazole maintenance	3/13	Kenyon et al 2013	[11]

54 ^c (18 cases have previously been reported in rows 2–4)	51 HIV +, 1 receiving immunosuppressant following renal transplant and 2 immunocompetent. All patients had systemic infection: 50 had skin lesions and 42 had pulmonary infection. 15 has TB coinfection, non-TB mycobacteria was diagnosed in 3 and 1 had both, 27 already on ART treatment and 24 naive In a patient, lesions became larger and numerous following ART treatment HIV + with other comorbidities	Median 16 (interquartile range, 6–40).	<i>Emergomyces</i> species were identified in 52	Histology examination Culture and sequencing of ITS region. PCR probe	ART was either initiated, continued, or modified. Patients received different drug combinations: amp B deoxy, and itraconazole maintenance, caspofungin and amphotericin B deoxy, and fluconazole incidentally prescribed.	26/36 including 8 deaths from those that did not receive antifungal	Schwartz et al 2015	[3]
1		12	<i>Emergomyces</i> species	Histology examination marrow Culture and sequencing of ITS region	ART was initiated. Fluconazole was commenced on assumption of hospital acquired infection before switching to amp B deoxy, and itraconazole maintenance	0/1	Lochan et al 2015	[12]

(Continued)

Table 1 (Continued).

^a Case	Patient Characteristic	CD4 Count (Cells/ μ L)	<i>Emergomyces</i> Species	^d Diagnostic Method	^b Treatment	Outcome for Emergomycosis	Author	Reference
34 (14 had emergomycosis)	All had HIV + with widespread skin lesions. In 25 with suspected systemic mycoses, 20 had fungal infection while no diagnosis could be made in 5. In the remaining 9 diagnosis of other infections including TB in 1 was made. Skin lesions either emerged or worsened in 16 with systemic mycoses following ART treatment.	\leq 100 Median 28 (interquartile range, 10–45)	<i>Es. africanus</i> was identified in 14 while <i>H. capsulatum</i> and <i>S. schenckii</i> were identified in 3 each.	Histopathology examination Clinical and clinicopathology assessments Culture and sequencing of ITS region	ART was either initiated, restarted, continued, or modified. Patients received amp B deoxy and itraconazole maintenance	6 ^e died (3/14)	Schwartz et al 2017	[4]
East Africa – Uganda								
1	HIV + with disseminated skin lesions. Skin lesions increased following treatment with antifungal and ART	140	<i>Es. pasteurianus</i>	Histology examination qPCR of ITS region and sequencing	ART continued. Fluconazole was started for suspected cryptococcosis before itraconazole was resumed	0/1	Rooms et al 2019	[13]

Notes: ^aThe true burden of emergomycosis is grossly underestimated as well as the TB coinfections. The interest was on emergomycosis. Targeting emergomycosis, a lot of the studies here have important limitations including in sample size, patient recruitment strategy, choice of antifungal therapy, overestimation of survival due to censoring, etc., that may not allow the estimation of prevalence, and limit conclusions on epidemiology, and attribution of mortality. However, the one thing all studies share is that the pathogen is deadly in those with HIV-induced immune impairment which Africa is struggling with the highest number - more than 70% - in the world, and the infection may be misdiagnosed, and missed diagnosis is common in Africa. ^bTreatment described here is for emergomycosis alone. Current treatment recommendations rely on observational studies and expert opinion due to the complex nature of the clinical manifestations. ^cOne of the surviving patients was from Lesotho. ^dMisdiagnosis and missed diagnosis are common. ^eOut of the 25 with systemic mycoses 6 died that is 3 died from the 14 with emergomycosis.

Abbreviations: HIV+, Human immunodeficiency virus positive; HIV-, Human immunodeficiency virus negative; ITS, internal transcribed spacer; ART, antiretroviral therapy; Amp B deoxy, amphotericin B deoxycholate; TB, tuberculosis.

Currently, South Africa has the highest burden of emergomycosis in the world. The reason for this concentration is unknown; however, it can be reasonably presumed to be due to the high prevalence of HIV with only less than half of those eligible for ART accessing it.⁸ In addition, it could be because South Africa has the most advanced diagnostic capability in Africa besides the high clinical awareness and disease surveillance systems in the country.

Es. africanus can infect immunocompetent individuals (Table 1).⁹ It is not clear whether the disease results from exposure to higher bioload of *Es. africanus*, infection with more virulent strains, or undiagnosed immune impairment. Limited clinical expertise on the management of this infection along with lack of specific diagnostic and therapeutic guidelines poses challenge to our current healthcare system's responsiveness. Most importantly, there is generally a systemic lack of awareness of the infection and invasive fungal infections (IFIs) among clinicians, which further reduces proactive approaches to this emerging condition. This paper calls for an increase in awareness, investment, and targeted approach to improve the management of emergomycosis in order to give this deadly infection the deserved priority as it has almost fulfilled the criteria for a neglected disease status.

Infection and Manifestation

Emergomycosis is an airborne infection that is amongst the common complications in HIV-related immunocompromised patients which can worsen with antifungal and antiretroviral therapies (ART).⁸

The environmental reservoir of *Emergomycetes* is not known. However, the infection is thought to begin through the inhalation of *Emergomycetes* species conidia dispersed by the saprophytic mycelia in the soil¹⁴ which then undergoes temperature-dependent transition from vegetative structures that lodge in the lungs to budding yeasts that cause pulmonary infection and upon haematogenous dissemination, extrapulmonary infections (Figure 1).

Emergomycosis also affects patients with other immune impairments including those with haematological malignancies, solid organ transplant, and those using immunosuppressants;^{2,9} however, little is known about the infection

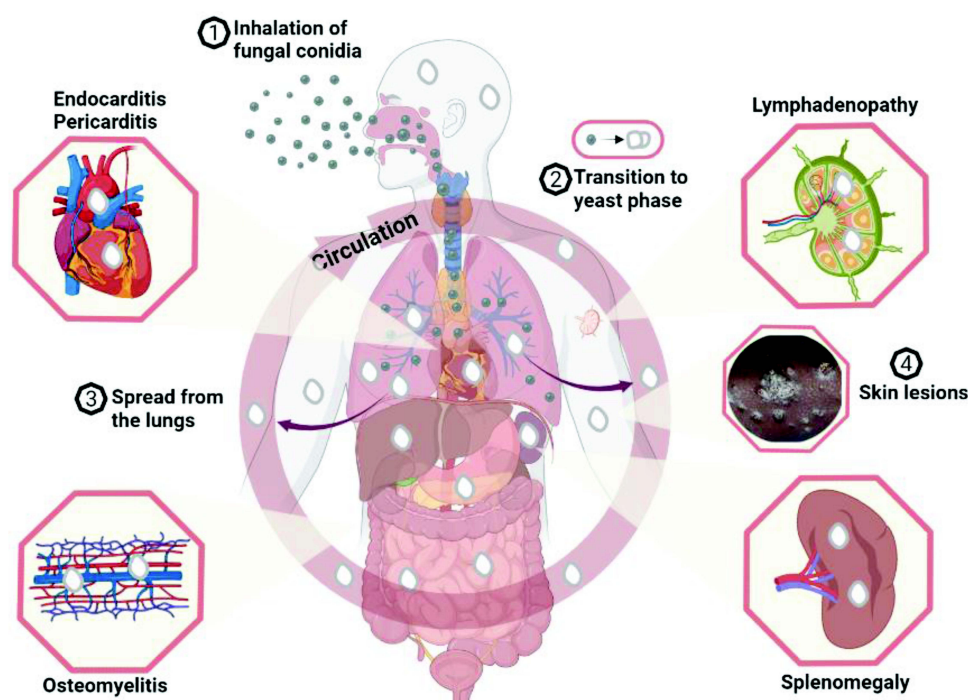


Figure 1 A model for *Emergomycetes* infection and clinical manifestation. *Emergomycetes* species (*Es. africanus*, *Es. pasteurianus*, *Es. canadensis*, *Es. europaeus* and *Es. orientalis*) have been reported - using *Es. africanus*⁵ - to exist in the soil as saprophytic moulds that produce spores (conidia). The conidia adapt for wind dispersal and can remain airborne for lengthy periods. Humans inhale the conidia (1) which then lodged in the terminal regions of the lungs where they undergo morphological transition to the infective phase - budding yeast (2). The yeast phase causes pulmonary infection in susceptible individuals especially in patients with advanced HIV infection which can lead to disseminated infections. From the lungs, the yeast cells can spread (3) throughout the body through haematogenous dissemination in neutrophils and infect virtually any organ including the skin, heart, bone marrow, spleen, and lymph node. Figure created with BioRender.com.

pathogenesis, but the infection manifestation is fairly well understood. Patients with *Es. africanus* infection often present with skin lesions manifesting as verrucous lesions, papules, plaques, nodules, or ulcers that are widespread.¹¹ Emergomycosis lesions are seen to become more numerous or erupt following ART initiation, suggesting that unmasking of immune reconstitution inflammatory syndrome (IRIS) is often involved.⁴ Pulmonary infection is common, and chest radiograph shows manifestations that include effusions, consolidation, reticulonodular disease, or lymphadenopathy.³ Emergomycosis has also been reported to affect other organs, such as bone marrow, gastrointestinal tract, and the liver.

Pathogenesis

Once the pathogen's conidia are inhaled, they are lodged in the terminal regions of the lungs where they undergo morphological transition to budding yeasts which are the infective phase. The phenotypic switch is similar to the mechanisms regulating dimorphism in *Blastomyces dermatitidis* and *Histoplasma capsulatum*, though genes regulating the process in *Emergomyces* species have yet to be identified.

Genomic analysis revealed that virulence factors are conserved in *Es. africanus* and *Es. pasteurianus*¹⁵ (causes emergomycosis in Europe). The roles of the virulence genes in pathogenesis are still unknown. However, *Es. africanus* expresses urease,¹⁶ a known virulence factor in *Cryptococcus neoformans*. Experiments in mice demonstrated dose-dependent susceptibility to emergomycosis infection.¹⁴ An infectious dose of 10^2 conidia was unable to cause infection in a mice model of systemic emergomycosis; however, *Es. africanus* was recovered from their livers and spleens. *Es. africanus* was fatal at an infectious dose of 10^6 conidia.¹⁴ Currently, research in emergomycosis and *Es. africanus* is limited and understanding the pathogen's pathogenicity traits holds potential in understanding the infection, its diagnosis and treatment.

Diagnosis and Setbacks

In spite of the ubiquity and fatal nature of many fungal infections, the field of medical mycology has been heavily underfunded compared to research in bacteriology, parasitology, or virology.^{17,18} This deficiency exists despite the more than 1.2 billion cases of fungal infection reported worldwide with about 2 million fatalities per annum. As a result of this chronic underfunding, medical mycologists have been left with limited tools to diagnose and treat emergomycosis. Additionally, the global response to the SARS-CoV-2 pandemic has left the existing healthcare structure for fungal infections in a rather bad state in terms of diagnostics, therapeutics, and funding.¹⁹ The unavailability of appropriate diagnostics may explain the under-reporting of emergomycosis cases in other parts of Africa. Current diagnostics present a lot of setbacks (Table 1 and Table 2):²⁰ Firstly, histology or tissue culture can be invasive, slow, and insensitive with *Es. africanus* that is indistinguishable from *Histoplasma* species when diagnosing these infections in patients with advanced HIV conditions (Table 2) and even in an otherwise health individual.²¹ Microscopically, *Emergomyces* mycelia morphology is also indistinguishable from *Sporothrix schenckii*, though this does not form a basis for diagnosis. Serological tests or serum biomarkers for early diagnosis are not yet available for emergomycosis. Cross-reactivity has been observed with urine *Histoplasma* galactomannan antigen test, and PCR-based assays have not been validated for emergomycosis. *Emergomyces* species have been reported to cross-react with the available DNA probe for *B. dermatitidis* (Table 2). Sequencing of rDNA internal transcribed spacer region is the most reliable diagnostic method, but the technology remains sophisticated and expensive for routine diagnosis in Africa. However, the current effort to expand genomics tools and research in Africa in response to the Covid-19 pandemic could be useful in addressing some of the challenges to emergomycosis diagnosis and treatment.

Treatment and Antifungal Availability

Even after a successful diagnosis, management of this fungal infection remains difficult (Table 1). Surgical debridement may be necessary to treat severely infected and necrotic skin, but this can lead to disfigurement.^{3,4,8} However, systemic antifungal therapy is the mainstay of treatment to restore severely infected skin to normal. Amphotericin B, a nephrotoxic antifungal, is the first-line therapy for emergomycosis, usually for 1–2 weeks followed by itraconazole or similar azole for maintenance (Table 1).⁶ Currently, according to the WHO guideline for cryptococcosis, liposomal amphotericin B is preferred because of its low toxicity and substituted for deoxycholate amphotericin B for treating emergomycosis²⁷ but it is

Table 2 Some Diagnostic Characteristics of Emergomycosis Pathogen

	Emergomycosis	Histoplasmosis
Histological findings	Skin biopsies show intracytoplasmic narrow base budding yeast cells measuring 2–5 µm with multinucleated giant cells, histiocytes, and plasma cells in the chronic suppurative dermal infiltrates. ^{20,22} In severely immunocompromised individuals the presence of immune cells may vary from very few to absent. ²⁰ In cases of IRIS a significantly mixed dermal inflammatory infiltrate can be seen.	Skin biopsies come with granulomatous inflammatory response with necrosis cessation showing phagocytosed narrow base budding yeast cells measuring 2–4 µm with nonrefractile cell walls and macrophages and histiocytes. ^{22,23} Yeast cells though seen in the extracellularly spaces are mostly seen phagocytosed by histiocytes and macrophages.
Serology	Cross-reaction has been seen with serological test for other fungi. Emergomycosis patients have been shown to react to 1,3-β-D-glucan (1 out of 3 patients reacted and urine <i>Histoplasma</i> galactomannan antigen tests (1 out of 4 patients reacted). ³ A study by Maphanga et al ²⁴ has also shown emergomycosis due to <i>Es. africanus</i> react to <i>Histoplasma</i> galactomannan antigen.	Enzyme Immunoassay and sandwich radioimmunoassay are serological tests available for probable and sometimes definitive histoplasmosis tests. ²⁵
Molecular identification	PCR amplification and sequencing is the most reliable though not standardised method of emergomycosis diagnosis. The fungal locus ITS1–5.8S–ITS2 with its universal primer pairs: ITS5 and ITS4, and the partial LSU region of rDNA with its universal primer pairs: and LROR and LR5, are used, followed with sequencing. This is followed with pairwise alignment by querying a relevant database such NCBI. However, <i>Emeromyces</i> species can cross-react with commercially available DNA probe for <i>B. dermatitidis</i> . ²⁶	Molecular identification of <i>Histoplasma</i> species has not been complicated with cross-reacting probes for other organisms. ²⁵

Abbreviations: NCBI, national centre for biotechnology information; LSU, large subunit; ITS, internal transcribed spacer; rDNA, ribosomal DNA.

prohibitively costly or unavailable in most resource poor settings. Only 7 countries (Benin, South Africa, Egypt, Tanzania, Mauritania, Eswatini and Ethiopia) have access to liposomal amphotericin B in Africa to date²⁸ (www.gaffi.org). The few alternatives¹⁴ are either unavailable or expensive (voriconazole, itraconazole) or completely out of reach (posaconazole) in Africa. Currently, treatment recommendations, in addition to antifungal therapy, rely on expert opinion and observational studies because of the complex clinical manifestations of emergomycosis.

Epidemiology and Clinical Surveillance

The seriousness of the already diagnosed cases of emergomycosis in South Africa and the possibility that the infection might be more prevalent in more African countries than it is known should bring attention to the pathogen. The true burden of emergomycosis in South Africa and its socioeconomic impacts are unknown. National surveillance data in South Africa and other African countries remain unavailable; however, the pathogen is airborne which brings a certain level of predictability and cause for concern. The inherent ability of airborne *Es. africanus* vegetative structures to survive in the air for long periods of time⁵ and the potential for long-distance dispersal indicate that the pathogen may be common across African countries. These potentials suggest that the infection might be part of the healthcare problems most sub-Saharan African countries currently face but fail to recognize. The last published report on emergomycosis in Africa was in 2019 even though there is visible manifestation of skin lesions in HIV-positive persons in HIV care centres in most sub-Saharan African countries which may be due to *Emergomyces* species.

Research Efforts and Gaps

A significant amount of work has been done to inform our current understanding of emergomycosis. The molecular and cellular mechanisms that govern the infection pathogenesis and host immune response or susceptibility to *Emergomyces* species remain a mystery and an interesting research focus. Our current understanding of the

manifestation, management of the disease, and risk factors associated with the infection and its epidemiology remain elusive. Concomitantly, there is a need for the development, testing, and uptake of accurate diagnostic tools, development of treatment guidelines, and increased access to effective antifungals. Appropriate timing of ART commencement after a positive emergomycosis diagnosis in ART naïve patients' needs to be defined, as a measure to mitigate the development of IRIS. Several possible interactions occur between ART and antifungals; thus, optimal dose adjustment must be established. Finally, epidemiological surveillance of emergomycosis is important to understand the distribution and then mount proper responses especially in the African context before it becomes a major healthcare crisis.

Perspective

Emergomycosis is an emerging infection, that is rapidly achieving a “neglected infection status” though not there yet. The infection is becoming prevalent in Africa. In our opinion, the time for action on emergomycosis is now. The possibility that the infection is common in most African countries is high due to the high burden of HIV infection, misdiagnosis, and missed diagnosis due to both limited expertise and laboratory infrastructure in sub-Saharan Africa. An online survey conducted in Africa involving 165 researchers in 40 institutions from 21 countries showed that only 5 institutions' laboratories met the minimum laboratory standards.²⁹ The paper also reported suboptimal diagnostic and therapeutic capacities to manage fungal infections in general. Furthermore, the problem of awareness is a major challenge especially amongst clinicians.³⁰ Public awareness of fungal infections in the African populace, especially in those living in rural communities, is generally low. These deficits may partly explain the poor response to IFIs and why most of the infections that are endemic in Africa are fast achieving a “neglected infection status”.

Conclusion

In conclusion, development and uptake of accurate diagnostic tools, increasing funding for research, raising awareness, plus integrated and targeted efforts are needed to tackle the suspected multifaceted healthcare challenges of emergomycosis in Africa. The pathogenesis of the infection is poorly understood in Africa. Data reflecting the true epidemiology of the infection are also lacking, and there are no surveillance systems established for the infection.

Increasing awareness is important to mobilise critical mass to boost mycology research in Africa. Studies to understand the epidemiology of the infection are required as well as clinical research to understand the disease manifestation and associated complications. The outcome of research will help to mount effective prevention and control measures against the infection. It will also help to enhance our understanding of the infection manifestation and guide the establishment of diagnostic and therapeutic guidelines. Additionally, research outcome will help us understand the environmental reservoir of emergomycosis. Government and non-governmental agencies in Africa need to prioritise the infection, which can be done through public-private sector partnership to mount and improve surveillance through data and resource sharing. These actions are important especially in ensuring that the infection does not take a “neglected infection status”.

Future research should aim to identify the pathogens' virulence attribute to understand the disease pathogenesis and host–pathogen interaction especially person with advanced HIV infection.

Acknowledgment

IC thanks Abia State University for support.

Funding

No funding was received for this study.

Disclosure

The authors declare no competing interests.

References

1. Dukik K, Muñoz JF, Jiang Y, et al. Novel taxa of thermally dimorphic systemic pathogens in the Ajellomycetaceae (Onygenales). *Mycoses*. 2017;60:296–309. doi:10.1111/myc.12601
2. Schwartz IS, Maphanga TG, Govender NP. *Emergomycetes*: a new genus of dimorphic fungal pathogens causing disseminated disease among immunocompromised persons globally. *Curr Fungal Infect Rep*. 2018;12:44–50. doi:10.1007/s12281-018-0308-y
3. Schwartz IS, Govender NP, Corcoran C, et al. Clinical characteristics, diagnosis, management, and outcomes of disseminated emmonsiosis: a retrospective case series. *Clin Infect Dis*. 2015;61(6):1004–1012. doi:10.1093/cid/civ439
4. Schwartz IS, Kenyon C, Lehloenya R, et al. AIDS-related endemic mycoses in Western Cape, South Africa, and clinical mimics: a cross-sectional study of adults with advanced HIV and recent-onset, widespread skin lesions. *Open Forum Infect Dis*. 2017;4(4):1–7. doi:10.1093/ofid/ofx186
5. Schwartz IS, McLoud JD, Berman D, et al. Molecular detection of airborne *Emergomycetes africanus*, a thermally dimorphic fungal pathogen, in Cape Town, South Africa. *PLoS Negl Trop Dis*. 2018;12(1):1–12. doi:10.1371/journal.pntd.0006174
6. Maphanga T, Britz E, Zulu TG, et al. In vitro antifungal susceptibility of yeast and mold phases of isolates of dimorphic fungal pathogen *Emergomycetes africanus* (Formerly *Emmonsia* sp.) from HIV-Infected South African Patients. *J Clin Microbiol*. 2017;56:1812–1820. doi:10.1128/JCM.02524-16
7. Schwartz IS, Govender NP, Sigler L, et al. *Emergomycetes*: the global rise of new dimorphic fungal pathogens. *PLoS Pathog*. 2019;15(9):e1007977. doi:10.1371/journal.ppat.1007977
8. Crombie K, Spengane Z, Locketz M, et al. Paradoxical worsening of *Emergomycetes africanus* infection in an HIV-infected male on itraconazole and antiretroviral therapy. *PLoS Negl Trop Dis*. 2018;12(3):1–7. doi:10.1371/journal.pntd.0006173
9. Heys I, Taljaard J, Orth H. An *Emmonsia* species causing disseminated infection in South Africa. *N Eng J Med*. 2014;370:283–284.
10. van Houghenhouck-Tulleken WG, Papavarnavas NS, Nel JS, et al. HIV-associated disseminated emmonsiosis, Johannesburg, South Africa. *Emerg Infect Dis*. 2014;20(12):2164–2166. doi:10.3201/eid2012.140902
11. Kenyon C, Bonorchis K, Corcoran C, et al. A dimorphic fungus causing disseminated infection in South Africa. *N Eng J Med*. 2013;369(15):1416–1424. doi:10.1056/NEJMoa1215460
12. Lochan H, Naicker P, Maphanga T, et al. A case of emmonsiosis in an HIV-infected child. *South Afr J HIV Med*. 2015;16(1). doi:10.4102/sajhivmed.v16i1.352
13. Rooms I, Mugisha P, Gambichler T, et al. Disseminated *emmergomyces* in a person with HIV infection, Uganda. *Emerg Infect Dis*. 2019;25(9):1750–1751. doi:10.3201/eid2509.181234
14. Schwartz IS, Lerm B, Hoving JC, et al. *Emergomycetes africanus* in Soil, South Africa. *Emerg Infect Dis*. 2018;24(2):377–380. doi:10.3201/eid2402.171351
15. Muñoz JF, McEwen JG, Clay OK, Cuomo CA. Genome analysis reveals evolutionary mechanisms of adaptation in systemic dimorphic fungi. *Sci Rep*. 2018;8:1–13. doi:10.1038/s41598-018-22816-6
16. Lerm B, Kenyon C, Schwartz IS, et al. First report of urease activity in the novel systemic fungal pathogen *Emergomycetes africanus*: a comparison with the neurotrope *Cryptococcus neoformans*. *FEMS Yeast Res*. 2017;17. doi:10.1093/femsyr/fox069
17. Rodrigues ML, Albuquerque PC. Searching for a change: the need for increased support for public health and research on fungal diseases. *PLoS Negl Trop Dis*. 2018;12:1–5. doi:10.1371/journal.pntd.0006479
18. Ibe C. The fight against mycoses in Africa, are we making progress? *Clin Microbiol Infect*. 2022;28:9–12. doi:10.1016/j.cmi.2021.09.004
19. Nargesi S, Bongomin F, Hedayati MT. The impact of covid-19 pandemic on aids-related mycoses and fungal neglected tropical diseases: why should we worry? *PLoS Negl Trop Dis*. 2021;15:e0009092. doi:10.1371/journal.pntd.0009092
20. Govender NP, Grayson W. *Emergomycosis* (*Emergomycetes africanus*) in advanced HIV disease. *Dermatopathology*. 2019;6:63–69. doi:10.1159/000495405
21. Mah J, Bakker A, Tseng C, et al. Isolated Pulmonary *Emergomycosis* in an Immunocompetent Patient in Alberta, Canada. *Open Forum Infect Dis*. 2022;9(3). doi:10.1093/ofid/ofac021
22. Moodley A, Mosam A, Govender NP, Mahabeer Y, Chateau AV. *Emergomycetes africanus*: the Mimicking Fungus. *Dermatopathology*. 2019;6:157–162. doi:10.1159/000497608
23. Linder KA, Kauffman CA. Histoplasmosis: epidemiology, Diagnosis, and Clinical Manifestations. *Curr Fungal Infect Rep*. 2019;13(3):120–128. doi:10.1007/s12281-019-00341-x
24. Maphanga TG, Naicker SD, Gómez BL, et al. Cross-reactivity of a *Histoplasma capsulatum* antigen enzyme immunoassay in urine specimens from persons with *emmergomyces* in South Africa. *Med Mycol*. 2021;59(7):672–682. doi:10.1093/mmy/myaa100
25. Azar MM, Hage CA. Laboratory diagnostics for histoplasmosis. *J Clin Microbiol*. 2017;55:1612–1620. doi:10.1128/JCM.02430-16
26. Schwartz IS, Sanche S, Wiederhold NP, Patterson TF, Sigler L. *Emergomycetes canadensis*, a Dimorphic Fungus Causing Fatal Systemic Human Disease in North America. *Emerg Infect Dis*. 2018;24:758–761. doi:10.3201/eid2404.171765
27. World Health Organisation (WHO). *Guidelines for diagnosing, preventing and managing cryptococcal disease among adults, adolescents and children living with HIV*. World Health Organisation; 2022.
28. Ibe C, Okoye CA. Integrated healthcare approach can curb the increasing cases of cryptococcosis in Africa. *PLoS Negl Trop Dis*. 2022;16:e0010625. doi:10.1371/journal.pntd.0010625
29. Driemeyer C, Falci DR, Oladele RO, et al. The current state of clinical mycology in Africa: a European Confederation of Medical Mycology and International Society for Human and Animal Mycology survey. *Lancet Microbe Preprint*. 2022;3(6):e464–e470. doi:10.1016/S2666-5247(21)00190-7
30. Oladele R, Otu AA, Olubamwo O, et al. Evaluation of knowledge and awareness of invasive fungal infections amongst resident doctors in Nigeria. *Pan Af Med J*. 2020;36:1–11. doi:10.11604/pamj.2020.36.297.23279

International Journal of General Medicine

Dovepress

Publish your work in this journal

The International Journal of General Medicine is an international, peer-reviewed open-access journal that focuses on general and internal medicine, pathogenesis, epidemiology, diagnosis, monitoring and treatment protocols. The journal is characterized by the rapid reporting of reviews, original research and clinical studies across all disease areas. The manuscript management system is completely online and includes a very quick and fair peer-review system, which is all easy to use. Visit <http://www.dovepress.com/testimonials.php> to read real quotes from published authors.

Submit your manuscript here: <https://www.dovepress.com/international-journal-of-general-medicine-journal>