

Current Status and Perspectives Regarding the Treatment of Osteosarcoma: Chemotherapy

Akio Sakamoto* and Yukihide Iwamoto

Department of Orthopaedic Surgery, Graduate School of Medical Sciences, Kyushu University, Japan

Abstract: Osteosarcoma is the most common primary bone tumor in childhood and adolescence. The use of combination chemotherapy and surgery enables long-term survival in approximately 60-70% of cases. However, the necessity for surgery, the poor prognosis of patients with metastatic or recurrent disease (long-term survival in only about 20% of cases), and the lack of establishment of second-line chemotherapy suggest that improvements in chemotherapy are desperately needed. Currently, in an effort to extend the protocol with the chemotherapy drugs that already exist, high-dose chemotherapy with/without autologous peripheral blood stem cell transplantation, and tumor-targeted drug delivery systems are under investigation. Future drug developments will no doubt lie in the direction of immunotherapy and anti-angiogenic therapy, as well as the use of cytotoxic drugs. Identifying the genes and signal transduction pathways responsible for the development of osteosarcoma or for the occurrence of malignancy in cases of osteosarcoma will undoubtedly lead to the identification of pathway-specific agents, or possible gene therapy. Furthermore, as increased light is shed on the character of osteoblastic differentiation in osteosarcoma, this will certainly give rise to new treatments utilizing differentiation therapy. This article reviews the current status and perspectives regarding the treatment of osteosarcoma in terms of chemotherapy.

Keywords: Osteosarcoma, chemotherapy.

INTRODUCTION

Osteosarcoma is the most common primary bone tumor in childhood and adolescence, and in about 80% of cases it occurs in the long bones of the limbs. In the other 20% of cases, it occurs in the axial skeleton and pelvis [1]. Commonly affected bones, in descending order, are the femur (40%), the tibia (20%) and humerus (10%) [2]. Osteosarcoma occurs primarily in the metaphysis of long bones around the knee region of the distal femur or proximal tibia. Osteosarcoma is highly aggressive and it metastasizes primarily to the lung [3]. The median age of an osteosarcoma patient is 16 years, with a male predominance (male/female ratio; 1.6:1). The occurrence of osteosarcoma seems to be associated with a spurt in growth [4]. The peak incidence among female patients has been reported to be a little earlier than that among male patients, probably because of the earlier onset of growth spurt at the growth plate [5, 6]. Histologically, osteosarcoma is characterized by a proliferation of atypical spindle cells. Malignant osteoid formation is diagnostic for osteosarcoma. Conventional osteosarcoma is classified into osteoblastic, chondroblastic and fibroblastic, according to its predominant features [7].

Genetic alterations have been reported in osteosarcoma. In particular, the tumor-suppressor pathways of p53 and Rb (retinoblastoma tumor-suppressor gene) are thought to be involved in the pathogenesis of osteosarcoma [8-11]. The majority of patients with osteosarcoma have neither a fami-

lial background nor a history of radiation exposure. Li-Fraumeni syndrome (germline deletion in p53) and familial retinoblastoma (germline mutations of Rb) are known to be risk factors in the development of osteosarcoma [10, 12-15]. Even osteosarcoma without such a background has alterations in both the p53 and Rb pathways in the majority of cases [7]. p53 is a tumor-suppressor gene and its product plays an important role in the cellular response to DNA damage [16]. Rb product has a suppressive effect on the cell cycle. p53 and Rb are thought to be involved in osteosarcoma oncogenesis [17-19]. Unbalanced karyotypes and other abnormal cellular signaling pathways have also been reported in osteosarcoma cells. Among possible cytogenetic alterations, gains in chromosome 1, loss of chromosome 9 and loss of heterozygosity on several chromosomes are consistently reported [7].

Mouse double minute 2 (MDM2) and cyclin-dependent kinase 4 (CDK4) genes have been reported to be amplified or overexpressed in osteosarcoma, and these genes are thought to be involved in the pathogenesis [20, 21]. The MDM2 gene product binds and inactivates p53 protein, whereas the CDK4 gene product is a cyclin-dependent kinase and possibly inactivates Rb function. c-fos is a transcriptional factor and controls cell-cycle progression. c-fos plays an important role in osteoblast and chondrocyte differentiation. Amplification or overexpression of the c-fos gene has been reported in osteosarcoma cells [22].

CURRENT CHEMOTHERAPY

Until the 1970s, osteosarcoma was treated by amputation in most cases, or else by radiotherapy. In spite of local control, most osteosarcoma patients died within a short period

*Address correspondence to this author at the Department of Orthopaedic Surgery, Graduate School of Medical Sciences, Kyushu University, 3-1-1, Higashi-ku, Maidashi, Fukuoka, 812-8582, Japan; TEL: +81-92-642-5488; FAX: +81-92-642-5507; E-mail: akio@med.kyushu-u.ac.jp

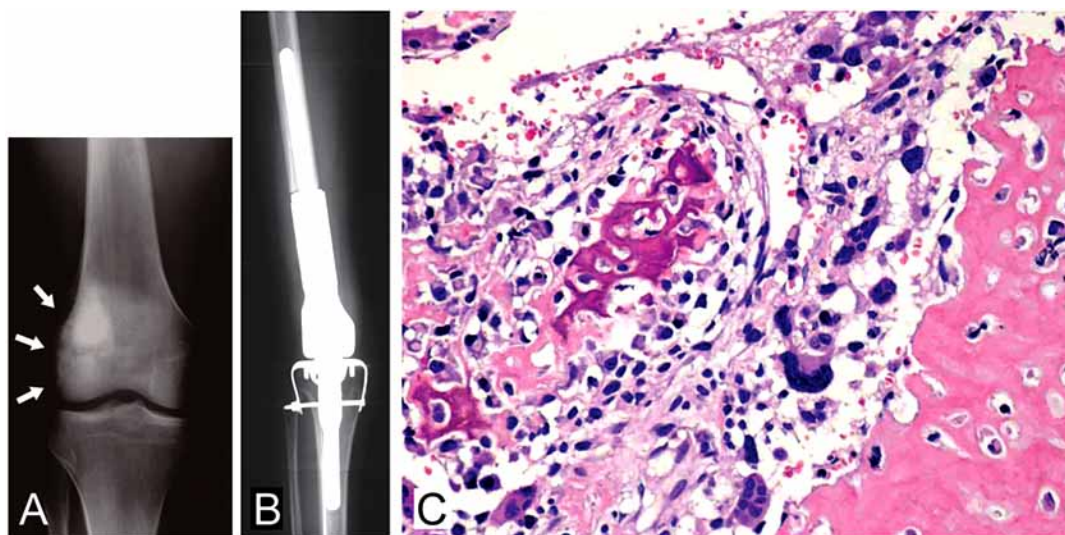


Fig. (1). Osteoblastic osteosarcoma. Plain radiograph of a 19-year-old male clearly shows an irregular osteoblastic feature in the medullary region of the distal femur with cortical irregularity over the lateral cortex (arrows) (A). After a three-drug chemotherapy regimen made up of cisplatin, doxorubicin and methotrexate, wide resection was carried out, followed by reconstruction using a Kotz prosthesis (HMRS: Howmedica Modular Reconstruction System) (B). Histological section reveals osteoblastic osteosarcoma clearly demonstrating osteoblastic features, comprising irregular immature bone deposition by anaplastic tumor cells (C).

because of lung metastasis. The results of surgery alone as a treatment of osteosarcoma have not been satisfactory. The 5-year disease-free survival rate after treatment by surgery alone has been reported to be only 12% [3]. Neoadjuvant (preoperative) chemotherapy was introduced in 1978 [23]. The purposes of neoadjuvant chemotherapy are the destruction of primary tumor cells and the eradication of micrometastasis. Doxorubicin and methotrexate have been applied successfully as chemotherapy drugs for the treatment of osteosarcoma [24-27]. In the course of a study into osteosarcoma chemotherapy, vincristine, bleomycin and dactinomycin have all been proven to be ineffective [28, 29]. Subsequently, the addition of cisplatin and ifosfamide to doxorubicin and methotrexate has been able to improve clinical results significantly [30, 31]. The current standard protocol of a three-drug chemotherapy regimen using cisplatin, doxorubicin and high-dose methotrexate provides about 70% long-term disease-free survival for osteosarcoma patients without metastasis (Fig. 1) [7].

The amount of tumor necrosis following preoperative chemotherapy has been known to be a reliable prognostic factor, enabling the effectiveness of the chemotherapy treatment to be accurately determined [32, 33]. Tumor necrosis is usually assessed as follows: Grade I: no necrosis; Grade II: necrosis of between 50 and 95%; Grade III: necrosis greater than 95 but less than 100%; and Grade IV: total necrosis; 100% [23]. Patients with tumor necrosis in excess of (\geq) 90% are classified as good responders to chemotherapy, whereas those whose tumor necrosis is less than ($<$) 90% are classified as poor responders.

Therapy for Patients with Metastasized Osteosarcoma

Unfavorable prognosis is associated with tumor location, the number and location of the metastases and lack of adequate surgical resection. In particular, the prognosis of osteosarcoma patients with metastasis is still poor, with only

20% achieving a 5-year survival rate [1]. Treatment for patients with relapsed osteosarcoma following standard chemotherapy or for patients with tumors that are unresponsive to standard chemotherapy remains challenging. A second-line chemotherapy regimen for use when applied standard chemotherapy fails, has not been widely accepted [34, 35]. High-dose ifosfamide could be used for these patients, especially when ifosfamide has not been applied previously to these same patients [36]. High-dose ifosfamide has been reported to be effective against recurrent disease, in a comparison with the standard dose [37, 38].

As for the treatment of lung metastases which appear after the initial diagnosis, surgical resection is usually considered. Radiotherapy in the lung after the resection of a metastatic lesion is not undertaken in most cases. In general, when a solitary metastatic lesion in the lung is detected more than 24 months after the initial diagnosis, surgical resection and close observation are chosen [39, 40], whereas in the case of patients with a single site of disease recurrence after a rather short relapse-free interval of around less than 24 months, systemic chemotherapy together with resection of the lesion is beneficial [7].

New Treatment

In order to improve the survival of metastatic patients or patients classes as poor-responders following the standard protocol of a three-drug chemotherapy regimen using cisplatin, doxorubicin and high-dose methotrexate, several protocols comprising intensive chemotherapy, such as high-dose or prolonged chemotherapy with/without peripheral blood stem cell rescue, have been considered, but the benefit of these therapies is not conclusive in long-term follow-up [3, 41, 42]. Improvement in the delivery efficacy of current agents may result in improved clinical results. Liposomal encapsulation of doxorubicin has been shown to be effective in delivering doxorubicin to patients, therefore providing the

possibility that the resistance to doxorubicin could be overcome [43]. Furthermore, the efficacy of an aerosolized formulation of cisplatin has been investigated, especially for osteosarcoma patients [7].

A variety of agents has been investigated for the treatment of osteosarcoma in clinical trials. Studies with monoclonal antibodies, such as 8H9, heat-shock protein inhibitors, such as 17-N-allylamino-17-demethoxygeldanamycin [17-AAG], and small molecule inhibitors, such as gefitinib and erlotinib, have been undertaken. Antifolate of methotrexate, trimetrexate, has been developed for the treatment of methotrexate-resistant osteosarcoma [44]. In addition, a new compound, PNU-159548, may have beneficial effects when combined with conventional agents [45]. Endostatin is an inhibitor of angiogenesis, and was administered in combination with liposome to experimental animals with osteosarcoma [46]. Liposomal muramyl tripeptide phosphatidylethanolamine is an activator of monocytes and macrophages and induces the secretion of different cytokines (Interleukin 1 [IL 1], IL 6, tumor necrosis factor α [TNF α]), and it has been tested in clinical studies on osteosarcoma patients [47, 48]. Moreover, an immunomodulator of interferon for use as maintenance therapy has also been tested [49].

Identifying the genes and signal transduction pathways responsible for the development and malignant behavior in osteosarcoma will lead to the discovery of new drugs and therapy. It has been suggested that inhibition of the mammalian target of the rapamycin (mTOR) pathway may be effective in osteosarcoma [50, 51]. Inhibitors of receptor tyrosine kinases, including insulin-like growth factor 1 receptor (IGF-1R) and a platelet-derived growth factor receptor (PDGFR) have been investigated and developed for osteosarcoma treatment [52-54]. It has been reported that sustained-release sandostatin successfully performed the function of reducing serum IGF-1 levels [55]. Gene therapy is approaching readiness for clinical studies, and it now offers potentially promising results. The effectiveness of p53 gene therapy via a transferring-liposome-p53 complex administered in animal models has also been reported [56].

The receptor activator of nuclear factor- κ B, its ligand and the osteoprotegerin (RANK/RANKL/OPG) system is important in bone remodeling and metabolism [57, 58]. This RANK/RANKL/OPG system possibly plays a role in the pathogenesis of osteosarcoma [59, 60], and its interference may provide a new therapeutic strategy. Bisphosphonates inhibit osteoclast action and the resorption of bone, and it has been demonstrated that bisphosphonates inhibit tumor growth *in vitro*. Moreover, the effect of bisphosphonates combined with the standard protocol of cisplatin, doxorubicin and high-dose methotrexate has been investigated for osteosarcoma [61-63]. Peroxisome proliferator activated receptor (PPAR) γ /retinoid X receptor (PPAR γ /RXR) agonists may induce differentiation in osteosarcoma, despite critical blocks to the normal bone morphogenetic protein (BMP)-regulated pathways. Differentiation therapy in osteosarcoma could be used as a new strategy [64].

CONCLUSION

Osteosarcoma is a highly aggressive tumor with a high metastasizing potential. There is no established second-line

chemotherapy, and accordingly, improvements in chemotherapy are desperately needed. Using microarray analysis in osteosarcoma, it has been demonstrated that a specific expression signature can differentiate between chemoresponsive and chemoresistant tumors [65]. Understanding the molecular mechanism of osteosarcoma development and malignant behavior will undoubtedly lead to the discovery of new chemotherapy agents.

ACKNOWLEDGEMENT

The English used in this manuscript was revised by Miss K. Miller (Royal English Language Centre, Fukuoka, Japan).

REFERENCES

- [1] Lamoureux F, Trichet V, Chipoy C, Blanchard F, Gouin F, Redini F. Recent advances in the management of osteosarcoma and forthcoming therapeutic strategies. *Expert Rev Anticancer Ther* 2007; 7: 169-81.
- [2] Klein MJ, Siegal GP. Osteosarcoma: anatomic and histologic variants. *Am J Clin Pathol* 2006; 125: 555-81.
- [3] Longhi A, Errani C, De Paolis M, Mercuri M, Bacci G. Primary bone osteosarcoma in the pediatric age: state of the art. *Cancer Treat Rev* 2006; 32: 423-36.
- [4] Gelberg KH, Fitzgerald EF, Hwang S, Dubrow R. Growth and development and other risk factors for osteosarcoma in children and young adults. *Int J Epidemiol* 1997; 26: 272-8.
- [5] Fraumeni JF Jr. Stature and malignant tumors of bone in childhood and adolescence. *Cancer* 1967; 20: 967-73.
- [6] Rytting M, Pearson P, Raymond AK, *et al*. Osteosarcoma in pre-adolescent patients. *Clin Orthop Relat Res* 2000; 39-50.
- [7] Chou AJ, Gorlick R. Chemotherapy resistance in osteosarcoma: current challenges and future directions. *Expert Rev Anticancer Ther* 2006; 6: 1075-85.
- [8] Hansen MF. Molecular genetic considerations in osteosarcoma. *Clin Orthop Relat Res* 1991; 237-46.
- [9] Ferguson WS, Goorin AM. Current treatment of osteosarcoma. *Cancer Invest* 2001; 19: 292-315.
- [10] Bramwell VH. The role of chemotherapy in the management of non-metastatic operable extremity osteosarcoma. *Semin Oncol* 1997; 24: 561-71.
- [11] Strauss SJ, McTiernan A, Whelan JS. Late relapse of osteosarcoma: implications for follow-up and screening. *Pediatr Blood Cancer* 2004; 43: 692-7.
- [12] Fuchs B, Pritchard DJ. Etiology of osteosarcoma. *Clin Orthop Relat Res* 2002; 40-52.
- [13] Swaney JJ. Familial osteogenic sarcoma. *Clin Orthop Relat Res* 1973; 64-8.
- [14] German J. Bloom's syndrome. XX. The first 100 cancers. *Cancer Genet Cytogenet* 1997; 93: 100-6.
- [15] Wang LL, Gannavarapu A, Kozinetz CA, *et al*. Association between osteosarcoma and deleterious mutations in the RECQL4 gene in Rothmund-Thomson syndrome. *J Natl Cancer Inst* 2003; 95: 669-74.
- [16] Chi SN, Conklin LS, Qin J, *et al*. The patterns of relapse in osteosarcoma: the Memorial Sloan-Kettering experience. *Pediatr Blood Cancer* 2004; 42: 46-51.
- [17] Masuda H, Miller C, Koeffler HP, Battifora H, Cline MJ. Rearrangement of the p53 gene in human osteogenic sarcomas. *Proc Natl Acad Sci USA* 1987; 84: 7716-9.
- [18] Scholz RB, Kabisch H, Weber B, Roser K, Delling G, Winkler K. Studies of the RB1 gene and the p53 gene in human osteosarcomas. *Pediatr Hematol Oncol* 1992; 9: 125-37.
- [19] Dryja TP, Rapaport JM, Epstein J, *et al*. Chromosome 13 homozygosity in osteosarcoma without retinoblastoma. *Am J Hum Genet* 1986; 38: 59-66.
- [20] Ragazzini P, Gamberi G, Benassi MS, *et al*. Analysis of SAS gene and CDK4 and MDM2 proteins in low-grade osteosarcoma. *Cancer Detect Prev* 1999; 23: 129-36.
- [21] Khatib ZA, Matsushime H, Valentine M, Shapiro DN, Sherr CJ, Look AT. Coamplification of the CDK4 gene with MDM2 and GLI in human sarcomas. *Cancer Res* 1993; 53: 5535-41.
- [22] van den Berg S, Rahmsdorf HJ, Herrlich P, Kaina B. Overexpression of c-fos increases recombination frequency in human osteosarcoma cells. *Carcinogenesis* 1993; 14: 925-8.

- [23] Rosen G, Caparros B, Huvos AG, *et al.* Preoperative chemotherapy for osteogenic sarcoma: selection of postoperative adjuvant chemotherapy based on the response of the primary tumor to preoperative chemotherapy. *Cancer* 1982; 49: 1221-30.
- [24] Campanacci M, Bacci G, Bertoni F, Picci P, Minuttillo A, Franceschi C. The treatment of osteosarcoma of the extremities: twenty year's experience at the Istituto Ortopedico Rizzoli. *Cancer* 1981; 48: 1569-81.
- [25] Enneking WF. Advances and treatment of primary bone tumors. *J Fla Med Assoc* 1979; 66: 28-30.
- [26] Rosenberg SA, Chabner BA, Young RC, *et al.* Treatment of osteogenic sarcoma. I. Effect of adjuvant high-dose methotrexate after amputation. *Cancer Treat Rep* 1979; 63: 739-51.
- [27] Rosen G, Murphy ML, Huvos AG, Gutierrez M, Marcove RC. Chemotherapy, en bloc resection, and prosthetic bone replacement in the treatment of osteogenic sarcoma. *Cancer* 1976; 37: 1-11.
- [28] Meyers PA, Heller G, Healey J, *et al.* Chemotherapy for nonmetastatic osteogenic sarcoma: the Memorial Sloan-Kettering experience. *J Clin Oncol* 1992; 10: 5-15.
- [29] Avella M, Bacci G, McDonald DJ, Di Scioscio M, Picci P, Campanacci M. Adjuvant chemotherapy with six drugs (adriamycin, methotrexate, cisplatin, bleomycin, cyclophosphamide and dactinomycin) for non-metastatic high grade osteosarcoma of the extremities. Results of 32 patients and comparison to 127 patients concomitantly treated with the same drugs in a neoadjuvant form. *Chemioterapia* 1988; 7: 133-7.
- [30] de Kraker J, Voute PA. Experience with ifosfamide in paediatric tumours. *Cancer Chemother Pharmacol* 1989; 24: S28-9.
- [31] Bacci G, Ferrari S, Longhi A, *et al.* High dose ifosfamide in combination with high dose methotrexate, adriamycin and cisplatin in the neoadjuvant treatment of extremity osteosarcoma: preliminary results of an Italian Sarcoma Group/Scandinavian Sarcoma Group pilot study. *J Chemother* 2002; 14:198-206.
- [32] Bielack SS, Kempf-Bielack B, Dellling G, *et al.* Prognostic factors in high-grade osteosarcoma of the extremities or trunk: an analysis of 1,702 patients treated on neoadjuvant cooperative osteosarcoma study group protocols. *J Clin Oncol* 2002; 20: 776-90.
- [33] Glasser DB, Lane JM, Huvos AG, Marcove RC, Rosen G. Survival, prognosis, and therapeutic response in osteogenic sarcoma. The Memorial Hospital experience. *Cancer* 1992; 69: 698-708.
- [34] Tabone MD, Kalifa C, Rodary C, Raquin M, Valteau-Couanet D, Lemerle J. Osteosarcoma recurrences in pediatric patients previously treated with intensive chemotherapy. *J Clin Oncol* 1994; 12: 2614-20.
- [35] Pastorino U, Gasparini M, Tavecchio L, *et al.* The contribution of salvage surgery to the management of childhood osteosarcoma. *J Clin Oncol* 1991; 9: 1357-62.
- [36] Chou AJ, Merola PR, Wexler LH, *et al.* Treatment of osteosarcoma at first recurrence after contemporary therapy: the Memorial Sloan-Kettering Cancer Center experience. *Cancer* 2005; 104: 2214-21.
- [37] Carli M, Passone E, Perilongo G, Bisogno G. Ifosfamide in pediatric solid tumors. *Oncol* 2003; 65(Suppl 2): 99-104.
- [38] Goorin AM, Harris MB, Bernstein M, *et al.* Phase II/III trial of etoposide and high-dose ifosfamide in newly diagnosed metastatic osteosarcoma: a pediatric oncology group trial. *J Clin Oncol* 2002; 20: 426-33.
- [39] Ferrari S, Briccoli A, Mercuri M, *et al.* Postrelapse survival in osteosarcoma of the extremities: prognostic factors for long-term survival. *J Clin Oncol* 2003; 21: 710-5.
- [40] Hawkins DS, Arndt CA. Pattern of disease recurrence and prognostic factors in patients with osteosarcoma treated with contemporary chemotherapy. *Cancer* 2003; 98: 2447-56.
- [41] Sauerbrey A, Bielack S, Kempf-Bielack B, Zoubek A, Paulussen M, Zintl F. High-dose chemotherapy (HDC) and autologous hematopoietic stem cell transplantation (ASCT) as salvage therapy for relapsed osteosarcoma. *Bone Marrow Transplant* 2001; 27: 933-7.
- [42] Fagioli F, Aglietta M, Tienghi A, *et al.* High-dose chemotherapy in the treatment of relapsed osteosarcoma: an Italian sarcoma group study. *J Clin Oncol* 2002; 20: 2150-6.
- [43] Alberts DS, Muggia FM, Carmichael J, *et al.* Efficacy and safety of liposomal anthracyclines in phase I/II clinical trials. *Semin Oncol* 2004; 31: 53-90.
- [44] Purcell WT, Ettinger DS. Novel antifolate drugs. *Curr Oncol Rep* 2003; 5:114-25.
- [45] Pasello M, Hattinger CM, Stoico G, *et al.* 4-Demethoxy-3'-deamino-3'-aziridinyl-4'-methylsulphonyl-daunorubicin (PNU-159548): a promising new candidate for chemotherapeutic treatment of osteosarcoma patients. *Eur J Cancer* 2005; 41: 2184-95.
- [46] Dutour A, Monteil J, Paraf F, *et al.* Endostatin cDNA/cationic liposome complexes as a promising therapy to prevent lung metastases in osteosarcoma: study in a human-like rat orthotopic tumor. *Mol Ther* 2005; 11: 311-9.
- [47] Nardin A, Lefebvre ML, Labroquere K, Faure O, Abastado JP. Liposomal muramyl tripeptide phosphatidylethanolamine: Targeting and activating macrophages for adjuvant treatment of osteosarcoma. *Curr Cancer Drug Targets* 2006; 6: 123-33.
- [48] Meyers PA, Schwartz CL, Krailo M, *et al.* Osteosarcoma: a randomized, prospective trial of the addition of ifosfamide and/or muramyl tripeptide to cisplatin, doxorubicin, and high-dose methotrexate. *J Clin Oncol* 2005; 23: 2004-11.
- [49] Smeland S, Muller C, Alvegard TA, *et al.* Scandinavian Sarcoma Group Osteosarcoma Study SSG VIII: prognostic factors for outcome and the role of replacement salvage chemotherapy for poor histological responders. *Eur J Cancer* 2003; 39: 488-94.
- [50] Vilella-Bach M, Nuzzi P, Fang Y, Chen J. The FKBP12-rapamycin-binding domain is required for FKBP12-rapamycin-associated protein kinase activity and G1 progression. *J Biol Chem* 1999; 274: 4266-72.
- [51] Wan X, Mendoza A, Khanna C, Helman LJ. Rapamycin inhibits ezrin-mediated metastatic behavior in a murine model of osteosarcoma. *Cancer Res* 2005; 65: 2406-11.
- [52] Casas-Ganem J, Healey JH. Advances that are changing the diagnosis and treatment of malignant bone tumors. *Curr Opin Rheumatol* 2005; 17: 79-85.
- [53] McGary EC, Weber K, Mills L, *et al.* Inhibition of platelet-derived growth factor-mediated proliferation of osteosarcoma cells by the novel tyrosine kinase inhibitor STI571. *Clin Cancer Res* 2002; 8: 3584-91.
- [54] Scotlandi K, Manara MC, Nicoletti G, *et al.* Antitumor activity of the insulin-like growth factor-I receptor kinase inhibitor NVP-AEW541 in musculoskeletal tumors. *Cancer Res* 2005; 65: 3868-76.
- [55] Mansky PJ, Liewehr DJ, Steinberg SM, *et al.* Treatment of metastatic osteosarcoma with the somatostatin analog OncoLar: significant reduction of insulin-like growth factor-1 serum levels. *J Pediatr Hematol Oncol* 2002; 24: 440-6.
- [56] Nakase M, Inui M, Okumura K, Kamei T, Nakamura S, Tagawa T. p53 gene therapy of human osteosarcoma using a transferrin-modified cationic liposome. *Mol Cancer Ther* 2005; 4: 625-31.
- [57] Wuyts W, Van Wesenbeeck L, Morales-Piga A, *et al.* Evaluation of the role of RANK and OPG genes in Paget's disease of bone. *Bone* 2001; 28: 104-7.
- [58] Itoh K, Udagawa N, Matsuzaki K, *et al.* Importance of membrane-associated forms of M-CSF and RANKL/ODF in osteoclastogenesis supported by SaOS-4/3 cells expressing recombinant PTH/PTHrP receptors. *J Bone Miner Res* 2000; 15: 1766-75.
- [59] Miyamoto N, Higuchi Y, Mori K, *et al.* Human osteosarcoma-derived cell lines produce soluble factor(s) that induces differentiation of blood monocytes to osteoclast-like cells. *Int Immunopharmacol* 2002; 2: 25-38.
- [60] Wittrant Y, Lamoureux F, Mori K, *et al.* RANKL directly induces bone morphogenetic protein-2 expression in RANK-expressing POS-1 osteosarcoma cells. *Int J Oncol* 2006; 28: 261-9.
- [61] Ashton JA, Farese JP, Milner RJ, Lee-Ambrose LM, van Gilder JM. Investigation of the effect of pamidronate disodium on the in vitro viability of osteosarcoma cells from dogs. *Am J Vet Res* 2005; 66: 885-91.
- [62] Cheng YY, Huang L, Lee KM, Li K, Kumta SM. Alendronate regulates cell invasion and MMP-2 secretion in human osteosarcoma cell lines. *Pediatr Blood Cancer* 2004; 42: 410-5.
- [63] Ory B, Heymann MF, Kamijo A, Gouin F, Heymann D, Redini F. Zoledronic acid suppresses lung metastases and prolongs overall survival of osteosarcoma-bearing mice. *Cancer* 2005; 104: 2522-9.
- [64] Haydon RC, Luu HH, He TC. Osteosarcoma and osteoblastic differentiation: a new perspective on oncogenesis. *Clin Orthop Relat Res* 2007; 454: 237-46.
- [65] Mintz MB, Sowers R, Brown KM, *et al.* An expression signature classifies chemotherapy-resistant pediatric osteosarcoma. *Cancer Res* 2005; 65:1748-54.