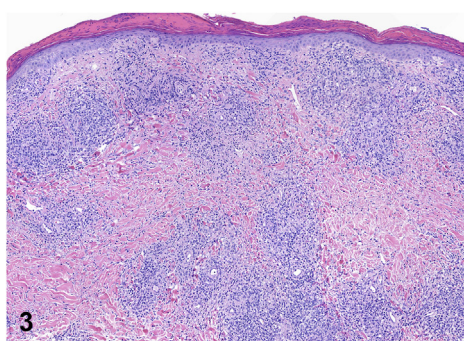
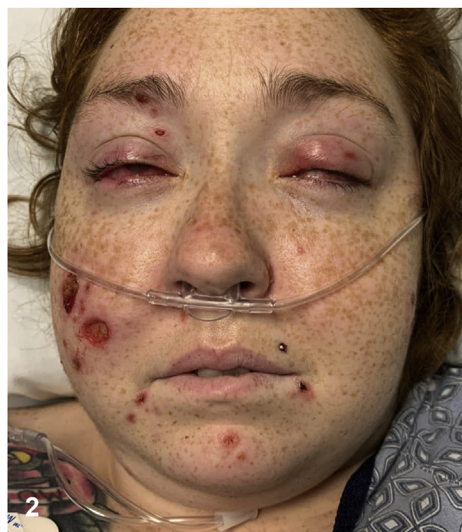
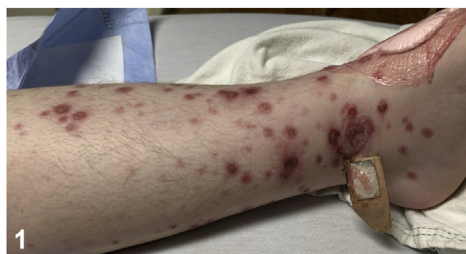
Ulceronecrotic rash in an immunocompetent individual



Shae Margulies, BS,^a Sagar P. Patel, MD,^b and Kiran Motaparthy, MD^b

Key words: lues maligna; malignant syphilis; syphilis; *Treponema pallidum*.



From the University of Florida College of Medicine, Gainesville, Florida^a; and Department of Dermatology, University of Florida College of Medicine, Gainesville, Florida.^b

Funding sources: This article has no funding source.

IRB approval status: Not applicable.

Consent for the publication of all patient photographs and medical information: patients gave consent for their photographs and medical information to be published in print and online and with the understanding that this information may be publicly available.

Correspondence to: Kiran Motaparthy, MD, Department of Dermatology, University of Florida College of Medicine, 4037

NW 86 Terrace, 4th Floor, Room 4123 Springhill, Gainesville, FL 32606. E-mail: kmotaparthy@dermatology.med.ufl.edu.

JAAD Case Reports 2022;27:29-31.

2352-5126

© 2022 by the American Academy of Dermatology, Inc. Published by Elsevier, Inc. This is an open access article under the CC BY-NC-ND license (<http://creativecommons.org/licenses/by-nc-nd/4.0/>).

<https://doi.org/10.1016/j.jidcr.2022.06.029>

A 28-year-old woman presented with a 6-week history of a pustular rash that began on her ankles and spread upward. Two weeks prior to presentation, she began experiencing eye redness, swelling, and vision loss with enlarged lymph nodes and fatigue. Examination revealed ulcerated papules and plaques involving the face, shins, knees, and thighs (Fig 1). The palms and soles were spared. Postauricular and cervical lymphadenopathy was present, and there was bilateral periorbital edema with conjunctival injection (Fig 2). Punch biopsy demonstrated a lichenoid granulomatous dermatitis with plasma cells (Fig 3).

Question 1: What is the most likely diagnosis?

- A. Pityriasis lichenoides
- B. Malignant syphilis
- C. Primary cutaneous aggressive epidermotropic cytotoxic T cell lymphoma
- D. Ecthyma
- E. Necrolytic migratory erythema (NME)

Answer:

A. Pityriasis lichenoides — Incorrect. Pityriasis lichenoides presents as papules that acutely develop hemorrhagic or necrotic crusts. Histopathology demonstrates a lichenoid interface dermatitis with a superficial and deep lymphocytic infiltrate; plasma cells and granulomas are not present.

B. Malignant syphilis — Correct. Malignant syphilis is a rare, ulceronecrotic subtype of secondary syphilis that begins with a prodrome of fever, fatigue, and lymphadenopathy.¹ This is followed by a diffuse eruption of erythematous papulopustules that eventually ulcerate. Diagnostic criteria are summarized in Table I.² The patient presented had a positive *Treponema pallidum* IgG serology followed by a serum rapid plasma reagin of 1:128. Enzyme-linked immunosorbent assay for Human immunodeficiency virus (HIV) and an interferon-gamma release assay were negative. Although this patient also had ocular findings, ocular syphilis is not required for a diagnosis of malignant syphilis. Histopathologic findings demonstrate an interface tissue reaction, epidermal hyperplasia, and psoriasiform features. The most frequently described pattern reflects a lymphoplasmacytic dermal infiltrate; a granulomatous infiltrate can also be observed.³ Immunohistochemistry for *T pallidum* is up to 80 percent sensitive in secondary syphilis.

C. Primary cutaneous aggressive epidermotropic cytotoxic T cell lymphoma — Incorrect. This rare lymphoma presents as papules and plaques with central necrosis and ulceration. Histopathology includes prominent epidermotropism by atypical lymphocytes, rather than an interface dermatitis with mixed inflammation including plasma cells.

Immunohistochemistry is required for distinction from other cytotoxic lymphomas, specifically gamma-delta ($\gamma\delta$) T cell lymphoma and natural killer/T cell lymphoma.

D. Ecthyma — Incorrect. Ecthyma is a deep pyoderma that is often caused by group A beta-hemolytic streptococci, beginning as a small vesicle or pustule that ulcerates. Histopathology demonstrates ulcer and abscess.

E. NME — Incorrect. NME is characterized by erythematous plaques that develop crusted erosions. These erosive plaques often resolve and reappear elsewhere. Histopathology demonstrates a psoriasiform dermatitis with keratinocyte pallor, dyskeratosis, and ballooning degeneration.

Question 2: What condition is most often associated with this diagnosis?

- A. Epstein–Barr virus (EBV)
- B. Glucagonoma
- C. Inflammatory bowel disease (IBD)
- D. HIV
- E. Systemic lupus erythematosus (SLE)

Answer:

A. EBV — Incorrect. The EBV causes infectious mononucleosis, which manifests as splenomegaly, pharyngitis, and bilateral cervical lymphadenopathy.

Table I. Diagnostic criteria for malignant syphilis*

Characteristic clinical and histopathologic morphology: crusted or scaly papules and pustules that evolve into ulceronecrotic lesions, with a characteristic interface tissue reaction, epidermal necrosis, and spongiosis.
High titer† treponemal serological tests
Jarisch-Herxheimer reaction: a transient clinical phenomenon with fever, chills, headache, nausea, vomiting, tachycardia, and hypotension due to the breakdown of spirochetes and release of toxins and cytokines during antibiotic treatment.
Resolution of lesions following therapy with benzathine penicillin G

*The majority of reported cases fulfill at least 3 criteria.

†Serologic titers >1:32 based on previously reported cases.

A morbilliform rash can occur following the administration of an aminopenicillin.

B. Glucagonoma — Incorrect. Glucagon-secreting tumors are associated with NME, which is described above.

C. IBD — Incorrect. IBD can be associated with erythema nodosum (EN) and pyoderma gangrenosum (PG), neither of which is seen here. EN does not ulcerate, and the presentation of PG is notable for ulcers with characteristic undermined edges and surrounding violaceous borders. EN is characterized by a septal granulomatous panniculitis, while established lesions of PG demonstrate ulceration and diffuse neutrophilic infiltrates.

D. HIV — Correct. Malignant syphilis is often associated with HIV infection or immunosuppression. In a systematic review of 45 patients from 2014 to 2018, 75% were HIV-positive.³ Decreased cell-mediated immunity, defective macrophage function, and a blunted humoral response in immunosuppressed patients enable greater virulence in *T pallidum* and subsequent severe clinical manifestations.⁴ The case presented here is notable in that the patient was healthy, without comorbidities or immunosuppression. All patients diagnosed with syphilis, including malignant syphilis, should be screened for HIV. Additionally, it is recommended that HIV-negative patients with neurosyphilis, ocular syphilis, and otosyphilis are offered HIV pre-exposure prophylaxis, as syphilis is a significant risk factor for HIV infection.

E. SLE — Incorrect. Necrotic findings associated with SLE include antiphospholipid syndrome, which presents with retiform purpura and a thrombotic vasculopathy, and Rowell syndrome or cutaneous lupus with epidermal necrosis.

Question 3: What is the treatment of choice for this condition?

A. Cyclophosphamide, doxorubicin, vincristine, and prednisolone for 21 days

B. Valacyclovir 500 mg twice daily for 3 days

C. Benzathine penicillin G 2.4 million units intramuscular weekly for 3 weeks

D. Doxycycline 100 mg twice daily for 4 weeks

E. Prednisone 30 mg daily for 7 days

Answer:

A. Cyclophosphamide, doxorubicin, vincristine, and prednisolone for 21 days — Incorrect. This

regimen, commonly referred to as CHOP therapy, is the most commonly used therapy for primary cutaneous aggressive epidermotropic cytotoxic T cell lymphoma.

B. Valacyclovir 500 mg twice daily for 3 days — Incorrect. This is the treatment for recurrent herpes simplex virus infection.

C. Benzathine penicillin G 2.4 million units intramuscular weekly for 3 weeks — Correct. Most cases of malignant syphilis have responded more significantly to this treatment rather than a single dose of penicillin, which is usually the treatment of choice for secondary syphilis. Due to this patient's syphilitic uveitis, she was treated with intravenous penicillin G for 14 days, as well as sub-Tenon triamcinolone, to reflect treatment guidelines for ocular syphilis.

D. Doxycycline 100 mg twice daily for 4 weeks — Incorrect. While this treatment has been proven to be effective in penicillin-allergic patients, it is not a first-line treatment.

E. Prednisone 30 mg daily for 7 days — Incorrect. Prednisone can be used to treat Jarisch-Herxheimer reactions, which are common in patients with malignant syphilis.

Abbreviations used:

EBV: Epstein–Barr virus
EN: erythema nodosum
HIV: human immunodeficiency virus
IBD: inflammatory bowel disease
NME: Necrolytic migratory erythema
PG: pyoderma gangrenosum
SLE: Systemic lupus erythematosus

Conflicts of interest

None disclosed.

REFERENCES

1. Forrestel AK, Kovarik CL, Katz KA. Sexually acquired syphilis: laboratory diagnosis, management, and prevention. *J Am Acad Dermatol*. 2020;82(1):17-28. <https://doi.org/10.1016/j.jaad.2019.02.074>
2. Petrozzi JW, Lockshin NA, Berger BJ. Malignant syphilis: severe variant of secondary syphilis. *Arch Dermatol*. 1974;109(3):387-389. <https://doi.org/10.1001/archderm.109.3.387>
3. Wibisono O, Idrus I, Djawad K. Malignant syphilis: a systematic review of the case reports published in 2014-2018. *Actas Dermosifiliogr (Engl Ed)*. 2021;21. <https://doi.org/10.1016/j.adengl.2021.05.014>
4. Tosca A, Stavropoulos PG, Hatzioleu E, et al. Malignant syphilis in HIV-infected patients. *Int J Dermatol*. 1990;29(8):575-578. <https://doi.org/10.1111/j.1365-4362.1990.tb03472.x>