



The protective effect of Papaverine and Alprostadil in rat testes after ischemia and reperfusion injury

Mehmet Ali Karagoz¹, Omer Gokhan Doluoglu¹, Hatice Ünverdi², Berkan Resorlu³, Mehmet Melih Sunay⁴, Arif Demirbas⁴, Tolga Karakan^{1,4}, Arif Aydin⁵

¹ Department of Urology, Ankara Training and Research Hospital, Ankara, Turkey; ² Department of Pathology Ankara Training Research Hospital, Ankara, Turkey; ³ Department of Urology, Faculty of Medicine, Canakkale Onsekiz Mart University, Canakkale, Turkey; ⁴ Sağlık Bakanligi Ankara Eğitim ve Araştırma Hastanesi Ankara, Ankara, Turkey; ⁵ Department of Urology, Faculty of Medicine, Necmettin Erbakan University Meram, Konya, Turkey

ABSTRACT

Objective: To investigate the effect of papaverine and alprostadil on testicular torsion-detorsion injury in rats.

Materials and Methods: A total of 40 male Wistar-Albino rats were used in this study. Four hours of right testicular torsion was applied to each group, excluding sham operated group. The torsion-detorsion (T/D), T/D + papaverine and T/D + alprostadil groups received saline, papaverine and alprostadil at the same time as surgical detorsion, respectively. At 14 days after the surgical detorsion, ischaemic changes and the degree of damage were evaluated with Cosentino scoring and the Johnson tubular biopsy score (JTBS).

Results: JTBS was determined as 8.8 ± 2.7 in the Sham group, 5.08 ± 1.9 in the T/D + papaverine group, 5.29 ± 2.3 in the T/D + alprostadil group and 2.86 ± 1.9 in the TD group. The JTBS was determined to be statistically significantly high in both the T/D + papaverine group and the T/D + alprostadil group compared to the T/D group ($p=0.01$, $p=0.009$). In the T/D + papaverine group, 3 (43 %) testes were classified as Cosentino 2, 3 (43%) as Cosentino 3 and 1 (14 %) as Cosentino 4. In the T/D + alprostadil group, 5 (50 %) testes were classified as Cosentino 2, 3 (30 %) as Cosentino 3 and 2 (20%) as Cosentino 4.

Conclusion: The present study indicated that spermatic cord administration of alprostadil and papaverine showed a protective effect against ischemia/reperfusion injury after right-side testes torsion and histological changes were decreased after testicular ischemia reperfusion injury.

ARTICLE INFO

Keywords:

Papaverine; Alprostadil; Spermatic Cord Torsion

Int Braz J Urol. 2018; 44: 617-22

Submitted for publication:
November 09, 2017

Accepted after revision:
January 22, 2018

Published as Ahead of Print:
February 28, 2018

INTRODUCTION

Testicular torsion is an urological emergency that may result in ischemia and necrosis of the testes. If not recognized in time, torsion may lead to ischemic injury and loss of the testes (1-3). Testicular damage varies depending

on the grade and duration of the torsion (4).

To ensure blood flow, surgical detorsion is required in all cases. Reperfusion of the ipsilateral testes after ischemia results in overproduction of free oxygen radicals (FORs), cytokines, and adhesion molecules, in addition to the migration of leukocytes (5, 6). The main patho-

physiology of testicular torsion/detorsion (T/D) seems to be ischemia/reperfusion (I/R) injury of the testes. FORs and cytokines are major initiating components of the testicular injury. The administration of vasodilator drugs has potential antioxidant and therapeutic effects on I/R injury of the testes (7). To the best of our knowledge, no study has investigated the role of alprostadil in testicular I/R injury and only one study could be found in literature related to the protective effect of papaverine on testicular I/R injury. The aim of this study was to investigate the protective role of papaverine and alprostadil in testicular I/R injury.

MATERIALS AND METHODS

Following approval from the Local Ethics Committee (No: 4/5/15-367) a total of 40 male Wistar-Albino rats, each weighing 250-300 grams, were included in the study. All rats were fed with standard laboratory rat chow and water ad libitum on a 12 hour light/dark cycle at 21-24°C. All animals were handled in compliance with the recommendations of the animal care committee of the university and the Principles of Laboratory Animal Care (NIH publication No: 85-23, revised 1985).

Rats were randomly divided into 4 groups as follows: sham operated, torsion/detorsion group (T/D), T/D+papaverine group, and T/D+alprostadil group. The rats were anesthetized with the administration of 50mg/kg ketamine hydrochloride and 10mg/kg xylazine hydrochloride under aseptic conditions.

In the sham group (n=10), the right testes was removed through the incision and then replaced in the scrotum. In this group, no T/D procedure was performed. In the T/D group (n=10), saline (2mL of 0.9% NaCl) was injected by using 30 gauge needle into the spermatic cord at the same time as detorsion was applied. In the T/D+papaverine group (n=10), 2mL of papaverine (20mg/kg) was injected by using 30 gauge needle into the last 1cm part of the spermatic cord at the same time as detorsion. In the T/D+alprostadil (20µg/kg) group (n=10), 2mL of alprostadil was injected by using 30 gauge needle into the last 1cm of spermatic cord at the same time as detorsion. Torsion was induced by twisting the right-side testis 720 in a clockwise direction and

this position was maintained for 4 hours by fixing the testes to the scrotum with 4/0 polyglactin (Vicryl; Ethicon Inc, Johnson&Johnson Co., Somerville, NJ,USA). At the end of the testicular ischemia period, the testes were released and restored to the normal position to allow reperfusion. After this operation, the rats were fed for 14 days and were then euthanised and right orchiectomy was performed. In the 14 day postoperative care period, 3 rats died in the T/D+papaverine group, so examination could only be made of 7 rats in that group.

The testicular tissue was fixed in 10% formaldehyde for histological analyses. Tissue sections of 4 micrometer thickness were stained with hematoxylin-eosin and evaluated by an experienced genitourinary pathologist. Ischaemic changes in the testes and the degree of damage were evaluated with Cosentino scoring (8) and the Johnson tubular biopsy score (JTBS). In Cosentino scoring, the testis is classified in 4 grades. Grade 1 to 4 stands for normal testis parenchyma to coagulation necrosis in the parenchyma. JTBS was developed to examine spermatogenesis histopathologically after testicular damaging circumstances. A Johnson score of 9 or 10 represents normal histology, a score of 8 hypospermatogenesis, 3-7 maturation arrest, 2 germinal cell aplasia and a score of 1, tubular fibrosis (9).

The data analysis was performed using SPSS for Windows, version 23.0 (SPSS Inc., Chicago, IL, USA). Conformity to normality of distribution was tested with P-P plot and Kolmogorov-Smirnov tests. Kruskal Wallis variance analysis was used for intergroup comparisons of continuous variables (Post hoc: Bonferroni), and the Chi square test was used for the comparison of categorical variables. Descriptive statistics for variables with non-normal distribution and nominal variables were presented as median (min-max) and the number of cases (n) and percentage (%), respectively. A value of $p < 0.05$ was considered statistically significant.

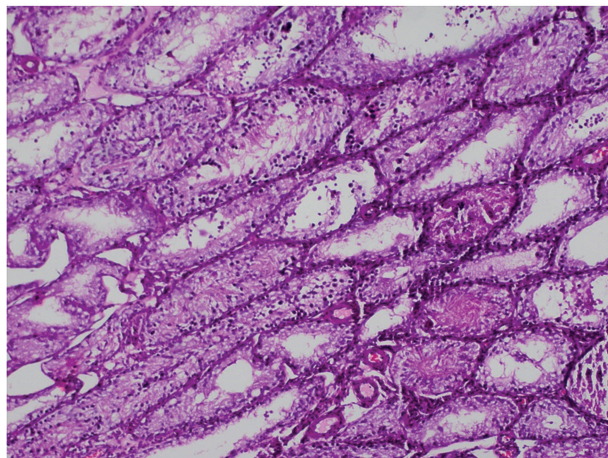
RESULTS

In the histopathological evaluation of removed right testes, 9 (90 %) testes in the sham group were determined as Cosentino Grade 1, and 1 as Grade 4. In the T/D group, 5 (50%) testes were

Cosentino Grade 3 and 5 (50%) were Grade 4. In the T/D+papaverine group, 3 (43%) testes were Cosentino Grade 2 (Figure-1), 3 (43%) were Grade 3 and 1 (14%) was Grade 4.

In the T/D+alprostadil group, 5 (50%) testes were Cosentino Grade 2, 3 (30%) were Grade 3 (Figure-2) and 4 (20%) were Grade 4 (Figure-3).

Figure 1 - Histopathology image of the testis parenchyma obtained from the papaverine group (Group 3) (Cosentino Grade 2).



The Cosentino scores of the T/D+papaverine group were determined to be better than those of the T/D group but the difference was not statistically significant ($p=0.55$). The Cosentino histopathological findings of the T/D+alprostadil group were observed to be significantly better than those of the T/D group ($p=0.03$). The Cosentino grades of the papaverine and alprostadil groups were seen to be similar ($p=0.85$).

The JTBS was determined as 5.08 ± 1.9 in the T/D+papaverine group, 5.29 ± 2.3 in the T/D+alprostadil group and 2.86 ± 1.9 in the T/D group. The JTBS was determined to be statistically significantly high in both the T/D+papaverine group and the T/D+alprostadil group compared to the T/D group ($p=0.01$, $p=0.009$) (Figure-4).

DISCUSSION

Testicular torsion is a medical emergency seen in males, particularly in adolescence, but also

Figure 2 - Histopathology image of the testis parenchyma obtained from the alprostadil group (Group 5) (Cosentino Grade 3).

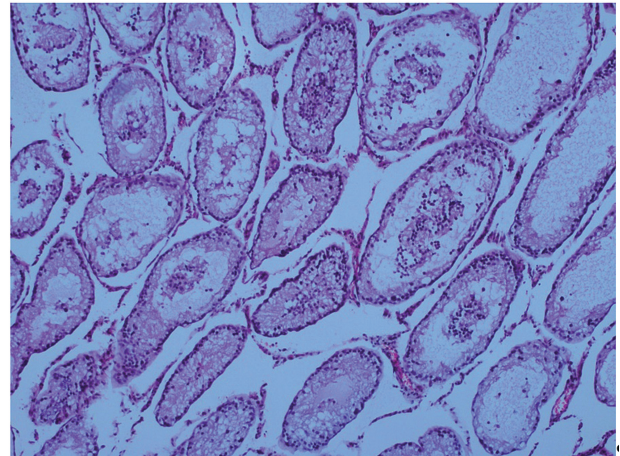
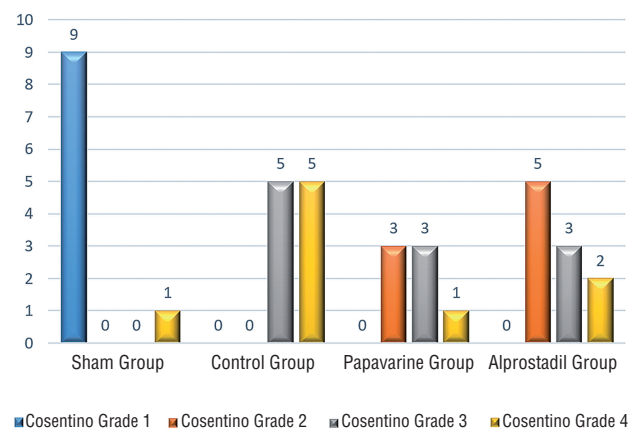


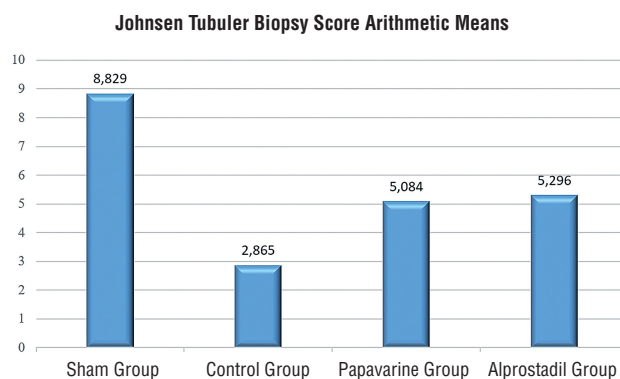
Figure 3 - Distribution of the groups according to Cosentino grades.



in childhood and young adulthood (10). To prevent loss of testicular function, surgical detorsion must be applied as an emergency in the treatment. It is necessary to obtain regular testicular blood flow to be able to continue normal spermatogenesis. Hypoxia is the main reason for testicular damage following testicular torsion (11). Although detorsion (reperfusion) provides correction of the blood flow, it can lead to additional dangers for the testis and this is known as reperfusion injury (12-15).

Reperfusion injury results in the formation of toxic FORs together with increased blood

Figure 4 - Distribution of the arithmetic means of the Johnsen Tubuler Biopsy Scores of the groups.



flow after ischaemia (12, 16). At the same time, a local and systemic inflammatory response develops. The complementary activation of leukocyte migration and platelet-leukocyte aggregation causes an increase in microvascular permeability (17-19). As a result of these events, testicular damage progresses further. To protect the testis from all forms of oxidative stress and I/R damage, many chemical agents have been tested in experimental studies. Despite successful results, it has still not been possible for these agents to come into clinical use as their use has not been possible on humans because of severe side-effects (7, 20).

Papaverine is an opium alkaloid used in the treatment of vasospasm and erectile dysfunction (15). Papaverine has also been used by direct application to the blood vessels as a smooth muscle relaxant in microsurgery. By inhibiting phosphodiesterase enzyme, the adenosine monophosphate (cAMP) level is usually increased. Another important effect which is formed is a change in mitochondrial respiration (14, 21). Some researchers have stated that sildenafil and other phosphodiesterase inhibitors may have anti-inflammatory properties by inhibiting ROS, leukocyte infiltration and inflammatory cytokines such as IL-1, IL-6 and TNF (22, 23).

The effect of alprostadil, which is a PGE1 analog, is shown through an increase in adenosine monophosphate (cAMP) with adenylate cyclase activation and by lowering the intracellular Ca^{++} level. With this effect, alprostadil leads to relaxation in the smooth muscle wall. Alprostadil

provides an immunosuppressive and cytoprotective effect with a reduction in leukocyte aggregation and a decrease in TNF expression. Increasing levels of TNF, P-selectin, E-selectin, ICAM-1 and VCAM-1 in ischaemia and reperfusion are significantly reduced with a PGE1 infusion (24). Therefore, activation and degranulation of macrophages and granulosis decrease. In transplanted pulmonary tissue, PGE1 has been shown to reduce the hypothermic thermal effect of ischaemia reperfusion damage and provide protection by increasing the acquisition of glucose and oxygen (25). This effect of PGE1 applied during reperfusion has been shown to be achieved by reducing pro and anti-inflammatory cytokine levels.

In previous studies that have evaluated ischaemia-reperfusion injury in different organs with papaverine and alprostadil, the drugs have been administered intravenously, intra-arterially or intraperitoneally. In the current study, considering that the dilatation effect could be greater in vascular structures, it was thought appropriate to administer papaverine and alprostadil directly into the spermatic cord.

For the histopathological evaluation of testicular deterioration in this study, Cosentino scoring and JTBS were used. In Cosentino scoring, the testis is classified in 4 grades. While Grade 1 shows normal testis parenchyma, Grade 4 testis shows coagulation necrosis in the parenchyma. Johnson et al. developed the JTBS to be able to evaluate spermatogenesis quantitatively following any event which has caused damage to the testis, and this is the currently most widely used scoring system in routine applications. This score gives a score for each seminiferous tubule in the biopsy material and the mean value is calculated for the examined tubules. A Johnson score of 9 or 10 represents normal histology, a score of 8 hypospermatogenesis, 3-7 maturation arrest, 2 germinal cell aplasia and a score of 1, tubular fibrosis (9).

In the revision of literature, it was found that protective effects of alprostadil were not evaluated before, by injection directly into spermatic cord, in a testicular T/D model. In the sham group, 9 testes were evaluated as Cosentino Grade 1 and 1 as Grade 4. The coagulation

necrosis seen in 1 was probably related to artery damage during surgery. In 50% of the rats applied with alprostadil, there was a mild degree of deterioration in the alignment of germ cells in the seminiferous tubules and a loss of cohesion in the cells (Grade 2). Only 2 of the testes were Cosentino Grade 4. A significant degree of improvement was observed in the mean JTBS in the alprostadil group compared with the control group ($p=0.009$).

In the revision of literature, it was found that only one study which has attempted to determine whether or not papaverine has a protective effect on I/R injury in the testes; 35 rats were separated into 5 groups (control, sham-operated, verapamil-treated, lidocaine-treated and papaverine treated). In that study, papaverine did not show any protective effect in respect of sperm count, motility or morphology (26). In contrast, in the current study, the JTBS of the papaverine group was determined to be significantly higher than that of the T/D group. Cosentino Grade 2 was determined in 3 (43%) rats of this group. Although a histopathological improvement was seen compared to the T/D group, the difference was not statistically significant. However, as the evaluation of this group was made on 7 rats, there could be Type II error in the findings.

CONCLUSIONS

In the results of the current study, a significant improvement was observed in the JTBS with the application of both papaverine and alprostadil. Protective effects were determined histopathologically in the Cosentino grades with both drugs, although papaverine was not statistically significant. According to these results, these drugs applied to the spermatic cord during detorsion in rats have a useful, protective effect on testicular injury. To clarify the protective effects of these drugs, there is a need for further studies using different doses and different administration pathways.

CONFLICT OF INTEREST

None declared.

REFERENCES

1. Visser AJ, Heyns CF. Testicular function after torsion of the spermatic cord. *BJU Int.* 2003;92:200-3.
2. Pogorelić Z, Mrklič I, Jurić I, Biočić M, Furlan D. Testicular torsion in the inguinal canal in children. *J Pediatr Urol.* 2013;9(6 Pt A):793-7.
3. Pogorelić Z, Mrklič I, Jurić I. Do not forget to include testicular torsion in differential diagnosis of lower acute abdominal pain in young males. *J Pediatr Urol.* 2013;9(6 Pt B):1161-5.
4. Gökçe A, Oktar S, Koc A, Gonenci R, Yalcinkaya F, Yonden Z, et al. Protective effect of thymoquinone in experimental testicular torsion. *Urol Int.* 2010;85:461-5.
5. Zimmerman BJ, Granger DN. Reperfusion injury. *Surg Clin North Am.* 1992;72:65-83.
6. Reilly PM, Schiller HJ, Bulkley GB. Pharmacologic approach to tissue injury mediated by free radicals and other reactive oxygen metabolites. *Am J Surg.* 1991;161:488-503.
7. Meštrović J, Drmić-Hofman I, Pogorelić Z, Vilović K, Šupe-Domić D, Šešelja-Perišin A, et al. Beneficial effect of nifedipine on testicular torsion-detorsion injury in rats. *Urology.* 2014;84:1194-8.
8. Cosentino MJ, Nishida M, Rabinowitz R, Cockett AT. Histopathology of prepubertal rat testes subjected to various durations of spermatic cord torsion. *J Androl.* 1986;7:23-31.
9. Johnsen SG. Testicular biopsy score count--a method for registration of spermatogenesis in human testes: normal values and results in 335 hypogonadal males. *Hormones.* 1970;1:2-25.
10. Yagmurdu H, Ayyildiz A, Karaguzel E, Ogus E, Surer H, Caydere M, et al. The preventive effects of thiopental and propofol on testicular ischemia-reperfusion injury. *Acta Anaesthesiol Scand.* 2006;50:1238-43.
11. Akgür FM, Kiling K, Tanyel FC, Büyükpamukçu N, Hiçsönmez A. Ipsilateral and contralateral testicular biochemical acute changes after unilateral testicular torsion and detorsion. *Urology.* 1994;44:413-8.
12. Erol B, Tokgoz H, Hanci V, Bektas S, Akduman B, Yencilek F, et al. Vardenafil reduces testicular damage following ischemia/reperfusion injury in rats. *Kaohsiung J Med Sci.* 2009;25:374-80.
13. Karbalay-Doust S, Noorafshan A, Ardekani FM, Mirkhani H. The reversibility of sperm quality after discontinuing nandrolone decanoate in adult male rats. *Asian J Androl.* 2007;9:235-9.
14. Kim YJ, Hong HK, Lee HS, Moh SH, Park JC, Jo SH, et al. Papaverine, a vasodilator, blocks the pore of the HERG channel at submicromolar concentration. *J Cardiovasc Pharmacol.* 2008;52:485-93.

15. Kocailik A, Basaran M, Ugurlucan M, Ozbek C, Kafali E, Yerebakan C, et al. Papaverine solution improves preservation of saphenous vein grafts used during cardiac surgery. *Acta Cardiol.* 2008;63:445-9.
16. Turner TT, Bang HJ, Lysiak JL. The molecular pathology of experimental testicular torsion suggests adjunct therapy to surgical repair. *J Urol.* 2004;172(6 Pt 2):2574-8.
17. Elshaari FA, Elfagih RI, Sherif DS, Barassi IF. Oxidative and antioxidative defense system in testicular torsion/detorsion. *Indian J Urol.* 2011;27:479-84.
18. Wei SM, Yan ZZ, Zhou J. Protective effect of rutin on testicular ischemia-reperfusion injury. *J Pediatr Surg.* 2011;46:1419-24.
19. Dirksen MT, Laarman GJ, Simoons ML, Duncker DJ. Reperfusion injury in humans: a review of clinical trials on reperfusion injury inhibitory strategies. *Cardiovasc Res.* 2007;74:343-55.
20. Şener TE, Yüksel M, Özyilmaz-Yay N, Ercan F, Akbal C, Şimşek F, et al. Apocynin attenuates testicular ischemia-reperfusion injury in rats. *J Pediatr Surg.* 2015;50:1382-7.
21. Morikawa N, Nakagawa-Hattori Y, Mizuno Y. Effect of dopamine, dimethoxyphenylethylamine, papaverine, and related compounds on mitochondrial respiration and complex I activity. *J Neurochem.* 1996;66:1174-81.
22. Koupparis AJ, Jeremy JY, Muzaffar S, Persad R, Shukla N. Sildenafil inhibits the formation of superoxide and the expression of gp47 NAD[P]H oxidase induced by the thromboxane A2 mimetic, U46619, in corpus cavernosal smooth muscle cells. *BJU Int.* 2005;96:423-7.
23. Toward TJ, Smith N, Broadley KJ. Effect of phosphodiesterase-5 inhibitor, sildenafil (Viagra), in animal models of airways disease. *Am J Respir Crit Care Med.* 2004;169:227-34.
24. Hafez T, Moussa M, Nesim I, Baligh N, Davidson B, Abdul-Hadi A. The effect of intraportal prostaglandin E1 on adhesion molecule expression, inflammatory modulator function, and histology in canine hepatic ischemia/reperfusion injury. *J Surg Res.* 2007;138:88-99.
25. de Perrot M, Fischer S, Liu M, Jin R, Bai XH, Waddell TK, et al. Prostaglandin E1 protects lung transplants from ischemia-reperfusion injury: a shift from pro- to anti-inflammatory cytokines. *Transplantation.* 2001;72:1505-12.
26. Shirazi M, Noorafshan A, Karbalay-Doust S, Ardeshiri M, Afrasiabi MA, Monabati A. Comparison of the protective effects of papaverine, lidocaine and verapamil on the sperm quality of the testis after induced torsion-detorsion in rats. *Scand J Urol Nephrol.* 2010;44:133-7.

Correspondence address:

Mehmet Ali Karagoz, MD
Department of Urology
Ankara Training and Research Hospital
Ankara, Turkey
E-mail: dr_mali@msn.com