

Spinal arthrodesis via lumbar interbody fusion without direct decompression as a treatment for recurrent radicular pain due to epidural fibrosis: patient series

Kevin Swong, MD, Michael J. Strong, MD, PhD, Jay K. Nathan, MD, Timothy J. Yee, MD, Brandon W. Smith, MD, MS, Paul Park, MD, and Mark E. Oppenlander, MD

Department of Neurosurgery, University of Michigan, Ann Arbor, Michigan

BACKGROUND Lumbar radiculopathy is the most common indication for lumbar discectomy, but residual postoperative radicular symptoms are common. Postoperative lumbar radiculopathy secondary to scar formation is notoriously difficult to manage, with the mainstay of treatment focused on nonoperative techniques. Surgical intervention for epidural fibrosis has shown unacceptably high complication rates and poor success rates.

OBSERVATIONS Three patients underwent spinal arthrodesis without direct decompression for recurrent radiculopathy due to epidural fibrosis. Each patient previously underwent lumbar discectomy but subsequently developed recurrent radiculopathy. Imaging revealed no recurrent disc herniation, although it demonstrated extensive epidural fibrosis and scar in the region of the nerve root at the previous surgical site. Dynamic radiographs showed no instability. Two patients underwent lateral lumbar interbody fusion, and one patient underwent anterior lumbosacral interbody fusion. Each patient experienced resolution of radicular symptoms by the 1-year follow-up. Average EQ visual analog scale scores improved from 65 preoperatively to 78 postoperatively.

LESSONS Spinal arthrodesis via lumbar interbody fusion, without direct decompression, may relieve pain in patients with recurrent radiculopathy due to epidural fibrosis, even in the absence of gross spinal instability.

<https://thejns.org/doi/abs/10.3171/CASE2173>

KEYWORDS anterior lumbar interbody fusion; epidural fibrosis; lateral interbody fusion; lumbar radiculopathy; spine

Lumbar radiculopathy is the most common indication for lumbar discectomy, with an estimated incidence of 300,000 operations per year.^{1,2} Unfortunately, in a subset of patients, surgical results may not be durable. Up to 29% of patients experience residual radicular symptoms.³ Etiologies for recurrent radiculopathy after surgical decompression include disc reherniation, failure to adequately decompress the neural elements, iatrogenic instability, and postoperative epidural fibrosis and scar.^{4,5} Postoperative pain secondary to epidural fibrosis is notoriously difficult to manage, particularly with repeat operation, and the mainstay of treatment focuses on nonsurgical interventions such as medications, steroid injections, and spinal cord or peripheral nerve stimulators.⁶ Surgical interventions at the index location have previously demonstrated significantly poor results, with only 30% of patients improving and up to 20% of patients experiencing worsening of symptoms.⁷ Reoperation also carries the

inadvertent risks of durotomy with cerebrospinal fluid (CSF) leakage, nerve injury, and infection on a greater magnitude than during the index procedure.⁶ Given these increased risks combined with the dismal clinical outcomes, surgical intervention for persistent pain from epidural fibrosis is not routinely recommended.⁶

Considering the pathophysiology of recurrent radiculopathy secondary to postoperative scar and fibrosis may allow for additional treatment strategies, however. Prior studies have demonstrated abnormal motion at the site of spinal pathology as a cause of clinical symptoms, including radiculopathy and/or myelopathy, and have concluded that fusion alleviates the clinical symptoms.^{8,9} We postulate that micromotion at the index spinal level in the setting of epidural fibrosis may create a tethering phenomenon whereby clinical radiculopathy of that nerve root is exacerbated, even in the absence of gross radiographic instability. Thus, fixation and fusion at

ABBREVIATIONS BMP = bone morphogenic protein; CSF = cerebrospinal fluid; MRI = magnetic resonance imaging; PEEK = polyetheretherketone.

INCLUDE WHEN CITING Published May 17, 2021; DOI: 10.3171/CASE2173.

SUBMITTED February 10, 2021. **ACCEPTED** March 18, 2021.

© 2021 The authors, CC BY-NC-ND 4.0 (<http://creativecommons.org/licenses/by-nc-nd/4.0/>).

the index level to stabilize the micromotion may decrease a patient's radicular symptomatology without direct decompression. Here, we report a series of patients who underwent spinal arthrodesis via lumbar interbody fusion as a treatment for recurrent radiculopathy secondary to epidural fibrosis after previous lumbar discectomy.

Study Description

Patient Population

This study was reviewed and approved by the Institutional Review Board of the University Hospital. Informed consent for spinal surgery was obtained for each patient. For this case series, we reviewed three consecutive patients who presented with recurrent lumbar radiculopathy and had a history of lumbar discectomy performed at outside hospitals. Imaging in all three patients showed enhancing epidural scar in the region of prior surgery but no evidence of recurrent disc herniation or spinal instability. Patients underwent spinal fusion without direct decompression between July 2017 and January 2019.

Case 1

A 66-year-old man presented to the neurosurgical clinic for evaluation and management of recurrent radicular pain after a previously successful L3–4 decompression and microdiscectomy at an outside institution 9 months earlier. The patient stated that approximately 6 weeks after his index operation, he began to experience pain and numbness radiating from his low back into his right buttock, medial thigh, knee, and medial lower leg. He reported that his lower extremity symptoms were considerably more bothersome than the back pain. He was without left lower extremity symptoms or dysfunction of bowel or bladder. He demonstrated full strength on confrontational testing of the lower extremities. Magnetic resonance imaging (MRI) of the lumbar spine with and without gadolinium contrast demonstrated avid postcontrast enhancement in the region of the previously decompressed right L3 and L4 nerve roots, consistent with periepidural fibrosis (Fig. 1A and B). There was no evidence of recurrent disc herniation. Radiographs did not demonstrate dynamic instability. His symptoms were refractory to conservative management, including medications, physical therapy, and epidural steroid injections. With a lack of improvement after conservative therapy, he was offered spinal arthrodesis without direct decompression at the index level.

He underwent a left-sided, lateral, retroperitoneal, transpsoas approach for L3–4 interbody fusion with intraoperative spinal navigation and lateral plate and screw fixation. A polyetheretherketone (PEEK) interbody cage with demineralized bone matrix and bone morphogenic protein (BMP) was used (Fig. 1C). Estimated blood loss was 30 mL, the length of the procedure was 129 minutes, and there were no surgical complications.

Case 2

A 42-year-old woman who underwent an L3–4 left far lateral microdiscectomy for radicular pain at an outside institution presented to our neurosurgical clinic 14 months after the index operation for evaluation of continued radicular pain and progressive left lower extremity weakness. She reported low back pain radiating into the left buttock and medial thigh. She demonstrated 4/5 strength with left knee extension but otherwise had full strength in the lower extremities. She was without right lower extremity symptoms or dysfunction of bowel or bladder. MRI with and without contrast (Fig. 2A and B)

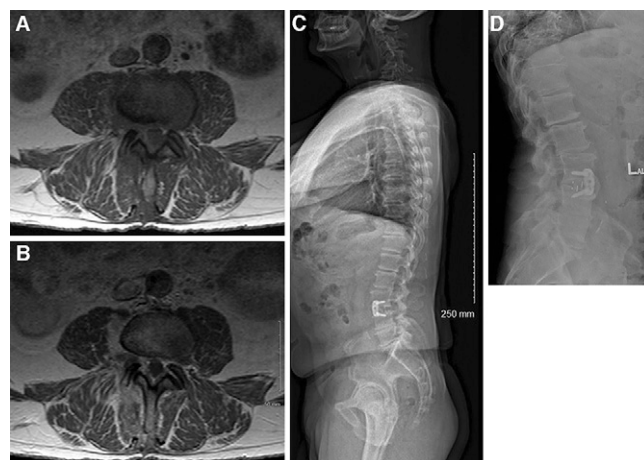


FIG. 1. MRI demonstrating clinical course of patient in case 1, a 66-year-old male with epidural fibrosis undergoing lateral lumbar interbody fusion. Axial T1 (A) and T1-weighted (B) images demonstrate presence of epidural fibrosis around the lateral recesses and tracking along the exiting nerve root on the right. C: Lateral standing radiograph shows placement of interbody cage at L3–4. D: Lateral standing radiograph at 1-year follow-up demonstrating stable construct, stable spinal alignment, no hardware failure, and evidence of arthrodesis.

demonstrated epidural fibrosis around the exiting L3 nerve root on the left. Radiographs showed no dynamic instability. Physical therapy and L3–4 transforaminal epidural steroid injections had failed. She was offered spinal arthrodesis without direct decompression. Similar to the patient in case 1, this patient underwent a left-sided, lateral, retroperitoneal, transpsoas approach for L3–4 interbody

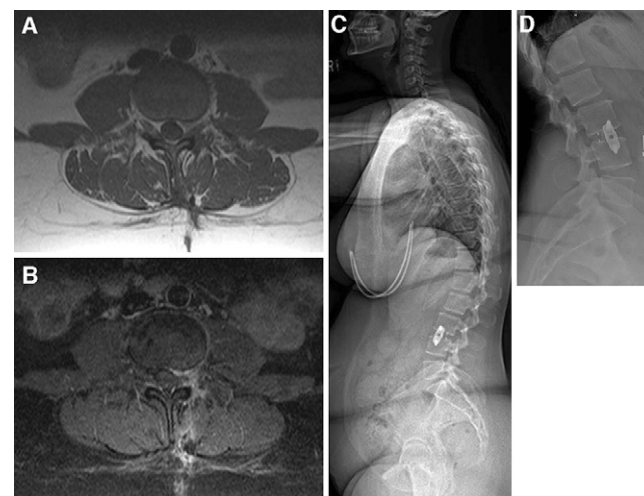


FIG. 2. MRI demonstrating clinical course of patient in case 2, a 42-year-old female with extensive epidural fibrosis undergoing lateral lumbar interbody fusion. Axial T1 (A) and T1-weighted (B) images demonstrate presence of epidural fibrosis around lateral recess with extension along the exiting nerve root on the left. C: Lateral standing radiograph demonstrates interbody cage at L3–4. D: Lateral standing radiograph at 1-year follow-up demonstrating stable construct, stable spinal alignment, no hardware failure, and evidence of arthrodesis.

fusion with intraoperative spinal navigation and lateral plate and screw fixation. A PEEK interbody cage with demineralized bone matrix and BMP was used (Fig. 2C). Estimated blood loss was 20 mL, the length of the procedure was 105 minutes, and there were no surgical complications.

Case 3

A 37-year-old man presented to our clinic for recurrent radicular leg pain after a left L5–S1 microdiscectomy for radicular pain 1 year earlier. The patient reported relief of symptoms for several days after the index operation but soon experienced progressive pain radiating from the left buttock down the posterior aspect of the thigh and into the popliteal fossa. He denied right lower extremity symptoms or dysfunction of bowel or bladder. On examination, he demonstrated full strength in the bilateral lower extremities. Conservative measures, including physical therapy and selective nerve root injections, had failed. MRI with and without contrast demonstrated epidural fibrosis surrounding the left S1 nerve root within the surgical corridor (Fig. 3A and B). Radiographs showed no dynamic instability; therefore, he was offered lumbosacral fusion. Given the lack of evidence of disc herniation, an anterior approach was chosen for interbody fusion at L5–S1. Similar to the lateral approach for cases 1 and 2, the anterior approach allowed placement of a larger interbody graft than that permitted with a posterior transforaminal approach, and it reduced the risk of CSF leakage and nerve root injury. Vascular surgery provided access to the L5–S1 disc space. A PEEK cage with BMP and demineralized bone matrix was used for arthrodesis (Fig. 3C). Shim fixation through the interbody

cage was used for fixation. Estimated blood loss was 50 mL, the length of the procedure was 200 minutes, and there were no surgical complications.

Results

The average length of stay for the three patients was 4 days. All three patients reported resolution of their radicular pain at their initial 6-week follow-up visit. At the 1-year follow-up, all three patients noted continued absence of their radicular pain, and imaging revealed stable construct, stable spinal alignment, no hardware failure, and evidence of interbody arthrodesis (Figs. 1D, 2D, 3D). The preoperative average EQ visual analog scale score was 65 for the three patients, which improved to an average score of 78 postoperatively. Additionally, all three patients reported satisfaction with their procedure and attested that they would undergo surgery again. Of note, the patient in case 3 initially presented to our clinic unable to work because of recurrent pain from his index operation, but he was able to return to work after the described spinal arthrodesis.

Discussion

Observations

The source for postoperative recurrent radiculopathy after previously successful laminectomy and discectomy may be multifactorial. Several studies have pointed to the formation of epidural fibrosis as a significant causative factor for recurrent symptomatology, with the amount of fibrosis strongly correlating to the degree of reported pain.^{4,10} Techniques have been used in an attempt to prevent epidural fibrosis formation in situ with mixed results,^{11–13} but none of the methods have led to a clinically meaningful reduction in the pain attributed to postprocedural epidural fibrosis formation.¹² Lumbar spinal instability has been proposed as one reason some patients form more epidural fibrosis. Although no study has definitively shown a causal link between instability and epidural fibrosis, a study by Schaller⁵ found that the amount of periepidural fibrosis positively correlated with the amount of postoperative instability. Furthermore, the author proposed that epidural fibrosis may cause tethering of the passing nerve, which in turn may cause irritation of the nerve and subsequent pain with motion. In Schaller's series,⁵ patients were diagnosed with gross radiographic spinal instability and treated with revision laminectomy and posterior arthrodesis.

The current series of patients demonstrated neither gross instability on dynamic radiography nor compressive recurrent disc herniation. Rather, imaging revealed avid enhancement along the affected nerve root suggestive of exuberant epidural fibrosis. Spinal arthrodesis via interbody fusion was used to stabilize the presumed micromotion around the scarred nerve, from either a lateral or an anterior lumbar approach. This strategy avoided repeat dissection through scar and accomplished the goal of stabilization and arthrodesis. Because no gross radiographic instability was noted, a single-approach interbody fusion with fixation provided adequate biomechanics to induce arthrodesis, thus avoiding an additional approach for pedicle screw fixation and decreasing operative time and blood loss. The favorable clinical outcomes in these patients suggest that a single-approach interbody fusion may be adequate in such clinical scenarios.

Additional treatment modalities exist for patients with recurrent lumbar radiculopathy due to epidural fibrosis, including nonoperative measures, spinal cord stimulation, and adhesiolysis of the epidural fibrosis. These modalities, however, have not provided lasting relief for this patient population. After spinal cord stimulation, lumbosacral

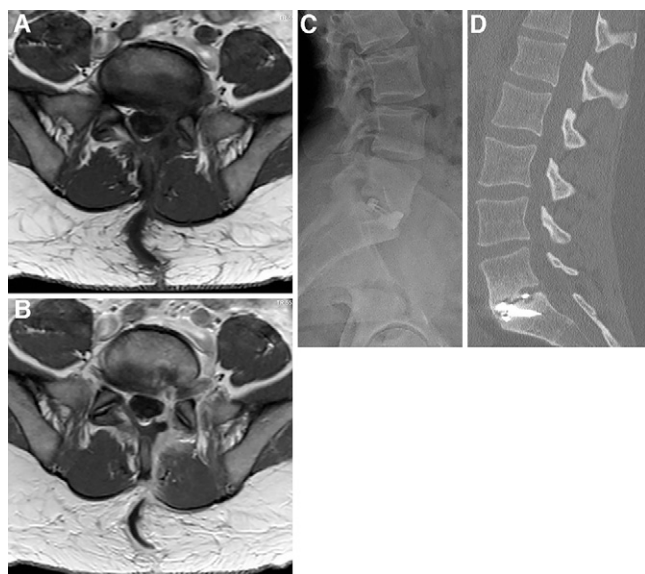


FIG. 3. MRI demonstrating clinical course of patient in case 3, a 37-year-old male with epidural fibrosis undergoing anterior lumbosacral interbody fusion. Axial T1 (A) and T1-weighted (B) images demonstrate presence of epidural fibrosis around the lateral recesses, greater on the left, with tracking along the exiting nerve root on the right. C: Lateral standing radiograph demonstrates interbody cage at L5–S1. D: Sagittal computed tomography at 1-year follow-up demonstrating stable construct, stable spinal alignment, no hardware failure, and evidence of arthrodesis.

radicular pain relief ranges from only 53% to 73% in reported series.¹⁴ More recently, adhesiolysis has been advocated as a means of removing the offending compressive lesion.⁶ Two methods of adhesiolysis have been used: percutaneous and endoscopic. Endoscopic epiduroscopy provides the advantage of directly visualizing the amount of epidural fibrosis with a more precise delivery of the adhesiolysing agent. Complications from endoscopic epiduroscopy, however, have been reported to be severe, including blindness, headaches, CSF leakage, and nerve injury.¹⁵ Additionally, reported studies of patients undergoing adhesiolysis contain a wide range of patients with epidural fibrosis; some patients did not have prior surgery, and the degree of radicular pain compared to back pain experienced by the patients was unclear from the literature.¹⁵ Manchikanti et al.¹⁶ studied a group of 83 patients with lower back pain thought to be due to epidural fibrosis. Eighty-four percent of the patients had prior lumbar surgery. With endoscopic adhesiolysis, only 48% of patients were able to attain pain relief by the 1-year follow-up.

Open exploration of the affected nerve root with adhesiolysis may also result in poor patient outcomes. In a series of patients with recurrent radiculopathy after lumbar microdiscectomy, five patients had symptoms due to epidural fibrosis.⁶ None of these patients experienced meaningful pain relief after open adhesiolysis of the epidural fibrosis.⁶ Given the almost universally poor results, open surgical intervention for epidural fibrosis has been discouraged.⁶

Although earlier surgical interventions for recurrent radicular pain have focused on exploration of the prior surgical site via a repeat posterior approach using either open or minimally invasive techniques,^{17–19} little evidence exists in the literature that spinal arthrodesis without direct decompression can accomplish relief of recurrent radiculopathy in the setting of an epidural scar. In the present study, we used lateral and anterior approaches for interbody fusion at the index level to address each patient's radicular symptomatology in the setting of epidural fibrosis. This approach provides several advantages. It avoids the known fibrosis and scar from the prior surgery, thereby potentially decreasing the risk of CSF leakage or nerve root injury. This approach also allows for a larger interbody graft to be placed than that permitted with a posterior approach for interbody fusion. Importantly, spinal arthrodesis eliminates potential micromotion at the index level, reducing tethering and irritation of the nerve. The postoperative improvement of radiculopathy observed in these patients lends support to the notion that a tethering phenomenon due to epidural fibrosis may be causative in patients with recurrent radiculopathy after lumbar discectomy who show no evidence of recurrent disc herniation. This phenomenon may occur even in patients without gross radiographic instability. This study is the first to describe spinal arthrodesis via lumbar interbody fusion, without direct decompression, as a treatment paradigm for patients with recurrent radiculopathy due to postoperative scar.

The present study has several limitations. It represents a small number of patients who were reviewed retrospectively at a single institution and without a control group for comparison. Further investigation with more patients is necessary to determine the efficacy of the proposed treatment paradigm. Despite these limitations, the technique discussed herein represents a novel and potentially effective approach for the treatment of a notoriously difficult clinical entity.

Lessons

Spinal arthrodesis via lumbar interbody fusion, without direct decompression, resulted in lasting pain relief in this patient population

with recurrent radiculopathy due to epidural fibrosis, even in the absence of gross spinal instability. Further investigation is warranted for comparison of outcomes with other treatment modalities in this patient population.

References

1. Daly CD, Lim KZ, Lewis J, et al. Lumbar microdiscectomy and postoperative activity restrictions: a protocol for a single blinded randomized controlled trial. *BMC Musculoskelet Disord*. 2017;18(1):312.
2. Parker SL, Xu R, McGirt MJ, et al. Long-term back pain after a single-level discectomy for radiculopathy: incidence and health care cost analysis. *J Neurosurg Spine*. 2010;12(2):178–182.
3. Suri P, Pearson AM, Zhao W, et al. Pain recurrence after discectomy for symptomatic lumbar disc herniation. *Spine (Phila Pa 1976)*. 2017;42(10):755–763.
4. Maroon JC, Abla A, Bost J. Association between peridural scar and persistent low back pain after lumbar discectomy. *Neurol Res*. 1999;21(suppl 1):S43–S46.
5. Schaller B. Failed back surgery syndrome: the role of symptomatic segmental single-level instability after lumbar microdiscectomy. *Eur Spine J*. 2004;13(3):193–198.
6. Phillips FM, Cunningham B. Managing chronic pain of spinal origin after lumbar surgery: the role of decompressive surgery. *Spine (Phila Pa 1976)*. 2002;27(22):2547–2554.
7. Braverman DL, Slipman CW, Lenrow DA. Using gabapentin to treat failed back surgery syndrome caused by epidural fibrosis: a report of 2 cases. *Arch Phys Med Rehabil*. 2001;82(5):691–693.
8. Goel A. Not neural deformation or compression but instability is the cause of symptoms in degenerative spinal disease. *J Craniovertebr Junction Spine*. 2014;5(4):141–142.
9. Goel A, Dharurkar P, Shah A, et al. Only spinal fixation as treatment of prolapsed cervical intervertebral disc in patients presenting with myelopathy. *J Craniovertebr Junction Spine*. 2017;8(4):305–310.
10. Merrild U, Sogaard I. Sciatica caused by perifibrosis of the sciatic nerve. *J Bone Joint Surg Br*. 1986;68(5):706.
11. Alkalay RN, Kim DH, Urry DW, et al. Prevention of postlaminectomy epidural fibrosis using bioelastic materials. *Spine (Phila Pa 1976)*. 2003;28(15):1659–1665.
12. Mohsenipour I, Daniaux M, Aichner F, Twerdy K. Prevention of local scar formation after operative discectomy for lumbar disc herniation. *Acta Neurochir (Wien)*. 1998;140(1):9–13.
13. Sen O, Kizilkilic O, Aydin MV, et al. The role of closed-suction drainage in preventing epidural fibrosis and its correlation with a new grading system of epidural fibrosis on the basis of MRI. *Eur Spine J*. 2005;14(4):409–414.
14. Fiume D, Sherkat S, Callovini GM, et al. Treatment of the failed back surgery syndrome due to lumbo-sacral epidural fibrosis. *Acta Neurochir Suppl (Wien)*. 1995;64:116–118.
15. Helm S, Hayek SM, Colson J, et al. Spinal endoscopic adhesiolysis in post lumbar surgery syndrome: an update of assessment of the evidence. *Pain Physician*. 2013;16(suppl 2):SE125–SE150.
16. Manchikanti L, Boswell MV, Rivera JJ, et al. A randomized, controlled trial of spinal endoscopic adhesiolysis in chronic refractory low back and lower extremity pain [ISRCTN 16558617]. *BMC Anesthesiol*. 2005;5:10.
17. Cauchoix J, Ficat C, Girard B. Repeat surgery after disc excision. *Spine (Phila Pa 1976)*. 1978;3(3):256–259.
18. Gadjradj PS, van Tulder MW, Dirven CM, et al. Clinical outcomes after percutaneous transforaminal endoscopic discectomy for lumbar disc herniation: a prospective case series. *Neurosurg Focus*. 2016;40(2):E3.
19. Qiao G, Feng M, Wang X, et al. Revision for endoscopic discectomy: is lateral lumbar interbody fusion an option? *World Neurosurg*. 2020;133:e26–e30.

Disclosures

Dr. Park reported personal fees from Globus Medical, NuVasive, and Allosource as well as grants from Pfizer, Vertex, Depuy, Cerapedics, and SI Bone outside the submitted work. Dr. Park is also involved in non-study-related research funded by the International Spine Study Group and Depuy. Dr. Oppenlander reported personal fees from Globus Medical, Bioventus Surgical, Depuy Spine, and LifeNet Health outside the submitted work.

Author Contributions

Conception and design: Oppenlander, Swong, Nathan, Smith.
Acquisition of data: Swong, Strong. Analysis and interpretation of data:

Oppenlander, Swong, Strong, Nathan, Yee. Drafting the article: Swong, Strong, Nathan, Yee, Smith. Critically revising the article: all authors. Reviewed submitted version of manuscript: Oppenlander, Swong, Strong, Nathan, Yee, Smith. Approved the final version of the manuscript on behalf of all authors: Oppenlander. Study supervision: Oppenlander.

Correspondence

Mark E. Oppenlander: University of Michigan, Ann Arbor, MI.
moppenla@med.umich.edu.